

THYROID ULTRASOUND

www.drHazhan.com
Hazhan@doctor.com



Patient Name: _____ Date: _____ Age: _____ Sex: F M

RT: ___ x ___ x ___ mm (___ mL) Isth: ___ mm

LT: ___ x ___ x ___ mm (___ mL)

Parenchyma: Homogeneous or Coarse

Contour: Smooth or Nodular

INDEX NODULE #1

Size: _____ (AP) x _____ (trv) x _____ (CC) mm

Size:
AP < Trv
AP > Trv

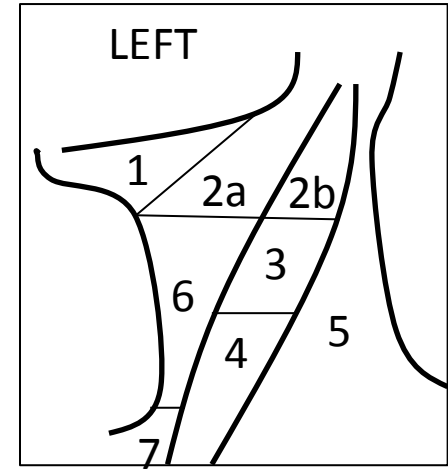
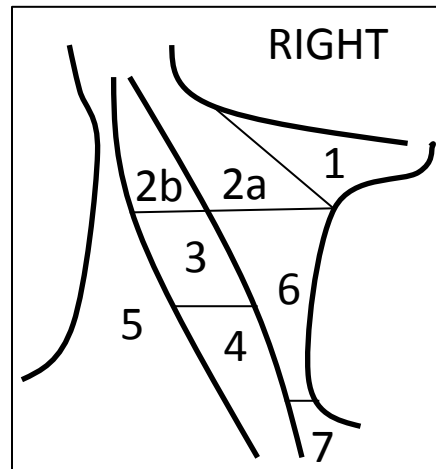

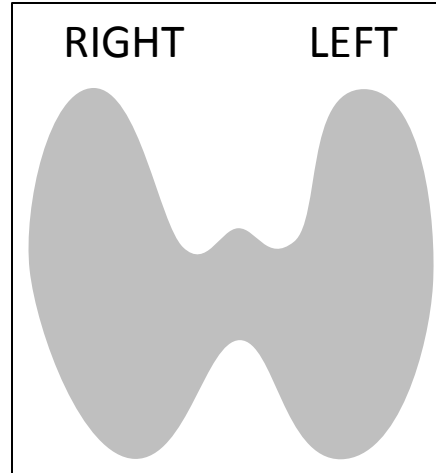
Composition:	Echogenicity:	Margin:	Echogenic Foci:
Mostly Cystic	Anechoic	Smooth	None
Spongiform	Hyperechoic	Ill-defined	Comet-tail
Cystic & Solid	Isoechoic	Lobulated	Ca ²⁺ shadowing
Mostly Solid	Hypoechoic	Irregular	Ca ²⁺ rim/periph
	Very hypoechoic	Extra-thyroid extension	Punctate echogenic foci

Add'l Thyroid Nodules or Lymph Nodes Features

#2: _____ x _____ x _____ mm

#3: _____ x _____ x _____ mm

#4: _____ x _____ x _____ mm



Conclusion:

Dr. _____