

A detailed anatomical illustration in light blue lines on a white background. It shows a multipolar neuron with a central cell body containing a nucleus and various organelles. Several dendrites extend from the cell body. A long axon extends from the cell body, covered by a myelin sheath. The axon terminates in a cross-section of a nerve, showing multiple axons within a common sheath.

KAPLAN[®]
medical

USMLE

Step 1

Lecture Notes

Anatomy

*USMLE is a joint program of the Federation of State Medical Boards of the United States, Inc. and the National Board of Medical Examiners.

Author and Executive Editor

David Seiden, Ph.D.

*Professor of Neuroscience and Cell Biology
Associate Dean for Admissions and Student Affairs
UMDNJ–Robert Wood Johnson Medical School
Piscataway, NJ*

Contributors

James A. Colgan, Ph.D.

*Visiting Lecturer and Course Coordinator
Human Gross Anatomy
Division of Biomedical Sciences
University of California
Riverside, CA*

Ronald Dudek, Ph.D.

*Professor
Department of Anatomy and Cell Biology
Brady School of Medicine
East Carolina University
Greenville, NC*

James White, Ph.D.

*Adjunct Assistant Professor of Neuroscience and Cell Biology
Robert Wood Johnson Medical School
New Brunswick/Piscataway, NJ
Adjunct Associate Professor of Cell Biology
University of Medicine and Dentistry of New Jersey
Newark, NJ
Adjunct Assistant Professor of Cell and Developmental Biology
University of Pennsylvania School of Medicine
Philadelphia, PA*

Jack Wilson, Ph.D.

*Distinguished Alumni Professor of Anatomy and Neurobiology
University of Tennessee Health Center
Memphis, TN*

Executive Director of Curriculum

Richard Friedland, M.D.

Director of Publishing and Media

Michelle Covello

Medical Illustrators

Rich LaRocco
Christine Schaar

Managing Editor

Kathlyn McGreevy

Production Editor

William Ng

Production Artist

Michael Wolff

Cover Design

Joanna Myllo

Cover Art

Christine Schaar
Rich LaRocco

Contents

Preface	vii
---------------	-----

Section I: Histology and Cytology

Chapter 1: Cell Components	3
Chapter 2: Nervous Tissue	25
Chapter 3: Muscle Tissue	33
Chapter 4: Lymphoid Organs	41
Chapter 5: Integument	45
Chapter 6: Respiratory System	49
Chapter 7: Gastrointestinal System	55
Chapter 8: Renal/Urinary System	63
Chapter 9: Male Reproductive System	71
Chapter 10: Female Reproductive System	77

Section II: Early Embryology

Chapter 1: Gonad Development	93
Chapter 2: Week 1: Beginning of Development	99
Chapter 3: Week 2: Formation of the Bilaminar Embryo	101
Chapter 4: Embryonic Period (Weeks 3–8)	103

Section III: Gross Anatomy and Organogenesis

Chapter 1: Back and Nervous System	111
Chapter 2: Thorax	125
Chapter 3: Abdomen, Pelvis, and Perineum	167
Chapter 4: Upper Limb	235
Chapter 5: Lower Limb	253
Chapter 6: Head and Neck	269

Section IV: Neuroscience

Chapter 1: Peripheral Nervous System	313
Chapter 2: Central Nervous System	323
Chapter 3: The Ventricular System	331
Chapter 4: The Spinal Cord	335
Chapter 5: The Brain Stem	363
Chapter 6: The Cerebellum	407
Chapter 7: Visual Pathways	417
Chapter 8: Diencephalon	429
Chapter 9: Basal Ganglia	435
Chapter 10: Cerebral Cortex	443
Chapter 11: The Limbic System	465

SECTION I

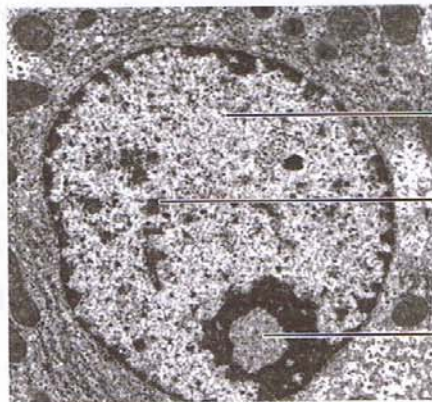
Histology and Cytology

Cell Components

1

NUCLEUS

The nucleus (Figure I-1-1) is the site of deoxyribonucleic acid (DNA) replication and transcription of DNA into precursor ribonucleic acid (RNA) molecules. It contains all of the enzymes required for replication and repair of newly synthesized DNA, as well as for transcription and processing of precursor RNA molecules. It is enclosed by the nuclear envelope and contains the nuclear lamina, nucleolus, and chromatin.



Euchromatin

Heterochromatin

Nucleolus

Figure I-1-1. Nucleus

Nuclear Envelope

The nuclear envelope is a double membrane containing pores that are approximately 90 nm in diameter. The outer nuclear membrane is continuous with the endoplasmic reticulum.

Nuclear Lamina

The nuclear lamina is a latticelike network of proteins that include lamins. Lamins attach chromatin to the inner membrane of the nuclear envelope and participate in the breakdown and reformation of the nuclear envelope during the cell cycle. **Phosphorylation of the lamina (by lamin kinase) during prophase of mitosis initiates nuclear disassembly into small vesicles.**

Nucleolus

The nucleolus is responsible for ribosomal RNA (rRNA) synthesis and ribosome assembly. It contains three morphologically distinct zones:

- **Granular zone**—found at the periphery; contains ribosomal precursor particles in various stages of assembly.
- **Fibrillar zone**—centrally located; contains ribonuclear protein fibrils.
- **Fibrillar center**—contains DNA that is not being transcribed.

Chromatin

Chromatin is a complex of DNA, histone proteins, and nonhistone proteins.

- **DNA**—a double-stranded helical molecule that carries the genetic information of the cell. It exists in three conformations: B DNA, Z DNA, and A DNA.
- **Histone proteins**—positively charged proteins enriched with lysine and arginine residues. They are important in forming two types of structures in chromatin: nucleosomes and solenoid fibers. **The nucleosomes are the basic repeating units of the chromatin fiber, having a diameter of approximately 10 nm.**
- **Nonhistone proteins**—include enzymes involved in nuclear functions such as replication, transcription, DNA repair, and regulation of chromatin function. They are acidic or neutral proteins.

Forms of chromatin

- **Heterochromatin**—highly condensed (30-nm solenoid fibers or higher states of condensation) and transcriptionally inactive. In a typical eukaryotic cell, approximately 10% of the chromatin is heterochromatin. Almost the entire inactive X chromosome (Barr body) in each somatic cell in a woman is condensed into heterochromatin.
- **Euchromatin**—a more extended form of DNA, which is potentially transcriptionally active. In a typical cell, euchromatin accounts for approximately 90% of the total chromatin, although only about 10% is being actively transcribed in the 10-nm fiber of nucleosomes.

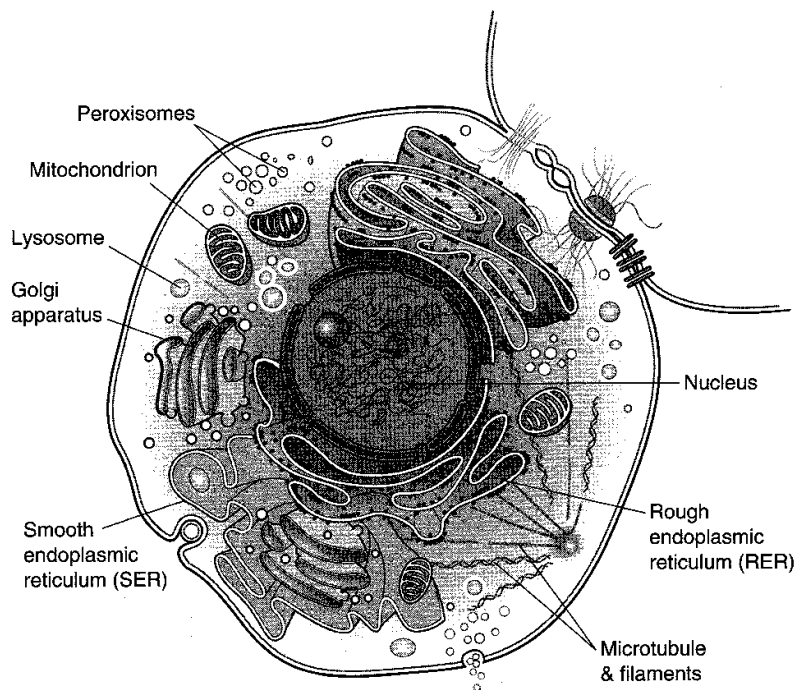


Figure I-1-2

CYTOPLASM

Ribosomes

Ribosomes are composed of rRNA and protein. They consist of large (60S) and small (40S) subunits. Ribosomes are assembled in the nucleus and transported to the cytoplasm through the nuclear pores. The large ribosomal subunits are synthesized in the nucleolus, whereas the small subunits are synthesized in the nucleus.

- **Polysomes**—Ribosomes often form polysomes, which consist of a single messenger RNA (mRNA) that is being translated by several ribosomes at the same time. **The ribosomes move on the mRNA from the 5' end toward the 3' end. The two ribosomal subunits associate on the mRNA, with the small subunit binding first.**

Forms of ribosomes

Ribosomes exist in two forms:

- **Free polysomes** are the site of synthesis for proteins destined for the nucleus, peroxisomes, or mitochondria.
- **Membrane-associated polysomes** are the site of synthesis of secretory proteins, membrane proteins, and lysosomal enzymes.

Endoplasmic Reticulum

The endoplasmic reticulum exists in two forms, **rough endoplasmic reticulum (RER)** and **smooth endoplasmic reticulum (SER)**.

Rough endoplasmic reticulum

RER is a single, lipid bilayer continuous with the outer nuclear membrane. It is organized into stacks of large flattened sacs called cisternae that are studded with ribosomes on the cytoplasmic side (Figure I-1-3).

RER synthesizes proteins that are destined for the **Golgi apparatus**, secretion, the plasma membrane, and lysosomes. RER is very prominent in cells that are specialized in the synthesis of proteins destined for secretion (e.g., pancreatic acinar cells).



Copyright 2000 Gold Standard Multimedia, Inc. All rights reserved.

Figure I-1-3. Rough Endoplasmic Reticulum

Smooth endoplasmic reticulum

SER is a network of membranous sacs, vesicles, and tubules continuous with the RER, but lacking ribosomes (Figure I-1-4).

SER contains enzymes involved in the biosynthesis of phospholipids, triglycerides, and sterols.

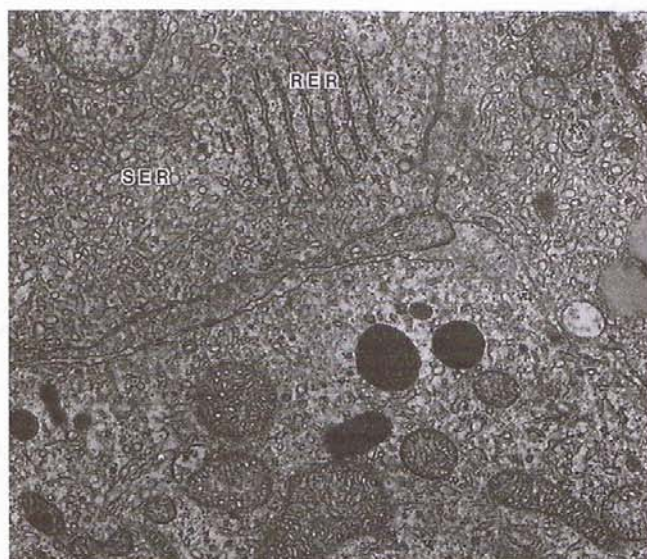


Image copyright 1984 Lippincott Williams & Wilkins. Used with permission.

Figure I-1-4. Human Corpus Luteum of Pregnancy

Functions of SER

Detoxification Reactions

These are reactions that make compounds water soluble so that they can be excreted. Two types of reactions that increase solubility are:

- **Steroid synthesis**
- **Hydroxylation reactions**—by way of hydroxylase complexes containing **cytochrome P450**, a flavoprotein, and a nonheme iron protein
- **Conjugation reactions**—the transfer of polar groups (i.e., glucuronic acid) from the active carrier UDPglucuronic acid to the toxic water-insoluble molecule

Glycogen Degradation and Gluconeogenesis

Removal of the phosphate group from glucose-6-phosphate by the enzyme glucose-6 phosphatase, an integral membrane protein of the SER. This controls the formation of free glucose from glycogen and via gluconeogenesis.

Reactions in Lipid Metabolism

Lipolysis begins in the SER with the release of a fatty acid from triglyceride. The SER is also the site where lipoprotein particles are assembled.

Sequestration and Release of Calcium Ions

In striated muscle the SER is known as the **sarcoplasmic reticulum (SR)**. The sequestration and release of calcium ions takes place in the SR.

Golgi

Do not confuse the Golgi apparatus with the Golgi tendon organs of the cell or any other factor bearing his name. Dr. Camillo Golgi was a prolific Italian histologist. Other structures or processes bearing his name include Golgi's silver stain for nerve cells, the cycle of Golgi for the development of the malaria parasite, the inhibitory Golgi cells of the cerebellum, and the acroblast, a part of the Golgi material of the spermatid known as the Golgi remnant.

Golgi Apparatus

The Golgi apparatus consists of disc-shaped smooth cisternae that are assembled in stacks (dictyosomes), having a diameter of approximately 1 μm and associated with numerous small membrane-bound vesicles (Figure I-1-5).

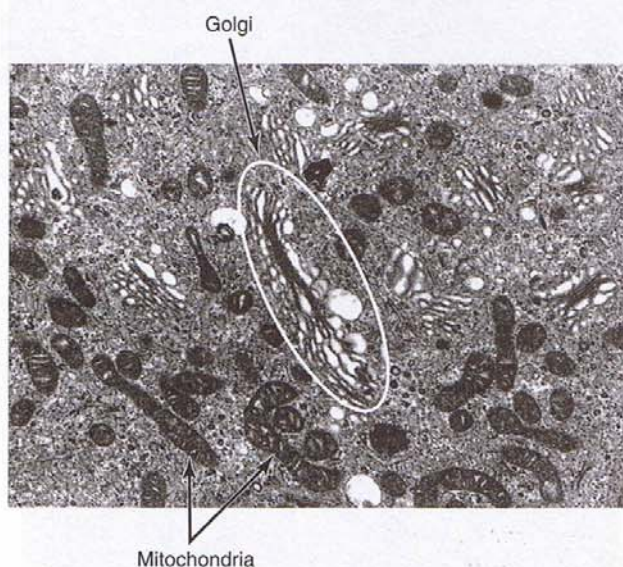


Figure I-1-5. Cytoplasm

The Golgi apparatus has two distinct faces:

- The **cis (forming) face** is associated with the RER.
- The **trans (maturing) face** is often oriented toward the plasma membrane. The trans-most region is a network of tubular structures known as the trans-Golgi network (TGN) (Figure I-1-6).

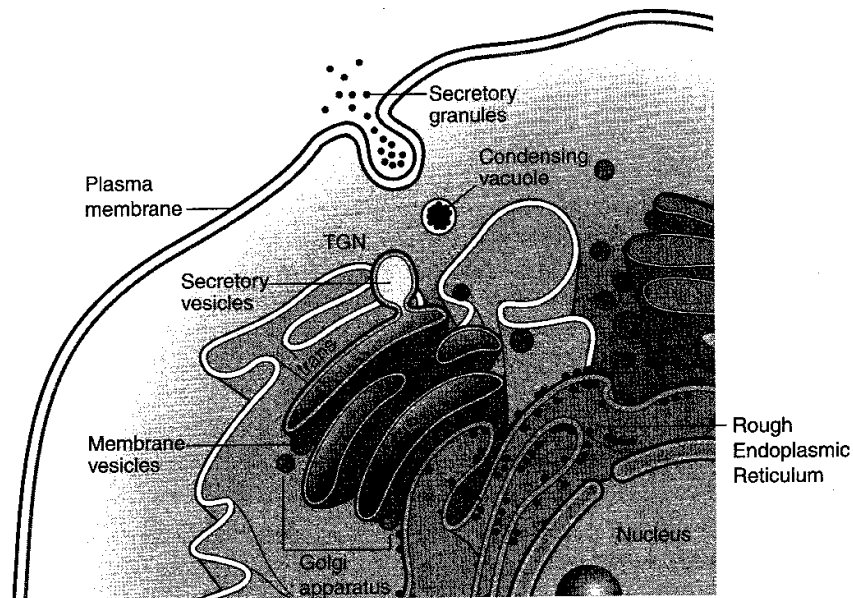


Figure I-1-6. Golgi Apparatus

Functions of the golgi apparatus

Proteins and Lipids

The Golgi apparatus is the site of posttranslational modification and sorting of newly synthesized proteins and lipids.

Glycoproteins

Further modification of the carbohydrate moiety of glycoproteins produces complex and hybrid oligosaccharide chains. This determines which proteins remain in the Golgi apparatus or leave the Golgi apparatus to become secretory proteins, lysosomal proteins, or part of the plasma membrane. Two diseases are caused by a breakdown in this process, I-cell disease and hyperproinsulinemia (see Clinical Correlates).

Clinical Correlate

Hyperproinsulinemia is characterized by elevated levels of proinsulin in the serum resulting from the failure of a peptidase to cleave proinsulin to insulin and C-peptide in the Golgi apparatus. The clinical manifestations are similar to those seen in patients with noninsulin-dependent diabetes.

Clinical Correlate

I-Cell Disease

Phosphorylation of mannose in glycoproteins targets proteins to lysosomes. Phosphate is added in a two-step sequence of reactions that are catalyzed by *N*-acetylglucosamine-phosphotransferase and *N*-acetylglucosaminidases.

A deficiency in *N*-acetylglucosamine-phosphotransferase results in I-cell disease (mucopolipidosis II), in which a whole family of enzymes is sent to the wrong destination. It is characterized by huge inclusion bodies in cells caused by the accumulation of undegraded glycoconjugates in lysosomes missing the hydrolases that normally degrade these macromolecules. The missing enzymes are found in the plasma and other body fluids, where they have normal levels of activity. **The absence of the mannose-6-phosphate on the hydrolases results in their secretion rather than their incorporation into lysosomes.**

The disease results in skeletal abnormalities, coarse features, restricted joint movements, and psychomotor retardation. Symptoms are generally noted at birth, and the life span is less than 10 years.

A somewhat less severe form of the disease with a later onset and potential survival into adulthood is called pseudo-Hurler polydystrophy.

There is no treatment for either disease, but prenatal diagnosis is available.

Lysosomes

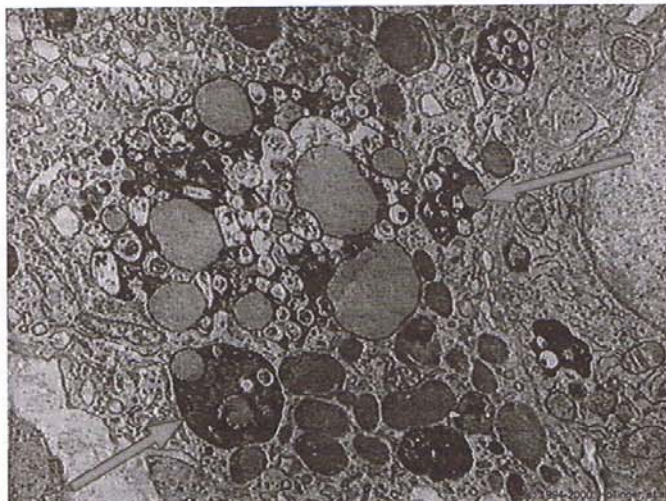
Lysosomes are spherical membrane-enclosed organelles that are approximately 0.5 μm in diameter and contain enzymes required for intracellular digestion (Figure I-1-7).

Lysosomes consist of two forms:

- **Primary lysosomes** have not yet acquired the materials to be digested. They are formed by budding from the trans side of the Golgi apparatus.
- **Secondary lysosomes** are formed by the fusion of the primary lysosome with the substrate to be degraded and have contents that are in various stages of degradation.

Lysosomes contain approximately 60 hydrolytic enzymes. These include nucleases for degrading DNA and RNA, lipases for degrading lipids, glycosidases for degrading glycoconjugates (glycoproteins, proteoglycans, and glycolipids), proteases and peptidases for degrading proteins, and a variety of phosphatases.

- All lysosomal enzymes are acid hydrolases, with optimal activity at a pH of approximately 5.0.
- The synthesis of the lysosomal hydrolases occurs in the RER; the hydrolases are transferred to the Golgi apparatus, where they are modified and packaged into lysosomes.



Copyright 2000 Gold Standard Multimedia, Inc. All rights reserved.

Figure I-1-7. Lysosomes

Peroxisomes

Peroxisomes are a heterogeneous group of small, spherical organelles with a single membrane and a diameter that ranges from approximately 0.15 to 0.5 μm (Figure I-1-8).

Peroxisomes contain a number of enzymes that transfer hydrogen atoms from organic substrates (urate, D-amino acids, and very long chain fatty acids) to molecular oxygen with the formation of hydrogen peroxide. Catalase, the major peroxisomal protein, degrades the hydrogen peroxide to water and oxygen.

Peroxisomal enzymes are synthesized on free polysomes. After translation, the enzymes are incorporated directly into peroxisomes.

Peroxisomes have several functions:

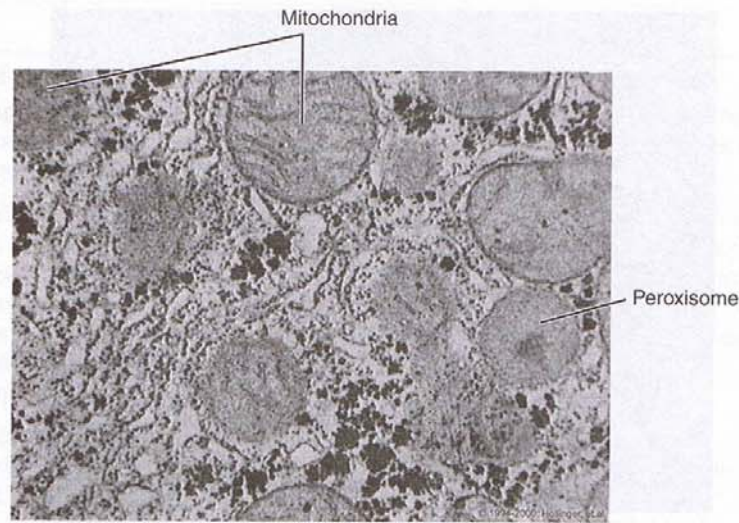
- Synthesis and degradation of hydrogen peroxide
- β -Oxidation of very long chain fatty acids (>C24) starts in the peroxisome and proceeds until the carbon chain has been reduced to a length of approximately 10 carbons. Oxidation of the residual 10 carbons is completed in the mitochondria.
- Phospholipid exchange—peroxisomes contain enzymes that convert phosphatidylserine and phosphatidylethanolamine.
- Bile acid synthesis

Clinical Correlate

Peroxisome Deficiency

Several genetic diseases are associated with the impairment or absence of peroxisomes. These patients fail to oxidize very long chain fatty acids and accumulate bile acid precursors. The four most common disorders are:

- Zellweger (cerebrohepato renal) syndrome
- Neonatal adrenoleukodystrophy
- Infantile Refsum disease
- Hyperpipecolatemia



Copyright 2000 Gold Standard Multimedia, Inc. All rights reserved.

Figure I-1-8. The Peroxisome

Mitochondria

Mitochondria have two membranes. They are about $0.5\ \mu\text{m}$ in width and vary in length from 1 to $10\ \mu\text{m}$ (Figure I-1-9). They synthesize adenosine triphosphate (ATP), contain their own double-stranded circular DNA, and make some of their own proteins. Mitochondria have several compartments.

Outer membrane

The outer membrane is smooth, continuous, and highly permeable. It contains an abundance of porin, an integral membrane protein that forms channels in the outer membrane through which molecules of less than 10 kD can pass.

Inner membrane

The inner membrane is impermeable to most small ions (Na^+ , K^+ , H^+) and small molecules (ATP, adenosine diphosphate, pyruvate). The impermeability is likely related to the high content of the lipid cardiolipin.

- The inner membrane has numerous infoldings, called **cristae**. The cristae greatly increase the total surface area. They **contain the enzymes for electron transport and oxidative phosphorylation**.
- The number of mitochondria and the number of cristae per mitochondrion are proportional to the metabolic activity of the cells in which they reside.

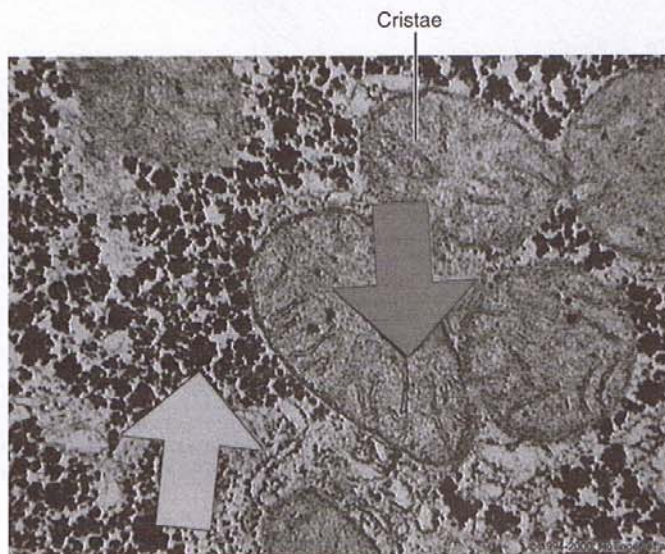
Intermembrane compartment

The intermembrane compartment is the space between the inner and outer membranes. It contains enzymes that use ATP to phosphorylate other nucleotides (creatine phosphokinase and adenylate kinase).

Matrix

The matrix is enclosed by the inner membrane and contains:

- **Dehydrogenases**—oxidize many of the substrates in the cell (pyruvate, amino acids, fatty acids), generating reduced nicotinamide adenine dinucleotide (NADH) and reduced flavin adenine dinucleotide (FADH₂) for use by the electron transport chain and energy generation.
- A **double-stranded circular DNA genome**—encodes a few of the mitochondrial proteins. Mitochondrial DNA is always inherited from the mother, resulting in the **maternal transmission** of diseases of energy metabolism.
- **RNA, proteins, and ribosomes**—although there is some protein synthesis, **most mitochondrial proteins are synthesized in the cytoplasm and are transferred into the mitochondria.**
- **Intramitochondrial granules**—contain calcium and magnesium. Their function is not known, but it is believed that they may represent a storage site for calcium.



Copyright 2000 Gold Standard Multimedia, Inc. All rights reserved.

Figure I-1-9. Mitochondria

Cytoskeleton

The cytoskeleton provides a supportive network of tubules and filaments in the cytoplasm of eukaryotic cells. It is composed of microtubules, intermediate filaments, and microfilaments.

Microtubules

Microtubules are polymers of tubulin that undergo rapid assembly and disassembly. They are found in the cytoplasmic matrix of all eukaryotic cells.

Clinical Correlate

Chédiak-Higashi syndrome is characterized by a defect in microtubule polymerization. This leads to defects in cytoplasmic granules including:

- Delayed fusion of phagosomes with lysosomes in leukocytes, thus preventing phagocytosis of bacteria.
- Increased fusion of melanosomes in melanocytes, leading to albinism.
- Granular defects in natural killer cells and platelets.

Clinical Correlate

Actin-binding drugs (e.g., cytochalasin B) can interfere with the polymerization-depolymerization cycle of microfilaments. Processes such as endocytosis, phagocytosis, cytokinesis, and cytoplasmic and amoeboid movements are all inhibited by cytochalasin B.

Tubulin

The major component of microtubules is tubulin, a protein dimer composed of two different polypeptides, α -tubulin and β -tubulin.

Polymerization of tubulin to form microtubules is accomplished by microtubule organizing centers and two types of accessory proteins, tau proteins and microtubule-associated proteins. Microtubules grow from the organizing centers. Calcium ions can block or reverse polymerization.

Microtubules play a role in:

- Chromosomal movement during meiosis and mitosis. **Microtubule assembly is an important event in spindle formation.**
- Intracellular vesicle and organelle transport. Two specific microtubule-dependent ATPases, **kinesin and dynein**, are involved in generating the force that drives transport, with the microtubular structure playing a more passive role in intracellular transport.
- Ciliary and flagellar movement.

Intermediate filaments

Intermediate filaments are intermediate in thickness (10-nm diameter) between microtubules and microfilaments. They function primarily in structural roles and contain several types of tissue-specific proteins:

- **Cytokeratins**—found in epithelial tissue
- **Desmin**—found in smooth muscle; Z disks of skeletal and cardiac muscle
- **Vimentin**—found in cells of mesenchymal origin (endothelial cells, fibroblasts, chondroblasts, vascular smooth muscle)
- **Neurofilaments**—found in neurons
- **Glial fibrillary acidic protein (GFA)**—found in astrocytes

Microfilaments

Microfilaments have a diameter of 6 nm and are composed of **actin**. Each actin filament (F-actin) consists of two strands of actin twisted into a helical pattern with 13.5 molecules of globular actin (G-actin) per turn of the helix.

Two types of movement are associated with microfilaments:

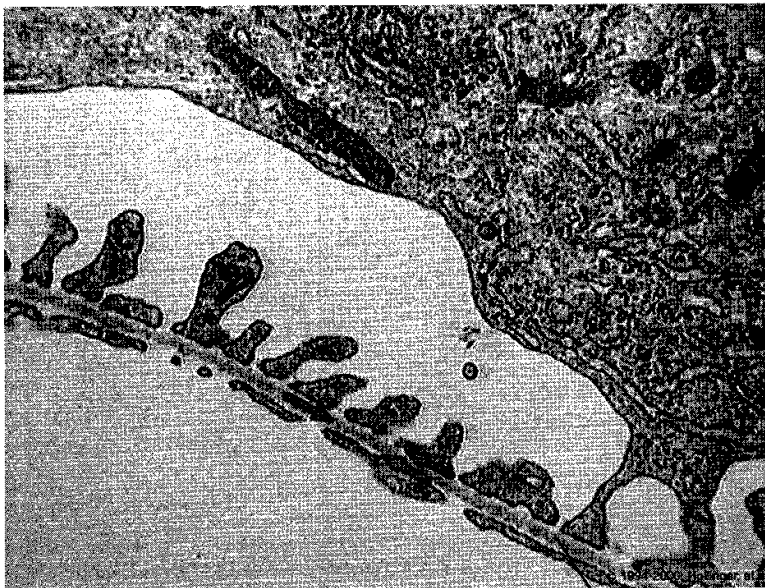
- Local movement takes advantage of the polymerization and depolymerization properties of microfilaments.
- Sliding filament movement is generated by the interaction of actin filaments with myosin filaments.

CELL SURFACE

Basement Membrane

The basement membrane is a sheetlike structure that underlies virtually all epithelia. It consists of the following:

- **Basal lamina**—composed of type IV collagen, glycoproteins (e.g., laminin), and proteoglycans (e.g., heparan sulfate) (Figure I-1-10).
- **Reticular lamina**—composed of delicate reticular fibers.



Basal Lamina

Figure I-1-10. Basal Lamina

Lateral Surface Specializations

The lateral surface specializations are illustrated in Figure I-1-11.

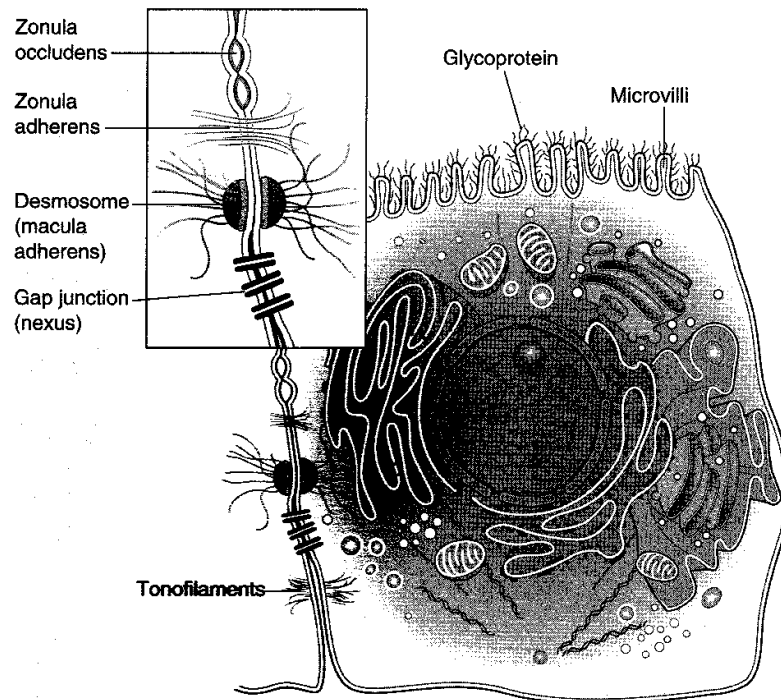


Figure I-1-11. Surface Specializations Found on Simple Columnar Epithelial Cells

Tight junction (zonula occludens)

The tight junction is formed by the fusion of opposed cell membranes (Figure I-1-11). These ridges of fusion present as "sealing strands" seen in freeze-fracture replicas (Figure I-1-12). It extends completely around the apical cell borders to seal the underlying intercellular clefts from contact with the outside environment. It constitutes the anatomic component of many barriers in the body.

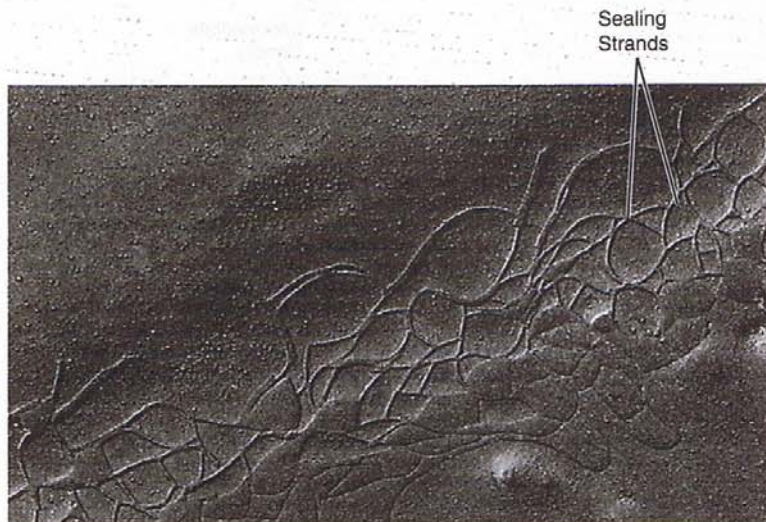

Image copyright 1984 Lippincott Williams & Wilkins. Used with permission.

Figure I-1-12. Freeze-Fracture Replica of a Tight Junction

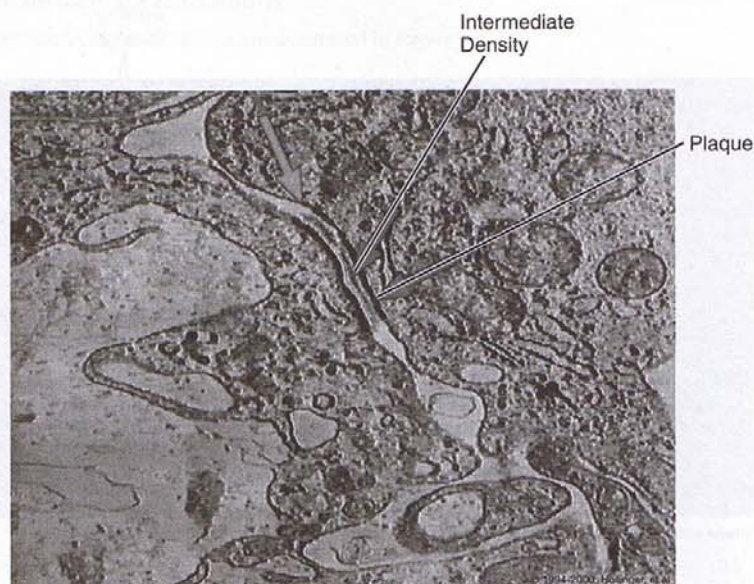
Zonula adherens

A zonula adherens (adherent junction) often lies basal to the zonula occludens (Figure I-1-11). It is a bandlike junction that serves in the attachment of adjacent epithelial cells.

Desmosome

The desmosome (macula adherens) is formed by the juxtaposition of two disk-shaped plaques contained within the cytoplasm of each adjacent cell (Figure I-1-13).

- **Intermediate filaments** (tonofilaments) radiate away from the plaques (not seen in Figure I-1-12). These intermediate filaments are anchored by desmoplakins (plaques) that also bind to transmembrane linker proteins, linking adjacent cells.
- **Desmosomes** are most common in lining membranes, are subject to wear and tear, and are considered spot welds that hold cells together.



Copyright 2000 Gold Standard Multimedia, Inc. All rights reserved.

Figure I-1-13. Desmosome

Gap junction

The gap junction is an area of communication between adjacent cells that allows the passage of very small particles and ions across a small intercellular gap within the junction (Figure I-1-14).

The gap junction consists of a hexagonal lattice of tubular protein subunits called **connexons**, which form hydrophilic channels connecting the cytoplasm of adjacent cells (Figure I-1-15). **This permits the direct passage of ions and small molecules between cells to conduct electrical impulses.**

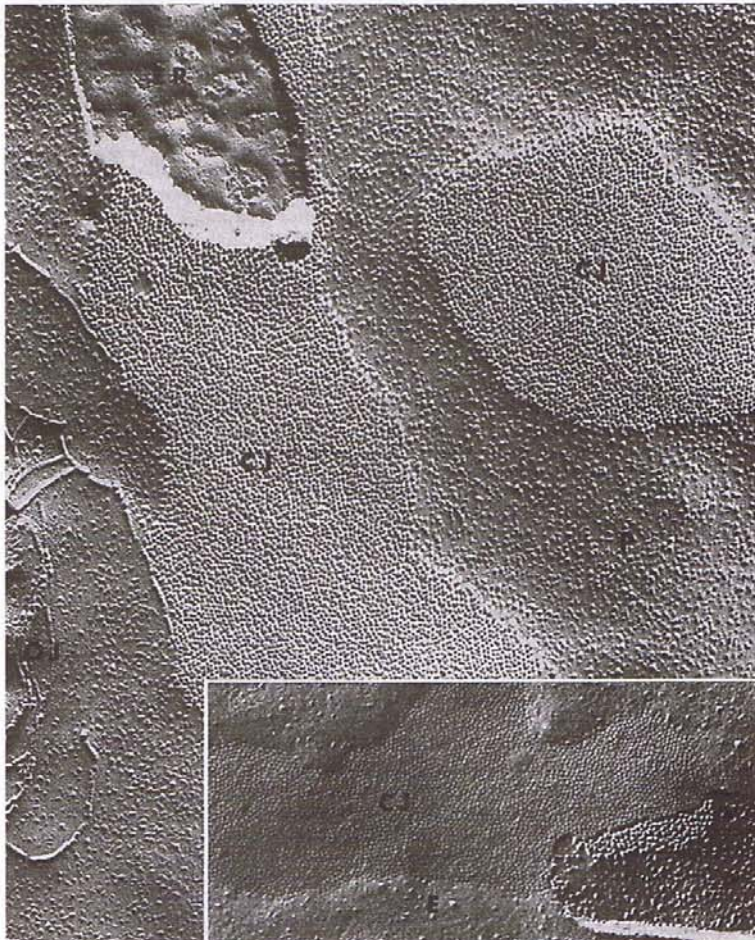


Image copyright 1984 Lippincott Williams & Wilkins. Used with permission.

Figure I-1-14. Freeze-Fracture Replica of a Gap (Communicating) Junction (CJ)

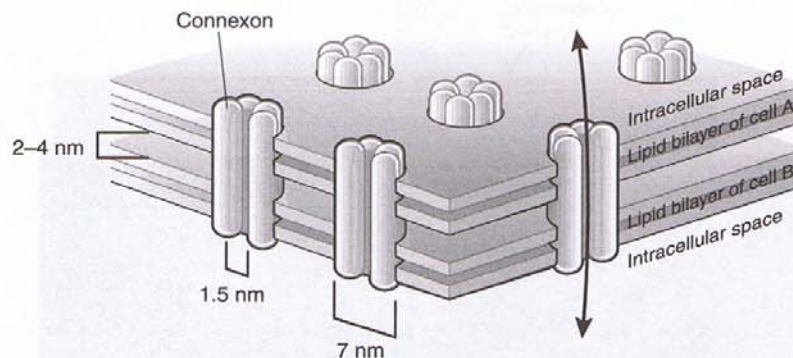


Figure I-1-15. Gap Junction

Note

Stereocilia are elongated microvilli found at the apices of cells lining the epididymis, ductus deferens, and hair cells of the inner ear, where they play a role in auditory sensation.

Note

Flagella are longer than cilia but have the same microstructure; a prominent example is in the sperm, where the single flagellum provides motility.

Apical (Free) Surface Specializations

Microvilli

Microvilli are apical cell surface evaginations of cell membranes that function to increase the cell surface area available for absorption (Figure I-1-16). A thick glycocalyx coat covers them. The core of each microvillus contains actin microfilaments. It is anchored in the apical cell cytoplasm to the terminal web, which itself is anchored to the zonula adherens of the cell membrane.

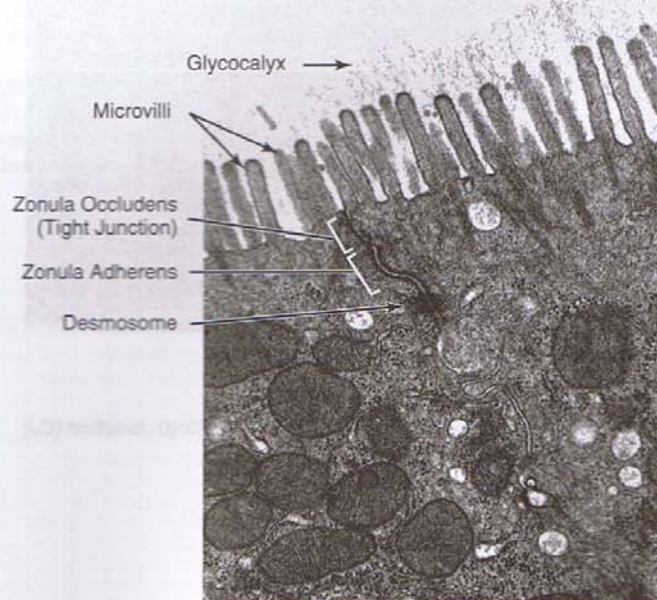


Figure I-1-16. Apical Cell Surface/Cell Junctions

Cilia

Cilia are apical cell surface projections of cell membrane that contain microtubules (Figures I-1-17 and I-1-18). They are inserted on centriole-like basal bodies present below the membrane surface at the apical pole.

Cilia contain two central microtubules surrounded by a circle of nine peripheral microtubule doublets. The peripheral doublets are fused so that they share a common tubule wall and form two subtubules, A and B. Adjacent doublets are connected to one another by nexin links (Figure I-1-18).

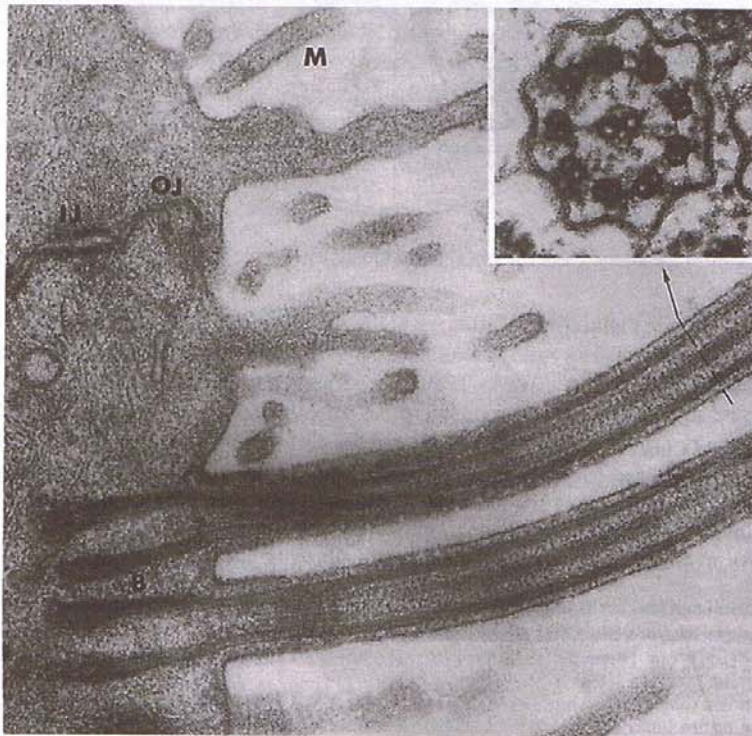


Image copyright 1984 Lippincott Williams & Wilkins. Used with permission.

B = Basal Body
IJ = Intermediate Junction
M = Microvilli
OJ = Occluding Junction

Figure I-1-17. Cilia

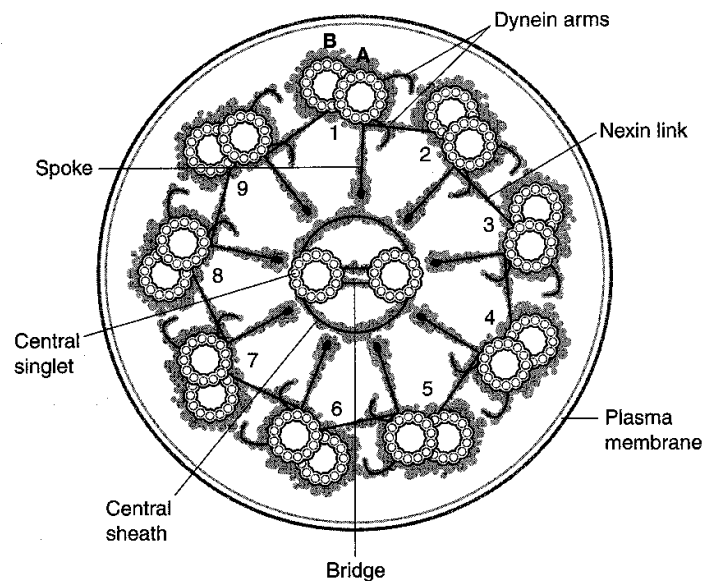


Figure I-1-18. Structure of the Axoneme of a Cilium

Movement of Cilia

A pair of **dynein** arms is attached to each A subunit. The arms bind to ATP and rearrange themselves so that a binding site for the B subunit in the tip of the arm is exposed. The B subunit interacts with the binding site, causing the arm to snap back and movement to occur. Each cycle of a single dynein arm slides adjacent doublets 10 nm past each other.

Cilia move back and forth to propel fluid and particles in one direction. They are important in clearing mucus from the respiratory tract.

Clinical Correlate

Kartagener Syndrome

Absent or aberrant dynein arms are found in the cilia and flagella of individuals suffering from Kartagener syndrome (a subset of immotile cilia syndrome). Such individuals often have chronic sinusitis and bronchiectasis, as well as infertility and, in some cases, situs inversus.

Chapter Summary

Cell components include the nucleus, cytoplasm, cytoskeleton, and cell surface.

The Nucleus

The **nucleus** consists of a nuclear envelope, lamina, nucleolus and chromatin.

Phosphorylation of the **lamina** during prophase of mitosis initiates nuclear disassembly into small vesicles.

The **nucleolus** assembles ribosomes and synthesizes ribosomal RNA. The nucleolus has a fibrillar center that contains nontranscribed DNA.

Chromatin is a complex of DNA, histone, and nonhistone proteins. DNA exists in three forms: B DNA, Z DNA, and A DNA. Histone proteins are positively charged and complex with DNA to form nucleosomes and solenoid fibers. Nonhistone proteins are neutral and perform diverse functions such as DNA repair, replication, transcription, and regulation of chromatin function. There are two forms of chromatin: euchromatin, which is transcriptionally active, and heterochromatin, which is transcriptionally inactive. Ten percent of chromatin is in the form of heterochromatin. The Barr body (inactive X chromosome) is heterochromatin.

The Cytoplasm

The **cytoplasm** contains ribosomes, endoplasmic reticulum, Golgi apparatus, lysosomes, peroxisomes, mitochondria, and matrix.

Ribosomes are composed of rRNA and protein. Large ribosomal units are synthesized in the nucleolus, whereas small ones are synthesized in the nucleus. Polysomes are formed from ribosomes associating with a single mRNA strand. There are two kinds of polysomes: free and membrane-bound. The former synthesize proteins destined for the nucleus, peroxisomes, or mitochondria. The latter form secretory proteins, lysosomal enzymes, and membrane proteins.

Endoplasmic reticulum exists in two forms: smooth and rough. **Smooth endoplasmic reticulum** (SER) lacks ribosomes. It is involved in detoxification reactions—hydroxylation, via cytochrome P450, and conjugation. It forms glucose from glycogen via membrane-bound enzyme glucose-6 phosphatase and lipolysis by releasing fatty acid from triglyceride. Other products made here include phospholipids, lipoproteins, and sterols. SER in striated muscle is known as sarcoplasmic reticulum. Calcium ions are sequestered and released here. **Rough endoplasmic reticulum** (RER) contains ribosomes that synthesize proteins that are delivered to Golgi apparatus, lysosomes, and plasma membrane.

Lysosomes are classified as primary or secondary. The latter are formed by fusion of the former with either phagosomes or cellular organelles. Lysosomes contain approximately 60 hydrolytic enzymes, all of which are acidic. They degrade DNA, RNA, lipids, glycoproteins, proteins, and phosphatases.

Peroxisomes are organelles that synthesize and degrade hydrogen peroxide, initiate β oxidation of very long-chain fatty acids, synthesize bile and exchange of phospholipid.

Mitochondria are organelles bounded by two membranes—an outer and inner membrane. The inner membrane contains enzymes for electron transport and oxidative phosphorylation.

(Continued)

Chapter Summary (continued)

Mitochondrial matrix contains dehydrogenases and mitochondrial DNA, which is always inherited from the mother. Thus, transmission of diseases of energy metabolism is from the mother.

Intramitochondrial granules contain calcium and magnesium and are probably stored here. The **cytoskeleton** is a supportive network that contains microtubules, intermediate filaments, and microfilaments. Assembly of microtubules is important for spindle formation. Intermittent filaments contain tissue-specific proteins. Microfilaments are composed of actin.

Cell Surface

Important cell surface modifications include the basal and reticular lamina, tight junctions, desmosomes, gap junctions, microvilli, and cilia.

Nervous Tissue

2

NEURONS

Neurons are composed of three basic parts: the cell body (soma or perikaryon); the dendrites, which receive information from other neurons; and a single axon, which conducts electrical impulses away from the cell body (Figure I-2-1).

Cell Body

The cell body contains a large vesicular nucleus with a single prominent nucleolus, mitochondria, and other organelles. It has abundant RER, reflecting high rates of protein synthesis. At the light microscopic level, the RER stains intensely with basic dyes and is referred to as Nissl substance.

Microtubules and neurofilaments contribute to the neuronal cytoskeleton and play important roles in axonal transport. Pigment granules such as lipofuscin ("wear and tear" pigment) and melanin (found in some catecholamine-containing neurons) may be seen in the cytoplasm.

Dendrites

Dendrites are neuronal processes that receive information and transmit it to the cell body. Extensive dendritic branching serves to increase the receptive area of the neuron.

Axons

Axons are thin, cylindrical processes typically arising from the perikaryon (or from a proximal dendrite) through a short pyramidal-shaped region called the axon hillock. The cell membrane of the axon is called the axolemma, and the cytoplasm of the axon is called the axoplasm.

Axonal transport

Axons contain abundant microtubules and neurofilaments. Axon fast transport uses microtubules. It proceeds in both anterograde and retrograde directions. Anterograde transport is powered by **kinesins**, whereas retrograde transport is powered by **dynein**.

Synaptic boutons

Axons terminate in specialized endings known as synaptic boutons, which contain synaptic vesicles full of neurotransmitter.

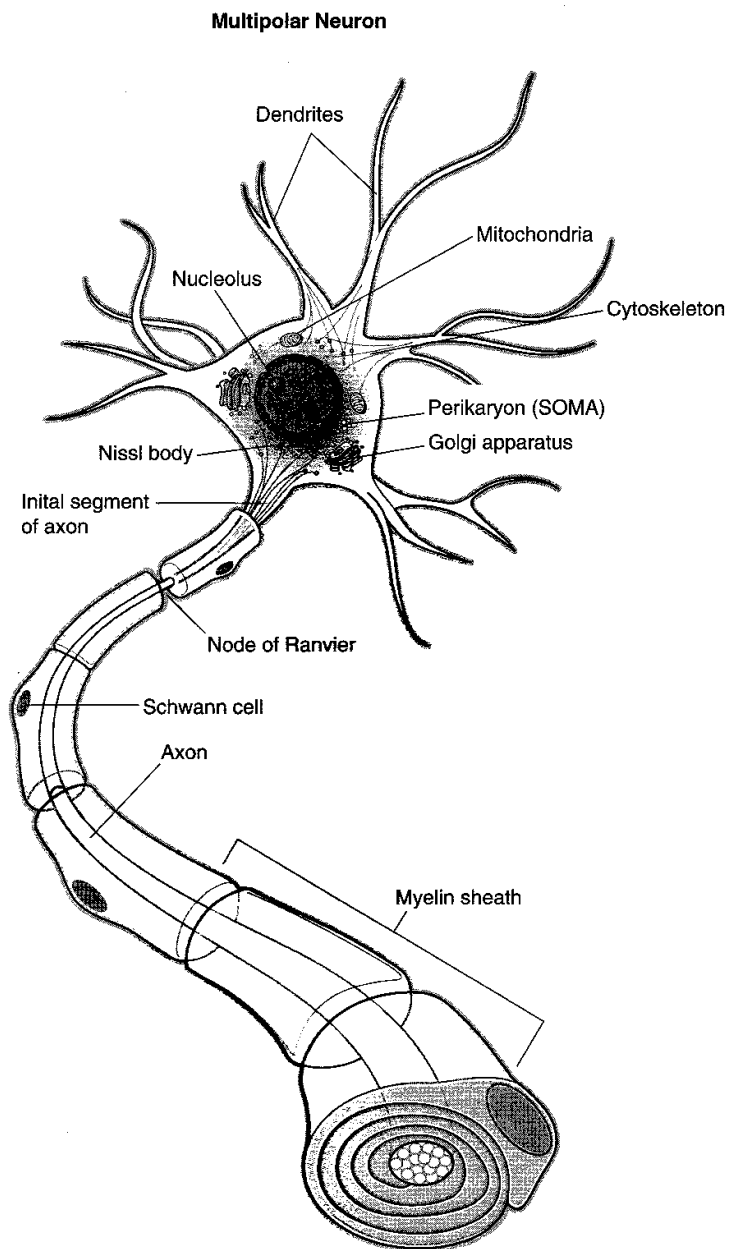


Figure I-2-1. Neuron Structure

Myelin

Axons may be unmyelinated or myelinated, depending on the type of covering provided by their supporting cells.

Unmyelinated Axons

Unmyelinated axons in peripheral nerves are surrounded by the cytoplasm of Schwann cells.

- These axons have a small diameter and a relatively slow conduction velocity.
- A single Schwann cell may ensheath several axons.

Myelinated Axons

Myelinated axons are larger in diameter and are ensheathed in myelin (Figure I-2-2).

Schwann cells are the myelin-forming cells of the peripheral nervous system (PNS). Myelination in the PNS begins during the fourth month of development. One Schwann cell will myelinate only one axon in peripheral nerves.

Oligodendrocytes are the myelin-forming cells of the central nervous system (CNS). In the CNS, myelination begins during the fourth month of development and continues into the second decade of life. **An individual oligodendrocyte is able to myelinate many axons.**

Node of Ranvier

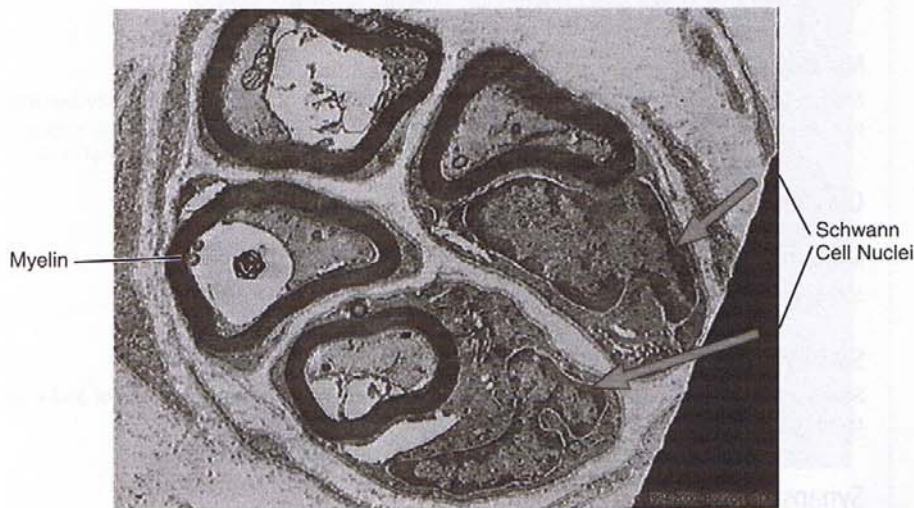At the junction between two myelin-producing cells, there is a discontinuity in the myelin. This creates a "collar" of naked axon, called a node of Ranvier, which is exposed to the extracellular space (Figure I-2-1). **The action potential skips from node to node in a process called saltatory conduction.** Myelinated axons conduct action potentials rapidly.

Composition

Because myelin is of membrane origin, it is rich in phospholipids and cholesterol.

Clinical Correlate

The degeneration of oligodendrocytes results in many of the so-called demyelinating disorders, such as multiple sclerosis.



Copyright 2000 Gold Standard Multimedia, Inc. All rights reserved.

Figure I-2-2. Axons Cut in Cross-Section

Classification of Neurons by Neuronal Processes

Unipolar neurons

Unipolar neurons have one axon and no dendrites and probably occur only during development.

Pseudounipolar neurons

Pseudounipolar neurons (Figure I-2-3) have a single process close to the perikaryon, which divides into two branches. One branch extends to a peripheral ending, and the other extends to the CNS. Pseudounipolar neurons are found in dorsal root ganglia and most cranial ganglia.

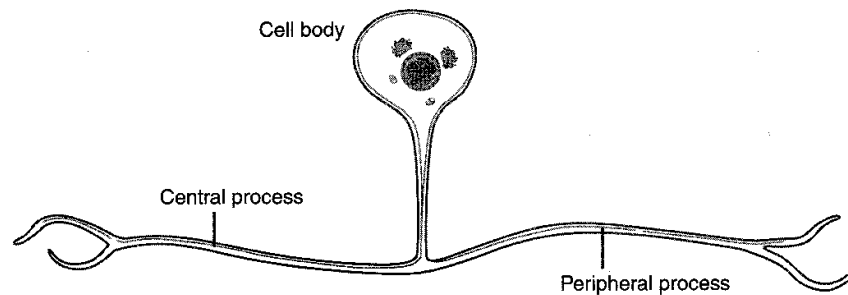


Figure I-2-3. Pseudounipolar Neurons

Bipolar neurons

Bipolar neurons have one axon and one dendrite. Bipolar neurons are found in the cochlear and vestibular ganglia as well as in the retina and olfactory mucosa.

Multipolar neurons

Multipolar neurons have one axon and multiple dendrites. Most neurons in the body are multipolar (e.g., ventral horn neurons in the spinal cord).

Classification of Neurons by Functional Role

Motor neurons

Motor neurons control effector organs and muscle fibers.

Sensory neurons

Sensory neurons receive sensory stimuli from the internal or external environment and relay them to the CNS.

Synapses

Synapses are specialized membrane junctions designed for the unidirectional communication between neurons or between neurons and effector cells (Figure I-2-4). The pre- and postsynaptic membranes are separated by only 20 nm; this space is called the synaptic cleft.

Location

Synapses are either between an axon and a dendrite (axodendritic; Figure I-2-5) or between an axon and a cell body (axosomatic). Synapses between dendrites (dendrodendritic) and between axons (axoaxonic) also occur.

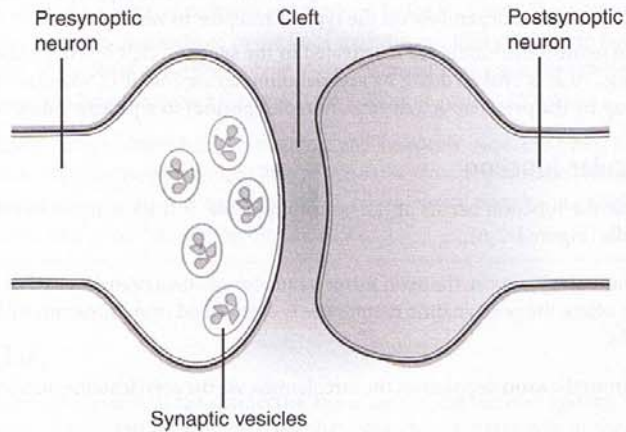
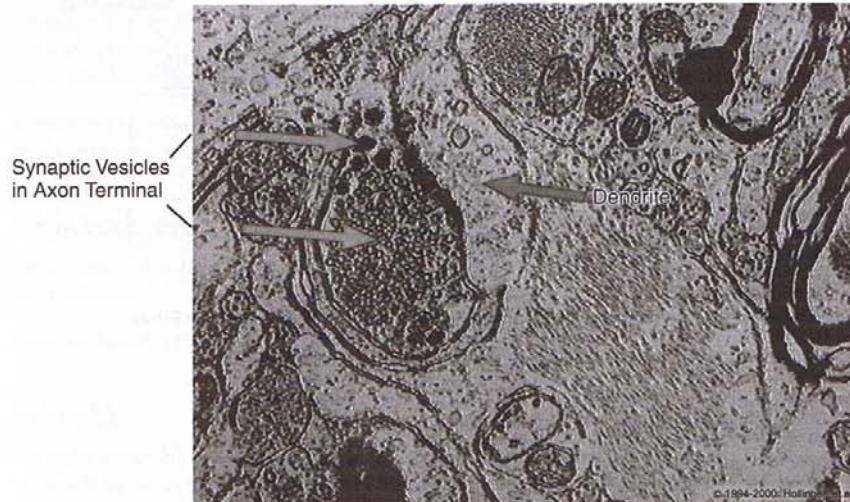


Figure I-2-4. Synapse



Copyright 2000 Gold Standard Multimedia, Inc. All rights reserved.

Figure I-2-5. Axodendritic Synapse

Synaptic vesicles

Synapses contain synaptic vesicles. They consist of 30- to 50- μ m spherical or ovoid structures in the axoplasm that contain neurotransmitter (e.g., acetylcholine [ACh]). Neurotransmitter is released into the synaptic cleft at the synapse when synaptic vesicles fuse with the presynaptic membrane.

- Neurotransmitters may either excite (depolarize) or inhibit (hyperpolarize) the postsynaptic membrane, depending on the type of receptor to which it binds.
- Certain neurotransmitters are inactivated in the synaptic cleft by enzymatic degradation (e.g., ACh is broken down by acetylcholinesterase [AChE]), whereas others are taken up by the presynaptic cell (e.g., norepinephrine) in a process called reuptake.

Neuromuscular Junction

The neuromuscular junction occurs at the motor end plate. It is the synapse between neurons and muscle cells (Figure I-2-6).

At the neuromuscular junction, the axon forms a number of small branches that fit into grooves on the muscle where the postsynaptic membrane is convoluted into numerous folds, called the subneural clefts.

ACh released from the axon depolarizes the sarcolemma via the acetylcholine nicotinic receptors.

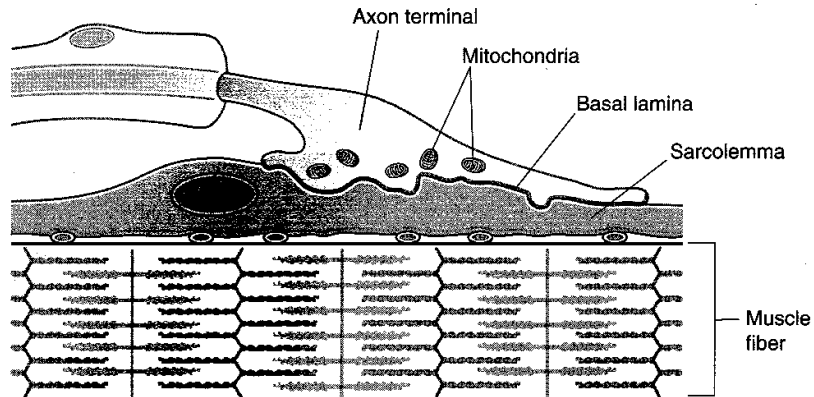


Figure I-2-6. Portion of a Motor End Plate Along a Skeletal Muscle Fiber

Clinical Correlate

Myasthenia gravis is a disease characterized by weakness and easy fatigue of muscles. It can be life threatening if swallowing or breathing is affected.

It is caused by an autoimmune response to the ACh receptor. Normally, old receptors are constantly removed by endocytosis and transported to and degraded by the lysosomes. These are replaced by new receptors, which are manufactured by the Golgi apparatus and then inserted into the junctional folds. The normal half-life of a receptor is about 10 days. In myasthenia gravis, the half-life is reduced to about 2 days, resulting in a marked decrease in the number of available receptors.

Administration of AChE inhibitors has both diagnostic and therapeutic value. By slowing the rate of ACh degradation, they increase the binding time of ACh to the remaining receptors. The usual response is prompt improvement in muscle power. An original clinical diagnosis of myasthenia gravis becomes questionable should no improvement be observed.

NEUROGLIA

Neuroglia (nerve glue) serve as the connective tissue cells of the nervous system. Although they do not generate or transmit neural impulses, they play an important role in the normal functioning of the nervous system. They form the myelin sheaths of axons and provide metabolic support to neurons. Neuroglia of the CNS include microglia, astrocytes, oligodendrocytes, and ependymal cells. In the PNS, neuroglia cells consist of Schwann cells.

Astrocytes

Astrocytes are the largest of the neuroglial cells. They have centrally located nuclei and numerous long processes with expanded vascular end-feet, or pedicels, which attach to the walls of blood capillaries.

Astrocytes are important in controlling the microenvironment of nerve cells and participate in the maintenance of the blood–brain barrier.

Oligodendrocytes

Oligodendrocytes have small nuclei and contain abundant mitochondria, ribosomes, and microtubules.

Oligodendrocytes myelinate axons in the CNS.

Microglia

Microglia are small, dense, elongated cells with elongated nuclei. They originate from the mesoderm, unlike other neuroglial cells, which originate from the neuroectoderm.

Microglia are phagocytic and are part of the **mononuclear phagocyte system**.

Ependymal Cells

Ependymal cells line the ventricular cavities of the brain and the central canal of the spinal cord. They are capable of mitosis and can develop long processes that deeply penetrate the neural tissue.

Cilia on the ependymal cells help move cerebrospinal fluid through the ventricles.

Schwann Cells

Schwann cells contain elongated nuclei that lie parallel to the axons of peripheral neurons.

Schwann cells myelinate peripheral axons.

Chapter Summary

Neurons are composed of a cell body, dendrites, and an axon. They contain pigments such as melanin and lipofuscin. The **cell body** (soma or perikaryon) contains a nucleus, other cellular components, and rough endoplasmic reticulum. Microtubules and neurofilaments form the cytoskeleton. They are important for axonal transport. **Dendrites** receive and transmit information to the cell body. **Axons** arise from the perikaryon or proximal dendrite. They contain microtubules and neurofilaments. Rapid axonal transport utilizes microtubules. Kinesins promote anterograde transport, whereas dynein promotes retrograde transport. **Myelin** is the covering of axons and is composed of phospholipids and cholesterol. Axons may be myelinated or nonmyelinated. Schwann cells myelinate a single peripheral nervous system axon.

They may also associate with several axons (unmyelinated) without forming myelin. Oligodendrocytes form myelin in the central nervous system. One oligodendrocyte myelinates many axons. The **node of Ranvier** is a collar of naked axon between a proximal and distal bundle of myelin that has myelinated the axon. Its purpose is to allow rapid signal transport by skipping from one node to the next, thus avoiding travel through the entire axon. This process is called saltatory conduction.

Muscle Tissue

3

GENERAL FEATURES

Muscle is classified as skeletal, cardiac, or smooth. Some general features of all three types of muscle are summarized in Table I-3-1.

Table I-3-1. General Cytologic Features of the Three Types of Muscle

Skeletal	Cardiac	Smooth
Striated, unbranched fibers	Striated, branched fibers	Nonstriated, fusiform fibers
Multinuclear	Single nucleus	Single nucleus
Strong, quick, discontinuous, voluntary contraction	Strong, quick, continuous, involuntary contraction	Weak, slow, involuntary contraction

SKELETAL MUSCLE

General Features

A gross view of skeletal muscle and the connective tissue (CT) investments are demonstrated in Figure I-3-1. Note the three levels of connective tissue:

- **Endomysium**—CT that surrounds individual muscle fibers
- **Perimysium**—CT that surrounds groups (fascicles) of muscle fibers
- **Epimysium**—CT that surrounds the entire muscle

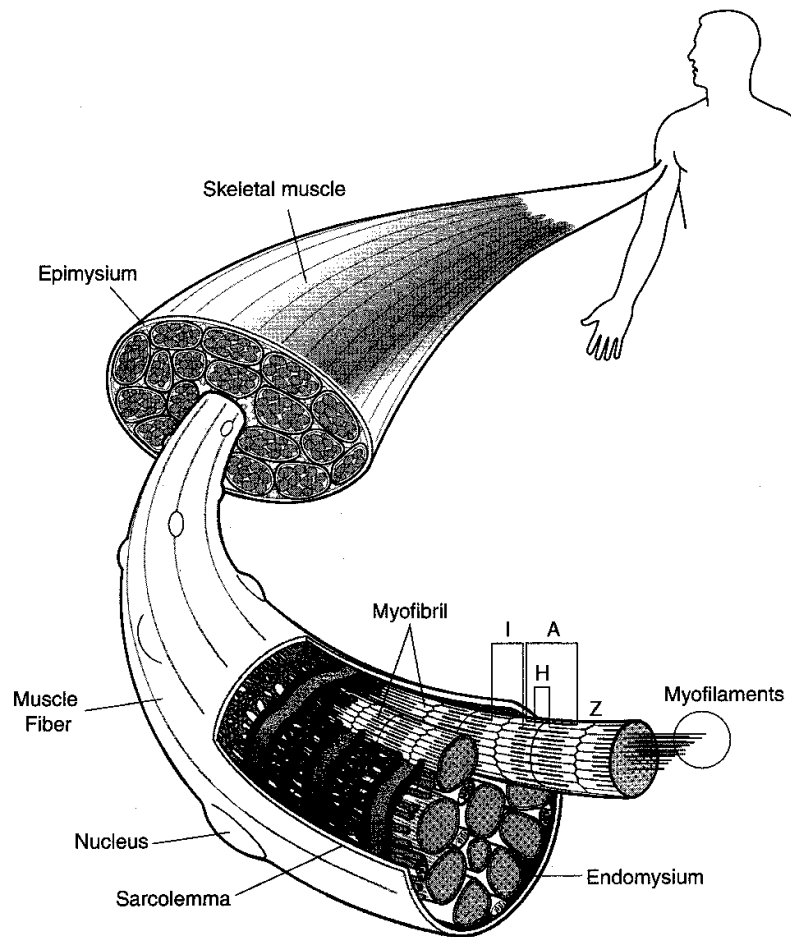


Figure I-3-1. Connective Tissue Investments of a Striated Skeletal Muscle

Fibers

Skeletal muscle fibers consist of long cylindrical fibers with multiple ovoid nuclei located peripherally beneath the sarcolemma (plasma membrane) and with striations composed of alternating dark and light bands.

- The dark bands are called A bands because they are anisotropic (birefringent) in polarized light. In the center of the A band a paler region, the H band, is seen in relaxed muscle.
- The light bands are called I bands (isotropic), and a dark transverse line, the Z line, bisects each I band.

These bands and the Z lines are well demonstrated in electron micrographs of skeletal muscle (Figure I-3-2).

Myofibrils

Skeletal muscle fibers contain 1- to 2-mm myofibrils that lie in the sarcoplasm (cytoplasm) parallel to the long axis of the muscle fiber (Figure I-3-2). Myofibrils are composed of a series of sarcomeres that consist of interdigitating polarized thin filaments and bipolar thick filaments (Figure I-3-3). The sarcomeres are the basic units of contraction of striated muscle.

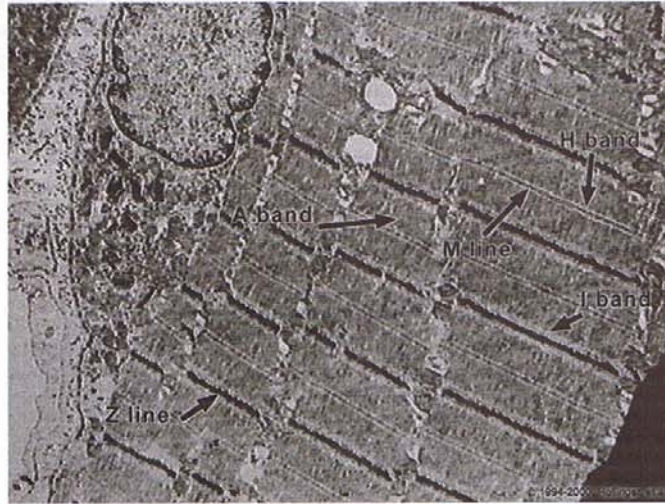


Figure I-3-2. EM of Skeletal Muscle

Sarcomere Structure

The banding pattern seen in striated muscle is caused by the arrangement of thin and thick myofilaments (Figure I-3-3).

- Thick filaments occupy the central portions of the sarcomere.
- Thin filaments attach at one end to the Z line and run parallel to, and between, the thick filaments.
- I bands are composed of thin filaments only.
- A bands are composed mostly of thick filaments and the thin filaments between them.
- H bands are composed of thick filaments only.

Thin filaments

Thin filaments are composed of the proteins actin, tropomyosin, and troponin.

- **Actin** is a long fibrous structure (F-actin) composed of two strands of spherical or globular G-actin monomers twisted in a double helix. The filament is polar and contains myosin-binding sites on the G-actin monomers.
- **Tropomyosin** is a polar molecule containing two polypeptide chains in the form of an α -helix. The tropomyosin molecules lie head-to-tail to form filaments that lie in the grooves of the actin helix.

- **Troponin (Tn)** is composed of three polypeptides: TnT binds to tropomyosin at intervals along the thin filament, TnC binds calcium ions, and TnI inhibits actin–myosin interaction.

Thick filaments

Thick filaments are composed of myosin. Myosin is a molecule that contains a tail and two heads.

- The tail fiber is formed from portions of two heavy chains, which are wound in a coil.
- The heads are globular regions formed by the association of part of one heavy chain with two light chains. **Myosin heads function as active sites for ATPase activity and as actin-binding sites.**

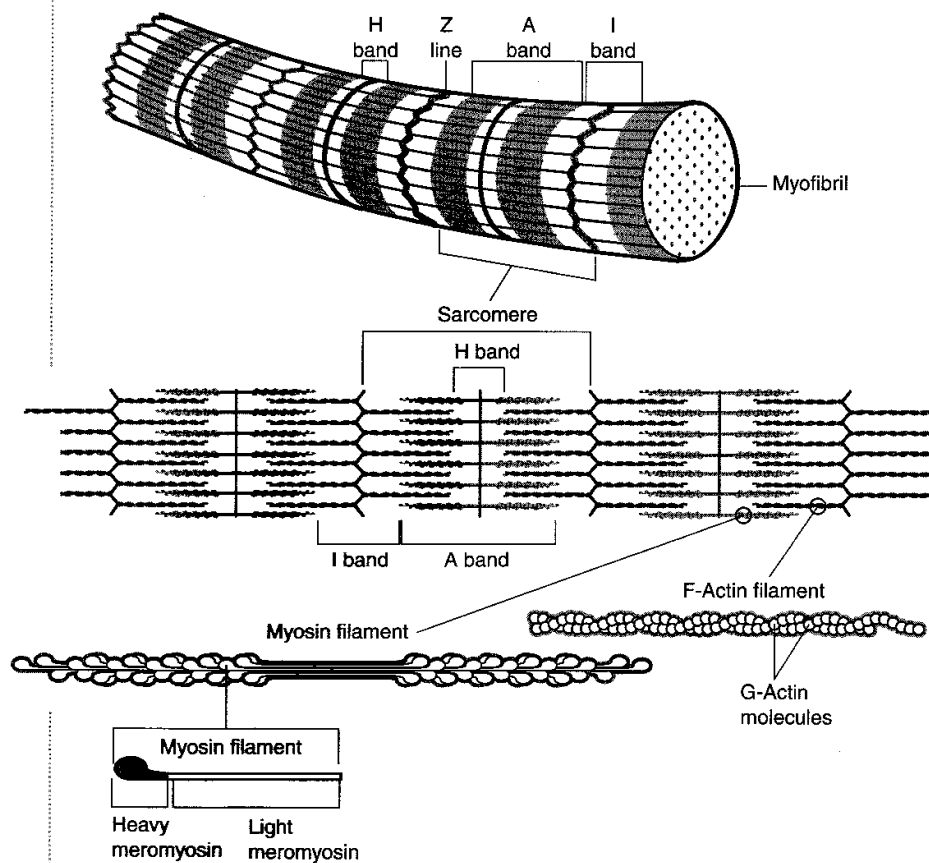


Figure I-3-3. Sarcomere Structure

Transverse Tubular System

Skeletal muscle fibers contain fingerlike invaginations of the sarcolemma that surround each myofibril. These invaginations constitute the transverse (T) tubule system (Figure I-3-4). Note the following:

- Each T tubule lies between the two cisternae of the sarcoplasmic reticulum (SR) to form a triad.
- There are two triads in each sarcomere, which are present at the junction between the A and I bands.
- These units serve to couple excitation of muscle cells to their contraction (excitation–contraction coupling).

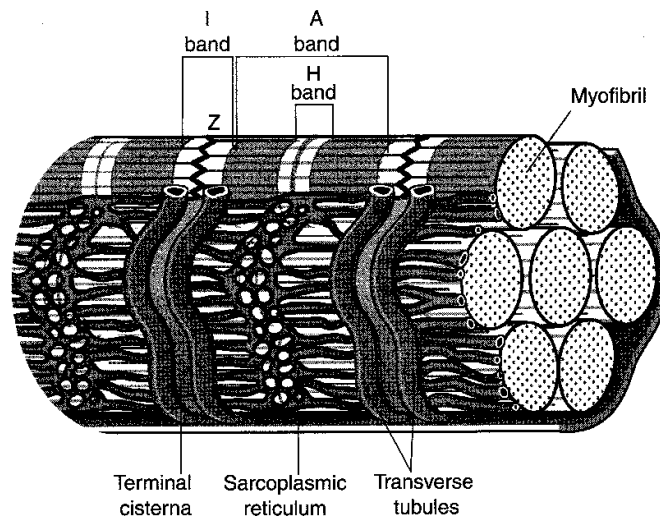


Figure I-3-4. Striated Muscle Fiber Showing Sarcoplasmic Reticulum and T-tubule System

CARDIAC MUSCLE

Cardiac muscle has an arrangement of sarcomeres similar to that in skeletal muscle as well as a T tubule system associated with the SR (near the Z line). However, unlike skeletal muscle fibers, the fibers are electrically coupled through gap junctions.

Cardiac muscle fibers are joined together by junctional complexes called intercalated discs. These and other differences are summarized in Table I-3-2.

SMOOTH MUSCLE

Smooth muscle is found in the walls of blood vessels and hollow viscera. Bands of smooth muscle cells can be found in the erector pili muscles of the skin.

Gap Junctions

Gap junctions electrically couple smooth muscle cells.

Filaments

Smooth muscles contain actin and myosin filaments, but the filaments are not arranged in orderly arrays as in skeletal muscle.

- Bundles of myofilaments course obliquely in the cell, forming a lattice-like arrangement.
- A sliding filament mechanism of contraction is thought to occur.
- Thin filaments insert into dense bodies located within smooth muscle cytoplasm and attach to their membranes.

Contraction

Smooth muscle contraction may be triggered by various stimuli such as autonomic nerves or hormones. Depolarization of the cell membrane results in an influx of Ca^{2+} from outside the cell. Ca^{2+} is sequestered in either the cell membrane or in the sparse SR.

SUMMARY

Some of the principal ultrastructural features of the three types of muscle are summarized in Table I-3-2.

Table I-3-2. Ultrastructure Comparison of the Three Types of Muscle

Skeletal	Cardiac	Smooth
Overlapping actin and myosin filaments, forming a characteristic banding pattern	Overlapping actin and myosin filaments, forming a characteristic banding pattern	Actin and myosin do not form a banding pattern
T tubules form triadic contacts with SR at A-I junction	T tubules form dyadic contacts with SR near Z line	Lack T tubules; have limited SR
Sarcolemma lacks junctional complexes between fibers	Junctional complexes between fibers (intercalated discs), including gap junctions	Gap junctions
Troponin	Troponin	Calmodulin
Z disks—intermediate filament protein is desmin	Z disks—intermediate filament protein is desmin	Dense bodies in intermediate filament protein is desmin; or vimentin in vascular smooth muscle

Chapter Summary

Muscles are classified as skeletal, cardiac, or smooth. General features are summarized in Table I-3-1.

Skeletal Muscle

Skeletal muscle has three levels of connective tissue: **endomysium**, **perimysium**, and **epimysium**. Skeletal muscle is composed of long cylindrical fibers that **have dark (A) bands and light (I) bands**. A dark transverse line, the **Z line**, bisects each I band. Skeletal muscle fibers contain **myofibrils**, which in turn are composed of **sarcomeres**.

Sarcomeres have **thick and thin filaments**. Thick filaments are centrally located in sarcomeres, where they interdigitate with thin filaments. The **I band contains thin filaments only**, the **H band contains thick filaments only**, and the **A bands contain both thick and thin filaments**.

Thin filaments contain three proteins: **actin**, **tropomyosin**, and **troponin**.

Actin forms a double helix, whereas tropomyosin forms an α -helix. Troponin includes three polypeptides: TnT, which binds to tropomyosin; TnC, which binds to calcium ions; and TnI, which inhibits actin-myosin interaction. **Thick filaments** are composed of myosin. Myosin has two heavy chains with globular head regions. The heads contain actin-binding sites and have ATPase activity. The **transverse tubular system** surrounds each myofibril and facilitates excitation-contraction coupling.

Cardiac Muscle

Cardiac muscle has an arrangement of sarcomeres similar to that in skeletal muscles, *but the fibers are coupled through gap junctions*.

Smooth muscle is found in the walls of blood vessels and hollow viscera. Gap junctions couple them electrically. Myofilaments of smooth muscles are not arrayed like in skeletal muscles; they are obliquely placed in order to form a latticework. Electrical or chemical signaling via hormones can trigger smooth muscles. Table I-3-2 summarizes the differences between the three types of muscles.

Lymphoid Organs

4

THYMUS

The thymus is encapsulated and contains trabeculae. It has cortical and medullary regions (Figure I-4-1). The thymus contains epithelial reticular cells and Hassall corpuscles in the medulla and lacks germinal centers. The thymus protects developing T cells by the blood–thymus barrier that consists of a capillary wall, connective tissue, a basement lamina of epithelial reticular cells, and cytoplasm of epithelial reticular cells.

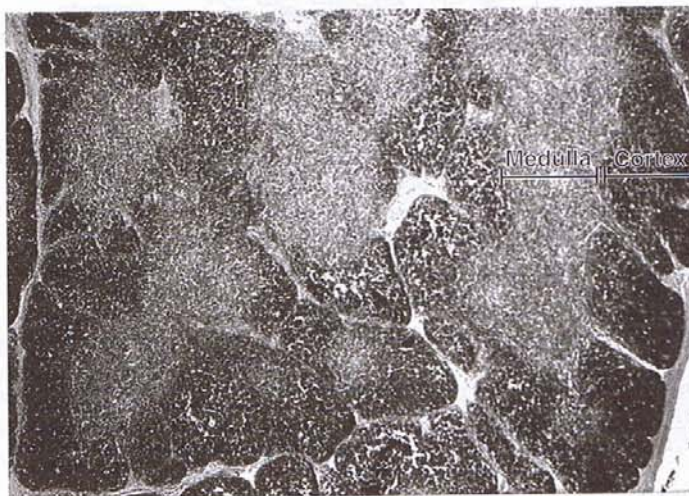


Figure I-4-1. Thymus

LYMPH NODE

The lymph node is associated with afferent and efferent lymphatic vessels. It is surrounded by a capsule, has trabeculae, and can be divided into outer cortical, inner cortical (paracortical), and medullary regions (Figure I-4-2):

- The outer cortex contains most of the nodules and germinal centers. It is populated by most of the B lymphocytes.
- The inner cortex is populated by T lymphocytes.

Dendritic Cells

The lymph node contains dendritic cells, which are antigen-presenting cells.

High Endothelial Venules

High endothelial venules form the site of repopulation of lymph nodes and are found in the paracortical zone.

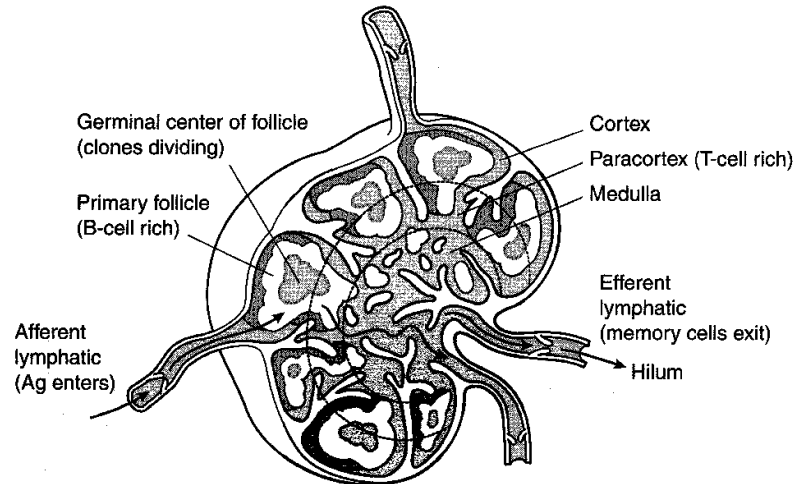


Figure I-4-2. Lymph Node

SPLEEN

The spleen has an extensive blood supply consisting of trabecular arteries, central arteries, penicillar arteries, sinusoids, red pulp veins, and trabecular veins. It is surrounded by a capsule, has trabeculae, and is divided into red and white pulp (Figure I-4-3).

White Pulp

White pulp consists of lymphoid tissue that ensheaths the central arteries (periarterial sheath) along with the associated nodules and germinal centers. The periarterial sheath is populated mainly by T lymphocytes. The peripheral white pulp and germinal centers are populated mainly by B lymphocytes.

Red Pulp

Red pulp **consists of splenic cords (of Billroth) and venous sinusoids**. Defective red blood cells resulting from aging or disease (as in sickle cell anemia, hereditary spherocytosis, or thalassemia syndromes) are delayed in their passage from Billroth cords into the venous sinusoids and phagocytosed by macrophages lining the cords.

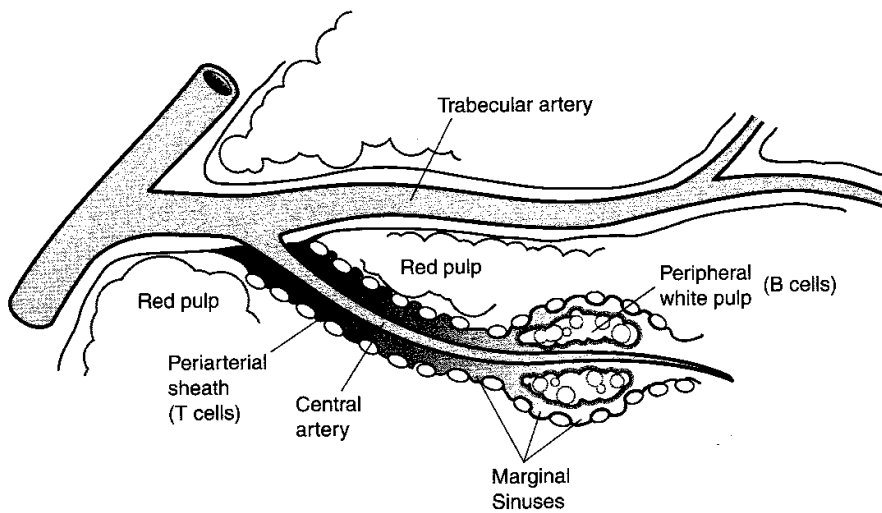


Figure I-4-3. Spleen Schematic

Chapter Summary

The thymus contains trabeculae and has a cortical and medullary region. Epithelial reticular cells and Hassall's corpuscles are located within the medulla. The cortex lacks germinal centers. The thymus protects developing T cells by the blood-thymus barrier.

The lymph node has three layers: **cortical** (outer and inner, i.e., **paracortical** and **medullary**). The outer cortical layer contains most of the nodules and germinal centers. Most of the **B lymphocytes** reside here, whereas **T lymphocytes** reside in the paracortical layer. **Dendritic cells** within lymph nodes are antigen-presenting cells. High endothelial venules are the site of repopulation of lymph nodes and are located within the paracortical zones.

The spleen is very vascular and has red and white pulp. **White pulp** is composed of lymphoid tissue. T lymphocytes are located in the periarterial sheaths, while peripheral white pulp and germinal centers contain B lymphocytes. **Red pulp** consists of splenic cords and venous sinusoids. Its function is to delay passage of defective red blood cells to enable their elimination through phagocytosis by macrophages.

Integument

5

GENERAL FEATURES

The integument consists of the skin (epidermis and dermis) and associated appendages (sweat glands, sebaceous glands, hairs, and nails). It is considered to be the largest organ in the body. The integument constitutes approximately 16% of total body weight. The integument functions to protect the body from injury, desiccation, and infection. It also participates in sensory reception, excretion, thermoregulation, and maintenance of water balance.

EPIDERMIS

The epidermis is the outermost layer of the integument (Figure I-5-1). It is a stratified squamous epithelial layer of ectodermal origin. It is devoid of blood vessels and consists of four or five layers from deep to superficial.

Layers

The layers of the epidermis are:

- **Stratum basale** (stratum germinativum) is a proliferative basal layer of columnar-like cells that contain the fibrous protein keratin.
- **Stratum spinosum** is a multilaminar layer of cuboidal-like cells that are bound together by means of numerous desmosomal junctions.
- **Stratum granulosum** consists of flat polygonal cells filled with basophilic keratohyalin granules. Viewed at the electron microscopic level, these cells also contain numerous membrane-coating granules.
- **Stratum lucidum** is the transitional zone of flat eosinophilic or pale-staining anucleated cells only found in regions with a thick stratum corneum.
- **Stratum corneum** is the superficial stratum consisting of several layers of flat, anucleated, and cornified (keratinized) cells.

Cell Types

The epidermis contains several cell types:

- **Keratinocytes** are the most numerous and are responsible for the production of the family of keratin proteins that provide the barrier function of the epidermis.
- **Melanocytes** are derivatives of neural crest ectoderm. They are found in the dermis and are also scattered among the keratinocytes in the basal layers of the epidermis. These cells produce the pigment melanin in the form of melanosomes that are transferred to keratinocytes.

Clinical Correlate

Pemphigus is an autoimmune blistering disorder caused by disruption of desmosomes linking keratinocytes.

Psoriasis results from an increase in the number of proliferating cells in stratum basale plus stratum spinosum. In addition, there is an increase in the rate of cell turnover. This results in greater epidermal thickness and continuous turnover of the epidermis.

Clinical Correlate

Albinism occurs when melanocytes are unable to synthesize melanin (either by absence of tyrosinase activity or inability of cells to take up tyrosine).

Vitiligo is a disorder in which melanocytes are destroyed. It is thought to occur secondary to autoimmune dysfunction, leading to depigmentation.

Clinical Correlate

Bullous pemphigoid is an autoimmune blistering disorder of the dermis-epidermis junction. Immunofluorescence studies demonstrate the presence of IgG that is directed against an antigen in the lamina lucida.

- **Langerhans cells** are members of the immune system and function as antigen-presenting cells.
- **Merkel cells** are found in the basal epidermis and appear to function in concert with the nerve fibers that are closely associated with them. At the electron microscopic level, their cytoplasm contains numerous membrane-bound granules that resemble those of catecholamine-producing cells.

DERMIS

The dermis is a connective tissue layer of mesodermal origin below the epidermis and its basement membrane.

Dermis-Epidermal Junction

The dermis-epidermal junction is characterized by numerous papillary interdigitations of the dermal connective tissue and epidermal epithelium, especially in thick skin. This increases the surface area of attachment and brings blood vessels in closer proximity to the epidermal cells.

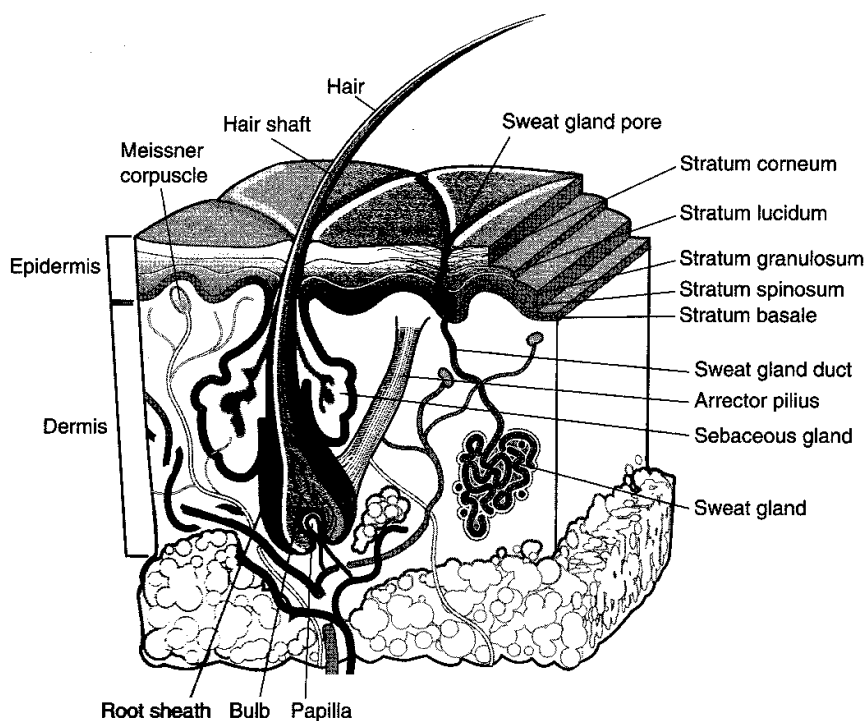


Figure 1-5-1. Skin

HYPODERMIS

The hypodermis is a layer of loose vascular connective tissue infiltrated with adipocytes, and it corresponds to the superficial fascia of gross anatomy. The hypodermis fastens the skin to underlying muscles and other structures.

SWEAT GLANDS

Sweat glands are epidermal derivatives. Two types are compared in Table I-5-1.

Table I-5-1. Features of Eccrine and Apocrine Sweat Glands

	Eccrine	Apocrine
Size	0.4 mm diameter	3–5 mm diameter
Location	Essentially everywhere with some exceptions (e.g., glans penis)	Axillary, areolar, and anal region
Site of opening	Skin surface	Hair follicles
Discharge	Watery, little protein, mainly H ₂ O, NaCl, urea, NH ₃ , and uric acid	Viscous, odor producing
Innervation	Cholinergic	Adrenergic

SEBACEOUS GLANDS

Sebaceous glands are simple, branched holocrine acinar glands. They usually discharge their secretions onto the hair shaft within hair follicles. They are found in the dermis throughout the skin, except on the palms and soles. Sebaceous glands lubricate hairs and cornified layers of the skin to minimize desiccation.

HAIR

Hairs are long, filamentous projections consisting of keratinized epidermal cells. They develop from epidermal invaginations called hair follicles. Bundles of smooth muscle cells, called arrector pili muscles, are attached to the hair follicle at one end and to the papillary dermis at the other. Contraction of these muscles raises the hairs and dimples the epidermis ("goose flesh"). The follicles and associated sebaceous glands are known as pilosebaceous units.

NAILS

Nails, like hair, are a modified stratum corneum of the epidermis. They contain hard keratin that forms in a manner similar to the formation of hair. Cells continually proliferate and keratinize from the stratum basale of the nail matrix.

Chapter Summary

The **integument** consists of the skin (epidermis and dermis) and associated appendages (sweat and sebaceous glands, hairs, and nails). It is the largest organ in the body. The **epidermis** is devoid of blood vessels and contains a stratified squamous epithelium derived primarily from **ectoderm**. It is composed of six layers in thick skin: **stratum basale**, which is a proliferative layer of columnar/cuboidal cells, showing mitotic activity; **stratum spinosum**, which is a multilaminar layer of cuboidal/polygonal cells; **stratum granulosum**, which has more flattened polygonal cells containing basophilic granules; **stratum lucidum**, which is a thin, eosinophilic layer of squamous cells; and **stratum corneum**, which is a thick layer containing anucleate keratinized cells. All six layers contain various amounts of keratin.

The **epidermis** contains four cell types: **keratinocytes**, which produce keratin; **melanocytes** derived from neural crest cells that produce melanin; **Langerhans cells**, which are antigen-presenting cells; and **Merkel cells**, associated with nerve fibers. The **dermis** is a connective tissue layer mainly of **mesodermal origin**. Other layers are the dermis-epidermal junction and hypodermis. The latter contain adipocytes.

Sweat glands may be eccrine or apocrine. These are compared in Table I-5-1.

Sebaceous glands are branched holocrine acinar glands that discharge their secretions onto hair shafts within hair follicles. They are absent in the palms and soles.

Hair is comprised of keratinized epidermal cells. Hair follicles and the associated sebaceous glands are known as pilosebaceous units.

Nails are modified stratum corneum of the epidermis and contain hard keratin. Cells continually proliferate and keratinize from the stratum basale of the nail matrix.

Respiratory System

6

GENERAL FEATURES

The respiratory system is divided into a conducting portion (nasal cavity, pharynx, larynx, trachea, bronchi, bronchioles) (Figure I-6-1), which carries the gases during inspiration and expiration, and a respiratory portion (alveoli), which provides for gas exchange between air and blood.

NASAL CAVITIES

The nasal cavities contain two major areas.

Respiratory Area

The respiratory area is lined by a pseudostratified, ciliated, columnar epithelium. The epithelium contains goblet cells (respiratory epithelium) and a subjacent fibrous lamina propria with mixed mucous and serous glands.

Mucus is carried toward the pharynx by ciliary motion. The lateral walls contain conchae, which increase the surface area and promote warming of the inspired air. This region is richly vascularized and innervated.

Olfactory Area

The olfactory area is located in the posterosuperior nasal cavity and is lined by a pseudostratified epithelium composed of bipolar neurons (olfactory cells), supporting cells, brush cells, and basal cells.

The basal cells are stem cells that continuously turn over to replace the olfactory receptor cells. **This is the only example in the adult human where neurons are replaced.**

Under the epithelium, Bowman glands produce serous fluid, which dissolves odorous substances.

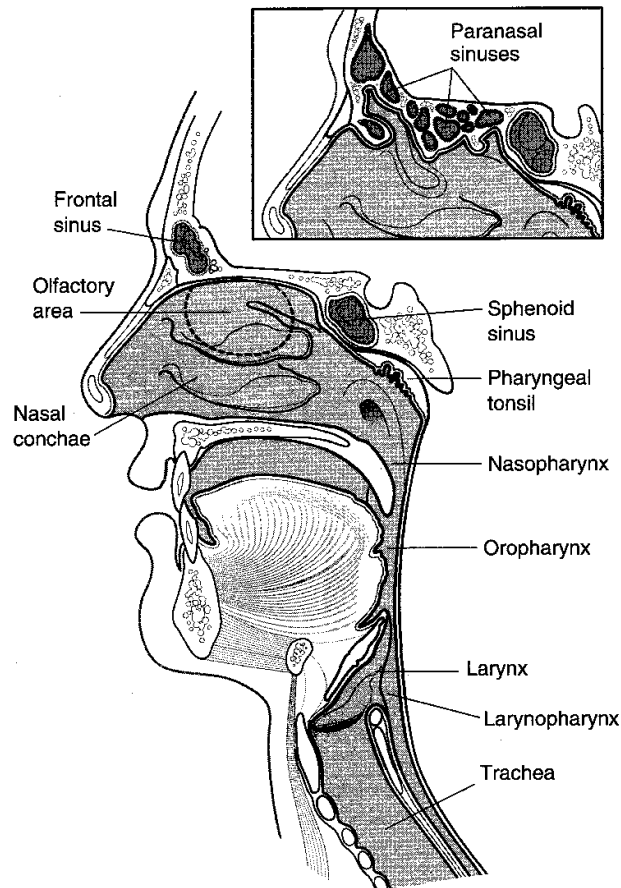


Figure I-6-1

PARANASAL SINUSES

Paranasal sinuses are cavities in the frontal, maxillary, ethmoid, and sphenoid bones that communicate with the nasal cavities. They contain a thin respiratory epithelium over a lamina propria containing numerous goblet cells, which produce mucus that drains into the nasal passages.

NASOPHARYNX

The nasopharynx is lined by a respiratory epithelium. The cilia beat toward the oropharynx, which is composed of a stratified, squamous, nonkeratinized epithelium.

Pharyngeal Tonsil

Located on the posterior wall of the nasopharynx, subjacent to the epithelium, is the pharyngeal tonsil, an aggregate of nodular and diffuse lymphatic tissue.

LARYNX

See Gross Anatomy section.

TRACHEA

The trachea leads to the terminal bronchioles. The major histologic changes occurring in the passage from the trachea to the bronchioles are summarized in Table I-6-1.

Clinical Correlate

Adenoiditis

Hypertrophy of the pharyngeal tonsil as a result of chronic inflammation results in a condition known as adenoiditis.

Table I-6-1. Histologic Features of Trachea, Bronchi, and Bronchioles

	Trachea	Bronchi	Bronchioles
Epithelia	Pseudostratified ciliated columnar (PCC) cells, goblet cells	PCC to simple columnar cells	Ciliated, some goblet cells, Clara cells in terminal bronchioles
Cartilage	16–20 C-shaped cartilaginous rings	Irregular plates	None
Glands	Seromucous glands	Fewer seromucous glands	None
Smooth muscle	Between open ends of C-shaped cartilage	Prominent	Highest proportion of smooth muscle in the bronchial tree
Elastic fibers	Present	Abundant	Abundant

RESPIRATORY BRONCHIOLES

Respiratory bronchioles contain alveoli and branch to form two to three alveolar ducts, which are long sinuous tubes that often terminate in alveolar sacs. Alveolar sacs are spaces formed by two or more conjoined alveoli. They are lined by the simple squamous alveolar epithelium.

ALVEOLI

Alveoli are the terminal, thin-walled sacs of the respiratory tree that are responsible for gas exchange. There are approximately 300 million alveoli per lung, each one 200 to 300 μ m in diameter (Figure I-6-2). The alveolar epithelium contains two cell types.

Type I Cells

Type I cells cover almost all of the alveolar luminal surface and provide a thin surface for gas exchange. This simple squamous epithelium is so thin (~25 nm) that its details are beyond the resolution of the light microscope.

Type I cells constitute one component of the blood–air interface.

- Oxygen in the alveoli is separated from the red blood cells of the alveolar capillaries by the type I cell.
- Its basal lamina is often conjoined with the basal lamina of the capillary and the capillary endothelial cell.
- The total thickness of all these layers can be less than 0.5 mm.

Type II Cells

Type II cells are cuboidal-like cells that sit on the basal lamina of the epithelium and contain membrane-bound granules of phospholipid and protein (lamellar bodies). The contents of these lamellar bodies are secreted onto the alveolar surface to provide a coating of surfactant that reduces alveolar surface tension.

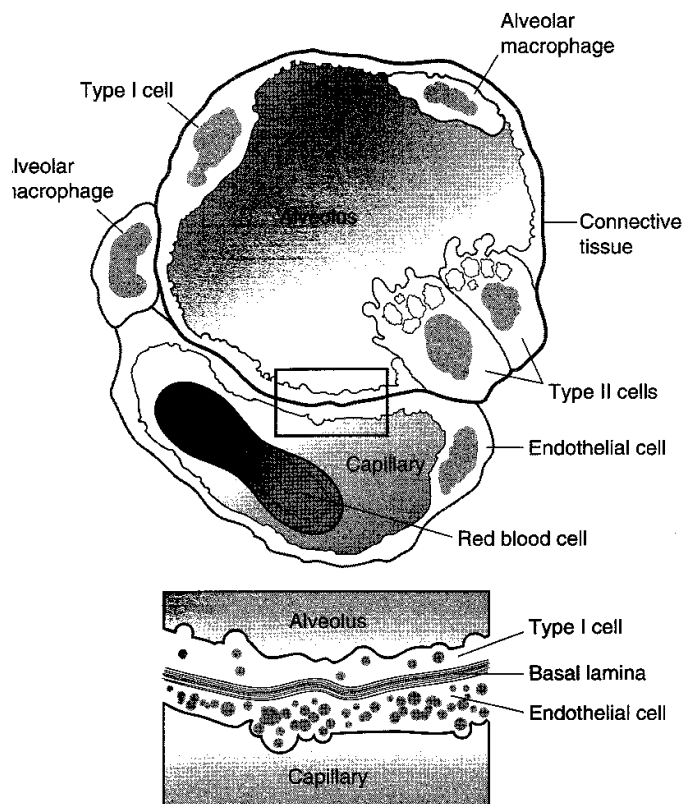


Figure I-6-2. Alveolus and Blood–Air Barrier

ALVEOLAR MACROPHAGES

Alveolar macrophages (dust cells) are found on the surface of the alveoli. They are derived from monocytes that extravasate from alveolar capillaries; alveolar macrophages are part of the mononuclear phagocyte system.

Alveolar macrophages continuously remove particles and other irritants in the alveoli by phagocytosis. They derive from monocytes and form part of the mononuclear phagocyte system.

Chapter Summary

The nasal cavities have two major areas: respiratory and olfactory.

The **respiratory area** is lined by pseudostratified, ciliated columnar epithelium. Goblet cells are present as well. The **olfactory area** is in the posterosuperior area and contains bipolar neurons. Olfactory neurons are constantly replenished. **Paranasal sinuses** are located in the frontal, maxillary, ethmoid, and sphenoidal bones. They communicate with the nasal cavities. The **nasopharynx** is composed of stratified, squamous nonkeratinized epithelium. The **pharyngeal tonsil** is an aggregate of nodular and diffuse lymphatic tissue within the posterior wall of the nasopharynx.

Histologic features of the trachea, bronchi, and bronchioles are described in Table I-6-1. **Respiratory bronchioles** contain alveoli and branch to form alveolar ducts, which terminate in alveolar sacs and are lined by squamous alveolar epithelium. **Alveoli** are terminal, thin-walled sacs of the respiratory tree responsible for gaseous exchange. They contain two kinds of cells. **Type I cells** provide a thin surface for gaseous exchange, whereas **Type II cells** produce surfactant. **Alveolar macrophages (dust cells)** are located on the surface of alveoli and within the interalveolar connective tissue. They are derived from monocytes.

Gastrointestinal System

7

GENERAL FEATURES

The gastrointestinal (GI) system consists of the digestive tract and its associated glands.

DIGESTIVE TRACT

The major regional characteristics and cell types of the digestive tract are summarized in Table I-7-1.

Table I-7-1. Digestive Tract—Regional Comparisons

Region	Major Characteristics	Mucosal Cell Types at Surface	Function of Surface Mucosal Cells
Esophagus	Nonkeratinized Stratified squamous epithelium; skeletal muscle in muscularis externa (upper 1/3); smooth muscle (lower 1/3)		
Stomach: body and fundus	Rugae: shallow pits; deep glands	Mucous cells	Secrete mucus. Form protective layer against acid. Tight junctions between these cells probably contributes to the acid barrier of the epithelium.
		Chief cells Parietal cells Enteroendocrine (EE) cells	Secrete pepsinogen and lipase precursor. Secrete HCl and intrinsic factor. Secrete a variety of peptide hormones.
Stomach: pylorus	Deep pits; shallow branched glands	Mucous cells Parietal cells EE cells	Same as above. Same as above. High concentration of gastrin.

(Continued)

Table I-7-1. Digestive Tract—Regional Comparisons (*continued*)

Region	Major Characteristics	Mucosal Cell Types at Surface	Function of Surface Mucosal Cells
Small intestine:	Villi, plicae, and crypts (Figure I-7-2)	Columnar absorptive cells	Contain numerous microvilli that greatly increase the luminal surface area, facilitating absorption.
Duodenum (Figure I-7-3)	Brunner glands, which secrete an alkaline secretion	Goblet cells Paneth cells EE cells	Secrete acid glycoproteins that protect mucosal lining. Contains granules that contain lysozyme. May play a role in regulating intestinal bacterial flora. High concentration of cells that secrete cholecystokinin and secretin.
Jejunum	Villi, well-developed plica, crypts	Same cell types as found in the duodenal epithelium	Same as above.
Ileum (Figure I-7-4)	Aggregations of lymph nodules called Peyer patches	M cells, found over lymphatic nodules and Peyer patches	Endocytose and transport antigen from the lumen to lymphoid cells.
Large intestine	Lacks villi, has crypts	Mainly mucus-secreting and absorptive cells	Transports Na ⁺ (actively) and water (passively) out of lumen.

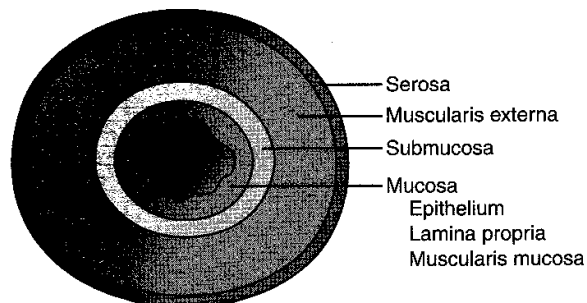


Figure I-7-1. Layers of the Digestive Tract

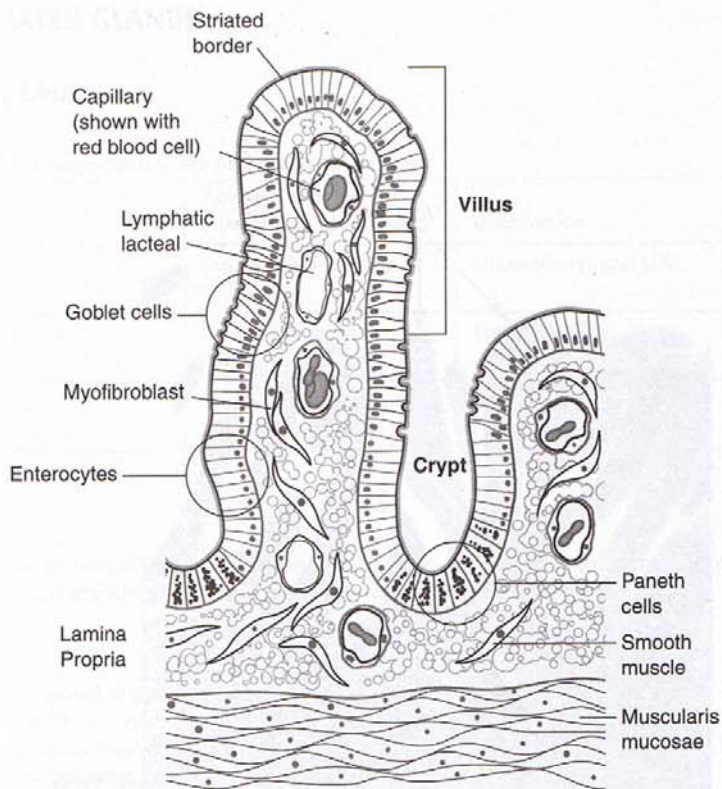


Figure I-7-2. Structure of Small Intestine Villus and Crypts

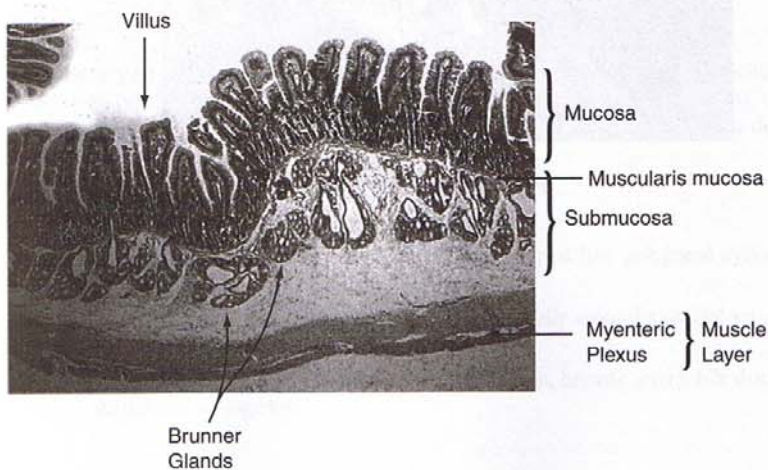


Figure I-7-3. Duodenum

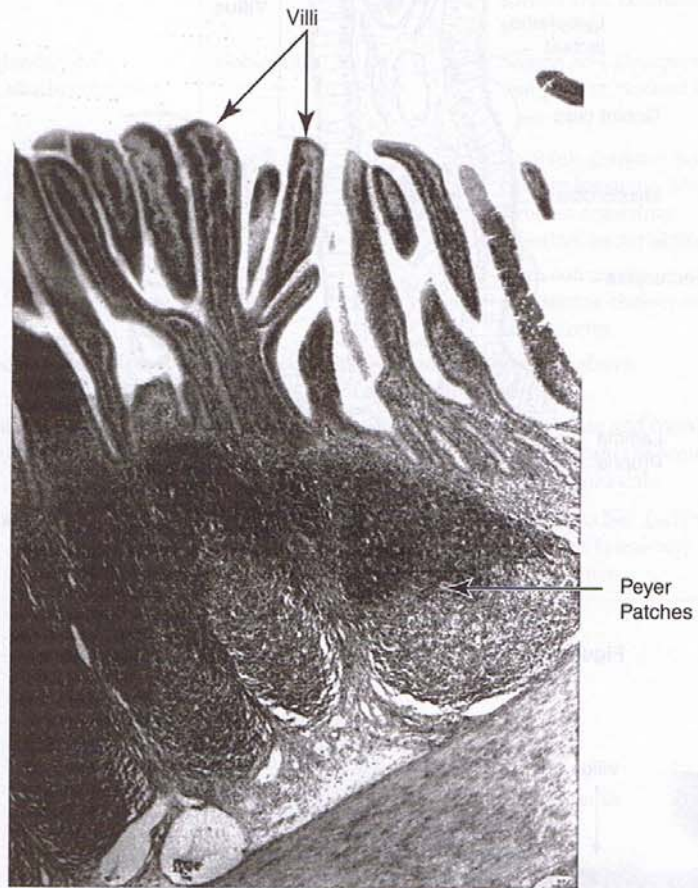


Figure I-7-4. Ileum

ASSOCIATED GLANDS

Salivary Glands

Table I-7-2. Comparison of the Major Salivary Glands

Gland	Acinar Cell Type (Histologic Appearance)	Innervation
Parotid	Serous (high amylase activity)	Glossopharyngeal (IX)
Submandibular	Serous and mucous; mainly serous	Facial (VII)
Sublingual	Mucous and serous; mainly mucous	Facial (VII)

Pancreas

The exocrine portion of the pancreas consists of parenchymal cells arranged in the form of acini and a system of branching ducts that drain into the lumen of the small intestine.

Acini

Acini are composed of pyramidal serous-type cells, each of which produces membrane-bound granules of mixed enzymes for secretion. Pancreatic enzymes cleave proteins (e.g., trypsin, chymotrypsin, carboxypeptidase, elastase), carbohydrates (e.g., amylase), fats (e.g., lipase, lecithinase), and nucleic acids (e.g., ribonuclease, deoxyribonuclease).

Duct cells

Duct cells secrete water, electrolytes, and bicarbonate (HCO_3^-), which dilute enzyme secretions and neutralize acidic chyme.

Liver

The liver is the largest gland of the body. It has multiple and complex functions, including exocrine secretion (via bile ducts into the duodenal lumen) and maintenance of optimal concentrations of various components of blood, which it receives via the portal vein from the digestive tract and spleen.

Liver parenchyma

The liver parenchyma is divided into many small lobules shaped like polygonal cylinders (Figure I-7-5).

- Each cylinder is composed of plates of cells arranged radially around a central vein. Between the plates are radial blood sinusoids.
- At the periphery of the lobules, branches of the portal vein, hepatic artery, bile ducts, and lymphatics course together.

Hepatocytes

Hepatocytes are 20- to 30- μ m polyhedral cells (Figure I-7-5). Liver regeneration can occur rapidly under some circumstances. As much as 90% can be replaced in about 2 weeks.

- Their six or more surfaces may either contact another cell to form gap junctions and bile canaliculi or form a free surface with microvilli exposed to the perisinusoidal space of Disse.
- Abundant glycogen in these cells takes the form of electron-dense granules that are clustered near the SER.
- There are several hundred mitochondria per liver cell.
- The hepatocyte produces proteins for export (e.g., albumin, prothrombin, fibrinogen), secretes bile, stores lipids and carbohydrates, converts lipids and amino acids into glucose via the enzymatic process of gluconeogenesis, and detoxifies and inactivates drugs by oxidation, methylation, and conjugation.

Sinusoids

The liver contains **sinusoids** (Figure I-7-5) that are lined with fenestrated endothelial cells and scattered phagocytic Kupffer cells, which are part of the mononuclear phagocyte system.

- **Kupffer cells** phagocytize red blood cells and particles and contain cytoplasmic residual bodies of iron and pigments.
- **Lipocytes** also lie in the perisinusoidal space.

Biliary system

The liver contains a biliary system consisting of:

- **Bile canaliculi**—tubular spaces limited by the plasma membrane of several hepatocytes (Figure I-7-5). These ducts empty into Hering canals, which are small ducts composed of cuboidal cells.
- **Hepatic ducts**—receive Hering canals and eventually form the right and left hepatic ducts, which join to form the common hepatic duct.
- **Common bile duct**—receives the common hepatic and cystic ducts.

Gallbladder

The **gallbladder** is lined by a surface epithelium composed of simple, tall, columnar cells. They bear irregular microvilli with a glycoprotein surface coat.

The gallbladder concentrates bile by active transport of Na^+ , Cl^- , and water (especially of Na^+) from the cytoplasm to the intercellular space. From there, the water moves into blood vessels, and the bile is concentrated.

Contraction of the muscle layer (**muscularis externa**) of the gallbladder is induced by the hormone cholecystokinin, which is produced in the mucosa of the small intestine.

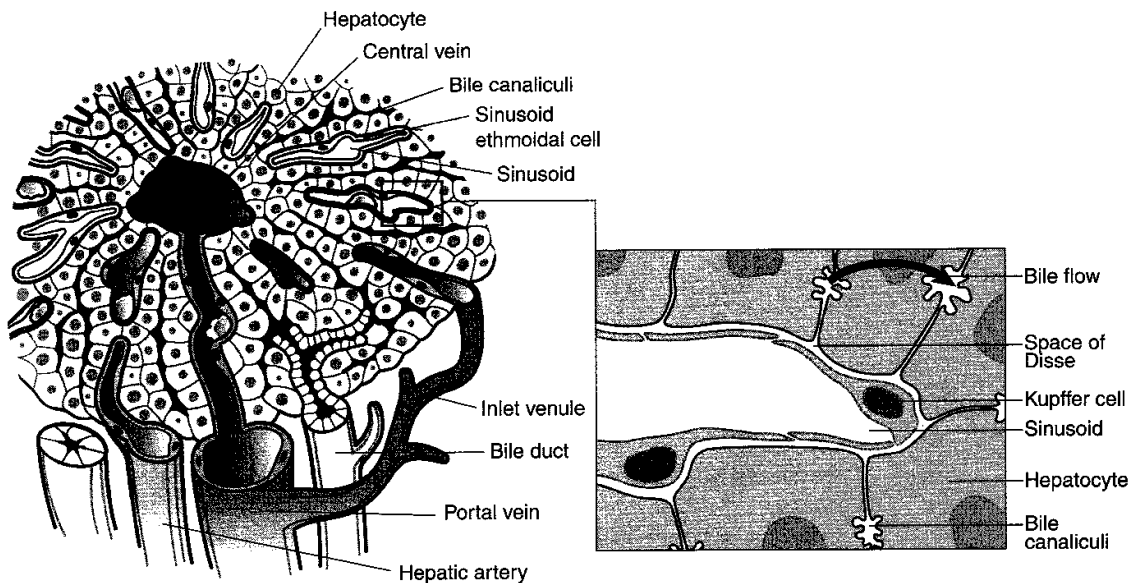


Figure I-7-5. Organization of a Liver Lobule

Chapter Summary

The **gastrointestinal system** includes the **digestive tract** and its associated **glands**. The regional comparisons of the **digestive tract** are given in Table I-7-1.

The associated **glands** are **salivary**, **pancreas**, **liver**, and the **gall bladder**. The **salivary glands** are compared in Table I-7-2.

The **pancreas** has an **exocrine** portion and an **endocrine** portion. The exocrine portion is composed of **acini** and **duct cells**. **Acini** secrete enzymes that cleave proteins, carbohydrates, and nucleic acids. **Duct cells** secrete water, electrolytes, and bicarbonate.

The **liver** is the largest gland in the body. The parenchyma is made up of hepatocytes arranged in cords within lobules. Hepatocytes produce proteins, secrete bile, store lipids and carbohydrates, and convert lipids and amino acids into glucose. They detoxify drugs by oxidation, methylation, or conjugation, and they are capable of regeneration. Liver **sinusoids**, found between hepatic cords, are lined with endothelial cells and scattered **Kupffer cells**, which phagocytose red blood cells.

The **biliary system** is composed of bile canaliculi, hepatic ducts, the cystic duct, and the common bile duct. The **gall bladder** is lined by simple tall columnar cells and has a glycoprotein surface coat. It concentrates bile by removing water through active transport of sodium and chloride ions (especially the former). Gall bladder contraction is mediated via cholecystokinin, a hormone produced by enteroendocrine cells in the mucosa of the small intestine.

Renal/Urinary System

8

KIDNEY

The kidney is divided into three major regions: the hilum, cortex, and medulla (Figure I-8-1).

Hilum

The hilum is located medially and serves as the point of entrance and exit for the renal artery, renal vein, and ureter.

- The renal pelvis, the expanded upper portion of the ureter, divides into two or three major calyces upon entrance into the kidney. These, in turn, divide into eight minor calyces.
- Branches of the renal artery, vein, and nerve supply each part of the kidney.

Cortex

The cortex forms the outer zone of the kidney as well as several renal columns, which penetrate the entire depth of the kidney.

Medulla

The medulla appears as a series of medullary pyramids. The apex of each pyramid directs the urinary stream into a minor calyx.

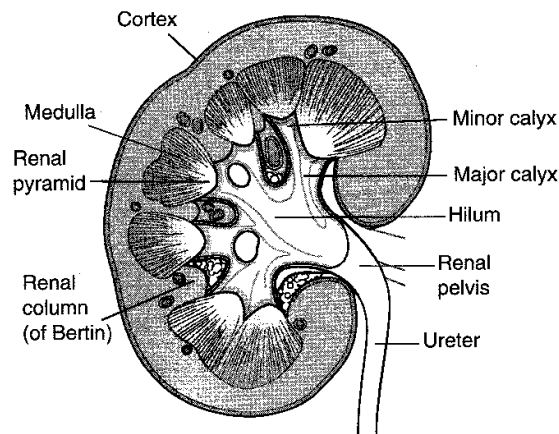


Figure I-8-1. Organization of the Kidney

URINIFEROUS TUBULES

The uriniferous tubules consist of two functionally related portions called the nephron and the collecting tubule.

Nephron

The nephron consists of a renal corpuscle, proximal convoluted tubule, loop of Henle, and distal convoluted tubule (Figure I-8-2).

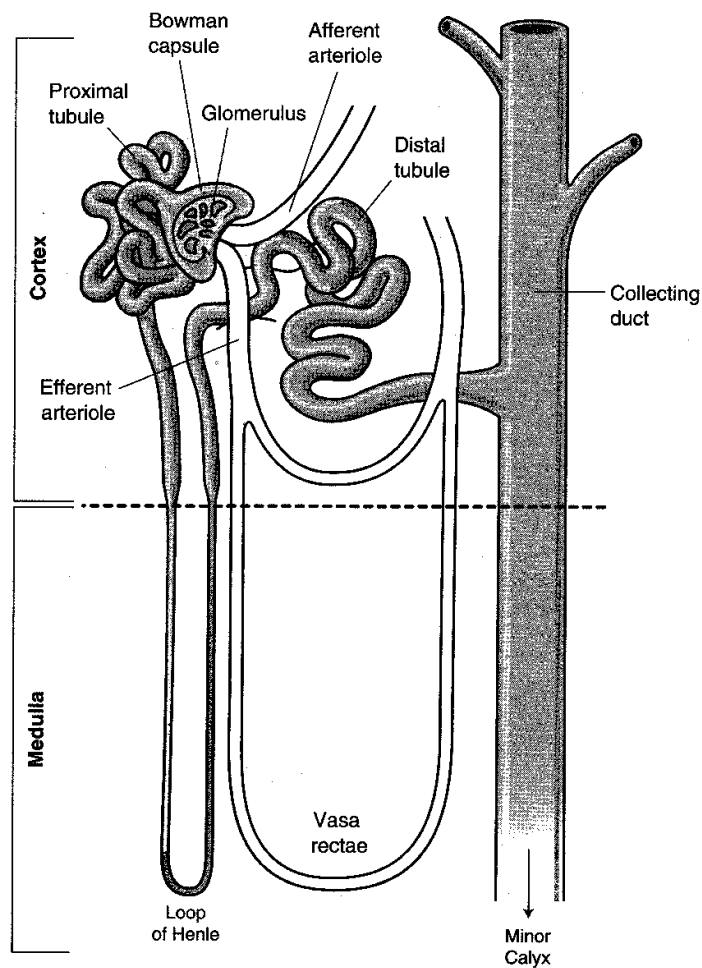


Figure I-8-2. Nephron Diagram

Renal corpuscle

The renal corpuscle consists of a tuft of capillaries, or glomerulus, surrounded by a double-walled epithelial capsule called Bowman capsule (Figure I-8-3).

Glomerulus

The glomerulus is composed of several anastomotic capillary loops interposed between an afferent and an efferent arteriole. The endothelium of the glomerulus is thin and fenestrated. Plasma filtration (ultrafiltration) occurs in the glomerulus.

Bowman Capsule

The Bowman capsule consists of an inner visceral layer and an outer parietal layer (Figure I-8-3). The space between these layers, the urinary space, is continuous with the renal tubule.

- The **visceral layer** is composed of podocytes resting on a basal lamina, which is fused with the basal lamina of the capillary endothelium (Figures I-8-4, I-8-5, and I-8-6).
- The **parietal layer** is composed of a simple squamous epithelium that is continuous with the proximal convoluted tubule epithelial lining.

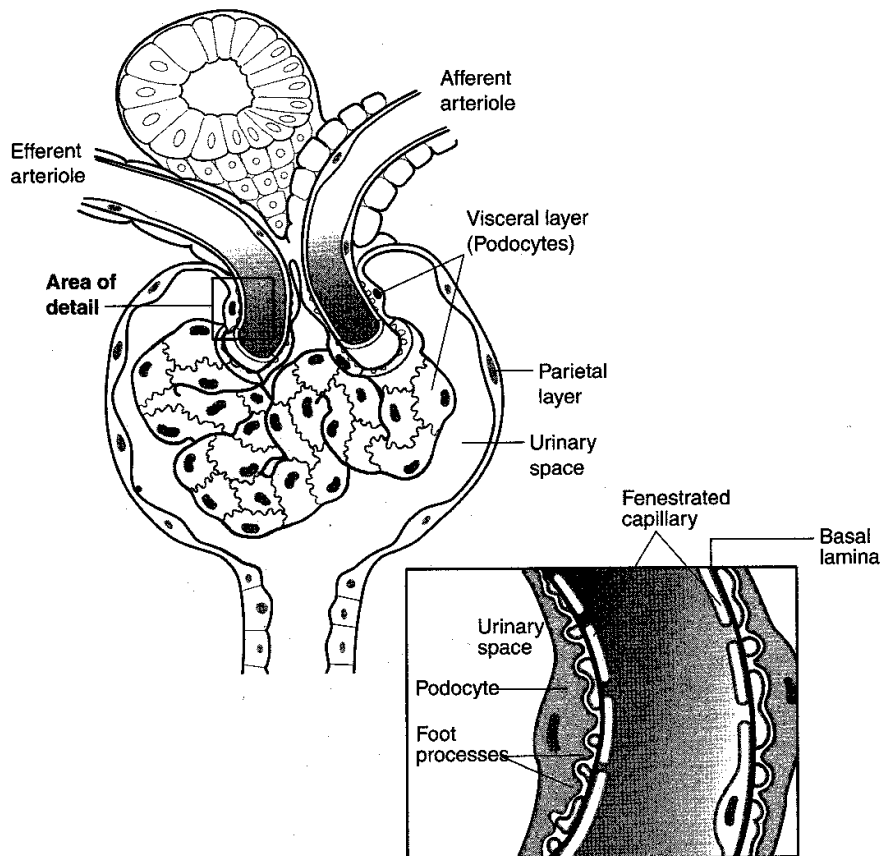
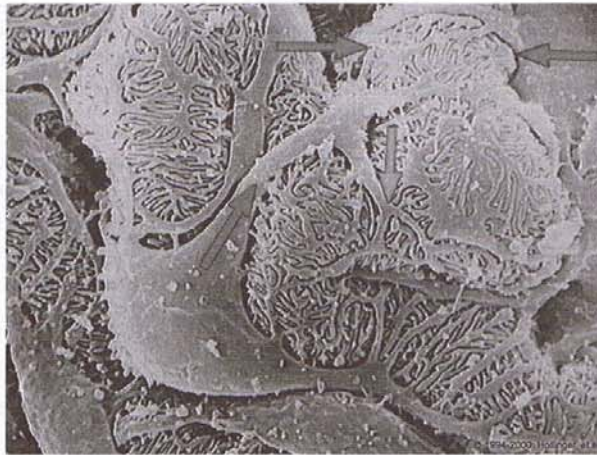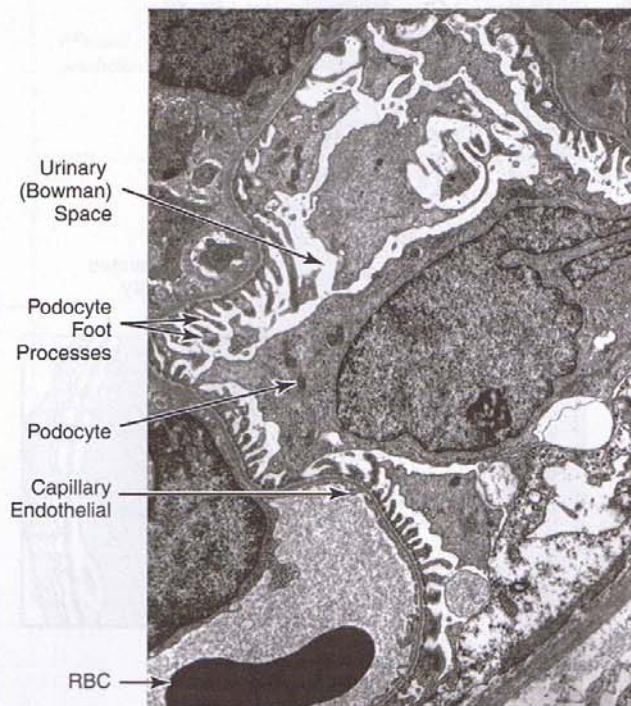


Figure I-8-3. Bowman Capsule Diagram



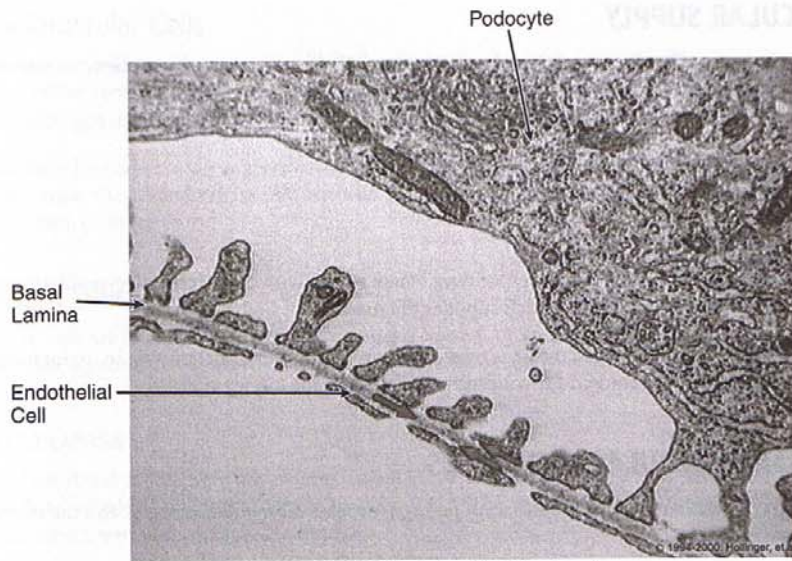
Copyright 2000 Gold Standard Multimedia, Inc. All rights reserved.

Figure I-8-4. Scanning Electron Micrograph Demonstrating Podocytes With Their Processes (arrows)



Copyright 2000 Gold Standard Multimedia, Inc. All rights reserved.

Figure I-8-5. Transmission Electron Micrograph Demonstrating Podocytes



Copyright 2000 Gold Standard Multimedia, Inc. All rights reserved.

Figure I-8-6. Electron Micrograph Demonstrating Relationship Between Basal Lamina, Podocyte, and Endothelial Cell

Proximal convoluted tubule

The proximal convoluted tubule is the longest and most convoluted segment of the nephron. Its cells possess an apical brush border that provides a much greater surface area for reabsorption and secretion. Most of the components of the glomerular filtrate are reabsorbed in the proximal tubule.

Loop of Henle

The loop of Henle is a hairpin loop of the nephron that extends into the medulla and consists of thick and thin segments.

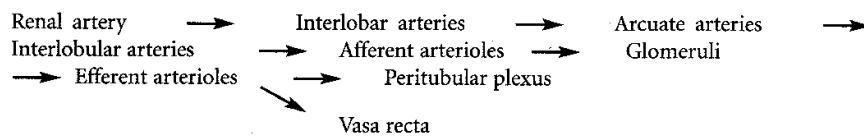
Distal convoluted tubule

The distal convoluted tubule is lined by cuboidal cells that reabsorb sodium and chloride from the tubular filtrate.

Collecting Tubules

Collecting tubules consist of arched and straight segments made up of cells that range from cuboidal to columnar. In response to vasopressin (also known as antidiuretic hormone, or ADH) secreted by the neurohypophysis, collecting tubules become permeable to water and, thus, are important in the kidney's role in water conservation and urine concentration.

VASCULAR SUPPLY



Vasa Recta

The **arteriolae rectae** and the corresponding **venae rectae** with their respective capillary networks comprise the **vasa recta**, which supplies the medulla.

The endothelium of the venae rectae is fenestrated and plays an important role in maintaining the **osmotic gradient** required for concentrating urine in the kidney tubules.

JUXTAGLOMERULAR APPARATUS

The juxtaglomerular apparatus consists of juxtaglomerular cells, polkissen cells, and the macula densa (Figure I-8-7).

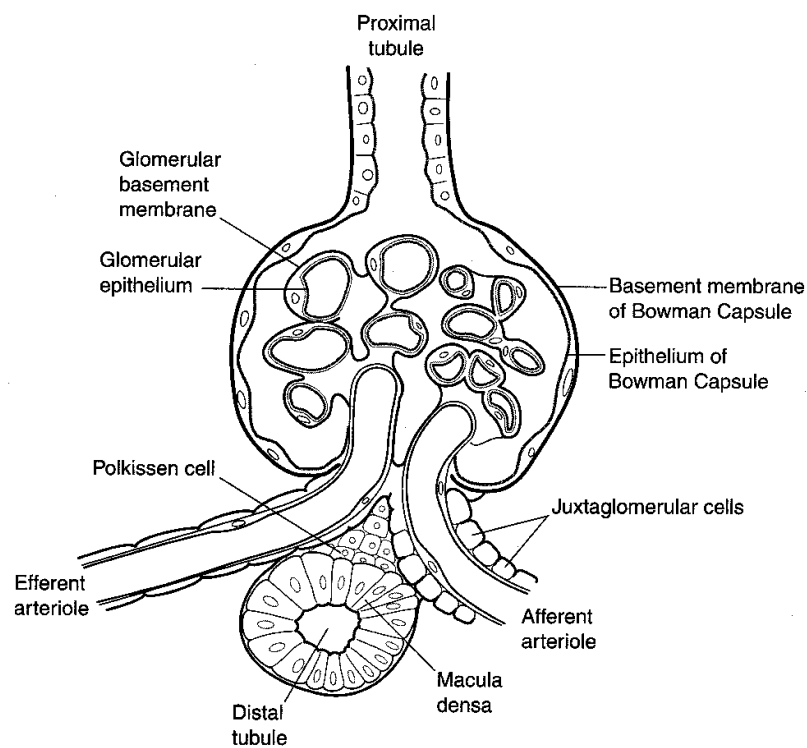


Figure I-8-7. Renal Corpuscle and Juxtaglomerular Apparatus

Juxtaglomerular Cells

The juxtaglomerular cells are myoepithelial cells in the afferent arteriole. They secrete an enzyme called renin, which enters the bloodstream and converts the circulating polypeptide angiotensinogen into angiotensin I.

Angiotensin I is converted to **angiotensin II**, a potent vasoconstrictor that stimulates aldosterone secretion from the adrenal cortex. Aldosterone increases sodium and water reabsorption in the distal portion of the nephron.

Polkissen Cells

Polkissen cells are located between the afferent and efferent arterioles at the vascular pole of the glomerulus, adjacent to the macula densa. Their function is unknown.

Macula Densa

Cells of the distal tubule near the afferent arteriole are taller and more slender than elsewhere in the distal tubule. They constitute the macula densa. The macula densa is thought to sense sodium concentration in the tubular fluid.

Chapter Summary

The **kidney** has three major regions: the hilum, cortex, and medulla. The **hilum** is the point of entrance and exit for the renal vessels and ureter. The upper expanded portion of the ureter is called the **renal pelvis**, and divides into two or three **major calyces** and several **minor calyces**. The **cortex** has several renal columns that penetrate the entire depth of the kidney. The **medulla** forms a series of pyramids that direct the urinary stream into a minor calyx.

The **uriniferous tubule** is composed of the **nephron** and **collecting tubule**. The **nephron** contains the **glomerulus** (a tuft of capillaries interposed between an afferent and efferent arteriole). Plasma filtration occurs here. The **Bowman's capsule** has an inner visceral and outer parietal layer. The space between is the urinary space. The **visceral layer** is composed of podocytes resting on a basal lamina, which is fused with the capillary endothelium. The **parietal layer** is composed of simple squamous epithelium that is continuous with the proximal tubule epithelial lining. The **proximal convoluted tubule** is the longest and most convoluted segment of the nephron. Most of the glomerular filtrate is reabsorbed here. The **loop of Henle** extends into the medulla and has a thick and thin segment. It helps to create an osmotic gradient important for concentration of the tubular filtrate. The **distal convoluted tubule** reabsorbs sodium and chloride from the tubular filtrate. The **collecting tubules** have a range of cells from cuboidal to columnar. Water removal and urine concentration occurs here with the help of the antidiuretic hormone. The blood supply is via renal artery and vein.

The **vasa rectae** supply the medulla. They play an important role in maintaining the **osmotic gradient**. The **juxtaglomerular apparatus (JGA)** is composed of **juxtaglomerular cells**, which are myoepithelial cells in the afferent arteriole. They secrete **renin**. The JGA also contains **Polkissen cells** (function unknown), located between afferent and efferent arterioles, and the **macula densa**. Macula densa cells are located in the wall of the distal tubule, located near the afferent arteriole. They sense sodium concentration in tubular fluid.

Male Reproductive System

9

GENERAL FEATURES

The male reproductive system consists of the primary reproductive organs, the testes, and the secondary organs, including a complex series of genital ducts, the accessory glands, and the penis.

TESTES

The testes are composed of many seminiferous tubules and connective testicular stroma (Figure I-9-1).

Seminiferous Tubules

The seminiferous tubules are the site of spermatogenesis. The epithelium is composed of supporting Sertoli cells and spermatogenic cells.

Sertoli cells

Sertoli cells are irregular columnar cells that extend from the basal lamina to the lumen and provide structural organization to the tubule.

- They synthesize testicular **androgen-binding protein**, which helps to maintain the high androgen levels within the seminiferous tubules. The androgen is necessary for spermatogenesis.
- They provide the **blood-testis barrier**. Tight junctions between adjacent Sertoli cells divide the seminiferous tubules into a basal compartment (containing spermatogonia) and an adluminal compartment (containing spermatocytes and spermatids).

Spermatogenic cells

Spermatogenic cells are the germ cells located between the Sertoli cells. They consist of spermatogonia, primary and secondary spermatocytes, spermatids, and spermatozoa (see Embryology section).

Spermatozoa

There are approximately 60,000 spermatozoa per cubic millimeter of seminal fluid, or 200 to 600 million in a single ejaculation (Figures I-9-2 and I-9-3).

The mature spermatozoa consist of a head and a tail.

- The head of the spermatozoon is pear-shaped, and chromatin is enclosed within the nuclear envelope. Covering the apex of the nucleus is the acrosome.
- The tail of the spermatozoon consists primarily of microtubules for the flagellum and mitochondria for energy.

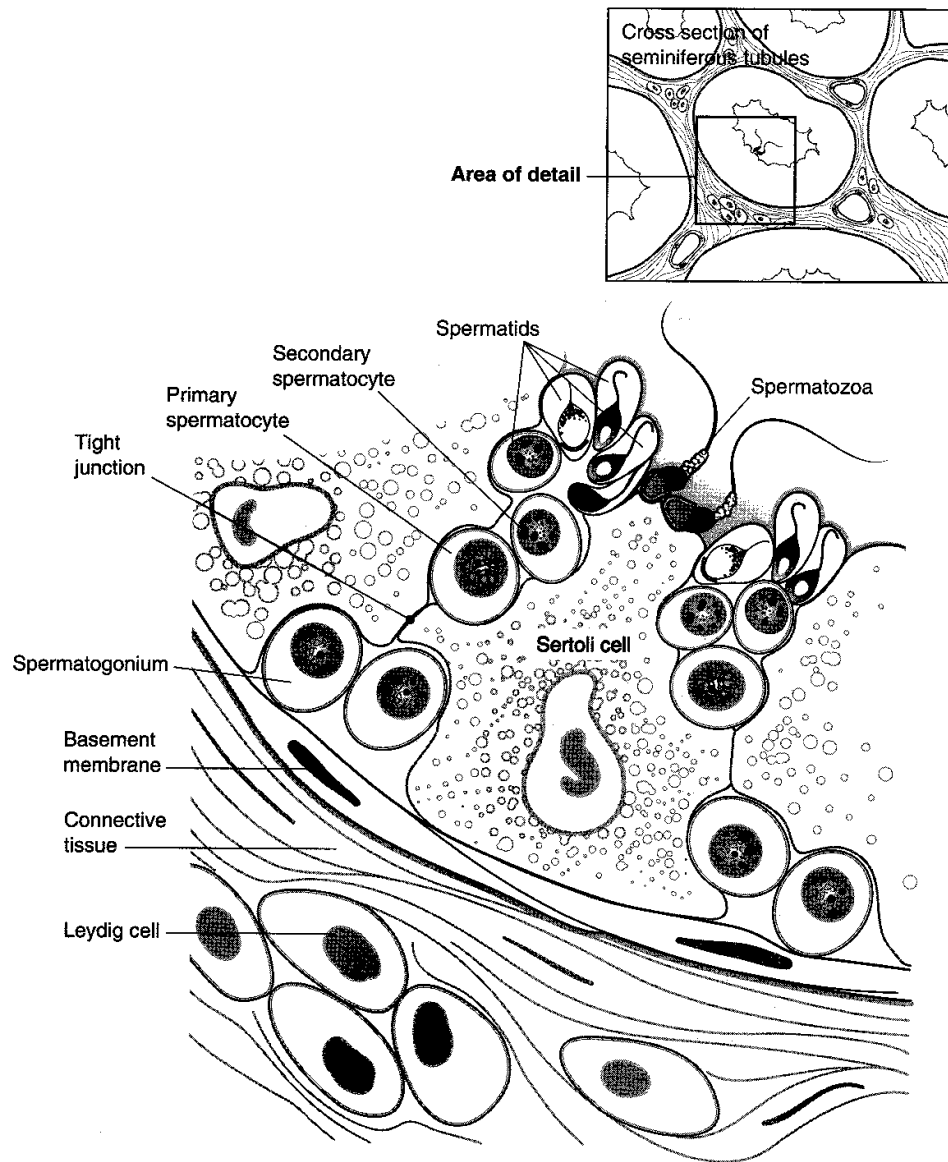


Figure I-9-1. Seminiferous Tubule Diagram

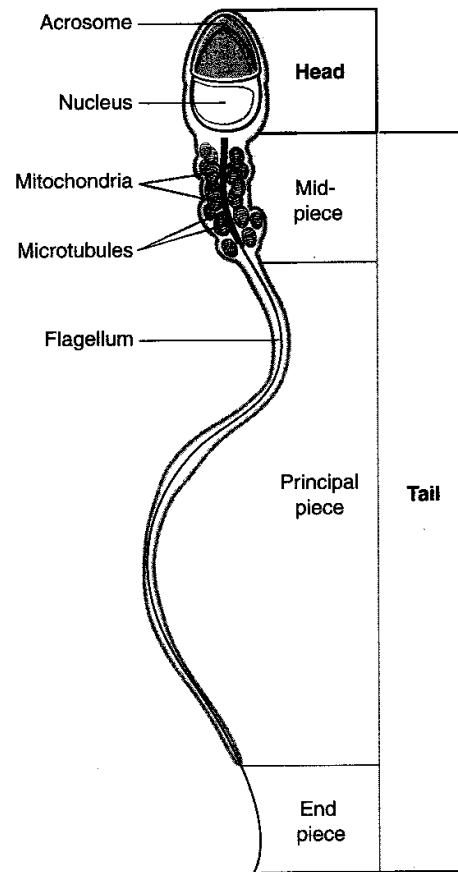
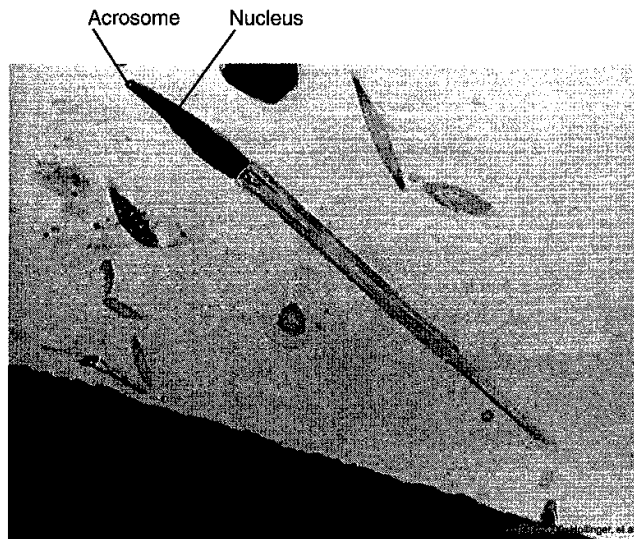


Figure I-9-2. Spermatozoan



Copyright 2000 Gold Standard Multimedia, Inc. All rights reserved.

Figure I-9-3. Electron Micrograph of a Spermatozoan

Interstitial Cells of Leydig

These are located between the seminiferous tubules in the interstitial connective tissue (Figure I-9-1).

- They synthesize and secrete testosterone and 80% of the male estrogen.
- They have abundant SER, mitochondria with tubular cristae, and numerous lipid droplets containing cholesterol esters.
- They depend on the production of luteinizing hormone (LH) by the anterior pituitary gland for activity.

GENITAL DUCTS

- **Tubuli recti**—connect the seminiferous tubules with the rete testis. Continuous production of testicular fluid by Sertoli cells helps to move the gametes out of the seminiferous tubules.
- **Rete testis**—consists of an anastomosing labyrinth of channels within the mediastinum that converge toward the efferent ductules
- **Efferent ductules**—lined by a pseudostratified, ciliated epithelium
- **Ductus epididymis**—a single, elongated tortuous duct that may be 6 m or more in length
It is lined by a pseudostratified epithelium containing stereocilia.
It is here that sperm undergo maturation and develop increased motility and fertilizing capacity.
- **Ductus deferens (vas deferens)**—contains a thick muscular coat, which dilates distally into an ampulla. The ampulla gradually narrows to form the ejaculatory duct, which penetrates the prostate gland and empties into the urethra.

Urethra

- The male urethra extends from the bladder to the end of the penis.
- The prostatic portion is composed of transitional epithelium.
- The penile distal portion is composed of stratified epithelium.

Sperm Storage

Sperm storage occurs in the efferent ductules, epididymis, and proximal ductus deferens.

ACCESSORY GLANDS AND PENIS

Seminal Vesicles

The seminal vesicles secrete a slightly alkaline, viscous fluid into the semen that is rich in fructose and serves as an energy source for the sperm.

They are not a storage organ for sperm.

Prostate Gland

The prostate gland produces a secretion rich in citric acid, lipids, zinc, and acid phosphatase activity.

It often contains concretions composed of protein and carbohydrate.

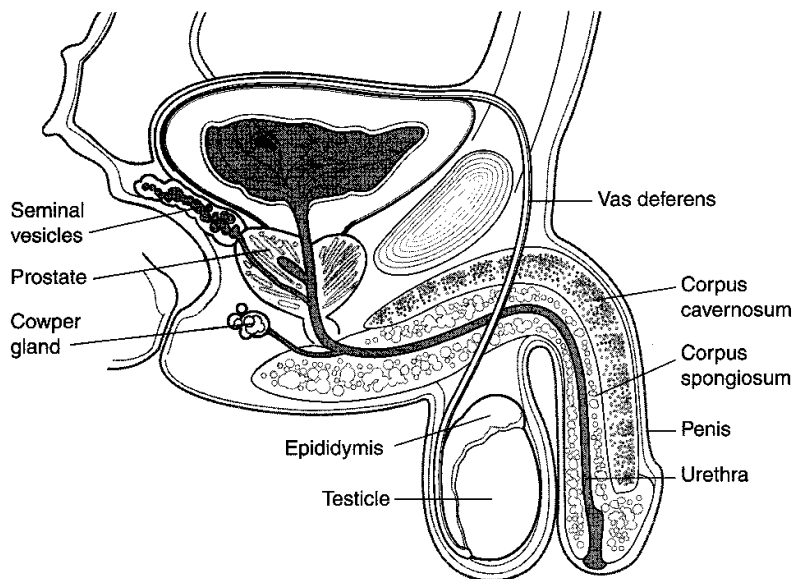


Figure I-9-4. Male Reproductive System

Bulbourethral (Cowper) Gland

The bulbourethral gland secretes a viscous mucous fluid into the urethra for lubrication before ejaculation.

Penis

The penis is composed of three cylindrical bodies of erectile tissue:

- **Corpora cavernosa** contains irregular vascular channels, separated by trabeculae and surrounded by a fibrous capsule called the tunica albuginea. **The trabeculae of erectile tissue** contain branches of the deep artery of the penis, which end in small arteries that open directly into the cavernous spaces.
- The inner surface of the tunica albuginea has a plexus of small veins that drain the cavernous spaces.
- **Corpus spongiosum** exhibits a similar arrangement of erectile tissue.

Chapter Summary

The **testes** contain seminiferous tubules and connective tissue stroma. **Seminiferous tubules** are the site of spermatogenesis. The epithelium contains **Sertoli cells** and spermatogenic cells. **Sertoli cells** synthesize **androgen-binding protein** and provide the **blood–testis barrier**. **Spermatogenic cells** are germ cells located between Sertoli cells. They include spermatogonia, primary and secondary spermatocytes, spermatids, and spermatozoa. **Spermatozoa** number about 60,000 per mm³ of seminal fluid. Each one has a **head**, which contains chromatin. At the apex of the nucleus is the **acrosome**. The tail contains **microtubules**.

Interstitial cells of Leydig are located between the seminiferous tubules in the interstitial connective tissue. They synthesize **testosterone** and are activated by **luteinizing hormone** from the anterior pituitary.

The **genital ducts** are composed of tubuli recti, rete testis, efferent ductules, ductus epididymis, ductus deferens, and ejaculatory ducts. Spermatozoa undergo maturation and increased motility within the ductus epididymis. Spermatozoa are stored in the efferent ductules, epididymis, and proximal ductus deferens.

The **urethra** extends from the urinary bladder to the tip of the penis. The prostatic urethra is composed of transitional epithelium and the distal urethra of stratified epithelium.

Seminal vesicles secrete alkaline, viscous fluid rich in fructose. They do not store spermatozoa.

Secretions from the **prostate gland** are rich in citric acid, lipids, zinc, and acid phosphatase.

Bulbourethral gland secretes mucous fluid into the urethra for lubrication prior to ejaculation.

The **penis** is composed of three cylindrical bodies of erectile tissue: **corpora cavernosa**, **corpus spongiosum**, and **trabeculae of erectile tissue**. The corpora cavernosa is surrounded by the **tunica albuginea**.

Female Reproductive System

10

GENERAL FEATURES

The female reproductive system consists of the ovaries, fallopian tubes (oviducts, uterine tubes), uterus and cervix, vagina, external genitalia, and mammary glands.

OVARIES

The ovaries are divided into two regions:

- The **cortex**—contains ovarian follicles and cellular connective tissue
- The **medulla**, or **zona vasculosa**—the central deeper layer contains many large blood vessels and nerves.

Ovarian Follicles and Follicular Development

Follicles (Figure I-10-1) are located in the cortical stroma and are composed of oocytes surrounded by follicular (granulosa) cells.

- Approximately 400,000 follicles are present in the newborn ovaries. Only a small percentage of the oocytes (approximately 450) reach maturity in the adult.
- The remaining follicles eventually degenerate through a process called **atresia**. Atresia may occur at any stage of follicular development.

Primordial follicles

The primary oocyte surrounded by a single layer of flattened granulosa cells.

Primary follicles

The primary oocyte and one or more layers of cuboidal-like granulosa cells.

Secondary follicles

The follicular cavity (antrum), **cumulus oophorus**, and **corona radiata** develops from the primary follicle, with the connective tissue surrounding the follicle developing into the theca interna and externa.

The **theca interna** produces androgens, which are converted into estradiol by granulosa cells.

The **zona pellucida** forms around the oocyte; it is rich in polysaccharides (periodic acid-Schiff [PAS]-positive).

Graafian follicle

The graafian follicle is the mature follicle that extends through the entire cortex.

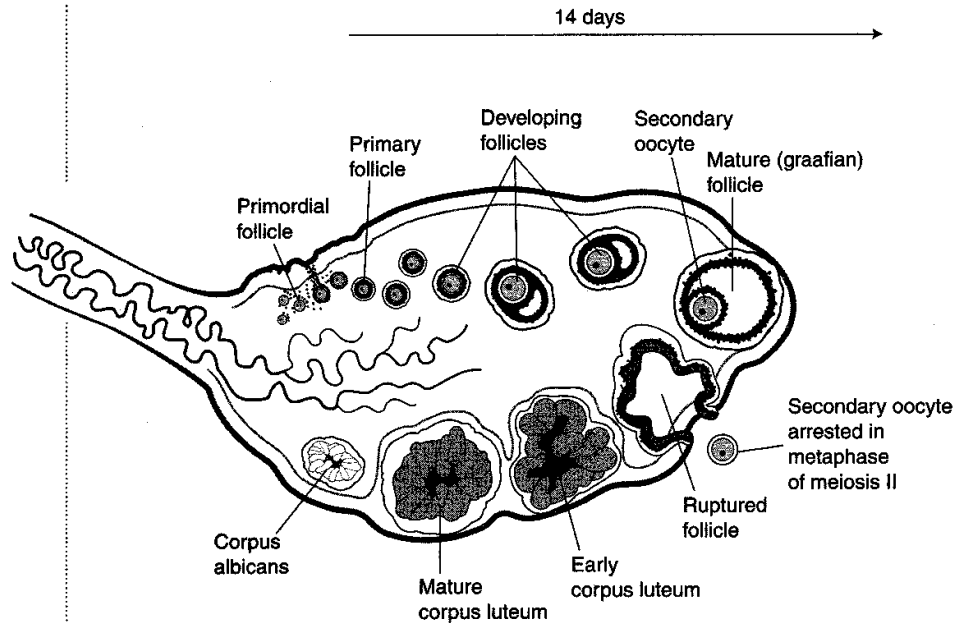


Figure I-10-1. Follicular Development

Ovulation

An increase of **antral fluid** causes an increase in pressure on the wall of the follicle and on the thin layer of ovarian tissue at the surface of the ovary. The follicle eventually ruptures, and the ovum, along with its corona radiata, passes out of the ovary.

The ovum must be fertilized within 24 hours or it degenerates.

Corpus Luteum

Follicular changes after ovulation lead to the formation of **the corpus luteum**.

- Theca interna cells enlarge and become theca lutein cells—secrete estrogen.
- Follicular (granulosa) cells enlarge and become granulosa lutein cells—secrete progesterone.
- If the ovum is not fertilized, the corpus luteum reaches its maximal development approximately 7 days after ovulation and then begins to degenerate.
- If the **ovum is fertilized**, the corpus luteum increases in size for approximately 3 months.
- The corpus luteum persists until the 12th week before degenerating and is maintained by human chorionic gonadotropin (hCG) secreted by the developing embryo. After the 40th day of pregnancy, the placenta produces the progesterone necessary to maintain pregnancy.

FALLOPIAN TUBES

The fallopian tubes are approximately 12 cm long, richly vascularized, and lined by a **ciliated mucosa** (cilia beat toward the uterus).

Regions of the Fallopian Tube

Infundibulum

The infundibulum is open to the peritoneal cavity with branched processes called fimbriae. It is covered with ciliated cells that beat toward the mouth of the tube.

Before ovulation, estrogens induce engorgement of blood vessels in the **fimbriae**, which expands the fallopian tube toward the surface of the ovary. Estrogens similarly induce growth and activity of the cilia as well as enhancement of the peristaltic contractions of the fallopian tube.

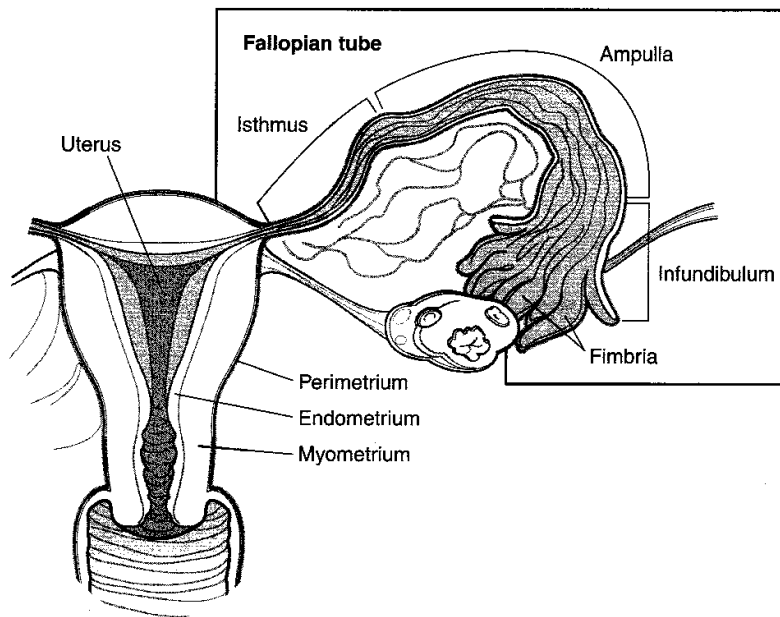


Figure I-10-2. Female Reproductive System

Ampulla

The ampulla is the thin-walled, longest region of the oviduct.

- **Fertilization** usually occurs in the ampulla.
- This is also the most frequent location of ectopic pregnancy.

Isthmus

The isthmus is a narrow, thick-walled segment nearest to the uterine wall.

Uterine (interstitial) segment

The uterine segment is the portion of the tube that traverses the uterine wall.

UTERUS

Uterine Wall

The uterine wall has three coats.

Endometrium

The endometrium is composed of simple columnar epithelium (ciliated and nonciliated cells), with two layers:

- The deeper **basal layer** is relatively thin and is not discharged during menstruation.
- The superficial **functional layer** alters during the menstrual cycle and is lost at menstruation.

Myometrium

The myometrium is composed of smooth muscle, connective tissue, and prominent blood vessels.

Perimetrium

The perimetrium consists of the peritoneal layer of the broad ligament.

Cyclic Endometrial Changes During the Menstrual Cycle

The average menstrual cycle lasts 28 days (Figure I-10-3).

Menstrual stage

The first 3 to 5 days of the cycle are characterized by menstrual flow.

Proliferative (estrogenic) stage

- Begins during the later stages of menstrual flow and continues through the 13th or 14th day
- Is marked by regrowth of the endometrium, including epithelial cell proliferation and growth of the spiral arteries

Secretory phase

- Continues the hypertrophy of the endometrium (no mitosis)
- There is increased vascularity and increased edema.

Premenstrual phase

- Consists mostly of changes in the spiral arteries that lead to the breakdown of the functional layer.
- Constriction of the spiral arteries leads to anoxia and ischemia.

Uterine Changes in Relation to the Ovary

Cyclic changes of the uterus are closely associated with cyclic changes of the ovary (Figure I-10-3).

Onset of menstruation

The onset of menstruation corresponds to the involution of the corpus luteum.

Proliferative phase

The proliferative phase is estrogen dependent. It corresponds to the preovulatory period of follicular maturation. Ovulation normally occurs at the end of the proliferative phase, 14 days before menstruation begins—usually between the 10th and 14th day.

Secretory phase

The secretory phase is progesterone-dependent and associated with the luteal phase of the ovary.

No fertilization

- The corpus luteum degenerates 12 days after ovulation.
- A drop in progesterone and estrogen levels ensues.
- The functional layer degenerates and menstrual flow commences.

Fertilization

Uterine changes in relation to fertilization (see Weeks 1 and 2 in Embryology section).

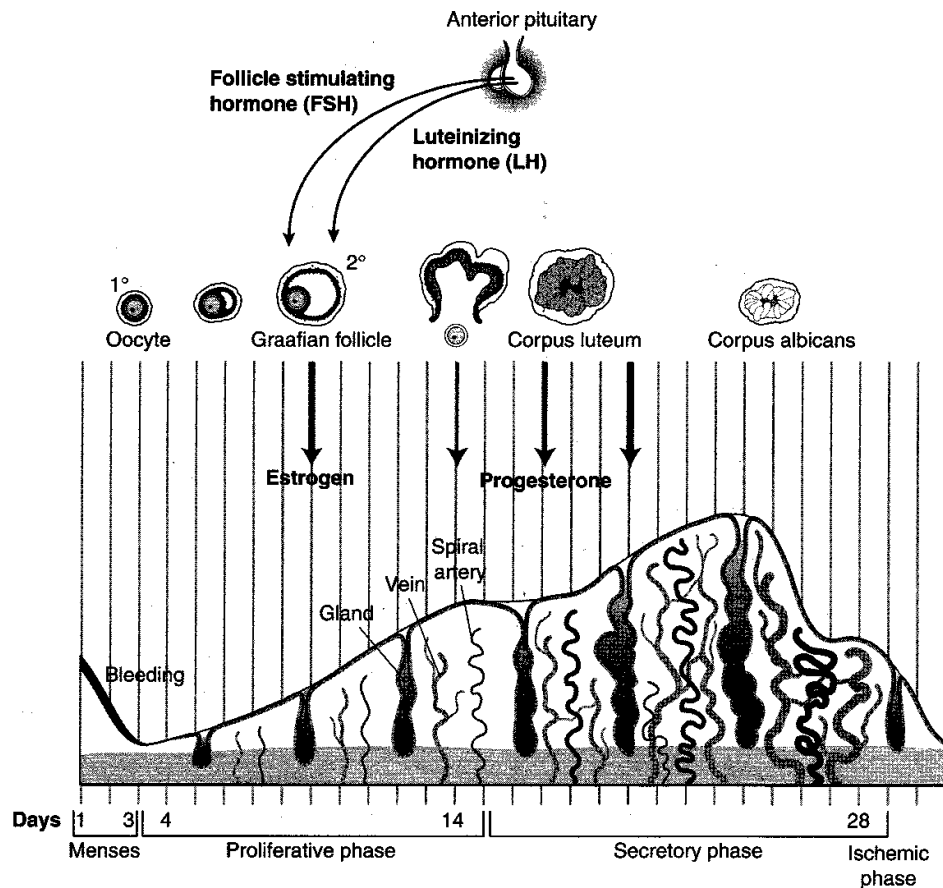


Figure I-10-3. Menstrual Cycle

PLACENTA

The placenta permits exchange of nutrients and waste products between the maternal and fetal circulations (Figure I-10-4).

Fetal Component

The fetal component consists of the chorionic plate and villi. It lies adjacent to the spaces near the endometrial decidua through which the maternal blood circulates.

The Maternal Component

The maternal component is composed of the **decidua basalis**.

Maternal blood vessels from the decidua conduct blood into the intervillous spaces of the placenta, where floating villi are present.

Placental barrier

Maternal blood is separated from fetal blood by cytotrophoblast, syncytiotrophoblast, a basement membrane, and fetal capillary endothelium.

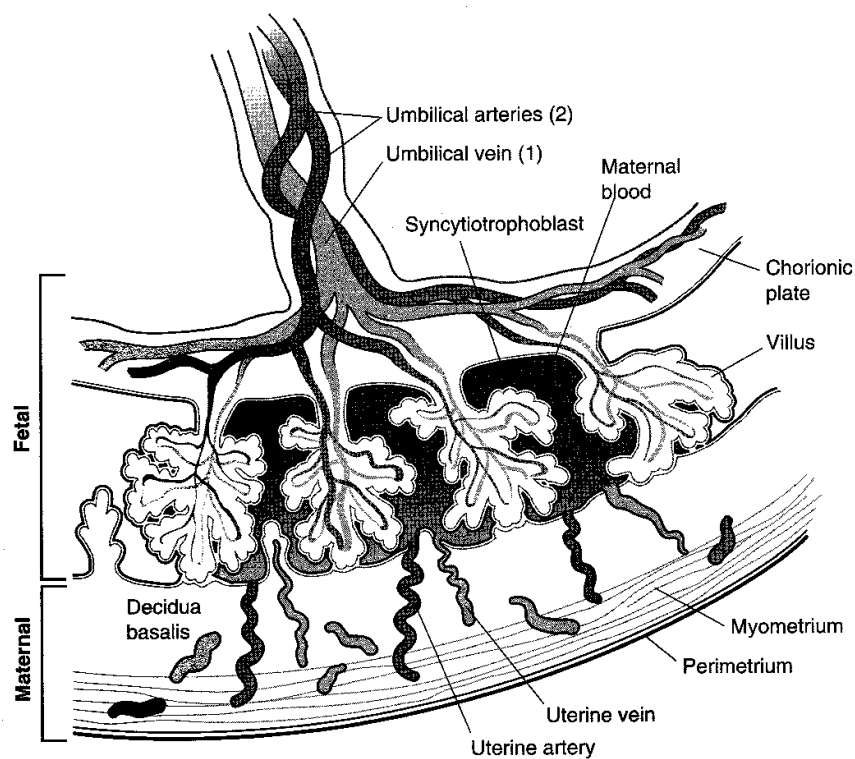


Figure I-10-4. Placenta

VAGINA

- The vagina extends from the vestibule of the external genitalia to the cervix.
- It contains no glands. The mucus lubricating it originates from the glands of the cervix and the vestibular glands.
- It is lined by a stratified squamous epithelium that is rich in glycogen.

Vaginal Changes Caused by Changes in Estrogen Levels

Estrogenic phase

During the estrogenic phase vaginal fluid has a lower pH than during the rest of the cycle, resulting from the formation of lactic acid by bacteria metabolizing glycogen.

Postestrogenic phase

The drop in estrogen levels induces a decrease in glycogen levels, which in turn causes an increase in vaginal pH and, thus, an increase in the likelihood of infection.

MAMMARY GLANDS AND EXTERNAL GENITALIA

See Gross Anatomy and Embryology sections.

Chapter Summary

The female reproductive system is composed of ovaries, fallopian tubes, the uterus, cervix, vagina, external genitalia, and mammary glands. The **ovaries** have two regions, the **cortex** and **medulla**. The former contain **follicles** and the latter vascular and neural elements. There are approximately 400,000 follicles at birth, of which approximately 450 reach maturity in the adult. The remaining follicles undergo atresia.

Maturation involves the formation of the primary, secondary, and finally, the **graafian follicle**. During ovulation, a rise in antral fluid causes the follicle to rupture. The ovum will degenerate in 24 hours unless fertilized by the spermatozoan. Following ovulation, the **follicle changes** in the following manner: **theca interna cells** become theca lutein cells and secrete **estrogen**, while follicular cells become **granulosa lutein cells** producing **progesterone**. If the ovum is fertilized, the **corpus luteum** persists for three months, producing progesterone. Its survival is dependent upon **human chorionic gonadotropin** secreted by the developing embryo. Thereafter, the placenta produces progesterone, required to maintain pregnancy.

The **fallopian tube** is divided into the infundibulum, ampulla, isthmus, and interstitial segment. Fallopian tubes are lined by a mucosa containing cilia that beat toward the uterus, except in the infundibulum, where they beat toward the fimbria. Fertilization occurs in the ampulla, which is also the most frequent site of ectopic pregnancies.

The **uterus** has three coats in its wall: the endometrium, myometrium, and perimetrium. The **endometrium** is a basal layer and superficial functional layer. The latter is shed during menstruation. The **myometrium** is composed of smooth muscle, and the **perimetrium** consists of the peritoneal layer of the broad ligament. The **menstrual cycle** results in cyclical endometrial changes. The first 3–5 days are characterized by menstrual flow. Thereafter, the **proliferative stage** commences. During this time, lasting 14 days, the endometrium regrows. This phase is estrogen-dependent. During the **secretory phase**, the endometrium continues to hypertrophy, and there is increased vascularity. This phase is progesterone dependent. The **premenstrual phase** is marked by constriction of spiral arteries leading to breakdown of the functional layer. Failure of fertilization leads to a drop in progesterone and estrogen levels, and degeneration of the corpus luteum about two weeks after ovulation.

The **placenta** permits exchange of nutrients and removal of waste products between maternal and fetal circulations. The fetal component consists of the **chorionic plate** and **villi**. The maternal component is **decidua basalis**. Maternal blood is separated from fetal blood by the cytotrophoblast and syncytiotrophoblast.

The **vagina** contains no glands. It is lined by stratified, squamous epithelium, rich in glycogen. During the **estrogenic phase** its pH is acidic. During the **postestrogenic phase**, the pH is alkaline, and vaginal infections could occur.

HISTOLOGY AND CYTOLOGY

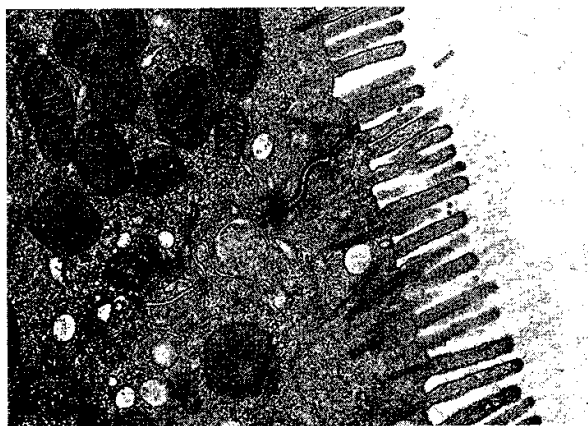
Review Questions

1. Which of the following functions in metabolic coupling between adjacent cells?
 - (A) Tight junction
 - (B) Desmosome
 - (C) Gap junction
 - (D) Zonula adherens
 - (E) Hemidesmosome
2. Which cell presents antigen to immature B lymphocytes in the ileum?
 - (A) Ito cells
 - (B) Kupffer cells
 - (C) Paneth cells
 - (D) Clara cells
 - (E) Microfold cells
3. Your patient has a deficiency in the ATPase motor protein dynein. Which of the following would most likely be seen in the patient?
 - (A) Anemia due to destruction of multiple mis-shaped RBCs by the spleen
 - (B) Dizziness and sensorineural hearing deficits
 - (C) Decreased absorption of nutrients by duodenal columnar epithelial cells
 - (D) Immotile sperm
 - (E) An increase in glial fibrillary acidic protein in astrocytes
4. Defects in the production of kinesin might result in
 - (A) vertigo
 - (B) inability of axons to transport substances in the anterograde direction
 - (C) respiratory distress
 - (D) inability of axon terminals to take up calcium
 - (E) reduced fertility
5. Which of the following is *not* a function associated with smooth endoplasmic reticulum?
 - (A) Production of testosterone by Leydig cells
 - (B) Drug detoxification by hepatocytes
 - (C) Sequestering of calcium in skeletal muscle
 - (D) Production of intramembrane proteins
 - (E) Production of glucocorticoids by the zona fasciculata of the adrenal cortex

6. A patient has a smaller than normal number of Clara cells. What will be seen in this patient?
 - (A) Respiratory infections
 - (B) Hyaline membrane disease
 - (C) Reduced ability to trap airborne toxins
 - (D) Reduced ability to produce surfactant
 - (E) Reduced ability to generate new Type I pneumocytes
7. Your male patient has a deficiency in the spectrin peripheral protein. Which of the following would most likely be seen in this patient?
 - (A) Tinnitus and vertigo
 - (B) Low sperm count
 - (C) Spherocytosis
 - (D) Situs inversus
 - (E) Atherosclerosis
8. What is the site of initial *N*-glycosylation of proteins?
 - (A) Golgi apparatus
 - (B) Nucleolus
 - (C) Rough endoplasmic reticulum
 - (D) Lysosomes
 - (E) Clathrin-coated vesicles
9. Lysosomal enzymes are produced in the
 - (A) Golgi apparatus
 - (B) rough endoplasmic reticulum
 - (C) peroxisomes
 - (D) smooth endoplasmic reticulum
 - (E) nucleolus
10. A young male has been diagnosed with a rhabdomyosarcoma in the cremaster muscle. The tumor, along with the testis and associated blood and lymph vessels, are removed. An increase in what intermediate filament serves as an indicator that confirms the type of tumor present?
 - (A) Vimentin
 - (B) Lamins
 - (C) Cytokeratin
 - (D) Desmin
 - (E) Tonofilament
11. Which glycoprotein functions to bind cells at a hemidesmosome to an underlying basal lamina?
 - (A) Entactin
 - (B) Heparin sulfate
 - (C) Fibronectin
 - (D) Integrin
 - (E) Tenascin

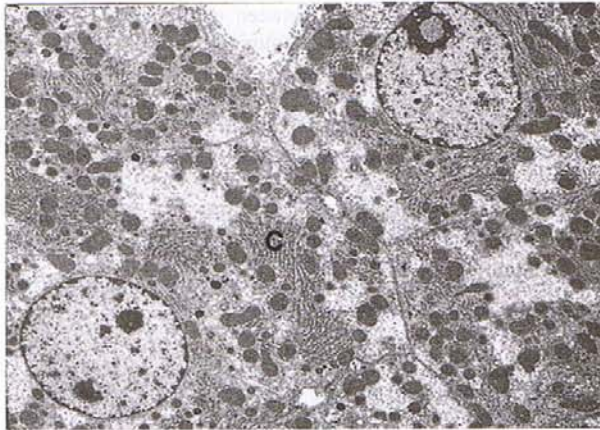
12. During contraction of skeletal muscle, which of the following does not change in length?
 - (A) Sarcomere
 - (B) A band
 - (C) I band
 - (D) Myofibril
 - (E) H band
13. Which component of an intercalated disc provides an attachment site for actin filaments in cardiac muscle?
 - (A) Sarcoplasmic reticulum
 - (B) Zonula occludens
 - (C) Fascia adherens
 - (D) Gap junction
 - (E) Tight junction
14. In the peripheral nervous system, which of the following helps promote regeneration of severed axons?
 - (A) Endoneurium
 - (B) Schmidt-Lanterman cleft
 - (C) Epineurium
 - (D) Node of Ranvier
 - (E) Perineurium
15. What is the first site of hematopoiesis in utero?
 - (A) Liver
 - (B) Spleen
 - (C) Bone marrow
 - (D) Yolk sac
 - (E) Plasma
16. Which of the following cells are found in the neurohypophysis?
 - (A) Paraventricular cells
 - (B) Thyrotrophs
 - (C) Gonadotrophs
 - (D) Pituicytes
 - (E) Chromaffin cells
17. Your patient displays large patches of skin lacking pigmentation. You interpret these observations to be characteristic of a patient with
 - (A) Albinism
 - (B) Dysplastic nevi
 - (C) Psoriasis
 - (D) Vitiligo
 - (E) Melanoma

18. Which hormone increases bicarbonate release into the lumen of the gastrointestinal tract?
- (A) Neurotensin
 - (B) Somatostatin
 - (C) Secretin
 - (D) Cholecystikinin
 - (E) Gastrin
19. In the GI tract, where are the cells that secrete antibacterial enzymes?
- (A) In Peyer patches
 - (B) On intestinal villi
 - (C) In crypts of Lieberkuhn
 - (D) In the lamina propria
 - (E) In rugae
20. In the kidney, which cells produce erythropoietin?
- (A) Mesangial cells
 - (B) Juxtaglomerular cells
 - (C) Podocytes
 - (D) Macula densa cells
 - (E) Henle loop cells
21. The electron micrograph below illustrates part of a cell that is most likely found in the



- (A) trachea
- (B) liver
- (C) duodenum
- (D) inner ear
- (E) lung

22. In the electron micrograph below, the structure at "C"



- (A) synthesizes steroid hormones
- (B) packages proteins bound for export
- (C) contains enzymes used in the electron transport chain
- (D) synthesizes albumin to be secreted to the space of Disse
- (E) stores vitamin A

Answers and Explanations

1. **Answer: C.** Gap junctions permit cell-to-cell communication by allowing movement of small molecules and ions through connexin channels.
2. **Answer: E.** Microfold cells (M cells) present antigen to Peyer patches in the ileum.
3. **Answer: D.** Dynein deficiency results in immotile cilia syndrome characterized by respiratory infections and sterility.
4. **Answer: B.** Kinesin is the ATPase motor protein used in anterograde axonal transport.
5. **Answer: D.** Membrane proteins are produced by rough endoplasmic reticulum.
6. **Answer: C.** Clara cells trap airborne toxins and produce cytochrome P-450.
7. **Answer: C.** Spectrin is the peripheral protein that is defective in red blood cells, resulting in anemia due to excessive destruction of mis-shaped RBCs by the spleen.
8. **Answer: C.** The addition of sugars to proteins begins in the RER and is completed in the Golgi apparatus.
9. **Answer: B.** RER produces nonsynthetic proteins bound for export, enzymes destined for incorporation into lysosomes, and membrane proteins.

10. **Answer: D.** Desmin is an intermediate filament found in skeletal, cardiac, and nonvascular smooth muscle.
11. **Answer: D.** Integrin allows interaction between epithelial cells and the extracellular matrix by anchoring the cell surface to the laminin glycoproteins in the underlying basal lamina.
12. **Answer: B.** The A band, which contains thick filaments of myosin, does not change its length during sarcomere shortening.
13. **Answer: C.** A fascia adherens is a form of a desmosome that provides a site of attachment site for actin intermediate filaments.
14. **Answer: A.** The endoneurium is produced mainly by Schwann cells and forms a sleeve for regenerating axons.
15. **Answer: D.** Blood formation begins in the yolk sac and proceeds in succession in the liver, spleen, and then bone marrow.
16. **Answer: D.** Only pituicytes, a form of glial cell, are found in the neurohypophysis, along with axons of supraoptic and paraventricular neurons, which are found in the hypothalamus.
17. **Answer: D.** Patients with vitiligo lack melanocytes in regions of the epidermis that are most noticeable in individuals who have dark pigmentation.
18. **Answer: C.** Secretin acts on the exocrine pancreas to increase secretion of bicarbonate into the duodenum.
19. **Answer: C.** Paneth cells, which produce lysozyme that regulates bacterial flora of the intestine, are found at the bases of crypts of Lieberkuhn.
20. **Answer: A.** Mesangial cells produce erythropoietin, which induces RBC formation.
21. **Answer: C.** The cell is an absorptive columnar epithelial cell in the epithelial lining, characteristic of the small intestine. These cells are capped by numerous microvilli and a glycocalyx.
22. **Answer: D.** The rough endoplasmic reticulum produces proteins bound for export.

SECTION II

Early Embryology

Gonad Development

1

PRIMORDIAL GERM CELLS

Primordial germ cells arise in the wall of the yolk sac.

INDIFFERENT GONAD

At week 4, primordial germ cells migrate into the indifferent gonad, which forms in a longitudinal elevation of **intermediate mesoderm** called the **urogenital ridge**.

TESTES AND OVARY

The indifferent gonad will develop into either the testes or ovary (Figure II-1-1).

Testes

Development of the testes is directed by:

- The **Sry gene** on the short arm of the Y chromosome, which encodes for **testes-determining factor (TDF)**.
- **Testosterone**, which is secreted by the Leydig cells.
- **Müllerian-inhibiting factor (MIF)**, which is secreted by the Sertoli cells.

Ovary

No factors are involved.

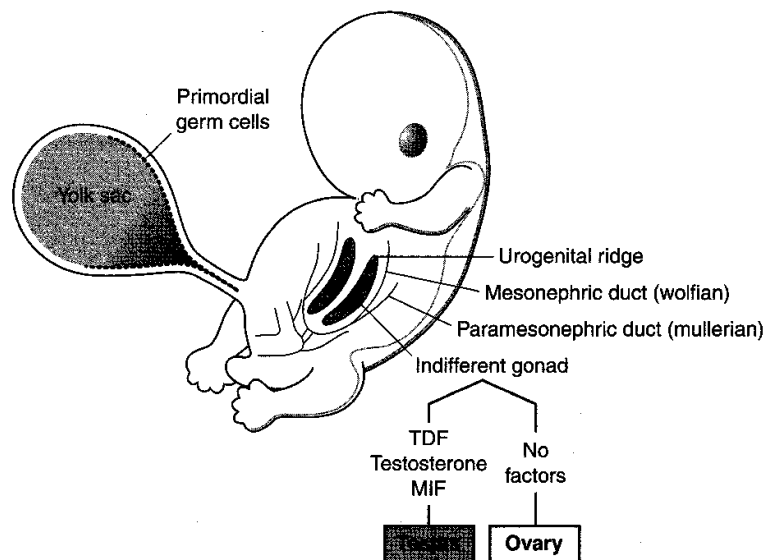


Figure II-1-1. Development Within Testes and Ovary

Meiosis

Meiosis occurs within the testes and ovary. This is a specialized process of cell division that produces the male gamete (**spermatogenesis**) and female gamete (**oogenesis**). There are notable differences between spermatogenesis and oogenesis, discussed below.

Meiosis consists of two cell divisions, meiosis I and meiosis II (Figure II-1-2).

Meiosis I

In meiosis I, the following events occur:

Synapsis—the pairing of 46 homologous chromosomes

Crossing over—the exchange of segments of DNA

Disjunction—the separation of 46 homologous chromosomes **without** centromere splitting

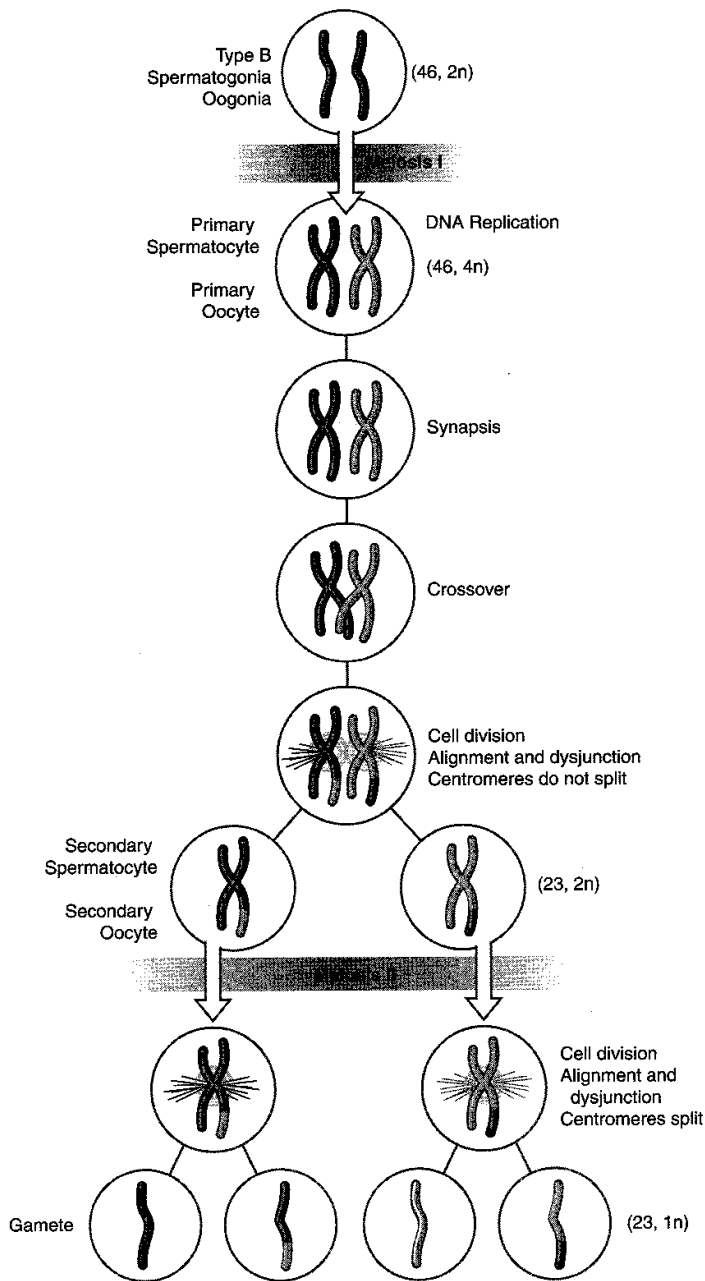


Figure II-1-2. Meiosis

Meiosis II

In meiosis II:

- Synapsis does not occur.
- Crossing over does not occur.
- Disjunction occurs **with** centromere splitting.

Spermatogenesis

Primordial germ cells arrive in the indifferent gonad at week 4 and remain **dormant until puberty**.

When a boy reaches puberty, primordial germ cells differentiate into **type A spermatogonia**, which serve as stem cells throughout adult life.

Some type A spermatogonia differentiate into **type B spermatogonia**.

Type B spermatogonia enter meiosis I to form **primary spermatocytes**.

Primary spermatocytes form two **secondary spermatocytes**.

Secondary spermatocytes form two **spermatids**.

Spermatids undergo **spermiogenesis**, which is a series of morphological changes resulting in the mature **sperm**.

Oogenesis

Primordial germ cells arrive in the indifferent gonad at week 4 and differentiate into oogonia.

Oogonia enter meiosis I to form **primary oocytes**. All primary oocytes are formed by **month 5 of fetal life** and remain **arrested in prophase (diplotene) of meiosis I** until puberty.

No oogonia are present at birth.

When a girl reaches puberty, a primary oocyte completes meiosis I to form a secondary oocyte and polar body.

The secondary oocyte becomes **arrested in metaphase of meiosis II** and is ovulated.

At fertilization within the uterine tube, the secondary oocyte completes meiosis II to form a **mature oocyte** and **polar body**.

Chapter Summary

The indifferent gonad begins development in a column of intermediate mesoderm called the urogenital ridge during week 4. Primordial germ cells arise in the wall of the yolk sac and migrate to the indifferent gonad. In the male, a testis develops from the indifferent gonad due to the presence of testis-determining factor (TDF), which is produced on the short arm of the Y chromosome. Testosterone secreted by the Leydig cells and müllerian-inhibiting factor (MIF) secreted by the Sertoli cells also contribute to the development of the testis. In the female, an ovary develops in the absence of any factors.

Meiosis is a specialized type of cell division that produces the male and female gametes during spermatogenesis and oogenesis, respectively. Meiosis consists of two cell divisions: meiosis I and meiosis II. In meiosis I, the events include synapsis, exchange of DNA, and dysjunction, resulting in a reduction from 46 to 23 chromosomes. In meiosis II, there is a reduction of DNA from $2n$ to $1n$.

Oogenesis begins in the female during the early weeks of development and by month 5 of fetal life all of the primary oocytes are formed and become arrested in prophase of meiosis I until puberty. After puberty, during each monthly menstrual cycle a secondary oocyte develops in the graafian follicle and is then arrested a second time in metaphase of meiosis II, which is then ovulated. Meiosis II is only completed if there is fertilization. In the male, spermatogenesis begins after puberty in the seminiferous tubules and moves through meiosis I and II without any arrested phases to produce spermatids. Spermatids undergo spermiogenesis to develop into the adult spermatozoa.

Week 1: Beginning of Development

2

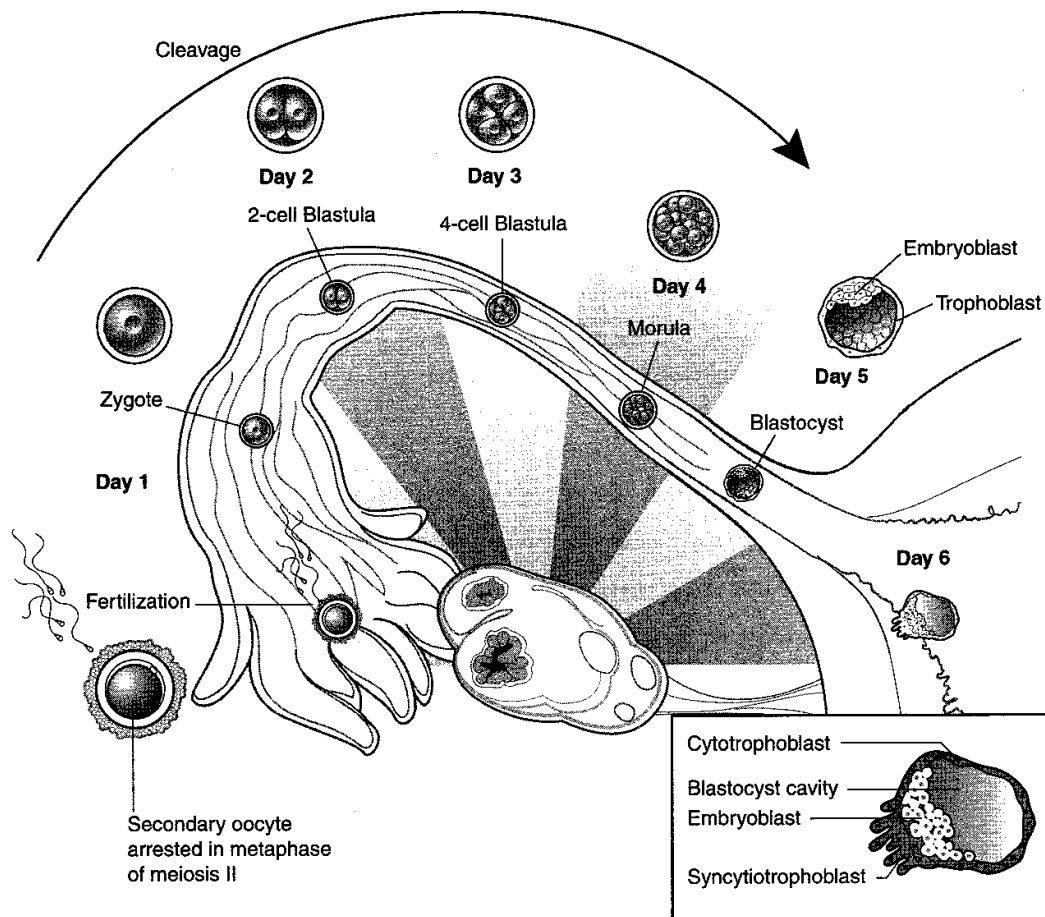


Figure II-2-1. Week 1

Clinical Correlate

Ectopic Tubal Pregnancy

This is the most common form of ectopic pregnancy. It most usually occurs when the blastocyst implants within the **ampulla of the uterine tube because of delayed transport**. Risk factors include endometriosis, pelvic inflammatory disease (PID), tubal pelvic surgery, or exposure to diethylstilbestrol (DES). Clinical signs include abnormal or brisk uterine bleeding, sudden onset of abdominal pain that may be confused with appendicitis, last menses 60 days ago, positive human chorionic gonadotropin (hCG) test, and culdocentesis showing intraperitoneal blood.

Ectopic Abdominal Pregnancy

Ectopic abdominal pregnancy most commonly occurs in the **rectouterine pouch (pouch of Douglas)**.

ZYGOTE FORMATION

Fertilization occurs in the ampulla of the uterine tube. The male and female pronuclei fuse to form a zygote.

CLEAVAGE

Cleavage is a series of **mitotic** divisions of the zygote. Total cytoplasmic volume remains constant.

Blastula

Zygote cytoplasm is successively cleaved to form a blastula consisting of increasingly smaller **blastomeres** (2-cell, 4-cell, 8-cell stage, etc.).

Morula

At the 32-cell stage, the blastomeres form a morula consisting of an **inner cell mass** and an **outer cell mass**.

BLASTOCYST

Blastocyst formation occurs when fluid secreted within the morula forms the **blastocyst cavity**:

The inner cell mass is now known as the **embryoblast** (becomes the embryo/fetus).

The outer cell mass is now known as the **trophoblast** (becomes part of the placenta).

IMPLANTATION

The **zona pellucida** must degenerate for implantation to occur.

The blastocyst usually implants within the **posterior wall of the uterus**.

The embryonic pole of blastocyst implants first.

The blastocyst implants within the **functional layer** of the endometrium during the **progestational phase** of the menstrual cycle.

The trophoblast differentiates into the **cytotrophoblast** and **syncytiotrophoblast**.

Chapter Summary

Fertilization occurs in the ampulla of the uterine tube with the fusion of the male and female pronuclei to form a zygote. During the first 4–5 days of the first week, the zygote undergoes rapid mitotic division (cleavage) in the oviduct to form a morula before entering the cavity of the uterus. A blastocyst forms as fluid develops in the morula, resulting in a blastocyst that consists of an inner cell mass known as the embryoblast (becomes the embryo) and the outer cell mass known as the trophoblast (becomes the placenta). At the end of the first week, the trophoblast differentiates into the cytotrophoblast and syncytiotrophoblast and then implantation begins.

Week 2: Formation of the Bilaminar Embryo

3

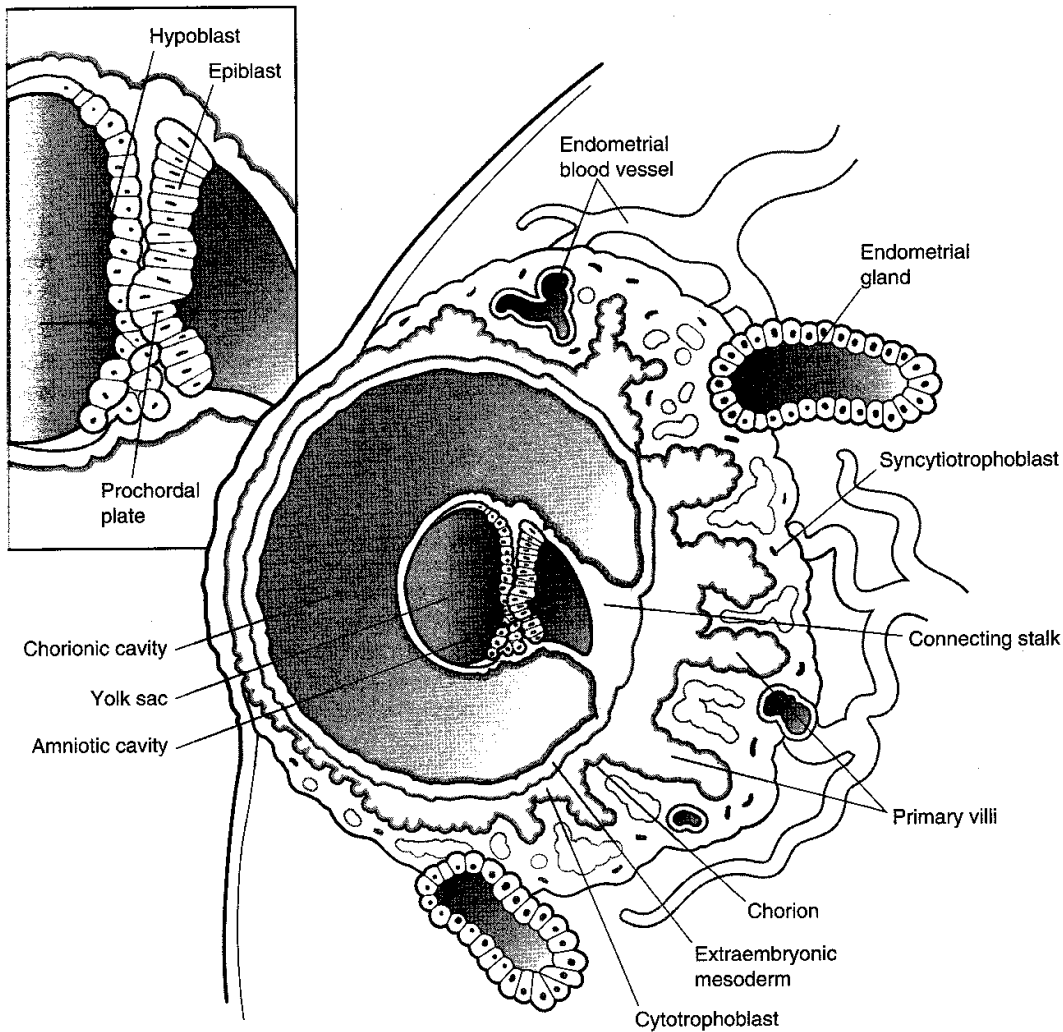


Figure II-3-1. Week 2

Clinical Correlate

Human Chorionic Gonadotropin

hCG is a glycoprotein, produced by the syncytiotrophoblast, which stimulates the production of progesterone by the corpus luteum (i.e., maintains corpus luteum function).

hCG can be assayed in maternal blood at day 8 or maternal urine at day 10 and is the basis for early pregnancy testing. hCG is detectable throughout pregnancy. Low hCG levels may predict a spontaneous abortion or ectopic pregnancy. High hCG levels may predict a multiple pregnancy, hydatidiform mole, or gestational trophoblastic neoplasia.

Clinical Correlate

A **hydatidiform mole** is a blighted blastocyst (embryo dies) followed by hyperplastic proliferation of the trophoblast within the uterine wall. Clinical signs are preeclampsia during the first trimester, high hCG levels ($>100,000$ mIU/mL), and an enlarged uterus with bleeding. Five percent of moles develop into gestational trophoblastic neoplasia, so follow-up visits are essential.

Clinical Correlate

Gestational trophoblastic neoplasia (GTN; or choriocarcinoma) is a malignant tumor of the trophoblast that may occur after a normal pregnancy, abortion, or hydatidiform mole. High hCG levels are diagnostic, with a high degree of suspicion.

Nonmetastatic GTN (confined to the uterus) is the most common form, and treatment is highly successful. However, prognosis of metastatic GTN is poor if it spreads to the liver or brain.

BILAMINAR EMBRYONIC DISK

The embryoblast differentiates into the **epiblast** and **hypoblast**, forming a bilaminar embryonic disk.

AMNIOTIC CAVITY AND YOLK SAC

The amniotic cavity and yolk sac form.

The **prochordal plate** marks the site of the future **mouth**.

GROWTH INTO THE ENDOMETRIUM

The syncytiotrophoblast continues its growth into the endometrium to make contact with endometrial blood vessels and glands. **No mitosis occurs in the syncytiotrophoblast.** The cytotrophoblast is mitotically active.

EXTRAEMBRYONIC MESODERM AND CHORION FORMATION

Extraembryonic mesoderm is a new layer of cells derived from the epiblast. **Extraembryonic somatic mesoderm** lines the cytotrophoblast, forms the connecting stalk, and covers the amnion. **Extraembryonic visceral mesoderm** covers the yolk sac.

The connecting stalk suspends the conceptus within the chorionic cavity. The wall of the chorionic cavity is called the **chorion**, which consists of extraembryonic somatic mesoderm, cytotrophoblast, and syncytiotrophoblast.

Chapter Summary

In the second week, implantation is completed with the rapid growth and erosion of the syncytiotrophoblast into the endometrium of the uterus where early utero-placental circulation is established. The inner cell mass of the first week differentiates into the epiblast and hypoblast cells and forms a bilaminar embryonic disk. An amniotic cavity develops from the epiblast and the primary yolk sac replaces the blastocyst cavity. The extraembryonic mesoderm and chorion are formed in the second week.

Embryonic Period (Weeks 3–8)

4

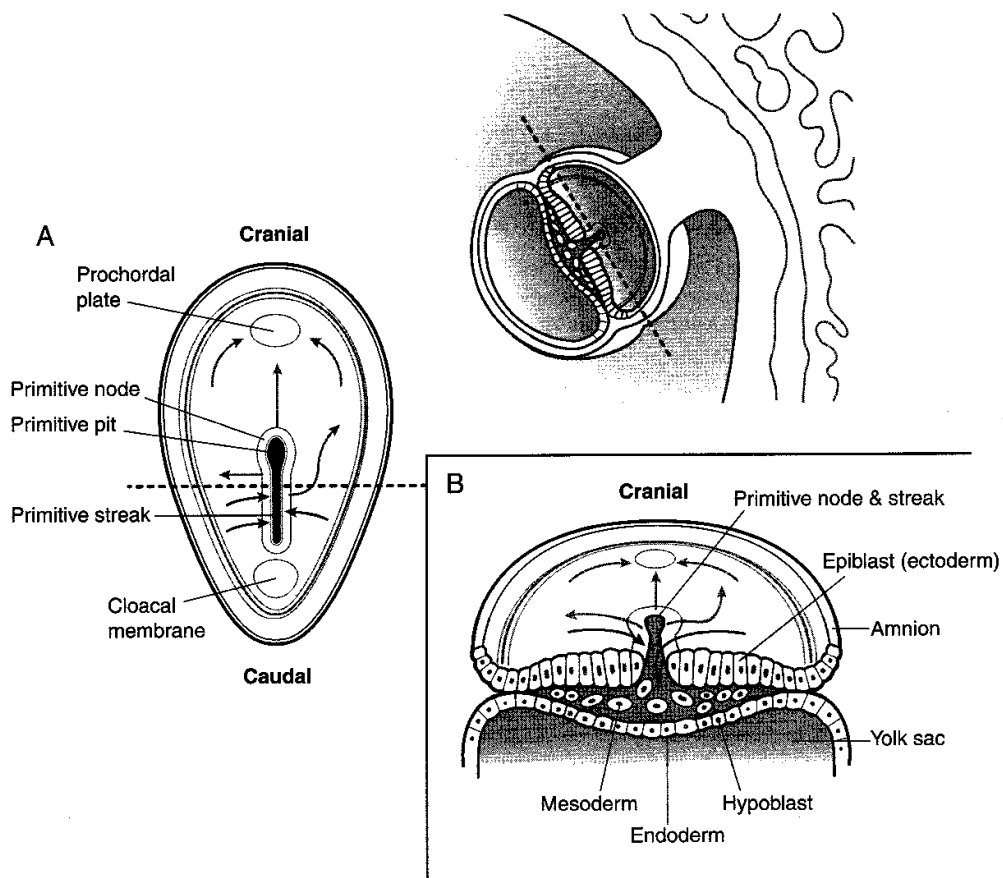


Figure II-4-1. Embryonic Period

Clinical Correlate

A **sacroccygeal teratoma** is a tumor that arises from remnants of the primitive streak. It often contains various types of tissue (bone, nerve, hair, etc).

A **chordoma** is a tumor that arises from remnants of the notochord found either intracranially or in the sacral region.

Clinical Correlate

Caudal Dysplasia (Sirenomelia)

Caudal dysplasia refers to a constellation of syndromes ranging from minor lesions of the lower vertebrae to complete fusion of lower limbs as a result of **abnormal gastrulation** in which migration of **mesoderm** is disturbed. It is associated with **VATER** (vertebral defects, anal atresia, tracheoesophageal fistula, and renal defects) or **VACTERL** (vertebral defects, anal atresia, cardiovascular defects, tracheoesophageal fistula, renal defects, and upper limb defects).

GASTRULATION

Gastrulation is a process that establishes the three primary germ layers: **ectoderm**, **mesoderm**, and **endoderm**. This process is first indicated by the formation of the **primitive streak** within the epiblast.

Ectoderm

Ectoderm gives further rise to **neuroectoderm** and **neural crest cells**.

Mesoderm

Mesoderm gives further rise to **paraxial mesoderm** (35 pairs of somites), **intermediate mesoderm**, and **lateral mesoderm**.

WEEK 3

Week 3 of embryonic development corresponds to the **first missed menstrual period**.

All cells and tissues of the adult can trace their origin back to the three primary germ layers.

ORGAN SYSTEMS DEVELOPMENT

All major organ systems begin to develop during the **embryonic period (weeks 3–8)**, causing a craniocaudal and lateral body folding of the embryo. By the end of the embryonic period (week 8), the embryo has a distinct human appearance.

Table II-4-1. Development of the Fetal Structures From the Three Germ Layers

Skin Ectoderm Epidermis, hair, nails Cochlear duct, semicircular ducts Enamel of teeth Adenohypophysis Lens of the eye Parotid gland Mammary glands Epithelial lining of lower anal canal	Mesoderm Muscle (smooth, cardiac, skeletal) Extraocular muscles (preotic somites) Muscles of the tongue (occipital somites) Connective tissue, dermis of skin Bone, cartilage Blood and lymph vessels Heart Adrenal cortex Spleen Kidney Dura mater Testes, ovaries	Endoderm Epithelial lining of: Gastrointestinal tract Trachea, bronchi, lungs Biliary apparatus Urinary bladder, urethra Vagina Auditory tube Middle ear cavity Parenchyma of: Liver Pancreas Submandibular gland Sublingual gland Thyroid Parathyroid
Neuroectoderm All neurons within brain and spinal cord Retina Neurohypophysis Astrocytes, oligodendrocytes	Notochord Nucleus pulposus	
Neural crest Adrenal medulla Ganglia Sensory Autonomic Pigment cells Schwann cells Meninges Pia and arachnoid mater Pharyngeal arch cartilage Odontoblasts Parafoallicular (C) cells Aorticopulmonary septum Endocardial cushions		

Further detail of the development into adult structures is presented in the Gross Anatomy section.

Chapter Summary

The critical events of the third week are gastrulation and early development of the nervous and cardiovascular systems. Gastrulation is the process that establishes three primary germ layers that derive from epiblast: ectoderm, mesoderm, and endoderm. Gastrulation begins with the development of the primitive streak and node. After regression of the primitive streak, the notochord is laid down in its place. The adult derivatives of ectoderm, mesoderm, and endoderm are given in Table II-4-1.

EARLY EMBRYOLOGY

Review Questions

1. At fertilization, what occurs to permit a sperm to penetrate the zona pellucida?
 - (A) Extrusion of second polar body
 - (B) Spermiogenesis
 - (C) Acrosomal reaction
 - (D) Zonal reaction
 - (E) Completion of meiosis II
2. In females, when does an oocyte complete meiosis II?
 - (A) After implantation of a blastocyst
 - (B) After fertilization
 - (C) Just prior to the LH surge
 - (D) Just prior to birth
 - (E) At the beginning of puberty
3. Which of the following has a haploid complement of chromosomes?
 - (A) Spermatid
 - (B) Primary spermatocyte
 - (C) Spermatogonium
 - (D) Oogonium
 - (E) Sertoli cell
4. At day 26 of the menstrual cycle, what is menstruated?
 - (A) Oogonium
 - (B) Oocyte arrested in metaphase
 - (C) Primary oocyte
 - (D) Haploid oocyte
 - (E) Oocyte arrested in prophase
5. At birth, all of the gametes in the ovary are
 - (A) haploid
 - (B) oogonia
 - (C) primary oocytes
 - (D) secondary oocytes
 - (E) graafian follicles
6. Cells of the adrenal medulla are derived from the same cells as those that form
 - (A) kidney collecting tubules
 - (B) preganglionic sympathetic neurons
 - (C) retinal ganglion cells
 - (D) pharyngeal arch cartilage
 - (E) thymic T cells

7. Which of the following are derived from the cells in the wall of the yolk sac?
 - (A) Syncytiotrophoblast cells
 - (B) Spermatogonia
 - (C) Basal plate cells
 - (D) Epiblast cells
 - (E) Prochordal plate cells
8. Which of the following are derived from neural crest cells?
 - (A) Oligodendrocytes
 - (B) Cells that synapse in the terminal ganglia in the wall of the gut
 - (C) Cells that secrete aldosterone in the adrenal gland
 - (D) Parafofollicular cells of the thyroid gland
 - (E) Cells that secrete vasopressin into the neurohypophysis
9. Cells of which of the following structures are derived from endoderm?
 - (A) Cochlear duct
 - (B) Renal pelvis
 - (C) Parotid gland
 - (D) Seminiferous tubule
 - (E) Auditory tube
10. Cells of which of the following are derived from mesoderm?
 - (A) Urethra
 - (B) Superior part of the vagina
 - (C) Liver hepatocytes
 - (D) Parietal cells of the stomach
 - (E) Sublingual gland

Answers and Explanations

1. **Answer: C.** In the acrosomal reaction, the enzyme contents of the acrosome are released to allow penetration of the corona radiata cells and the zona pellucida. Extrusion of second polar body and completion of meiosis II occur only after fertilization occurs. Spermiogenesis is the maturation process that transforms spermatids into spermatozoa. The zonal reaction prevents polyspermy after fertilization.
2. **Answer: B.** Meiosis II is rapidly completed just after fertilization occurs and only if fertilization occurs.
3. **Answer: A.** Spermatid is the only choice that has completed meiosis I and meiosis II and therefore has a haploid complement of chromosomes.
4. **Answer: B.** If fertilization does not occur, a secondary oocyte is menstruated, which is arrested in the metaphase stage of meiosis II.

5. **Answer: C.** At birth, all female gametes that began meiosis I in utero are arrested in the prophase stage of meiosis I and are primary oocytes.
6. **Answer: D.** Chromaffin cells are derived from neural crest cells, as are the cells that migrate into the first three pharyngeal arches and form the cartilage in those arches. All other cartilage is derived from mesoderm. Kidney tissue is also derived from mesoderm. Retinal ganglion cells and preganglionic sympathetic neurons are derived from the neural tube, and the T cells of the thymus are derived from endoderm.
7. **Answer: B.** Primordial gametes, spermatogonia, and oogonia are the only significant cells derived from the wall of the yolk sac and not from a germ layer. Syncytiotrophoblast cells are derived from the outer cell mass of the embryo, and basal plates are derived from neuroectoderm. Epiblast cells are totipotent cells that give rise to all embryonic tissues except for the gametes. Prochordal plate cells are derived from endoderm cells and indicate the site of the buccopharyngeal membrane separating the oral cavity from the oropharynx.
8. **Answer: D.** Parafollicular "C" cells are neural crest cells that migrate into the fourth pharyngeal pouch and embed themselves in the thyroid gland adjacent to thyroid follicles. Choices A, B, and E are all derived from neuroectoderm and are found inside the CNS. Cells producing aldosterone in the adrenal cortex are derived from mesoderm.
9. **Answer: E.** Cells lining the auditory tube and middle ear are derived from an outgrowth of the endoderm lining the first pharyngeal pouch. Cochlear hair cells and the parotid gland are derived from ectoderm; the renal pelvis and seminiferous tubule cells are derived from mesoderm.
10. **Answer: B.** The superior part of the vagina is derived from mesoderm cells that were part of the paramesonephric ducts that fuse to form the upper part of the vagina and uterus. The urethra, liver hepatocytes, and parietal cells are derived from endoderm. Cells in the sublingual gland are derived from endoderm.

SECTION III

**Gross Anatomy and
Organogenesis**

Back and Nervous System

1

VERTEBRAL COLUMN

Embryology

During the fourth week, sclerotome cells (mesoderm) migrate medially to surround the spinal cord and notochord. After proliferation of the caudal portion of the sclerotomes, the vertebrae are formed, each consisting of the caudal part of one sclerotome and the cephalic part of the next.

The notochord persists in the areas between the vertebral bodies, forming the nucleus pulposus. The latter, together with surrounding circular fibers of the anulus fibrosis, forms the intervertebral disc.

Cervical Vertebrae

There are seven cervical vertebrae of which the first two are atypical. All cervical vertebrae have openings in their transverse processes, the transverse foramina, which, when aligned, produce a canal that transmits the vertebral artery and vein (Figure III-1-1).

Atlas

This is the first cervical vertebra (C1). It has no body and leaves a space to accommodate the dens of the second cervical vertebra.

Axis

This is the second cervical vertebra (C2). It has a tooth-shaped process, the dens (odontoid process), which articulates with the atlas as a pivot joint. Movement at this joint allows lateral rotation of the head.

Clinical Correlate

Compression of the vertebral artery within the transverse foramina by osteoarthritic osteophytes may result in decreased blood flow to the brain stem.

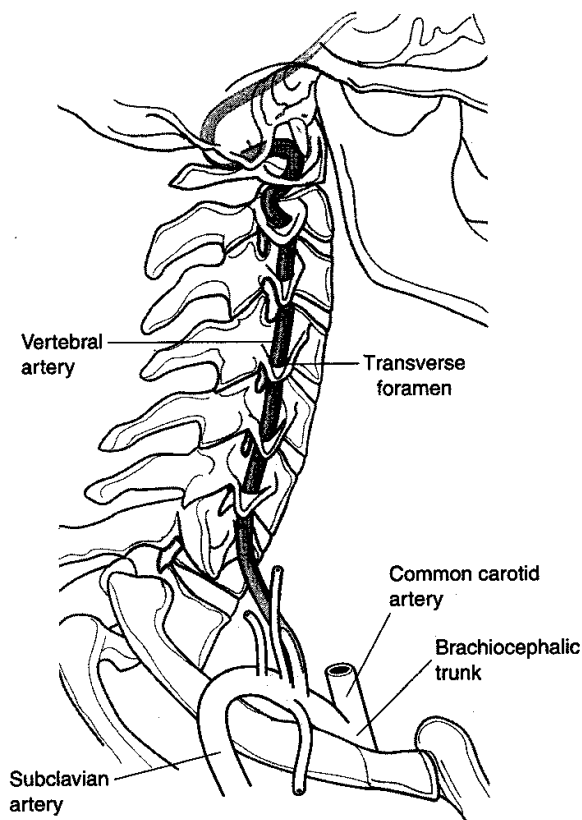


Figure III-1-1. Vertebral Artery

Thoracic Vertebrae

There are 12 thoracic vertebrae (Figure III-1-2).

- The vertebrae have facets on their bodies to articulate with the heads of ribs; each rib head articulates with the body of the numerically corresponding vertebra and the one above it.
- The thoracic vertebrae have facets on their transverse processes to articulate with the tubercles of the numerically corresponding ribs.

Lumbosacral Vertebrae

Unlike the thoracic wall, the bony support of the abdomen is minimal, consisting only of the lumbar vertebrae and portions of the pelvis (the ilium and the pubis).

- There are five lumbar vertebrae, L1 through L5.
- There are five sacral vertebrae, S1 through S5, which are fused.

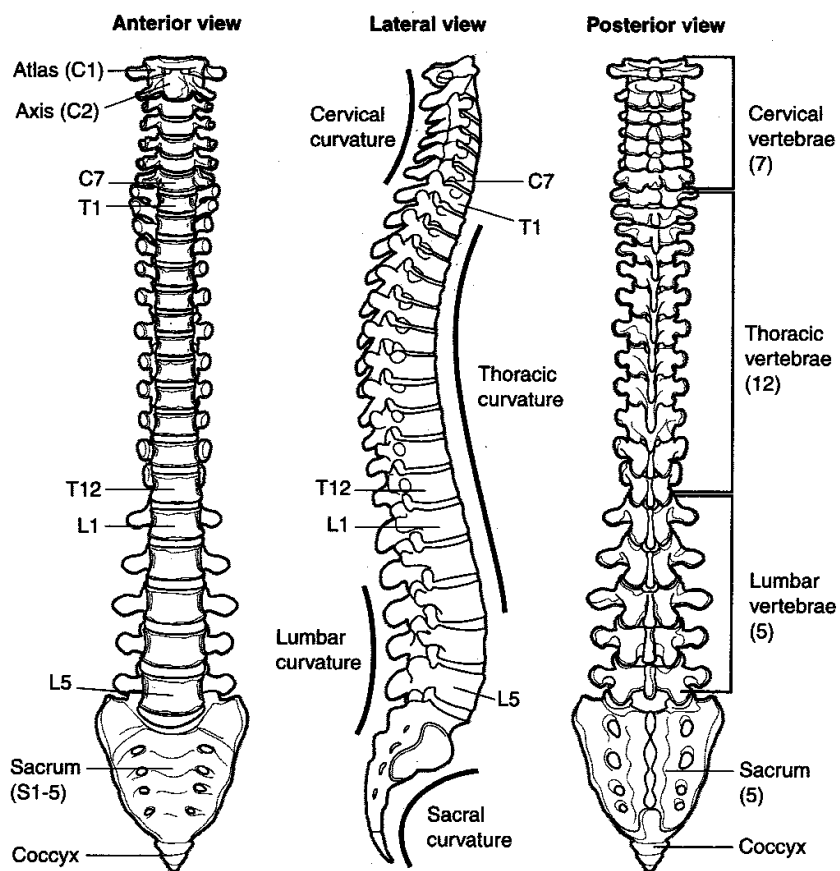


Figure III-1-2

Intervertebral Disks

Each disk has an outer portion, the **anulus fibrosus**, which is composed of fibrocartilage and fibrous connective tissue, and an inner portion, the **nucleus pulposus**, which is a semigelatinous fluid with very few, if any, cells.

Herniation of a nucleus pulposus is almost always in a **posterolateral** direction, passing through a rupture of the anulus fibrosus.

The herniated nucleus often comes to lie in the intervertebral foramen where it may compress a spinal nerve.

Ligaments

The intervertebral disk is reinforced anteriorly and anterolaterally by the **anterior longitudinal ligament**.

Clinical Correlate

The presence of interlaminar spaces between the laminae of lumbar vertebrae allows for lumbar puncture. The patient flexes the vertebral column to enlarge these spaces.

The posterior longitudinal ligament reinforces it posteriorly.

It is not reinforced posterolaterally.

Intervertebral Foramen

The intervertebral foramen is bounded **superiorly and inferiorly** by the **pedicles** of the vertebrae (Figure III-1-3).

It is bounded **anteriorly** by parts of the **bodies** of the vertebrae and the **intervertebral disk**.

The articular processes and the zygapophyseal joint bound it posteriorly.

The **spinal nerve** contained within the intervertebral foramen may be compressed by herniation of the nucleus pulposus or zygapophyseal joint disease.

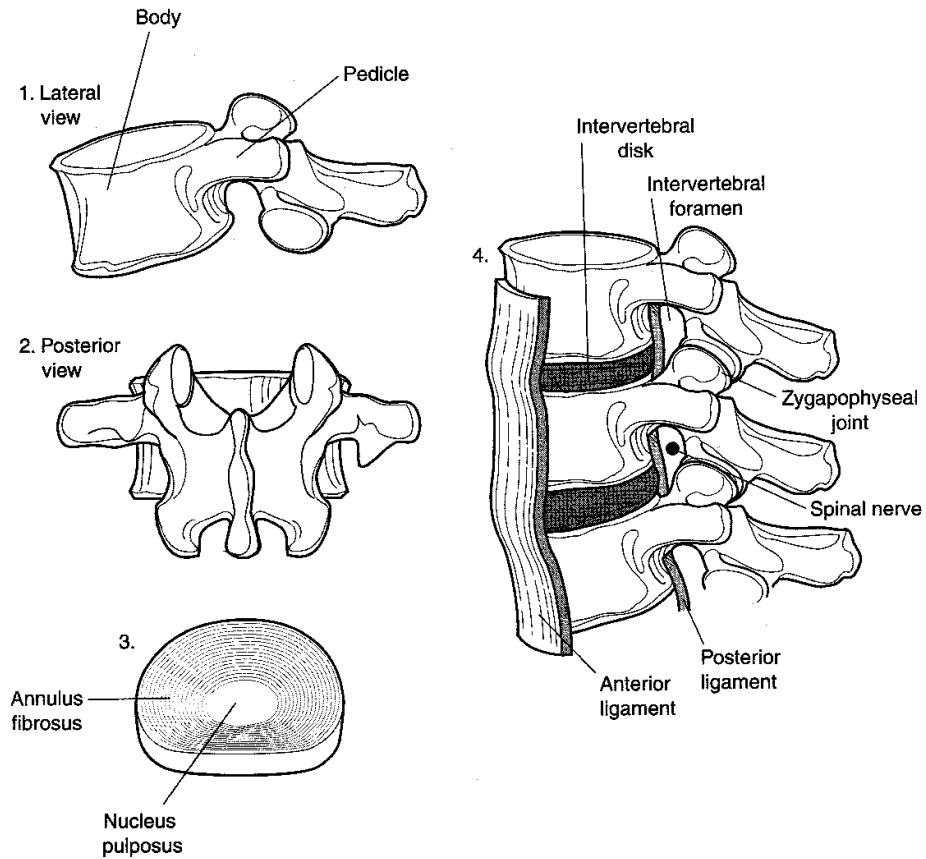


Figure III-1-3. Intervertebral Foramen

SPINAL NERVES AND SPINAL CORD

Neuron and Spinal Cord

The basic functional unit of the nervous system is the neuron. Many different types of neurons are found in the nervous system, and most of them contain three elements: the soma (cell body), dendrites, and an axon. A multipolar neuron is shown below to illustrate the main components of a neuron (Figure III-1-4).

Spinal nerves arise from the spinal cord by way of dorsal and ventral roots. The dorsal root contains sensory nerve fibers with their cell bodies in the dorsal root ganglion. The ventral root contains motor nerve fibers with their cell bodies in the gray matter of the spinal cord. The spinal nerve divides into a dorsal ramus and ventral ramus. Each ramus carries sensory and motor fibers to the dorsal and ventral parts of the body, respectively (Figure III-1-5). The dorsal ramus innervates the skin of the back, the deep back muscles, and the zygapophyseal joints. The anterior rami innervate the anterior and lateral portions of the body wall and the limbs.

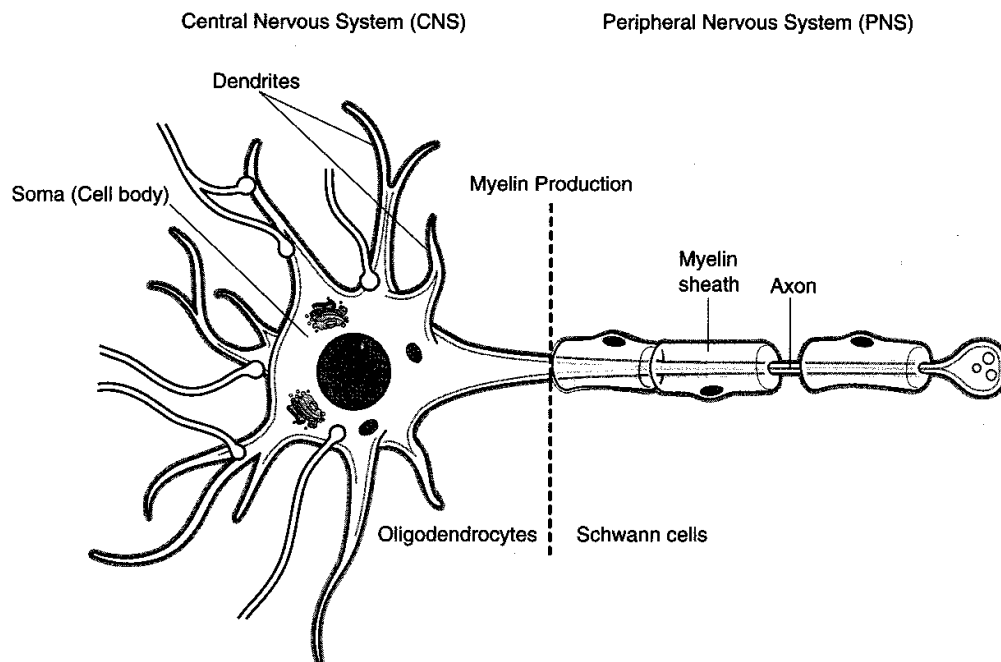


Figure III-1-4. Main Components of a Neuron

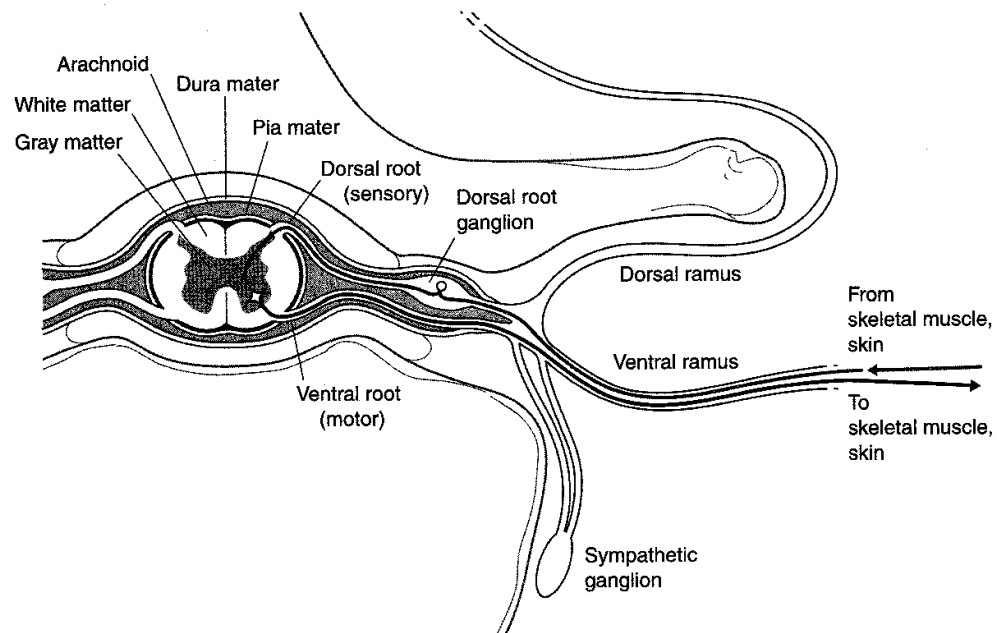


Figure III-1-5. Cross Section of Spinal Cord and the Components of a Spinal Nerve

Clinical Correlate

Lumbar puncture is typically performed at the L4–L5 interspace. The top of the iliac crest marks the level of the L4 vertebra.

Meninges

Pia mater

The **pia mater** is fused to the surface of the spinal cord and cannot be separated from it.

External to this is the subarachnoid space, which is filled with **cerebrospinal fluid (CSF)**.

The pressure of this fluid keeps the next layer, the **arachnoid**, away from the pia mater.

Dura mater

The outermost layer is the **dura mater**.

There normally is no subdural space, but such a space can be created when, for example, bleeding occurs into this space.

External to the dura is the **epidural space**, which contains fat and a plexus of veins.

The inferior limit of the dural sac and the subarachnoid space is at vertebral level S2.

Cauda equina

Below the inferior limit of the spinal cord at the level of L1 and L2, but within the subarachnoid space, is the cauda equina. This is composed of dorsal and ventral roots.

When a **spinal tap** is performed it is typically done at the level of L4 (top of the iliac crest). The cauda equina is at this level.

AUTONOMIC NERVOUS SYSTEM

General Organization

Definition

The autonomic nervous system (ANS) is responsible for the motor innervation of smooth muscle, cardiac muscle, and glands of the body. The ANS is composed of two divisions: (1) sympathetic and (2) parasympathetic.

In both divisions there are two neurons in the peripheral distribution of the motor innervation (Figure III-1-6).

Preganglionic neuron with the cell body in the central nervous system (CNS).

Postganglionic neuron with the cell body in a motor ganglion in the peripheral nervous system (PNS).

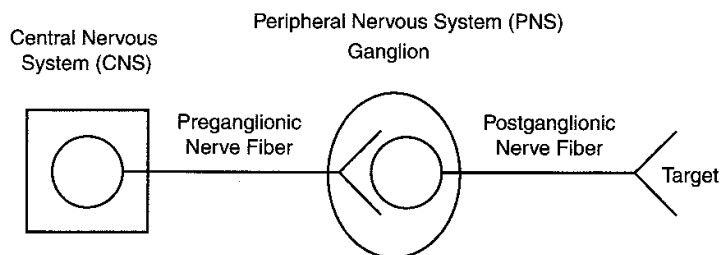


Figure III-1-6. Autonomic Nervous System

Sympathetic System

Sympathetic = thoracolumbar outflow (Figures III-1-7 and III-1-8).

Clinical Correlate

To perform a **lumbar puncture**, a needle is passed through the interlaminar space in the midline while the vertebral column is flexed. The layers that the needle must pass through are:

- Skin
- Superficial fascia
- Deep fascia
- Supraspinous ligament
- Interspinous ligament
- Interlaminar space
- Epidural space
- Dura
- Arachnoid
- Subarachnoid space

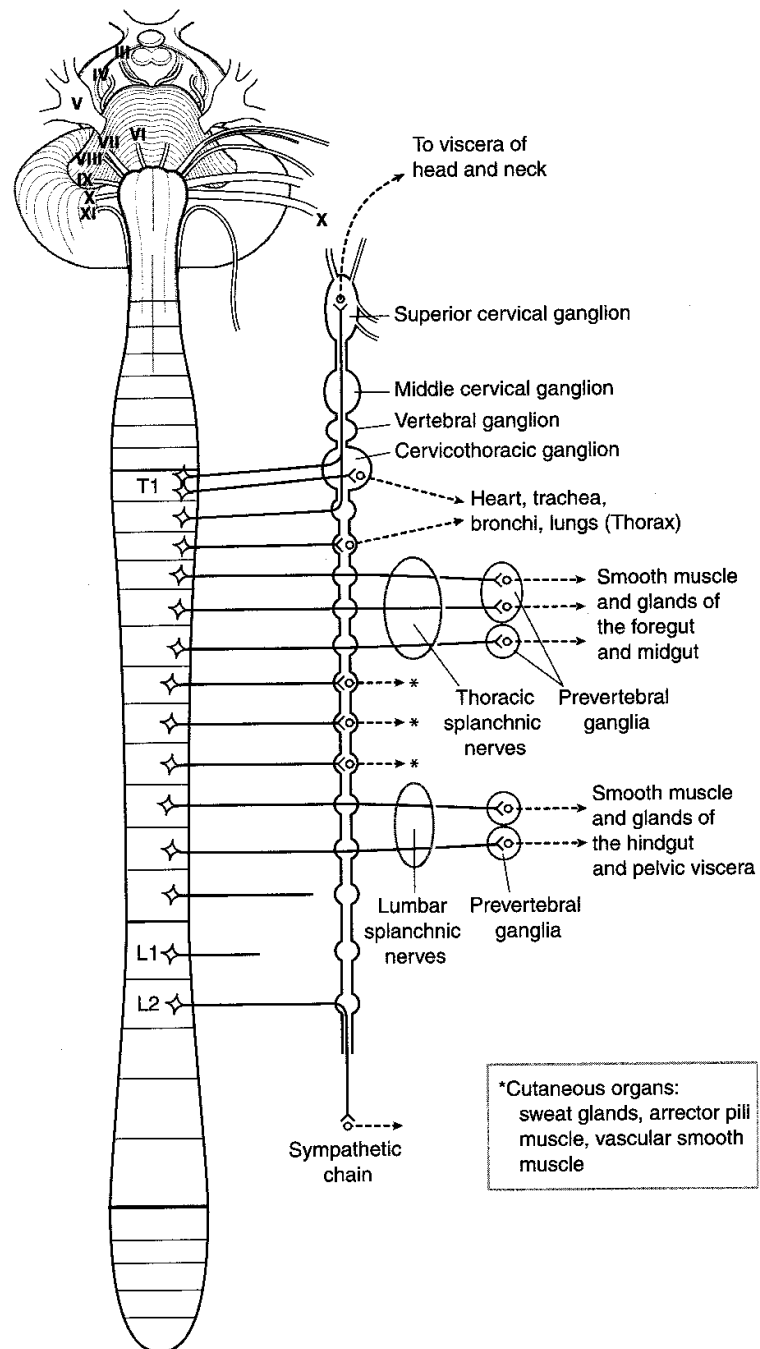


Figure III-1-7. Overview of Sympathetic Outflow

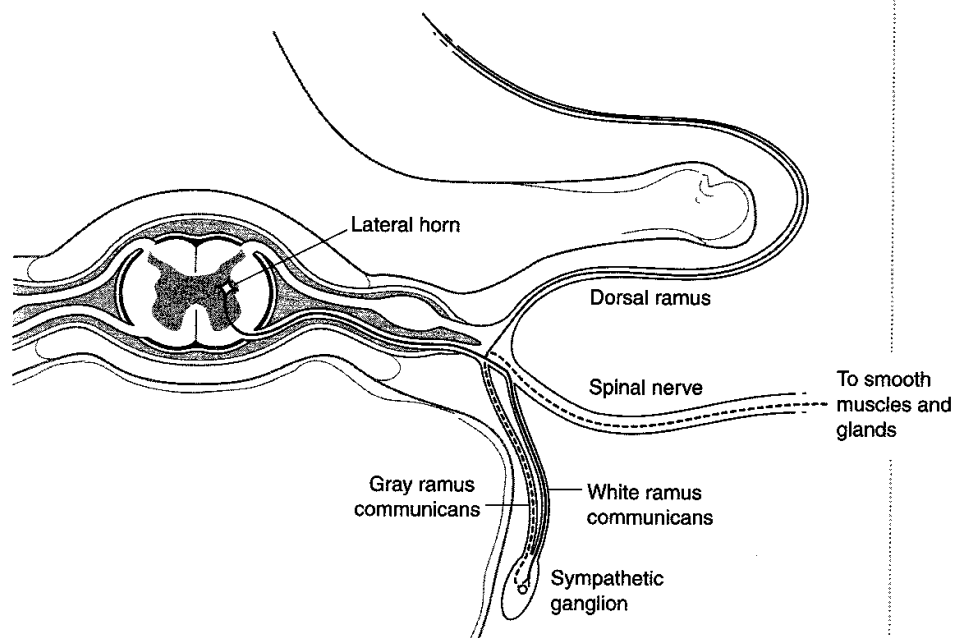


Figure III-1-8. Cross-Section of Spinal Cord Showing Sympathetic Outflow

Parasympathetic System

Parasympathetic = Craniosacral outflow (Figure III-1-9)

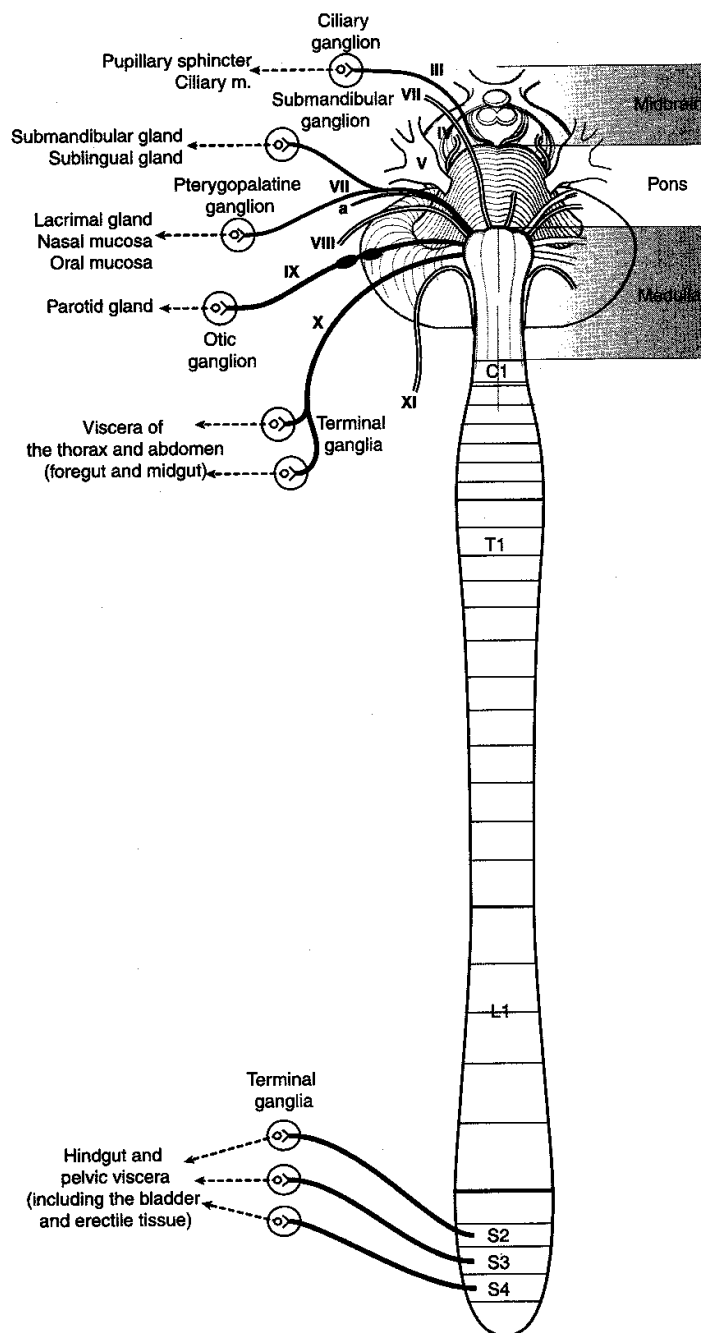


Figure III-1-9. Overview of Parasympathetic Outflow

Chapter Summary

The vertebral column is composed of a series of cervical, thoracic, lumbar, sacral, and coccygeal vertebrae connected by intervertebral disks and ligaments. The disks consist of an outer core of fibrocartilage, the annulus fibrosus, and an inner part—the nucleus pulposus, which developed from the notochord. Herniation of the nucleus pulposus is usually posterolateral where it can compress a spinal nerve at the intervertebral foramen.

The spinal nerve exits the vertebral column at the intervertebral foramen. The foramen is bound superiorly and inferiorly by the pedicles of the vertebrae, anteriorly by the vertebral bodies and intervertebral disks, and posteriorly by the zygapophyseal joint.

The spinal cord is covered by three protective layers of meninges: dura mater, arachnoid, and pia mater. The dura and dural sac terminate inferiorly at the second sacral vertebra, and the spinal cord terminates at the second lumbar vertebra. The cauda equina fills the lower part of the dural sac and contains the filum terminale and the ventral and dorsal roots of the lumbar and sacral spinal nerves. Between the arachnoid and pia is the subarachnoid space that contains cerebrospinal fluid, and between the dura mater and the vertebrae is the epidural space, which contains fat and a plexus of veins. Spinal taps are performed at the level of the L4 vertebra (located at the horizontal level of the iliac crest) to avoid puncturing the spinal cord.

Autonomic Nervous System

The autonomic nervous system (ANS) provides visceral motor innervation to smooth muscle, cardiac muscle, and glands. The ANS is divided into two divisions: sympathetic (thoracolumbar) and parasympathetic (craniosacral). The peripheral distribution of these two divisions consists of two neurons: (1) the preganglionic neuron (cell bodies in the CNS) and (2) the postganglionic neuron (cell bodies in motor ganglia in PNS).

Sympathetic preganglionic cell bodies are found in the lateral horn of the gray matter of spinal cord segments T1–L2. These synapse with postganglionic cell bodies located in either chain (paravertebral) ganglia or collateral (prevertebral) ganglia. Sympathetics to the body wall, head, and thoracic viscera synapse in the chain ganglia. Sympathetics to the foregut and midgut (thoracic splanchnic nerves: T5–T12) and to the hindgut and pelvic viscera (lumbar splanchnic nerves: L1–L2) synapse in collateral ganglia. Interruption of sympathetic innervation to the head results in ipsilateral Horner syndrome.

Parasympathetic preganglionic neuron cell bodies are located in the brain stem nuclei of cranial nerves III, VII, IX, and X, or in the gray matter of the spinal cord segments S2–S4 (pelvic splanchnics). The preganglionic neurons synapse with postganglionic neurons in terminal ganglia scattered throughout the body. Parasympathetics to the head originate in cranial nerves III, VII, and IX; those to the thorax, foregut, and midgut originate in cranial nerve X; and those to the hindgut and pelvic viscera originate in the S2–S4 cord segments.

Review Questions

1. Which of the following procedures is correctly matched to the last layer that a needle will traverse in the proper performance of that procedure?
 - (A) Lumbar puncture/arachnoid mater
 - (B) Pericardiocentesis/fibrous pericardium
 - (C) Thoracocentesis/visceral pleura
 - (D) Culdoscopy/posterior fornix
 - (E) Pudendal block/dura mater
2. You are performing a spinal tap slightly off the midline between the L3 and L4 vertebrae. What structure will the needle pass through during proper performance of this procedure?
 - (A) Posterior longitudinal ligament
 - (B) Ligamentum flavum
 - (C) Anterior longitudinal ligament
 - (D) Denticulate ligament
 - (E) Filum terminale
3. Which nerves increase peristalsis and glandular secretion in the gastrointestinal tract?
 - (A) Greater splanchnic nerves
 - (B) Lesser splanchnic nerves
 - (C) Pelvic splanchnic nerves
 - (D) Vagus nerves
 - (E) Lumbar splanchnic nerves
4. Your patient has a dry eye and reduced nasal secretions. The location of a lesion might be in the
 - (A) otic ganglion
 - (B) pterygopalatine ganglion
 - (C) ciliary ganglion
 - (D) superior cervical ganglion
 - (E) submandibular ganglion
5. Your patient has a herniated nucleus pulposus of the intervertebral disc between the L4 and L5 vertebrae. Which is the most likely condition that your patient would present with?
 - (A) Altered sensation in the L3 dermatome
 - (B) Weakness of muscles innervated by the L5 spinal cord segment
 - (C) Inability to contract the bladder
 - (D) Fecal incontinence
 - (E) Weakness in the ability to extend the leg at the knee

6. During a pregnancy, amniocentesis reveals elevated levels of alpha-fetoprotein, and ultrasound imaging indicates the presence of a cyst in the dorsal midline in the lower lumbar region. Corrective postnatal surgery reveals that the cyst contains cerebrospinal fluid but no neural tissue. What is your evaluation of the cyst?
- (A) It is seen in infants with spina bifida occulta.
 - (B) It was a meningocele.
 - (C) It was an Arnold Chiari formation.
 - (D) It results from the rostral neuropore failing to close.
 - (E) It was a cystocele.

Answers and Explanations

1. **Answer: A.** In a lumbar puncture, which is used to sample CSF, the needle must enter the subarachnoid space by last crossing the arachnoid mater. Pericardiocentesis is performed after the needle crosses the parietal layer of serous pericardium, which is deep to fibrous pericardium. Thoracocentesis is performed after the needle traverses the parietal pleura. Culdoscopy is performed after an endoscope traverses the parietal peritoneum lining the rectouterine pouch of Douglas. A pudendal block anesthetizes the pudendal nerve after it has emerged from the greater sciatic foramen.
2. **Answer: B.** The ligamentum flava unite the laminae of adjacent vertebrae and would be pierced in an off-midline lumbar puncture. The posterior and longitudinal ligaments are found on the corresponding side of the bodies and discs of vertebrae and are outside the dural sac. The denticulate ligament and the filum terminale are pial extensions that help stabilize the spinal cord. Neither would have to be pierced in a lumbar puncture.
3. **Answer: D.** Branches of the vagus nerves provide preganglionic parasympathetic innervation to terminal ganglia in the midgut. Pelvic splanchnic nerves increase peristalsis and glandular secretion in the hindgut. The other choices provide sympathetic innervation to gut structures, which inhibits peristalsis and glandular secretion.
4. **Answer: B.** The pterygopalatine ganglion provides postganglionic parasympathetic innervation to the lacrimal gland and to mucous glands of the oral and nasal cavities. The otic ganglion innervates the parotid gland, the ciliary ganglion innervates the ciliary and constrictor pupillae muscles, the superior cervical ganglion provides sympathetic innervation to the face scalp and orbit, and axons from the submandibular ganglion innervate the submandibular and sublingual salivary glands.
5. **Answer: B.** The spinal nerves affected by lumbar disc herniation between L4 and L5 might be the L5 and S1 spinal nerves. The L4 spinal nerve exits between L4 and L5 but is spared because it passes through the intervertebral foramen superior to the site of the herniation. The bladder and rectum are controlled by the S2, S3, and S4 spinal cord segments and are less likely to be affected. The L3 dermatome would not be affected, but the S1 dermatome might show some paresthesia. The quadriceps femoris muscle, which is the sole extensor of the leg at the knee, is innervated by the L2–L4 spinal cord segments and would not be affected.
6. **Answer: B.** A lumbar midline cyst containing CSF and no neural tissue is classified as spina bifida cystica with meningocele. Spina bifida occulta is asymptomatic, Arnold Chiari formations are downward herniations of the cerebellum through the foramen magnum, spina bifida defects are caudal neuropore problems, and a cystocele is a herniation of the bladder into the vagina.

Thorax

2

CHEST WALL

Breast

The breast (mammary gland) is a subcutaneous glandular organ of the superficial pectoral region. It is a modified sweat gland, specialized in women for the production and secretion of milk. A variable amount of fat surrounds the glandular tissue and duct system and is responsible for the shape and size of the female breast.

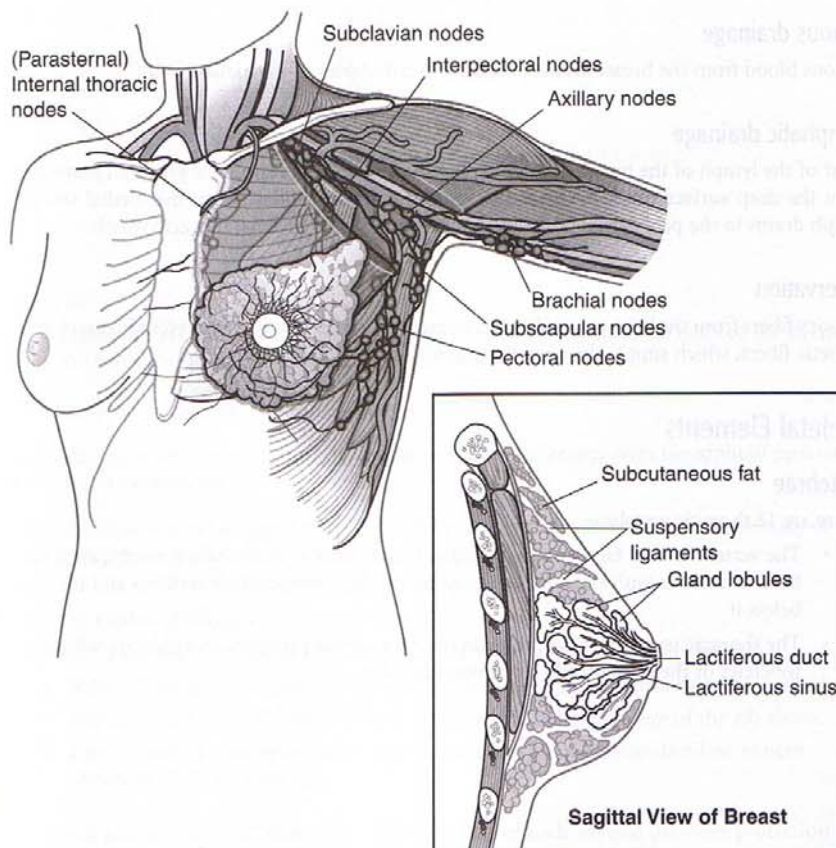


Figure III-2-1. Breast

Clinical Correlate

The presence of a tumor within the breast can distort Cooper ligaments, which results in dimpling of the skin.

Nipple

The nipple contains the openings of the lactiferous ducts. It is located approximately at the level of the fourth intercostal space in nulliparous women and in men. It contains circular smooth muscle fibers that contract during emission (let-down) of milk from the ducts.

The areola is a variable area surrounding the nipple. It contains sebaceous glands.

There are 15 to 20 lactiferous ducts, each of which drains a glandular lobule of breast tissue. The ducts radiate outward from the nipple. The terminal portion of each duct, the lactiferous sinus, is dilated.

Cooper ligaments

Cooper ligaments are suspensory ligaments, which attach the mammary gland to the skin and run from the skin to the deep fascia.

Arterial supply

Most of the blood supply to the breast is derived from branches of the internal thoracic (internal mammary) artery. However, the lateral thoracic and thoracoacromial branches of the axillary artery and the intercostal arteries also contribute to the blood supply.

Venous drainage

Venous blood from the breast drains primarily to tributaries of the axillary vein.

Lymphatic drainage

Most of the lymph of the breast drains laterally to axillary nodes (pectoral group). Lymphatics from the deep surface drain to the apical group of axillary nodes. From the medial surface, lymph drains to the parasternal nodes, which accompany the internal thoracic vessels.

Innervation

Sensory fibers from the breast contribute to intercostal nerves 2–6. These nerves also carry sympathetic fibers, which supply the smooth muscle of the areolae.

Skeletal Elements

Vertebrae

There are 12 thoracic vertebrae.

- The vertebrae have facets on their bodies to articulate with the heads of ribs; each rib head articulates with the body of the numerically corresponding vertebra and the one below it.
- The thoracic vertebrae have facets on their transverse processes to articulate with the tubercles of the numerically corresponding ribs.

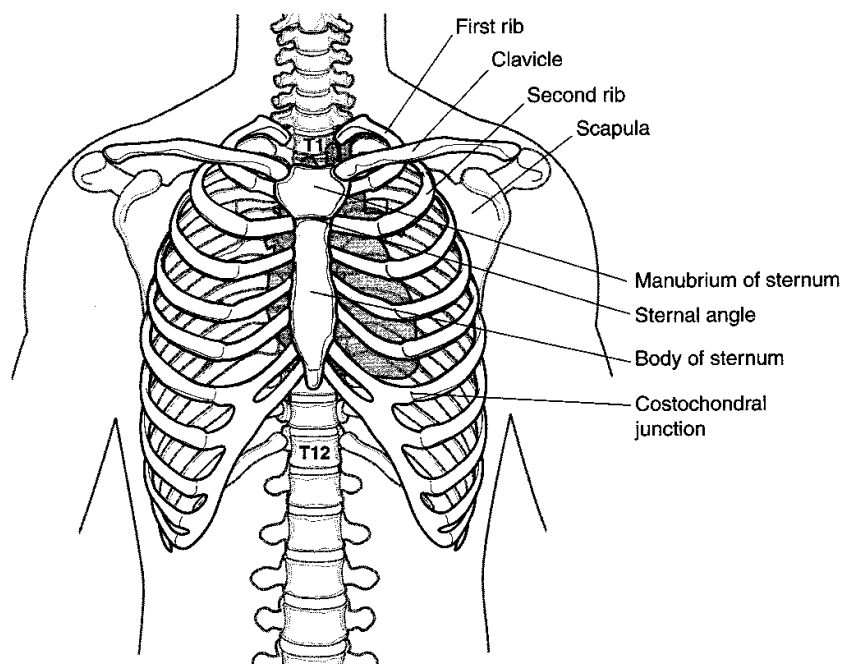


Figure III-2-2. The Thoracic Wall

Sternum

The manubrium articulates with the clavicle and the first rib. It meets the body of the sternum at the sternal angle, **an important clinical landmark**.

The second rib articulates at the sternal angle.

The body articulates directly with ribs 3–7; it articulates inferiorly with the xiphoid process at the xiphisternal junction.

The xiphoid process is cartilaginous at birth and usually ossifies and unites with the body of the sternum around age 40.

Ribs and costal cartilages

There are 12 pairs of ribs, which are attached posteriorly to thoracic vertebrae.

- Ribs 1–7 are termed “true ribs” and attach directly to the sternum by costal cartilages.
- Ribs 8–10 are termed “false ribs” and attach to the costal cartilage of the rib above.
- Ribs 11 and 12 have no anterior attachments, and are therefore classified as both “floating ribs” and false ribs.

The costal groove is located along the inferior border of each rib and provides protection for the intercostal nerve, artery, and vein.

Clinical Correlate

Coarctation of the aorta leads to increased blood flow through the intercostal arteries. Enlargement of these arteries results in costal notching on the lower border of the ribs.

Clinical Correlate

Passage of instruments through the intercostal space is done in the lower portion of the space to avoid the intercostal neurovascular structures.

An intercostal nerve block is done in the upper portion of the intercostal space.

Muscles

External intercostal muscles

There are 11 pairs of external intercostal muscles. Their fibers run anteriorly and inferiorly in the intercostal spaces from the rib above to the rib below.

These muscles fill the intercostal spaces from the tubercles of ribs posteriorly to the costochondral junctions anteriorly; external intercostal membranes replace them anteriorly.

Internal intercostal muscles

There are 11 pairs of internal intercostal muscles. Their fibers run posteriorly and inferiorly in the intercostal spaces deep to the external layer.

These muscles fill the intercostal spaces anteriorly from the sternum to the angles of the ribs posteriorly; internal intercostal membranes replace them posteriorly.

Innermost intercostal muscles

The deep layers of the internal intercostal muscles are the innermost intercostal muscles.

These muscles are separated from the internal intercostal muscles by intercostal nerves and vessels.

Intercostal Structures

Intercostal nerves

There are 12 pairs of thoracic nerves, 11 intercostal pairs, and 1 subcostal pair.

Intercostal nerves are the ventral primary rami of thoracic spinal nerves. These nerves supply the skin and musculature of the thoracic and abdominal walls and the parietal pleura and parietal peritoneum.

Intercostal arteries

There are 12 pairs of posterior and anterior arteries, 11 intercostal pairs, and 1 subcostal pair.

Anterior Intercostal Arteries

- Pairs 1–6 are derived from the internal thoracic arteries.
- Pairs 7–9 are derived from the musculophrenic arteries.
- There are no anterior intercostal arteries in the last two spaces; branches of the posterior intercostal arteries supply these spaces.

Posterior Intercostal Arteries

- The first two pairs arise from the superior intercostal artery, a branch of the costocervical trunk of the subclavian artery.
- Nine pairs of intercostal and one pair of subcostal arteries arise from the thoracic aorta.

Intercostal veins

Anterior branches of the intercostal veins drain to the internal thoracic and musculophrenic veins.

Posterior branches drain to the azygos system of veins.

Lymphatic drainage of intercostal spaces

Anterior drainage is to the internal thoracic (parasternal) nodes.

Posterior drainage is to the para-aortic nodes of the posterior mediastinum.

EMBRYOLOGY OF THE RESPIRATORY SYSTEM

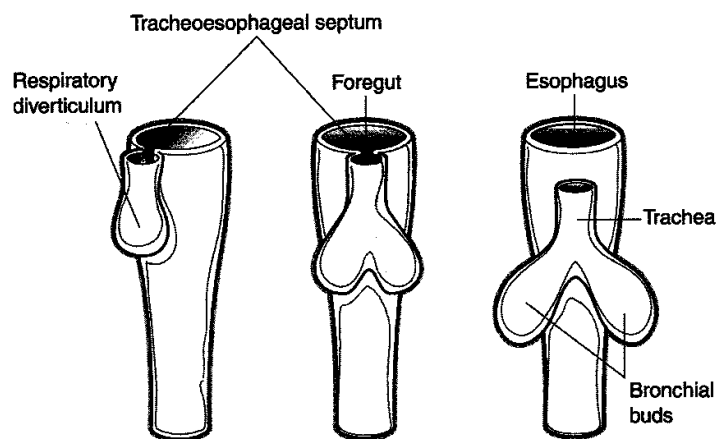


Figure III-2-3. Development of the Respiratory System

Foregut

The **respiratory (laryngotracheal) diverticulum** forms in the ventral wall of the foregut.

The **tracheoesophageal septum** divides the foregut into the esophagus and trachea.

Lung Bud

The distal end of the **respiratory diverticulum** enlarges to form the lung bud.

The lung bud divides into two **bronchial buds**, which branch into the **main bronchi**, **lobar bronchi**, and **segmental bronchi**.

The tertiary bronchi are related to **bronchopulmonary segments** of the lungs.

The lungs undergo four stages of development. These are summarized in Table III-2-1.

Clinical Correlate

A **tracheoesophageal fistula** is an abnormal communication between the trachea and esophagus caused by a malformation of the tracheoesophageal septum. It is generally associated with **esophageal atresia** and **polyhydramnios**. This condition results in gagging and cyanosis after feeding, excessive accumulation of saliva or mucus in the nose and mouth, abdominal distention after crying, and reflux of gastric contents into lungs causing pneumonitis. The fistula is most commonly (90% of all cases) located between the esophagus and distal third of the trachea.

Table III-2-1. The Four Stages of Lung Development

Stage	Characteristics
Glandular (weeks 5–17)	Respiration is not possible Premature fetuses cannot survive
Canalicular (weeks 13–25)	Respiration is not possible Premature fetuses rarely survive
Terminal sac (weeks 24–birth)	Type I and type II pneumocytes are present Respiration is possible Premature fetuses born between weeks 25 and 28 can survive with intensive care
Alveolar (birth–8 years) Note: Lung development continues after birth	Respiratory bronchioles, terminal sacs, alveolar ducts, and alveoli increase in number Chest radiograph is more dense in children

Clinical Correlate

Respiratory Distress Syndrome

Respiratory distress syndrome is caused by a deficiency of **surfactant** (composed of **phosphatidylcholine** [mainly **dipalmitoyl lecithin**] and proteins). This condition can be associated with premature infants, infants of diabetic mothers, and prolonged intrauterine asphyxia.

Thyroxine and **cortisol** treatment increase the production of surfactant.

Hyaline Membrane Disease

Surfactant deficiency may lead to **hyaline membrane disease** whereby repeated gasping inhalations damage the alveolar lining. Hyaline membrane disease is characterized histologically by **collapsed alveoli (atelectasis)** and **eosinophilic (pink) fluid** covering the alveoli.

PLEURA AND PLEURAL CAVITY

Parietal pleura lines the inner surface of the thoracic cavity; visceral pleura follows the contours of the lung itself (Figures III-2-4 and III-2-5).

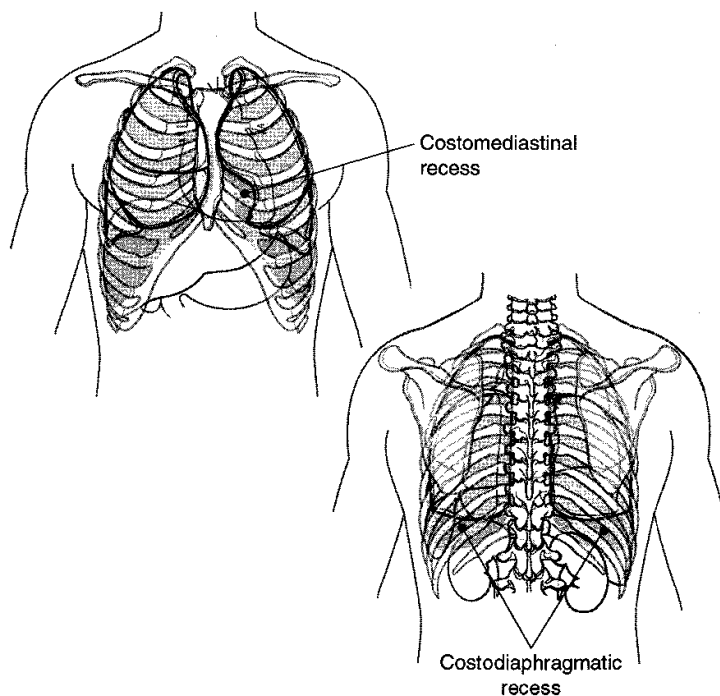


Figure III-2-4. Lungs and Pleura

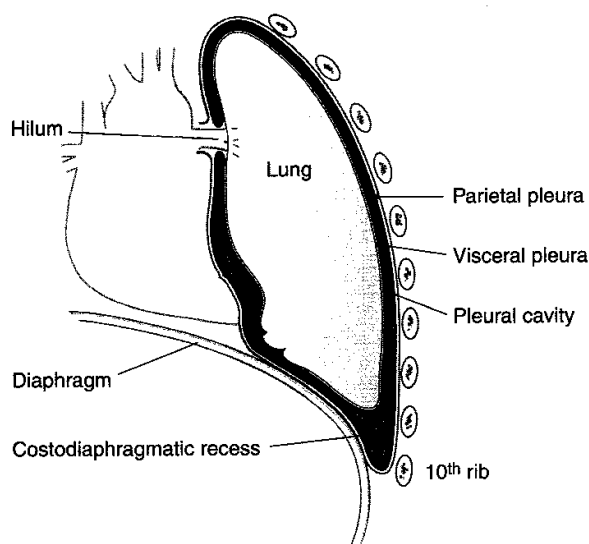


Figure III-2-5. Layers of the Pleura

Pleural Cavity

The pleural cavity is the space between the parietal and visceral layers of the pleura (Figures III-2-4 and III-2-5). It is a sealed, blind space. The introduction of air into the pleural cavity may cause the lung to collapse (pneumothorax).

It normally contains a small amount of serous fluid elaborated by mesothelial cells of the pleural membrane.

Pleural Reflections

Pleural reflections are areas where the pleura change direction from one wall to the other.

- The sternal line of reflection is where the costal pleura is continuous with the mediastinal pleura behind the sternum (from costal cartilages 2–4). The pleural margin then passes inferiorly to the level of the sixth costal cartilage.
- The costal line of reflection is where the costal pleura becomes continuous with the diaphragmatic pleura from rib 8 in the midclavicular line, to rib 10 in the midaxillary line, and to rib 12 lateral to the vertebral column.

Pleural Recesses

Pleural recesses are potential spaces not occupied by lung tissue except during deep inspiration (Figure III-2-4).

- Costodiaphragmatic recesses are spaces below the inferior borders of the lungs where costal and diaphragmatic pleura are in contact.
- The costomediastinal recess is a space where the left costal and mediastinal parietal pleura meet, leaving a space caused by the cardiac notch of the left lung. This space is occupied by the lingula of the left lung during inspiration.

Clinical Correlate

Pulmonary hypoplasia occurs when lung development is stunted. This condition can be associated with **congenital diaphragmatic hernia** (herniation of abdominal contents into the thorax, which compresses the lung) or with **bilateral renal agenesis** (this causes oligohydramnios, which increases the pressure on the fetal thorax).

In A Nutshell

	Bottom of Lung	Bottom of Pleura
Midclavicular line	6th rib	8th rib
Midaxillary line	8th rib	10th rib
Paravertebral line	10th rib	12th rib

Innervation of Parietal Pleura

The intercostal nerves supply the costal and peripheral portions of the diaphragmatic pleura.

The phrenic nerve supplies the central portion of the diaphragmatic pleura and the mediastinal pleura.

LUNGS

Regions

The costal surface is a large convex area related to the inner surface of the ribs.

The mediastinal surface is a concave medial surface:

- The left lung has a deep cardiac impression.
- The mediastinal surface contains the root, or hilus, of the lung.
- The pulmonary ligament is a double fold of pleura hanging inferior to the root of the lung.

The diaphragmatic surface (base) is related to the convex surface of the diaphragm. It is more concave on the right owing to the presence of the liver.

The apex (cupola) protrudes into the root of the neck. It is crossed by the subclavian artery and vein anteriorly.

The hilus is the point of attachment for the root of the lung. It contains the bronchi, pulmonary and bronchial vessels, lymphatics, and nerves.

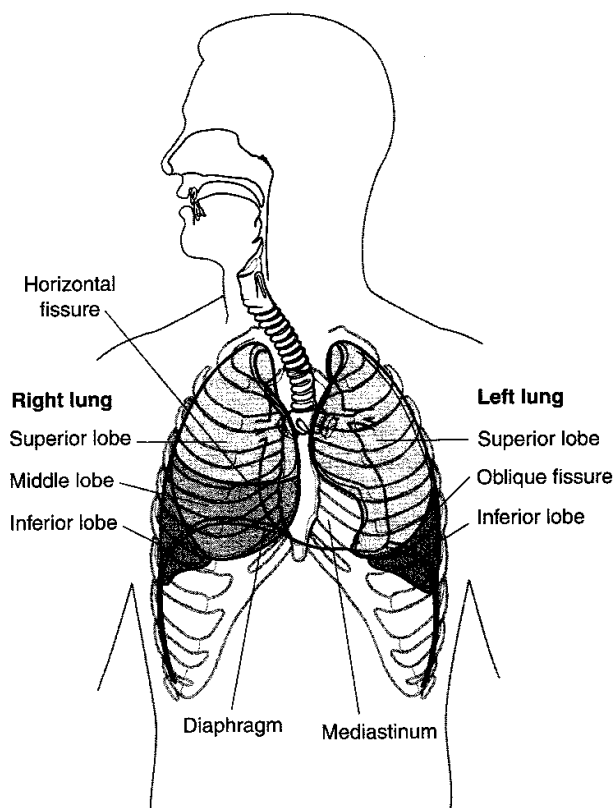


Figure III-2-6. Pleural Cavities and Mediastinum

Lobes and Fissures

The right lung is divided by the oblique and horizontal fissures into three lobes: superior, middle, and inferior.

The left lung has only one fissure, the oblique, which divides the lung into upper and lower lobes. The lingula of the upper lobe corresponds to the middle lobe of the right lung.

Bronchopulmonary Segments

Bronchopulmonary segments of the lung are supplied by the segmental (tertiary) bronchus, artery, and vein. There are 10 on the right and 8 on the left.

Arterial Supply

The right and left pulmonary arteries arise from the pulmonary trunk. The pulmonary arteries deliver deoxygenated blood to the lungs from the right side of the heart.

The bronchial arteries supply the bronchi and nonrespiratory portions of the lung. They are usually branches of the thoracic aorta.

Clinical Correlate

The upper lobes project primarily to the anterior chest wall.

The lower lobes project primarily to the posterior chest wall.

The oblique fissures are at approximately the fifth intercostal space.

The horizontal fissure ends anteriorly at approximately the fourth costal cartilage.

Venous Drainage

There are four pulmonary veins: superior right and left and inferior right and left.

The pulmonary veins carry oxygenated blood to the left atrium of the heart.

The bronchial veins drain to the azygos system. They share drainage from the bronchi with the pulmonary veins.

Lymphatic Drainage

Superficial drainage is to the bronchopulmonary nodes; from there, drainage is to the tracheo-bronchial nodes.

Deep drainage is to the pulmonary nodes; from there, drainage is to the bronchopulmonary nodes.

Bronchomediastinal lymph trunks drain to the right lymphatic duct and the thoracic duct.

Innervation of Lungs

Anterior and posterior pulmonary plexuses are formed by vagal (parasympathetic) and sympathetic fibers.

Parasympathetic stimulation has a bronchoconstrictor effect.

Sympathetic stimulation has a bronchodilator effect.

EMBRYOLOGY OF THE HEART

Formation of Heart Tube

Endocardium

Lateral plate mesoderm fuses in the midline to form the **primitive heart tube**, which becomes the endocardium of the adult heart (Figure III-2-7).

Myocardium

Mesoderm surrounding the primitive heart tube secretes **cardiac jelly** and forms the myocardium of the adult heart.

Epicardium

Mesoderm from the coelomic wall forms the epicardium of the adult heart.

Dextral looping

The primitive heart tube undergoes dextral looping (bends to the right).

Adult structures derived from the dilatations of the primitive heart

The primitive heart forms five dilatations, the fates of which are shown in Table III-2-2.

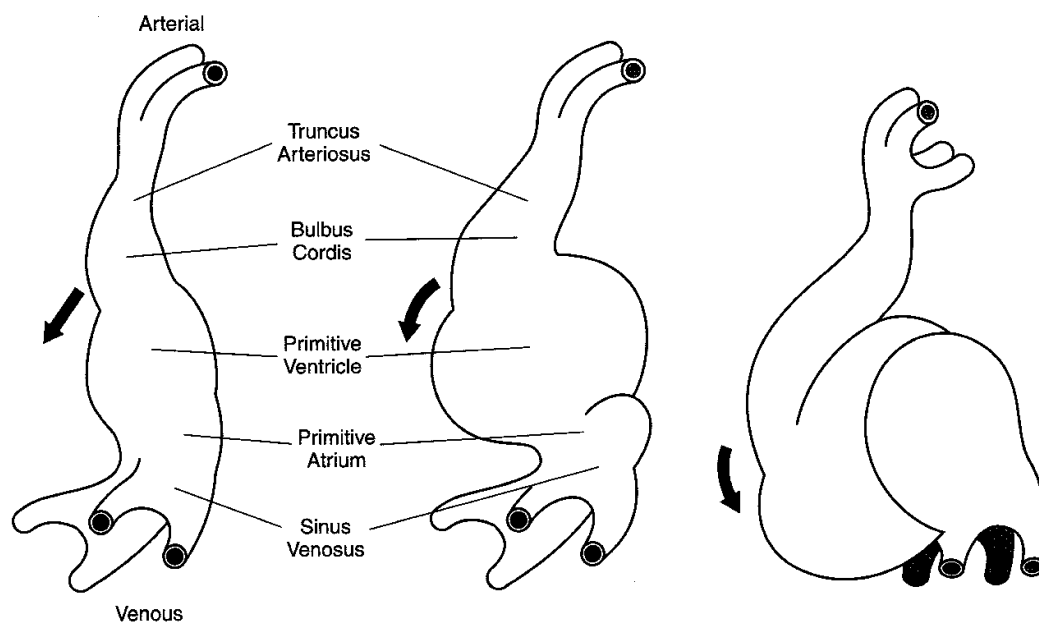


Figure III-2-7. Development of the Heart Tube

Table III-2-2. Adult Structures Derived From the Dilatations of the Primitive Heart

Embryonic Dilatation	Adult Structure
Truncus arteriosus (neural crest)	Aorta Pulmonary trunk
Bulbus cordis	Smooth part of right ventricle (conus arteriosus) Smooth part of left ventricle (aortic vestibule)
Primitive ventricle	Trabeculated part of right ventricle Trabeculated part of left ventricle
Primitive atrium	Trabeculated part of right atrium Trabeculated part of left atrium
Sinus venosus	Right—smooth part of right atrium (sinus venarum) Left—coronary sinus Oblique vein of left atrium

Note

The smooth part of the left atrium is formed by incorporation of parts of the pulmonary veins into its wall.

The junction of the trabeculated and smooth parts of the right atrium is called *crista terminalis*.

Clinical Correlate

Atrial septal defects are called ASDs.

Secundum-type ASDs are caused by excessive resorption of the SP, or reduced size of SS or both. This results in an opening between the right and left atria (patent FO). If the ASD is small, clinical symptoms may be delayed as late as age 30. This is the most clinically significant ASD.

Premature closure of the FO is the closure of the FO during prenatal life. This results in hypertrophy of the right side of the heart and underdevelopment of the left side.

Atrial Septum

The septum primum (SP) grows toward the atrioventricular (AV) septum (Figure III-2-8).

The foramen primum (FP) is located between the edge of the SP and the AV septum; it is obliterated when the SP fuses with the AV septum.

The foramen secundum (FS) forms within the SP. The septum secundum (SS) forms to the right of the SP and fuses (after birth) with the SP to form the atrial septum.

The foramen ovale (FO) is the opening pathway between SP and SS.

During fetal life, blood is shunted from the right atrium to the left atrium via the FO and FS (right-to-left shunt).

Closure of the FO normally occurs immediately after birth and is caused by the increased left atrial pressure that results from changes in the pulmonary circulation and decreased right atrial pressure caused by the closure of the umbilical vein.

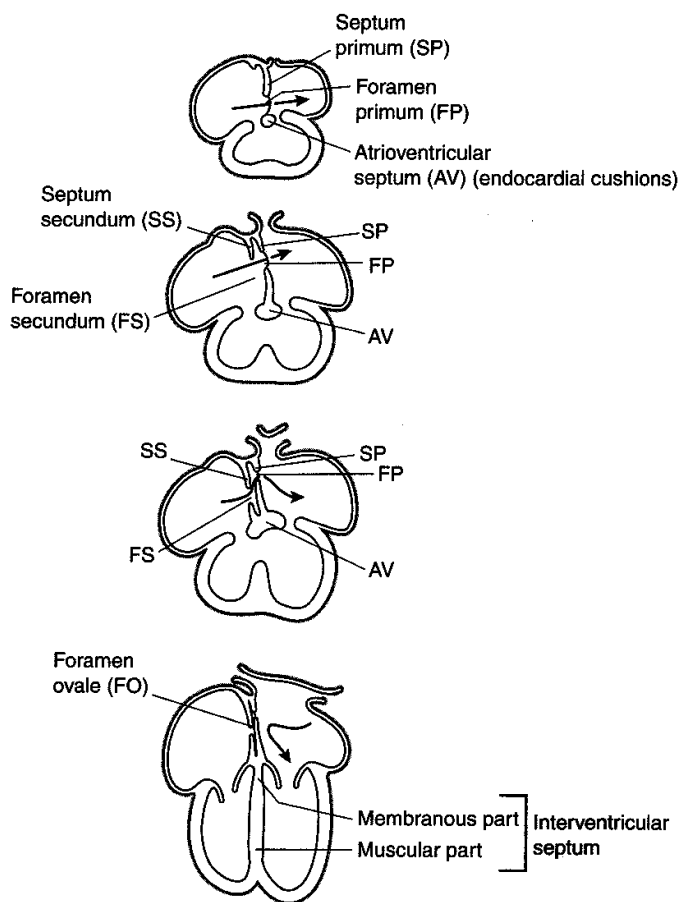


Figure III-2-8. Formation of Atrial Septum

Interventricular Septum

The **muscular interventricular (IV) septum** develops in the floor of the ventricle and grows toward the AV cushions but stops short, leaving the **IV foramen** (Figure III-2-9).

The **membranous IV septum** (closes the IV foramen) forms by the fusion of the:

- (a) Right bulbar ridge
- (b) Left bulbar ridge
- (c) AV cushions

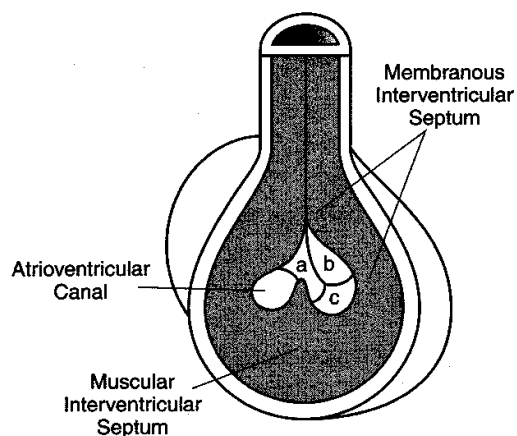


Figure III-2-9. Formation of Interventricular Septum

Clinical Correlate

Membranous Ventricular Septal Defect (VSD)

A membranous VSD is caused by the failure of the membranous IV septum to develop, and it results in **left-to-right shunting** of blood through the IV foramen. Patients with left-to-right shunting complain of **excessive fatigue upon exertion**. Left-to-right shunting of blood is noncyanotic but causes increased blood flow and pressure to the lungs (pulmonary hypertension). Pulmonary hypertension causes marked proliferation of the tunica intima and media of pulmonary muscular arteries and arterioles. Ultimately, the pulmonary resistance becomes higher than systemic resistance and causes **right-to-left shunting** of blood and **cyanosis**. At this stage, the condition is called **Eisenmenger complex**.

Clinical Correlate

Transposition of the great vessels occurs when the AP septum fails to develop in a spiral fashion and results in the aorta opening into the right ventricle and the pulmonary trunk opening into the left ventricle. This causes **right-to-left** shunting of blood with resultant **cyanosis**.

Infants born alive with this defect must have other defects that allow mixing of oxygenated and deoxygenated blood.

Tetralogy of Fallot occurs when the AP septum fails to align properly and results in (1) pulmonary stenosis, (2) overriding aorta, (3) interventricular septal defect, and (4) right ventricular hypertrophy. This causes **right-to-left** shunting of blood with resultant **cyanosis**.

Persistent truncus arteriosus occurs when there is only partial development of the AP septum. This results in a condition in which only one large vessel leaves the heart and it receives blood from both the right and left ventricles. This causes **right-to-left** shunting of blood with resultant **cyanosis**. This defect is always accompanied by membranous ventricular septal defect.

Aorticopulmonary Septum

Neural crest cells migrate into the truncal and bulbar ridges of the truncus arteriosus, which grow in a spiral fashion and fuse to form the aorticopulmonary (AP) septum. The AP septum divides the truncus arteriosus into the **aorta** and **pulmonary trunk** (Figure III-2-10).

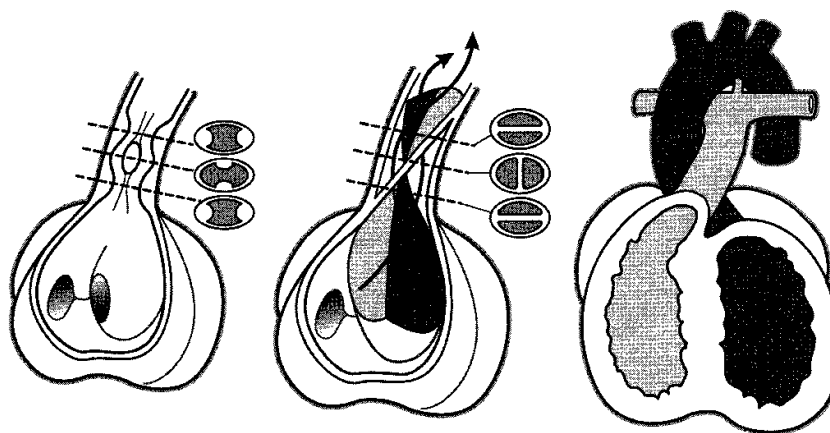


Figure III-2-10. Formation of the Aorticopulmonary Septum

Fetal Circulation

Fetal circulation involves three shunts: **ductus venosus**, **ductus arteriosus**, and **foramen ovale** (Figure III-2-11). After birth, a number of changes occur in the circulatory system because of the cessation of placental blood flow and start of lung respiration (Table III-2-3).

Table III-2-3. Adult Vestiges Derived From the Fetal Circulatory System

Changes After Birth	Remnant in Adult
Closure of right and left umbilical arteries	Medial umbilical ligaments
Closure of left umbilical vein	Ligamentum teres
Closure of ductus venosus	Ligamentum venosum
Closure of foramen ovale	Fossa ovale
Closure of ductus arteriosus	Ligamentum arteriosum

Vasculogenesis starts in the mesoderm surrounding the yolk sac.

Hematopoiesis occurs initially in the mesoderm surrounding the yolk sac and later in the fetal liver, spleen, thymus, and bone marrow.

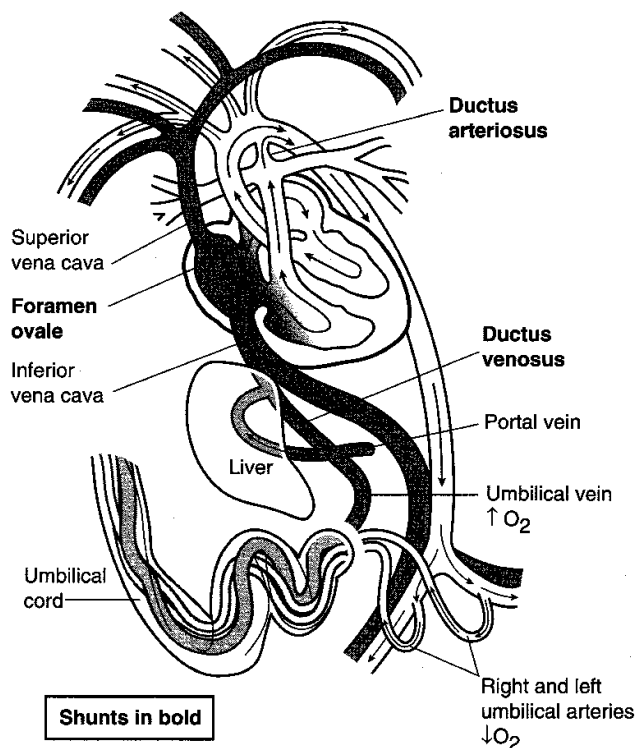


Figure III-2-11. Fetal Circulation

MEDIASTINUM

General Features

Located between the pleural cavities, the mediastinum is divided into inferior and superior parts by a plane passing from the sternal angle anteriorly to the intervertebral disc between T4 and T5 posteriorly. The inferior mediastinum is classically subdivided into middle, anterior, and posterior parts (Figure III-2-12).

Clinical Correlate

Patent ductus arteriosus (PDA) occurs when the ductus arteriosus (a connection between the pulmonary trunk and aorta) fails to close after birth. Normally, the ductus arteriosus closes within a few hours after birth via smooth muscle contraction to form the ligamentum arteriosum.

Prostaglandin E and intrauterine or neonatal asphyxia sustain patency of the ductus arteriosus.

Prostaglandin inhibitors (e.g., indomethacin), acetylcholine, histamine, and catecholamines promote closure of the ductus arteriosus.

PDA is common in premature infants and cases of maternal rubella infection. It causes a left-to-right shunting of blood (Note: the ductus arteriosus during fetal development is a right-to-left shunt).

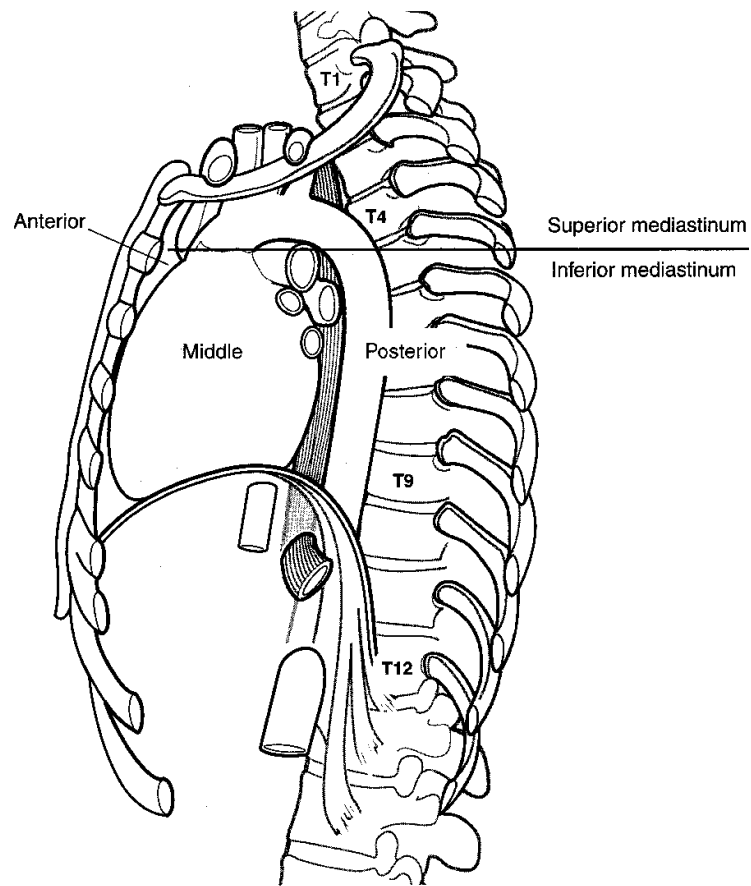


Figure III-2-12. Divisions of the Mediastinum

Middle Mediastinum

This section contains the pericardium, phrenic nerves, and heart.

Pericardium

The pericardium has an outer fibrous sac and a double-layered serous membrane that encloses the pericardial cavity between its parietal and visceral layers (Figure III-2-13).

- The transverse pericardial sinus is a space posterior to the ascending aorta and pulmonary trunk and anterior to the superior vena cava and left atrium.
- The oblique pericardial sinus is a blind, inverted, U-shaped space posterior to the heart and bounded by reflection of serous pericardium around the four pulmonary veins and the inferior vena cava as they enter the heart.

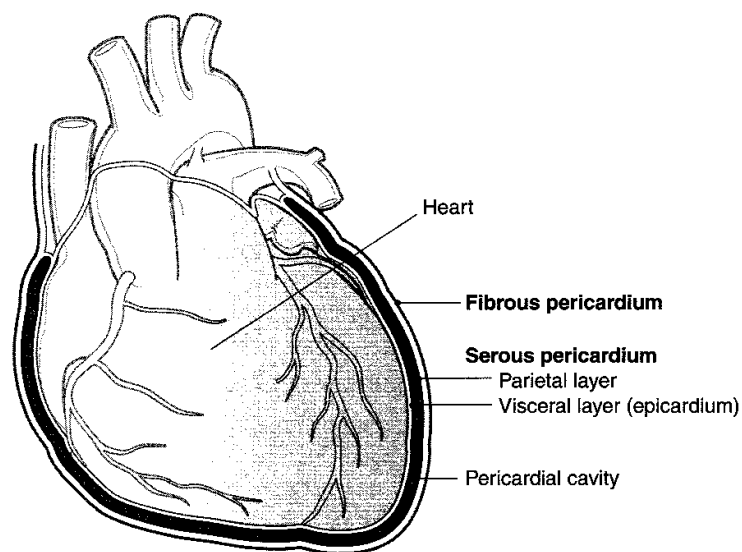


Figure III-2-13. Layers of the Pericardium

Phrenic nerves

Phrenic nerves arise from the ventral rami of cervical nerves 3, 4, and 5.

They are the sole motor supply of the diaphragm and convey sensory information from the central portion of both the superior and inferior portions of the diaphragm.

Both phrenic nerves pass through the middle mediastinum lateral to the fibrous pericardium and anterior to the root of the lung.

Heart

Discussed separately below.

Anterior Mediastinum

This section contains fat and areolar tissue and the inferior part of the thymus.

Posterior Mediastinum

Thoracic (descending) aorta

The most important branches of the thoracic aorta are the bronchial, esophageal, and posterior intercostal arteries.

It terminates at vertebral level T12, where it passes through the aortic hiatus of the diaphragm to become the abdominal aorta.

Esophagus

The esophagus is immediately behind the pericardium and is related anteriorly to the left atrium.

The esophagus is related anteriorly to the anterior esophageal plexus, which is derived mainly from the left vagus.

The esophagus is related posteriorly to the posterior esophageal plexus, which is derived mainly from the right vagus.

The thoracic esophagus terminates at vertebral level T10 by passing through the esophageal hiatus of the diaphragm.

Thoracic duct

The thoracic duct lies behind the esophagus and between the thoracic aorta and azygos vein.

It arises from the cisterna chyli in the abdomen at vertebral level L1 through L2 and enters the thorax through the aortic hiatus of the diaphragm.

Azygos system of veins

The posterior thoracic and abdominal walls are drained by the azygos system of veins (Figure III-2-14).

The azygos vein usually communicates with the inferior vena cava in the abdomen; the hemiazygos vein often communicates with the left renal vein. These veins ascend to the thorax through the aortic orifice of the diaphragm.

The azygos vein terminates by arching over the root of the right lung to empty into the superior vena cava.

It receives blood directly from the right posterior intercostal veins and indirectly via the left-sided tributaries of the hemiazygos and accessory hemiazygos veins and the left posterior intercostal veins.

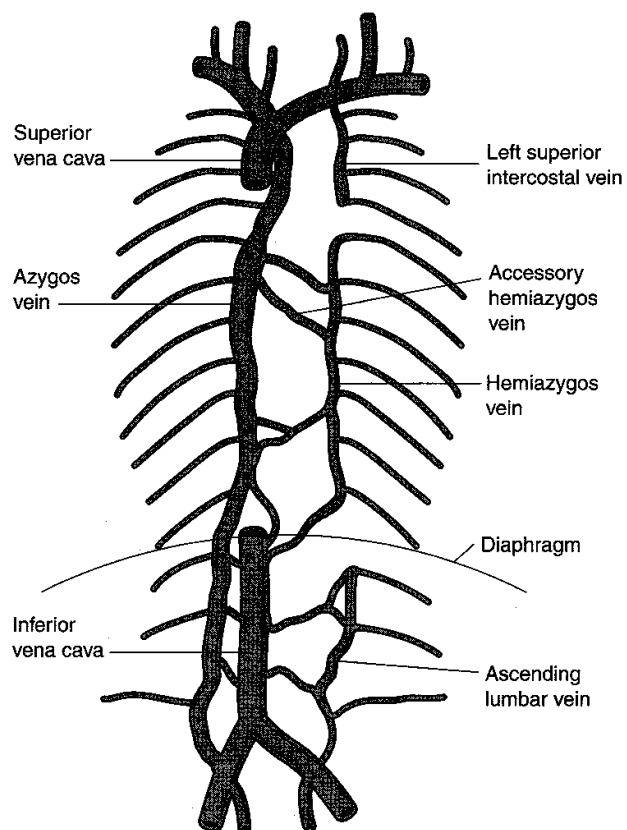


Figure III-2-14. The Azygos System of Veins

Sympathetic trunks

The sympathetic trunks are located paravertebrally, just outside the posterior mediastinum.

Greater, lesser, and least splanchnic nerves, which convey preganglionic sympathetic fibers to the preaortic ganglia of the abdomen, enter the posterior mediastinum as branches of the sympathetic trunks.

Superior Mediastinum

Thymus

The thymus usually atrophies in the adult. The remains of the thymus may be found as a fatty mass.

Superior vena cava

The superior vena cava is formed behind the right first costal cartilage by the union of the right and left brachiocephalic veins (Figure III-2-15).

It returns blood from the head, neck, and upper extremities to the right atrium of the heart.

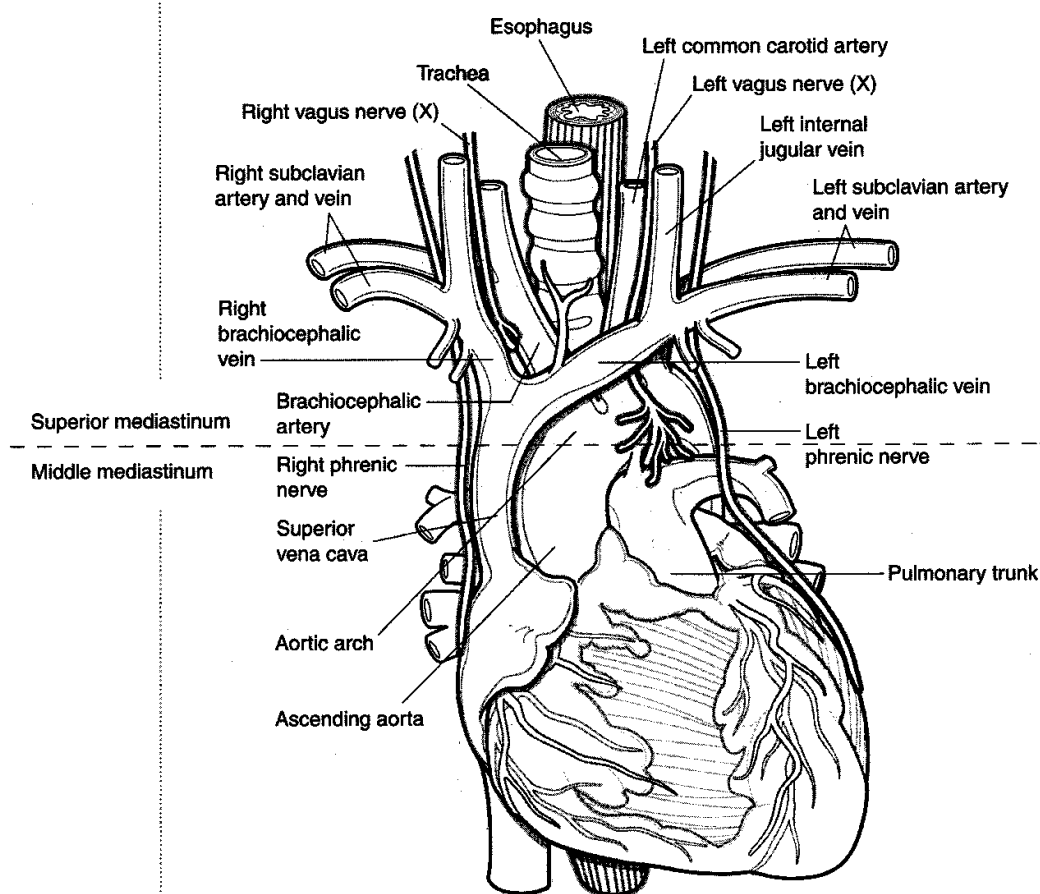


Figure III-2-15. Structures of the Mediastinum

Arch of aorta

The aortic arch begins and ends at the level of the sternal angle.

There are three branches: the brachiocephalic trunk, the left common carotid artery, and the left subclavian artery.

Vagus

Right and left vagus nerves contribute to the pulmonary and cardiac plexuses.

- In the neck, the right vagus nerve gives rise to the right recurrent laryngeal nerve, which passes under the right subclavian artery to ascend in the groove between the esophagus and the trachea to reach the larynx. **Note:** The right recurrent laryngeal nerve is not in the thorax.
- The left vagus nerve gives rise to the left recurrent laryngeal nerve, which passes under the aortic arch and ligamentum arteriosum to ascend to the larynx (Figure III-2-15).

Trachea

The trachea extends from below the cricoid cartilage (vertebral level C6) to its bifurcation (behind the sternal angle) to form the primary bronchi.

At the bifurcation is a ridge called the carina whose mucosa is very sensitive to external stimuli.

Esophagus

The esophagus extends from the cricoid cartilage (vertebral level C6) and passes through the esophageal hiatus of the diaphragm (T10).

It lies posterior to the trachea.

Thoracic duct

The thoracic duct is the largest lymphatic channel in the body.

It returns lymph to the venous circulation at the junction of the left internal jugular vein and the left subclavian vein.

HEART

Borders of the Heart

The right border is formed by the right atrium (Figure III-2-16).

The left ventricle and the auricle of the left atrium form the left border.

The superior border is formed by the right and left auricles plus the conus arteriosus of the right ventricle.

The apex is the tip of the left ventricle.

Surfaces of the Heart

The base is opposite the apex, formed mainly by the surface where the pulmonary veins enter the heart (left atrium) and by part of the right atrium.

1. The anterior surface (sternocostal) is formed primarily by the right ventricle.
2. The posterior surface is formed by the left atrium.
3. The diaphragmatic surface is formed primarily by the left ventricle.

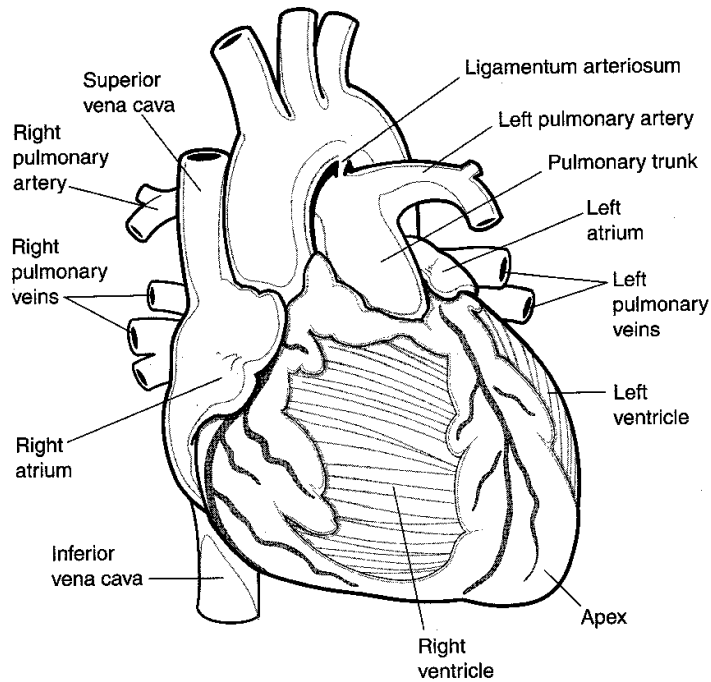


Figure III-2-16. Sternocostal View of the Heart

Surface Projections

Surface projections of the heart may be traced on the anterior chest wall (Figure III-2-16).

- The right border extends from the margin of the third right costal cartilage to the sixth right costal cartilage just to the right of the sternum.
- The inferior border extends from the sixth right costal cartilage to the fifth left intercostal space at the midclavicular line.
- The left border extends from the fifth left intercostal space to the second left costal cartilage.
- The superior border extends from the inferior margin of the second left costal cartilage to the superior margin of the third right costal cartilage.

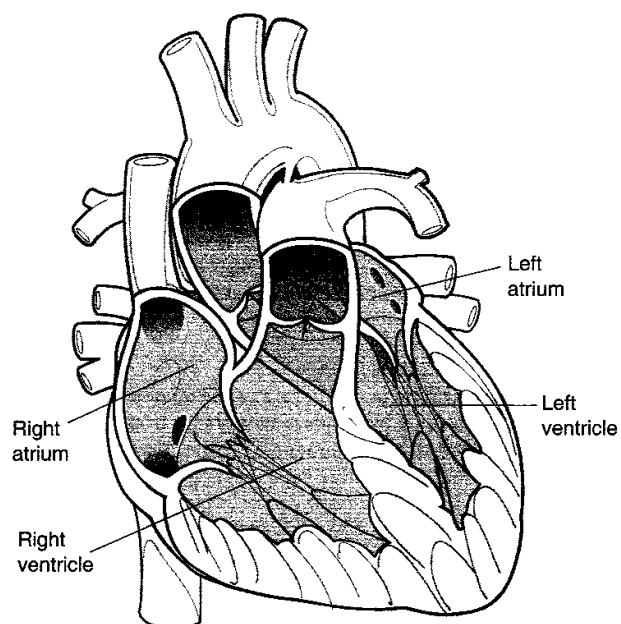


Figure III-2-17. The Chambers of the Heart

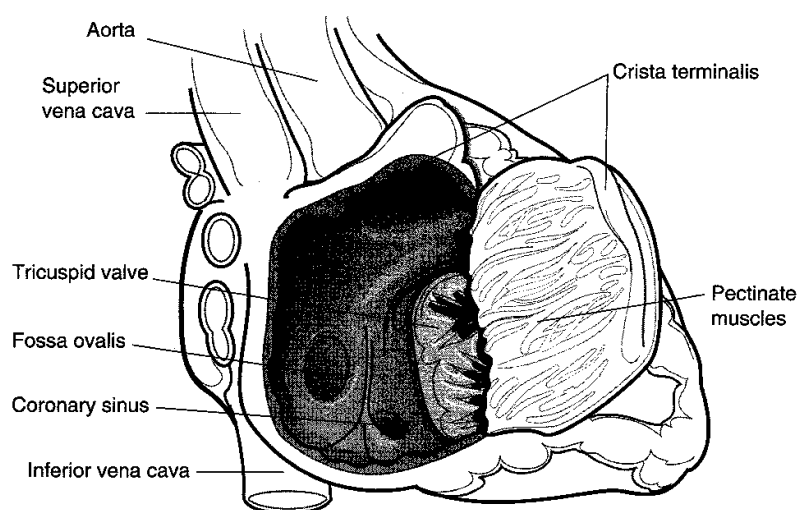


Figure III-2-18. Inside the Right Atrium

Chambers of the Heart

Right atrium

The right atrium (Figure III-2-18) receives venous blood from the entire body with the exception of blood from the pulmonary veins.

Auricle

The auricle is derived from the fetal atrium; it has rough myocardium known as pectinate muscles.

Sinus Venarum

The sinus venarum is the smooth-walled portion of the atrium, which receives blood from the superior and inferior venae cavae.

Crista Terminalis

The crista terminalis is the vertical ridge that separates the smooth from the rough portion (pectinate muscles) of the right atrium; it extends longitudinally from the superior vena cava to the inferior vena cava. The SA node is in the upper part of the crista terminalis.

Foramen Ovale

In the fetus, the FO is an opening in the interatrial septum, which allows blood entering the right atrium from the inferior vena cava to pass directly to the left side of the heart.

Tricuspid Valve

The right AV (tricuspid) valve communicates with the right ventricle.

Right ventricle

The right ventricle receives blood from the right atrium via the tricuspid valve; outflow is to the pulmonary trunk via the pulmonary semilunar valve.

Trabeculae Carneae

The trabeculae carneae are ridges of myocardium in the ventricular wall.

Papillary Muscles

The papillary muscles project into the cavity of the ventricle and attach to cusps of the AV valve by the strands of the chordae tendineae.

Chordae Tendineae

The chordae tendineae control closure of the valve during contraction of the ventricle.

Infundibulum

The infundibulum is the smooth area of the right ventricle leading to the pulmonary valve.

Left atrium

The left atrium receives oxygenated blood from the lungs via the pulmonary veins.

There are four openings: the upper right and left and the lower right and left pulmonary veins.

Bicuspid Valve

The left AV orifice is guarded by the mitral (bicuspid) valve; it allows oxygenated blood to pass from the left atrium to the left ventricle.

Left Ventricle

Blood enters from the left atrium through the mitral valve and is pumped out to the aorta through the aortic valve.

Trabeculae Carneae

The trabeculae carneae, or ridges of myocardium in the ventricular wall, are normally three times thicker than those of the right ventricle.

Papillary Muscles

The papillary muscles, usually two large ones, are attached by the chordae tendineae to the cusps of the bicuspid valve.

Aortic Vestibule

The aortic vestibule leads to the aortic semilunar valve and ascending aorta; the right and left coronary arteries originate from the right and left aortic sinuses at the root of the ascending aorta.

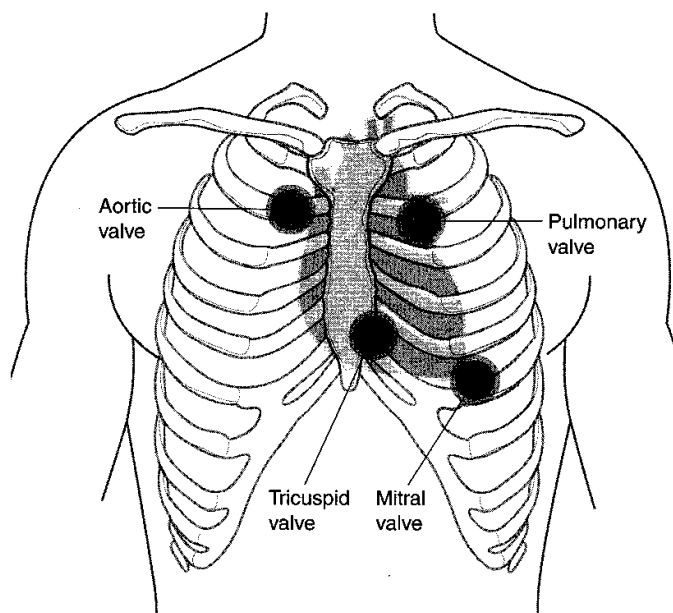


Figure III-2-19. Projection of Heart Valve Sounds on Anterior Chest Wall

Arterial Supply of the Heart

Right coronary artery

The right coronary artery arises from the ascending aorta and runs in the coronary (AV) sulcus (Figure III-2-20).

The right coronary artery primarily supplies the right atrium, the right ventricle, the sino-atrial (SA) and AV nodes.

Important branches are the SA nodal artery, the right marginal artery, and the posterior inter-ventricular artery (supplies posterior aspect of IV septum).

Left coronary artery

The left coronary artery arises from the ascending aorta. It divides into two branches, the anterior interventricular (descending) artery and the circumflex artery.

The left coronary artery supplies most of the left ventricle, the left atrium, bundle of His, and the interventricular septum (anterior aspect).

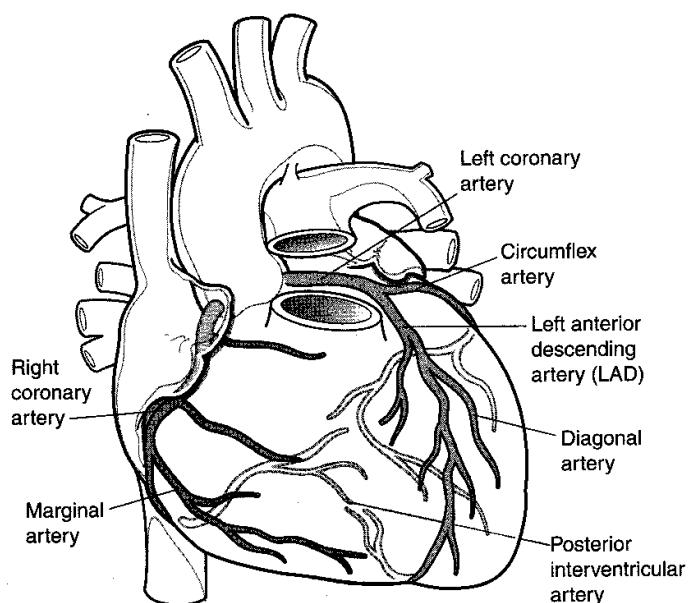


Figure III-2-20. Arterial Supply to the Heart

Venous Drainage of the Heart

Coronary sinus

The coronary sinus is the main vein of the coronary circulation; it lies in the posterior coronary sulcus. It drains to an opening in the right atrium (Figure III-2-21).

Great cardiac vein

The great cardiac vein lies in the anterior interventricular sulcus. It is the main tributary of the coronary sinus.

Middle cardiac vein

The middle cardiac vein lies in the posterior interventricular sulcus. It joins the coronary sinus.

Venae cordis minimae (thebesian veins) and anterior cardiac veins

The venae cordis minimae and anterior cardiac veins open directly to the chambers of the heart.

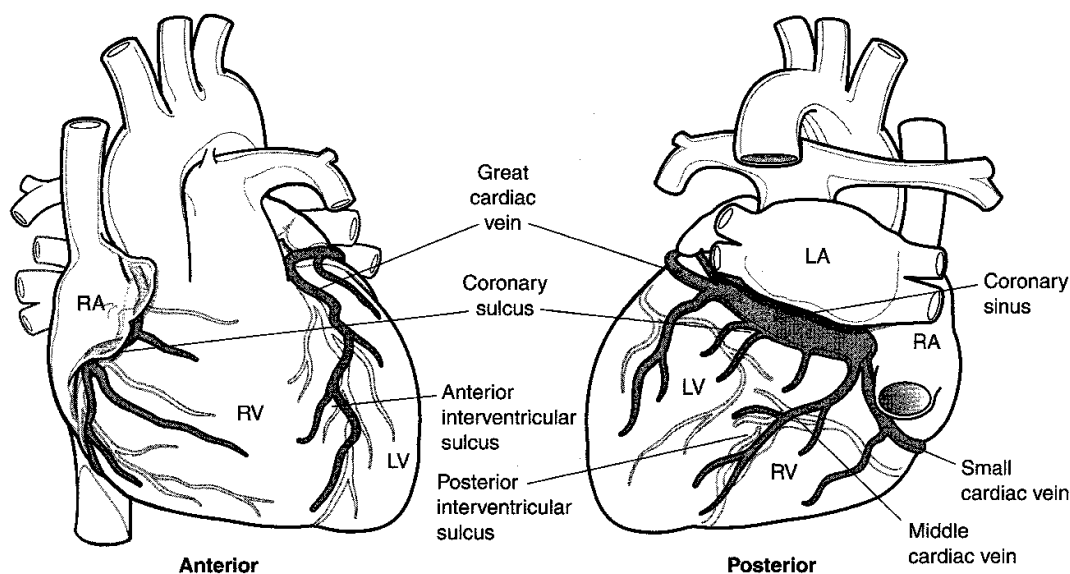


Figure III-2-21. Venous Drainage of the Heart

Conducting System of the Heart

SA node

The SA node initiates the impulse for contraction of heart muscle (and is therefore termed the "pacemaker" of the heart). It is located at the superior end of the crista terminalis, where the superior vena cava enters the right atrium (Figure III-2-22).

The SA node is supplied by the SA nodal branch of the right coronary artery.

Impulse production is speeded up by sympathetic nervous stimulation; it is slowed by parasympathetic (vagal) stimulation.

AV node

The AV node receives impulses from the SA node. The AV node is located in the interatrial septum near the opening of the coronary sinus. The AV node slows the impulse so that it reaches the ventricles after it has reached the atria.

The **bundle of His** originates in the AV node. It conducts impulses to the right and left ventricles.

In the right ventricle, the moderator band (septomarginal trabecula) contains the right bundle branch.

Impulses pass from the right and left bundle branches to the papillary muscles and ventricular myocardium.

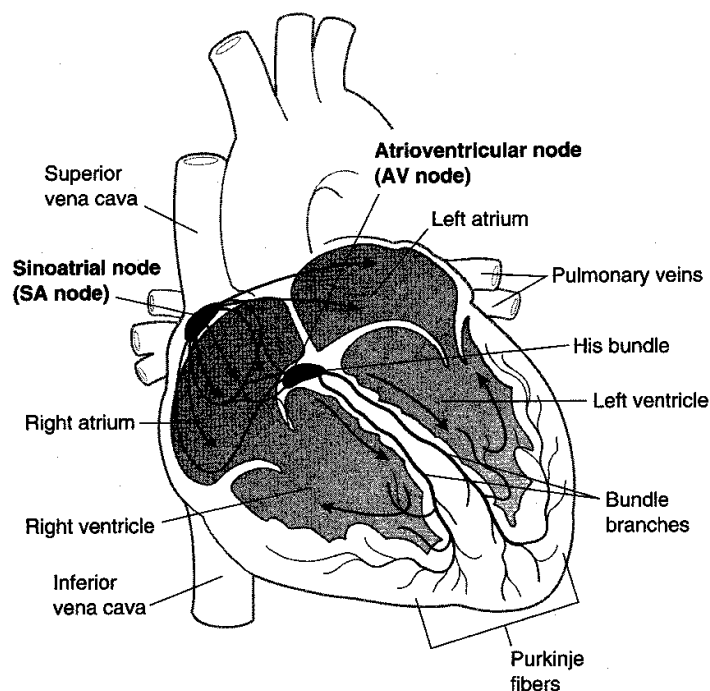


Figure III-2-22. The Cardiac Conduction System

Innervation

The cardiac plexus is a combination of sympathetic and parasympathetic (vagal) fibers.

- Sympathetic stimulation increases the heart rate.
- Parasympathetic stimulation slows the heart rate.

DIAPHRAGM

Composition

The diaphragm is composed of a **muscular portion** and a **central tendon**. It is dome shaped, and upon contraction of its muscular portion, it descends. It is innervated by the **phrenic nerves** arising from spinal cord segments C3 through C5. The muscular portion has three regions of origin.

Lumbar origin

- **Two crura**—each crus takes its origin from the bodies of the upper two (left) or three (right) lumbar vertebral bodies.
- **Medial arcuate ligament**—a thickening of the deep fascia covering the anterior surface of the psoas major. Some muscle of the diaphragm arises from this thickening.

- **Lateral arcuate ligament**—a thickening of the deep fascia covering the anterior surface of the quadratus lumborum. Some muscle of the diaphragm arises from this thickening.

Costal origin

From muscle fibers arising from the inner surfaces of the lower six ribs.

Sternal origin

From muscle fibers arising from the inner surface of the xiphoid process.

Apertures in the Diaphragm

Caval hiatus

Located to the right of the midline at the level of **T8**, within the central tendon (Figure III-2-23). Transmits the inferior vena cava and some branches of the right phrenic nerve.

Esophageal hiatus

Located to the left of the midline at the level of **T10**, within the muscle of the right crus. Transmits the esophagus and the anterior and posterior vagus nerves.

Aortic hiatus

Located in the midline at the level of **T12**, behind the two crura. Transmits the aorta, the azygos vein, and the thoracic duct.

Sternocostal hiatuses

Located at the level of **T10**, between the muscle of the sternal origin and the costal origin. Transmits the superior epigastric vessels.

Note

Structures that pass through the diaphragm without a specific hiatus include the sympathetic trunk, the thoracic splanchnic nerves, the hemiazygos vein, and most branches of the phrenic nerves.

Clinical Correlate

Pain Referral

Because the innervation to the diaphragm (motor and sensory) is primarily from C3 through C5 spinal nerves, pain arising from the diaphragm (e.g., subphrenic abscess) is referred to these dermatomes in the shoulder region.

Clinical Correlate

A **congenital diaphragmatic hernia** is a herniation of abdominal contents into the pleural cavity due to the failure of the pleuroperitoneal membranes to develop properly. The hernia is most commonly found on the left posterolateral side and causes pulmonary hypoplasia.

An **esophageal hiatal hernia** is a herniation of the stomach into the pleural cavity due to an abnormally large esophageal hiatus to the diaphragm. This condition renders the esophagogastric sphincter incompetent so that contents reflux into the esophagus.

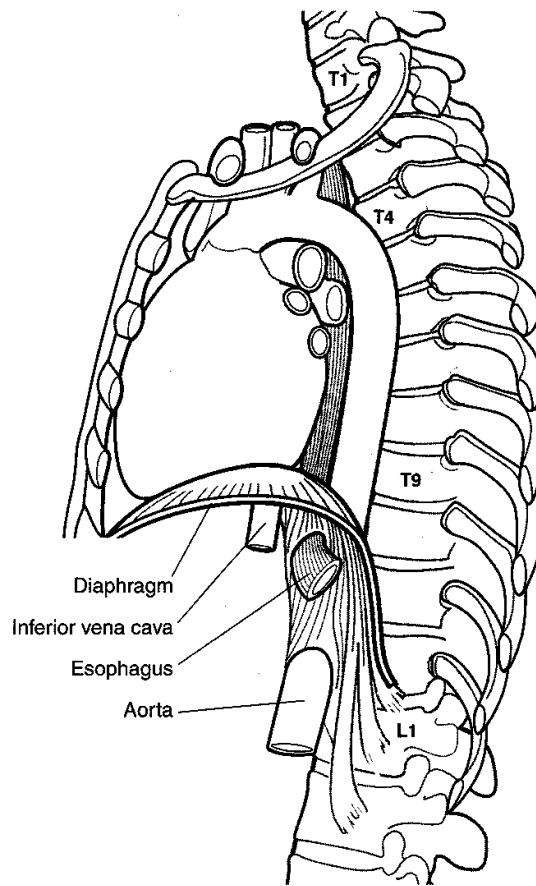


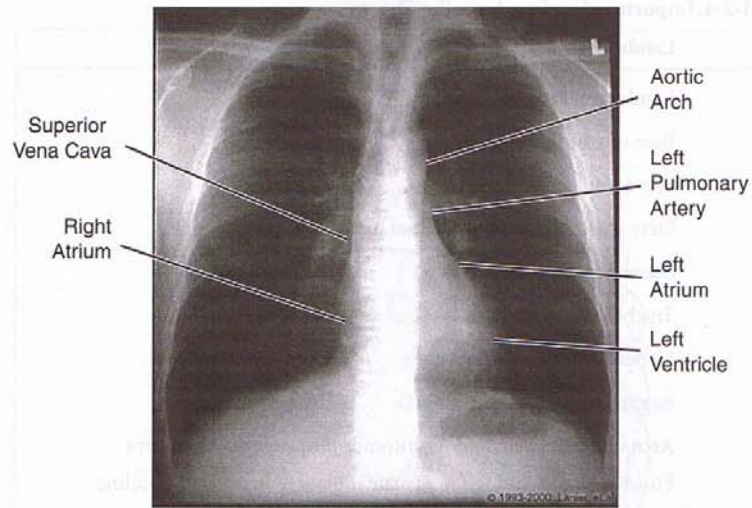
Figure III-2-23. The Diaphragm

The diaphragm is formed by the fusion of tissues from four different sources:

1. The septum transversum gives rise to the central tendon of the diaphragm.
2. The pleuroperitoneal membranes give rise to parts of the tendinous portion of the diaphragm.
3. The dorsal mesentery of the esophagus gives rise to the crura of the diaphragm.
4. The body wall contributes muscle to the periphery of the diaphragm.

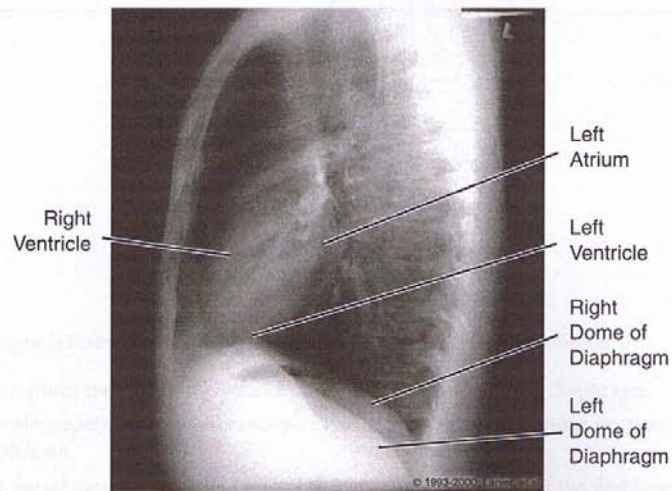
Table III-2-4. Important Landmarks in the Thorax

Level	Landmark
T2	Jugular notch
T3	Base of scapular spine Top of aortic arch
T4	Sternal angle (manubriosternal junction) Second costal cartilage Tracheal bifurcation Upper end of ascending aorta Beginning of descending aorta Arch of azygos vein and its entrance into superior vena cava Fusion of right and left mediastinal pleurae in anterior midline
T7	Inferior angle of scapula
T8	Caval hiatus
T9	Xiphoid process
T10	Esophageal hiatus
T12	Aortic hiatus



Copyright 2000 Gold Standard Multimedia, Inc. All rights reserved.

Figure III-2-24. Anterior Projection of Chest, Male



Copyright 2000 Gold Standard Multimedia, Inc. All rights reserved.

Figure III-2-25. Lateral Projection of Chest, Male

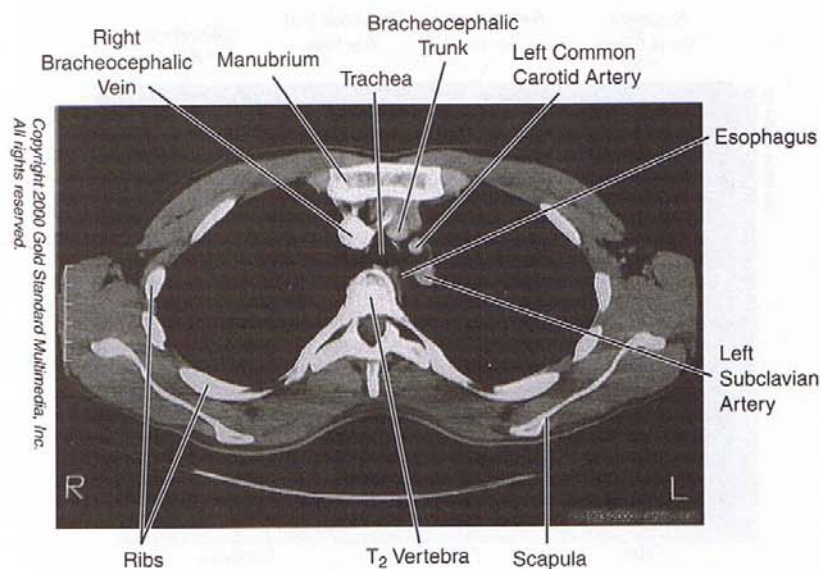


Figure III-2-26. Chest: CT, T₂

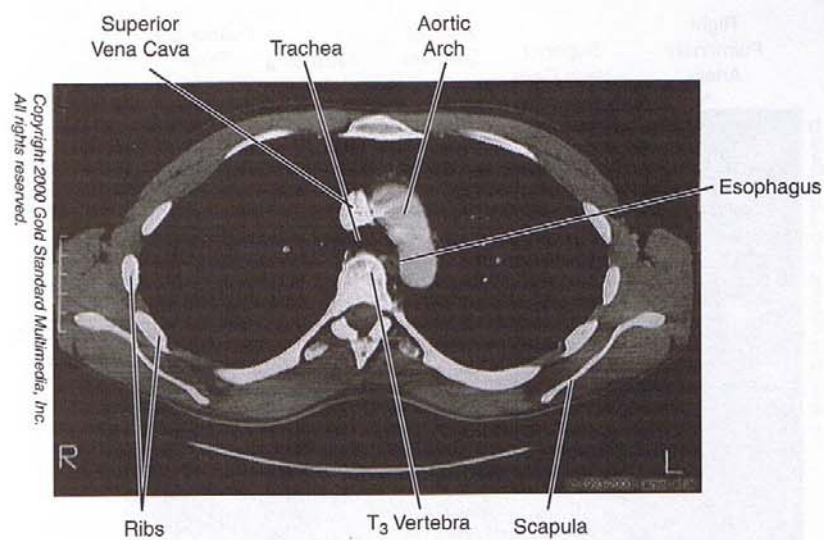


Figure III-2-27. Chest: CT, T₃

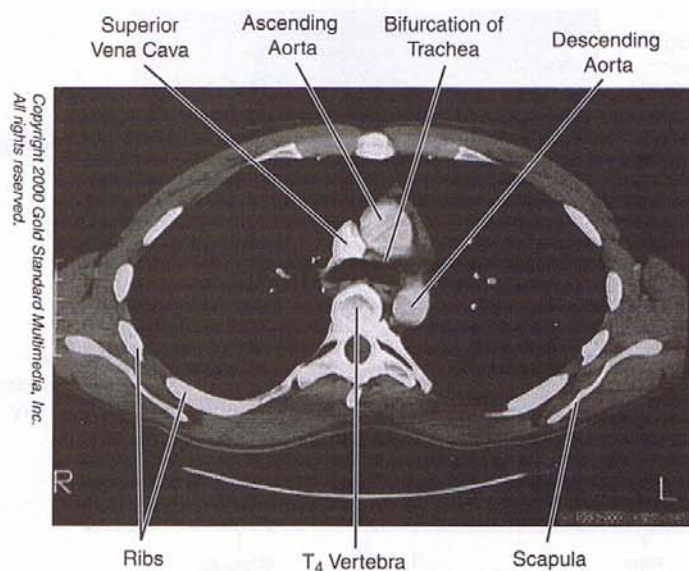


Figure III-2-28. Chest: CT, T₄

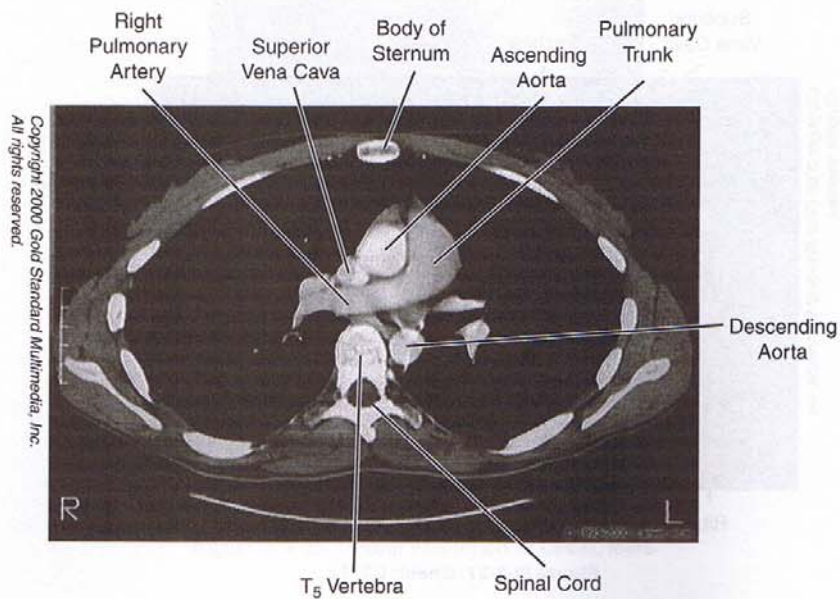


Figure III-2-29. Chest: CT, T₅

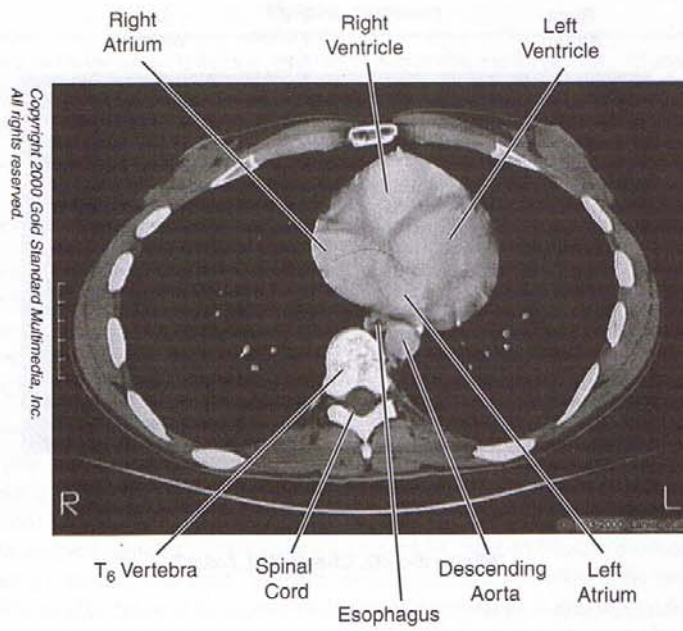


Figure III-2-30. Chest: CT, T₆

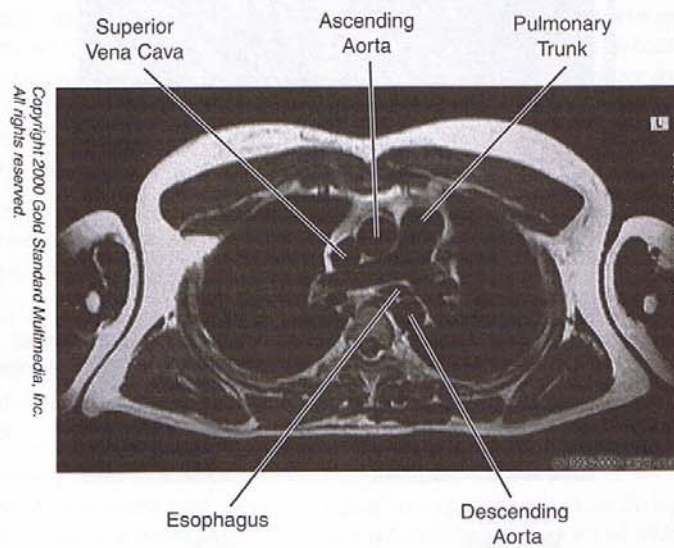


Figure III-2-31. Chest: MRI, Axial T₄

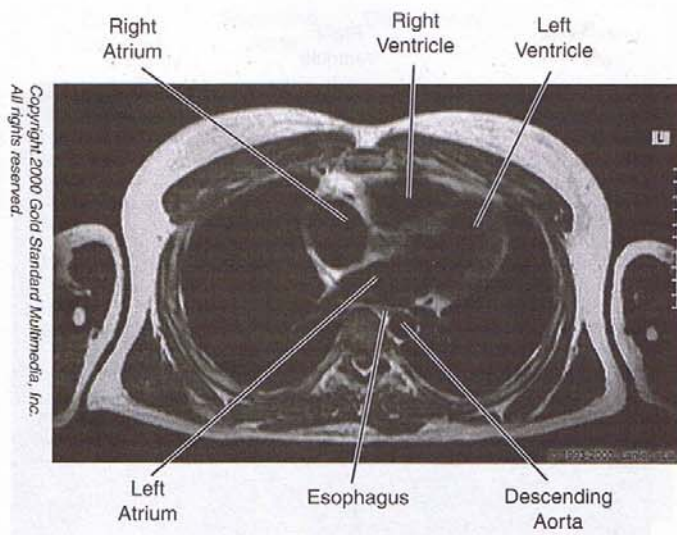


Figure III-2-32. Chest: MRI, Axial T₆

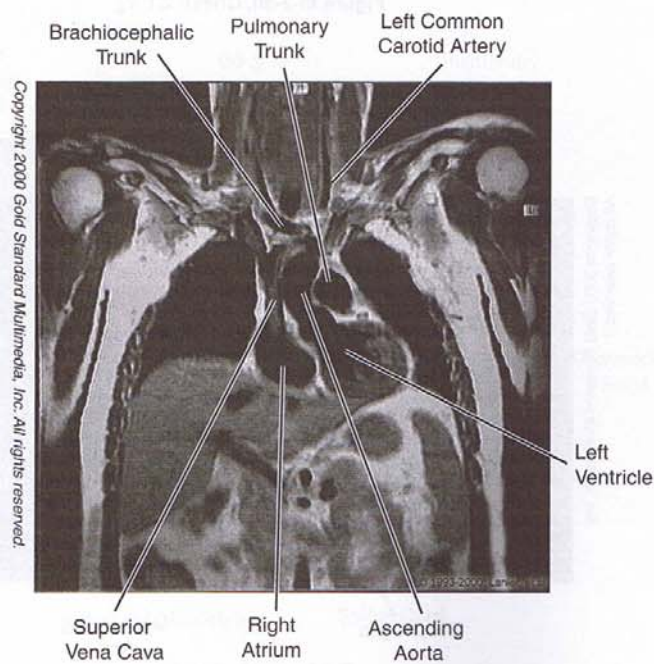


Figure III-2-33. Chest: MRI, Coronal

Chapter Summary

The chest wall is formed by 12 thoracic vertebrae, 12 pairs of ribs, and the sternum. An important landmark on the anterior chest wall is the sternal angle found where the second rib articulates with the sternum.

The respiratory system develops as an endodermal outgrowth of the foregut. The tracheoesophageal septum separates the lung buds from the foregut. Improper development of this septum will produce an abnormal communication between the trachea and esophagus, a tracheoesophageal fistula.

The lungs are surrounded by the pleura, which is divided into the parietal pleura lining the inner surface of the thoracic cavity, and the visceral pleura that is attached to the surface of the lung. Between these two layers is the pleural cavity containing a small amount of serous fluid. The lungs demonstrate costal, mediastinal, and diaphragmatic surfaces and an apex that projects through the thoracic inlet into the root of the neck. Oblique and horizontal fissures divide the lungs into lobes.

Heart development begins with the formation of a primitive heart tube, which develops from the lateral plate mesoderm in the third week. The arterial end of the heart tube is called the truncus arteriosus and will develop into the aorta and pulmonary trunk. The sinus venosus at the venous end of the heart tube will develop into the coronary sinus and the smooth part of the right atrium. The primitive atrial and ventricle chambers divide into right and left chambers following development of interatrial and interventricular septae. Ventricular septal defects result from failure of the membranous septum to develop. Failure of the foramen ovale to close at birth results in atrial septal defects. Fetal circulation involves three shunts: ductus venosus, ductus arteriosus, and the foramen ovale. After birth these shunts shut down following changes in the circulatory system.

The thoracic cavity is divided into the superior mediastinum above the plane of the sternal angle and the inferior mediastinum (anterior, middle, and posterior mediastina) below that sternal plane. The superior mediastinum contains the superior vena cava, aortic arch and its branches, trachea, esophagus, thoracic duct, and the vagus and phrenic nerves. The anterior mediastinum is anterior to the heart and contains remnants of the thymus. The middle mediastinum contains the heart and great vessels and the posterior mediastinum containing the thoracic aorta, esophagus, thoracic duct, azygos veins, and the vagus nerve. The inferior vena cava passes through the diaphragm at the caval hiatus at the level of the 8th thoracic vertebra, the esophagus through the esophageal hiatus at the 10th thoracic vertebra, and the aorta course through the aortic hiatus at the level of the 12th thoracic vertebra.

Covering the heart is the pericardium formed by an outer, tough fibrous layer and a doubled-layered serous membrane divided into parietal and visceral layers. The pericardial cavity is located between these two serous layers and includes the transverse and oblique pericardial sinuses.

The external surface of the heart consists of several borders: the right border formed by the right atrium, the left border formed by the left ventricle, the base formed by the two atria, and the apex at the tip of the left ventricle. The anterior surface is formed by the right ventricle, the posterior surface formed mainly by the left atrium, and a diaphragmatic surface is formed primarily by the left ventricle.

Arterial supply to the heart muscle is provided by the right and left coronary arteries, which are branches of the ascending aorta. The right coronary artery supplies the right atrium, the right ventricle, the sinoatrial and atrioventricular nodes, and parts of the left atrium and left ventricle. The distal branch of the right coronary artery is the posterior interventricular artery that supplies, in part, the posterior aspect of the interventricular septum.

(Continued)

Chapter Summary (continued)

The left coronary artery supplies most of the left ventricle, the left atrium, and the anterior part of the interventricular septum. The two main branches of the left coronary artery are the anterior interventricular artery and the circumflex artery.

Venous drainage of the heart is provided primarily by the great cardiac and middle cardiac veins and the coronary sinus, which drains into the right atrium.

Sympathetic innervation increases the heart rate while the parasympathetics slows the heart rate. These autonomic fibers fire upon the conducting system of the heart. The sinoatrial node initiates the impulse for cardiac contraction. The atrioventricular node receives the impulse from the sinoatrial node and transmits that impulse to the ventricles through the bundle of His. The bundle divides into the right and left bundle branches and Purkinje fibers to the two ventricles.

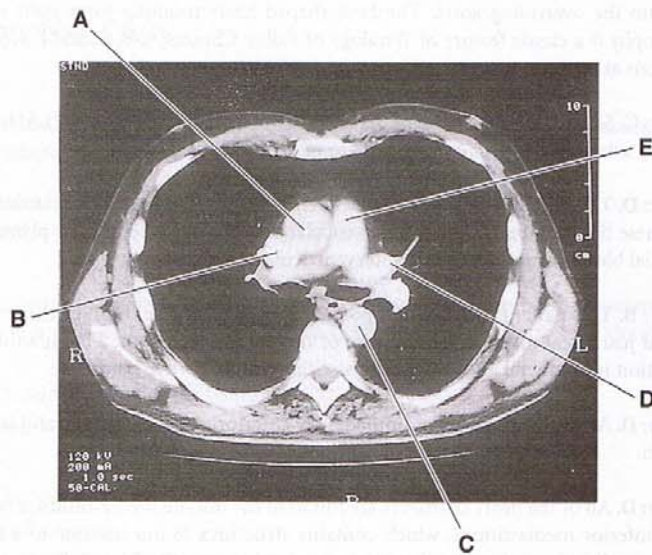
Review Questions

- During fetal life, in which of the following structures is the percent hemoglobin/oxygen saturation level of fetal blood the lowest?
 - Ductus arteriosus
 - Left ventricle
 - Inferior vena cava
 - Umbilical vein
 - Right atrium
 - Descending aorta
- An infant born 2 weeks premature presents with a machine-like diastolic and systolic murmur heard over the left sternoclavicular joint. What will be observed in the infant as a result of this defect?
 - There will be blood flow from the arch of the aorta into the pulmonary trunk through the defect.
 - The pulmonary trunk will have a significantly smaller diameter than the ascending aorta.
 - The infant will be cyanotic at birth.
 - There will be blood flow from the left ventricle to the right ventricle through the defect.
 - The aorta overrides the interventricular septum and collects blood from both the right and left ventricles.
- Your patient presents with pneumonia. Examination of lateral-view chest films reveals that the pneumonia is localized just inferior to the horizontal fissure. Where would the pneumonia most likely be localized?
 - Inferior lobe of the left lung
 - Inferior lobe of the right lung
 - Middle lobe of the right lung
 - Middle lobe of the left lung
 - Superior lobe of the left lung

4. A mother brings her 5-year-old to the ER with the complaint that her child's lips turn blue after exertion and that the child gasps for air. The mother reveals that the child often assumes a squatting position when the lips are bluish. Echocardiography reveals a boot-shaped heart indicative of right ventricular hypertrophy. Which of the following is the most likely congenital defect of this infant?
- (A) Ostium secundum defect
 - (B) Patent ductus arteriosus
 - (C) Mitral valve stenosis
 - (D) Anterior and superior displacement of the aortopulmonary septum
 - (E) Coarctation of the aorta
5. A 56-year-old man is brought to the emergency room by his wife. The patient complains of intense chest pain. Over a period of years, the patient has exhibited pains radiating down the medial aspect of the left arm following exertion. The patient is in shock with low blood pressure and diminished radial pulses. Heart sounds are weak. Despite administration of oxygen and stimulants, the patient expires 3 hours after administration. Autopsy would most likely reveal an occlusion of which coronary blood vessel at its origin?
- (A) Right coronary artery
 - (B) Posterior interventricular artery
 - (C) Anterior interventricular artery
 - (D) Left coronary artery
 - (E) Circumflex artery
6. A patient experiences heart block as a result of occlusion of branches of the anterior interventricular branch of the left coronary artery. Which structure was most likely affected by the vascular insult?
- (A) Cardiac plexus
 - (B) Sinoatrial node
 - (C) Atrial node
 - (D) Bundle of His
 - (E) Vagal branches
7. A 27-year-old male worker comes to the hospital complaining of fatigue upon exertion. He had been diagnosed previously with high blood pressure. An exam reveals elevated pressure in both common carotid arteries but diminished pulses in both femoral arteries. Radiology reveals a hypertrophic left ventricle, a stenosis of the aorta, and bilateral erosion of the lower thoracic ribs. The site of the aortic narrowing is most likely
- (A) between the brachiocephalic trunk and the left common carotid artery
 - (B) immediately distal to the left subclavian artery
 - (C) in the ascending aorta
 - (D) between the left common carotid artery and the left subclavian artery
 - (E) between the right common carotid artery and the right subclavian artery

8. A 45-year-old housewife is admitted to the hospital. She is having great difficulty swallowing and has lost 20 pounds in the last 3 months because of reliance on a liquid diet. She has become hoarse and frequently spits up bloody sputum. A barium swallow reveals cancer of the esophagus at the level of the T3 vertebra. If there is an anterior expansion of the carcinoma, which nearby structure is most likely to be invaded?
(A) Left atrium
(B) Superior vena cava
(C) Right ventricle
(D) Trachea
(E) Ascending aorta
9. In a horizontal section extending through the superior mediastinum, which of the following structures will not be seen?
(A) Arch of the aorta
(B) Superior vena cava
(C) Esophagus
(D) Left atrium
(E) Trachea
10. In postnatal life, the right atrium contains the fossa ovalis, a shallow depression in the interatrial septum. Which embryonic structure forms the floor of the fossa?
(A) Septum secundum
(B) Septum primum
(C) Endocardial cushion
(D) Bulbus cordis
(E) AV node
11. Which of the following structures does not become subdivided by a septum during fetal heart development?
(A) Truncus arteriosus
(B) Primitive atrium
(C) Sinus venosus
(D) Bulbus cordis
(E) Primitive ventricle
12. A 56-year-old male patient presents with a sliding hiatal hernia in the diaphragm. Which other structure might be compressed as it courses through the same opening in the diaphragm?
(A) Right phrenic nerve
(B) Right greater splanchnic nerve
(C) Thoracic duct
(D) Azygous vein
(E) Right vagal branches

13. During a thoracocentesis to remove pleural exudate, a patient feels a twinge of pain as the needle enters the pleural sac. Which nerve fibers carried the painful sensations?
- (A) Intercostal nerve
 - (B) Greater splanchnic nerve
 - (C) Phrenic nerve
 - (D) Iliohypogastric nerve
 - (E) Vagus nerve
14. Which of the following labeled structures drains into a remnant of the sinus venosus from the fetal heart?



- (A) A
- (B) B
- (C) C
- (D) D
- (E) E

Answers and Explanations

1. **Answer: A.** In the ductus arteriosus, the percent hemoglobin/oxygen saturation level of fetal blood is the lowest (50%) of the choices because most of the blood in the ductus arteriosus comes from the superior vena cava by way of the right ventricle and pulmonary trunk. The highest percent hemoglobin/oxygen saturation level of fetal blood is in the umbilical vein (80%). At each successive point in the primary fetal circulation pathway—inferior vena cava, right atrium, left ventricle, and then descending aorta—the saturation level falls to 60% due to dilution by deoxygenated blood.

2. **Answer: A.** There will be blood flow from the arch of the aorta into the pulmonary trunk through the defect, which results from a patent ductus arteriosus. PDAs are frequently seen in premature infants and present with machine-like murmurs. PDAs present with left to right shunts of blood, a condition that is acyanotic at birth. Choices B and E are two characteristics of Tetralogy of Fallot, which is a cyanotic condition; choice D is a feature of a ventricular septal defect.
3. **Answer: C.** Only the right lung has a horizontal fissure. The presence of pneumonia just inferior to this fissure localizes it to the middle lobe between the horizontal and oblique fissures.
4. **Answer: D.** The anterior and superior displacement of the aorticopulmonary septum is the cause of Tetralogy of Fallot. The result is a right-to-left shunt of blood from the right ventricle into the overriding aorta. The boot-shaped heart resulting from right ventricular hypertrophy is a classic feature of Tetralogy of Fallot. Choices A, B, C, and E are acyanotic conditions at birth.
5. **Answer: C.** Statistically, occlusion of the anterior interventricular branch (LAD) of the left coronary artery is the most common cause of an acute MI.
6. **Answer: D.** The bundle of His is the most likely to be affected by the vascular insult in this case. These fibers course in the interventricular septum and receive their primary source of arterial blood from the anterior interventricular artery.
7. **Answer: B.** This patient has the adult postnatal form of a coarctation of the aorta, which is found just distal to the site of closure of the ductus arteriosus. The infantile form of coarctation is preductal and is typically associated with Turner syndrome.
8. **Answer: D.** At T3, the trachea lies immediately anterior to the esophagus and is subject to invasion.
9. **Answer: D.** All of the heart chambers are found in the middle mediastinum, a subdivision of the inferior mediastinum, which contains structures found inferior to a horizontal plane extending from the sternal angle to the disc between the T4 and T5 vertebrae.
10. **Answer: B.** The septum primum forms the floor of the fossa after it fuses with the septum secundum to complete the interatrial septum.
11. **Answer: C.** All other dilatations of the heart tube develop a septum to divide them into a right side structure and a left side structure.
12. **Answer: E.** The right and left vagal branches course through the esophageal hiatus with the esophagus. All other structures traverse the diaphragm through the aortic hiatus (choices C and D), the hiatus for the inferior vena cava (choice A), or through a crus (choice B).
13. **Answer: A.** Intercostal nerves innervate costal parietal pleura; the phrenic nerves innervate mediastinal pleura. The greater splanchnic nerves are preganglionic sympathetic nerves destined to synapse in the celiac ganglion for the foregut; the vagus nerve carries visceral sensory fibers other than those for pain, and the iliohypogastric nerve innervates the abdominal skin, musculature, and parietal peritoneum of the abdominal wall.
14. **Answer: B.** The right atrium incorporates the sinus venosus during fetal life; the superior vena cava drains into the right atrium.

Abdomen, Pelvis, and Perineum

3

ANTERIOR ABDOMINAL WALL

Abdominopelvic Cavity

Osteology

Unlike the thoracic wall, the bony support of the abdomen is minimal, consisting only of the lumbar vertebrae and portions of the pelvis (the ilium and the pubis).

Lumbar Vertebrae

There are five lumbar vertebrae, L1 through L5 (Figure III-3-1).

Ilium

The ilium is part of the hipbone or os coxae. The osteology of this bone is presented in detail in the section on the pelvis. Only the landmarks pertinent to the anterior abdominal wall are listed here.

- Anterior superior iliac spine (ASIS)

- Iliac fossa

- Iliac crest

- Iliac tubercle

Pubis (part of os coxae)

- Pubic tubercle

- Pubic crest

- Pubic symphysis

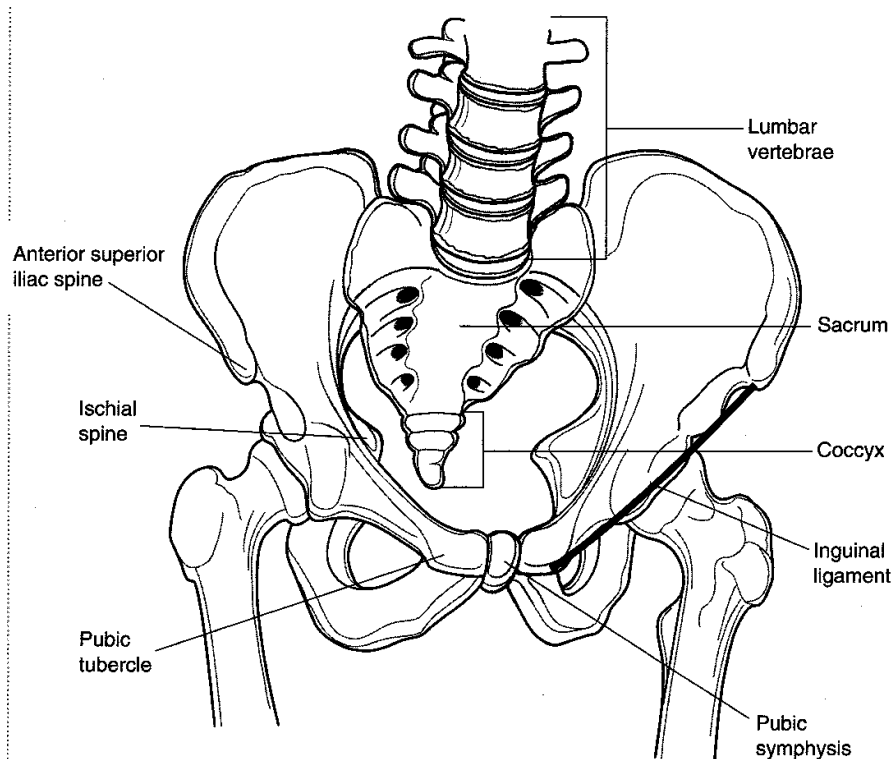


Figure III-3-1. The Abdominopelvic Cavity

Surface anatomy

Linea Alba

The linea alba is a shallow groove that runs vertically in the median plane from the xiphoid to the pubis. It separates the right and left rectus abdominis muscles.

Linea Semilunaris

The linea semilunaris is a curved line defining the lateral border of the rectus abdominis, a bilateral feature.

Inguinal Groove

The inguinal groove indicates the site of the inguinal ligament, the rolled-over, free border of the external oblique aponeurosis. It separates the abdomen superiorly from the lower limb inferiorly. The inguinal ligament extends from the ASIS to the pubic tubercle (Figure III-3-2).

Planes and regions

There are four planes to define nine regions of the abdomen (Figure III-3-2).

Subcostal Plane

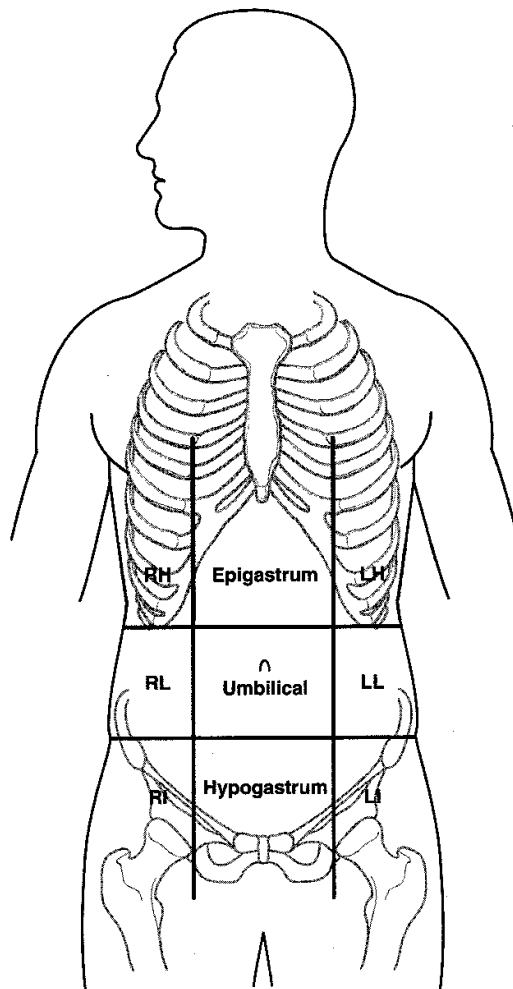
The subcostal plane (horizontal) passes through the inferior margins of the 10th costal cartilages.

Transtubercular Plane

The transtubercular plane (horizontal) passes through the iliac tubercles.

Midclavicular Lines

The midclavicular lines (vertical) are the two planes that pass from the midpoint of the clavicle to the midpoint of the inguinal ligament on each side.



Note

Definition of abbreviations for Figure III-3-2 (*left*):

RH: right hypochondrium

LH: left hypochondrium

RL: right lumbar

LL: left lumbar

RI: right inguinal

LI: left inguinal

Figure III-3-2. Regions of the Abdomen

In A Nutshell

Layers of the anterior abdominal wall

1. Skin
2. Superficial fascia
 - a. Camper (fatty)
 - b. Scarpa (fibrous)
3. External oblique
4. Internal oblique
5. Transversus abdominis
6. Transversalis fascia
7. Extraperitoneal
8. Parietal peritoneum

Fascial layers

Superficial Fascia

Camper fascia is subcutaneous and variable in thickness owing to the presence of fat.

Scarpa fascia is a deeper membranous layer devoid of fat, and it fuses to the fascia lata of the thigh below the inguinal ligament. It is continuous with the dartos fascia of the scrotum or the labia majora, and Colles fascia of the perineum.

Deep Fascia

The deep fascia is the investing fascia of the abdominal musculature.

Muscles

External Oblique

The fibers run anteriorly and inferiorly (i.e., the hands-in-pockets direction like the external intercostal layer in the thorax; Figure III-3-3).

As fibers pass medially, they become aponeurotic and contribute to the anterior layer of the rectus sheath.

Inferiorly, the free border of the external oblique aponeurosis forms the inguinal ligament.

The superficial inguinal ring is an opening in the external oblique aponeurosis just superior and lateral to the pubic tubercle.

In men, the external oblique fascia gives rise to the external spermatic fascia of the spermatic cord.

Internal Oblique

The fibers run posteriorly and inferiorly at right angles to those of the external oblique like those of the internal intercostal layer in the thorax.

As the fibers pass medially, they become aponeurotic and split to contribute to the rectus sheath.

Inferiorly, these fibers contribute to the formation of the conjoint tendon.

In men, the internal oblique layer gives rise to the middle spermatic fascia and the cremaster muscle of the spermatic cord.

Transversus Abdominis

The muscle fibers run horizontally. As the fibers pass medially, they become aponeurotic and contribute to the posterior rectus sheath.

Inferiorly, the fibers join with those of the internal oblique to form the conjoint tendon.

Rectus Abdominis

The fibers run vertically between the pubic symphysis and the xiphoid process.

The right and left recti muscles are separated medially by the linea alba.

The rectus sheath is formed by aponeurotic fibers of three lateral muscle layers.

- The arcuate line is located midway between the umbilicus and pubis. It is a landmark for the change in disposition of the aponeurotic fibers. Above the arcuate line, posterior and anterior layers of the rectus sheath have equal thickness; below it, all aponeurotic fibers run anterior to the rectus abdominis.
- Superior and inferior epigastric vessels travel in the posterior layer of the rectus sheath.

Transversalis fascia

The transversalis fascia lines the abdominal cavity. It forms the posterior layer of the rectus sheath below the arcuate line and the internal spermatic fascia of the spermatic cord.

The deep inguinal ring begins as an outpouching of transversalis fascia just lateral to where the inferior epigastric vessels intersect the inguinal ligament.

The transversalis fascia is separated from the peritoneum by a layer of fatty areolar connective tissue.

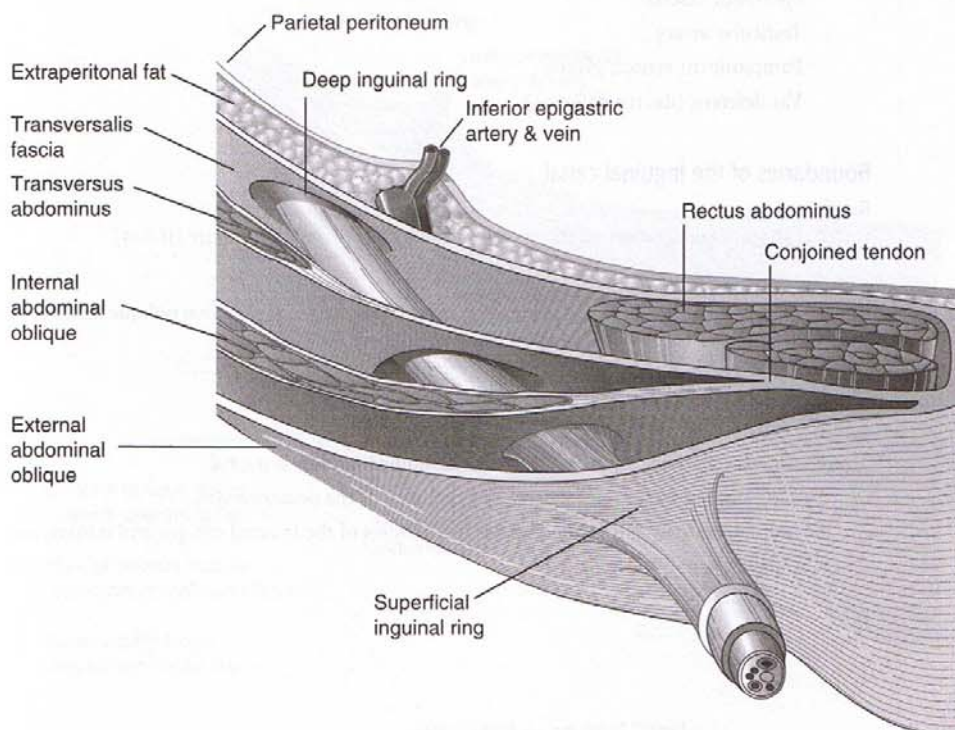


Figure III-3-3. Layers of Anterolateral Abdominal Wall

Nerves, blood vessels, and lymphatics

Innervation of the skin and musculature of the anterior abdominal wall is via branches of the ventral primary rami of the lower six thoracic spinal nerves (includes the subcostal nerve), plus the iliohypogastric and ilioinguinal branches of the ventral primary rami of L1.

The major arterial blood supply to the anterior wall is derived from the superior epigastric branch of the internal thoracic artery as well as the inferior epigastric and the deep circumflex iliac branches of the external iliac artery.

Venous drainage from the anterior wall is to the superficial epigastric, the lateral thoracic veins superiorly, and the great saphenous vein inferiorly.

Lymph from tissues of the anterior wall drains to axillary nodes superiorly and to superficial inguinal nodes inferiorly.

Inguinal Canal

Contents

Female: Round ligament and ilioinguinal nerve

Male: Spermatic cord and ilioinguinal nerve. Spermatic cord includes:

- Spermatic fascias
- Testicular artery
- Pampiniform venous plexus
- Vas deferens (ductus deferens)

Boundaries of the inguinal canal

Roof

Internal abdominal oblique and the transverse abdominus muscles (Figure III-3-4).

Anterior Wall

Aponeurosis of the external abdominal oblique and the internal abdominal oblique muscle.

Floor

Inguinal ligament (part of the aponeurosis of the external oblique).

Posterior Wall

Transversalis fascia (weak area) is lateral and conjoined tendon is medial.

The conjoined tendon reinforces the medial part of the posterior wall.

The conjoined tendon is formed by the aponeuroses of the internal oblique and transversus abdominus muscles.

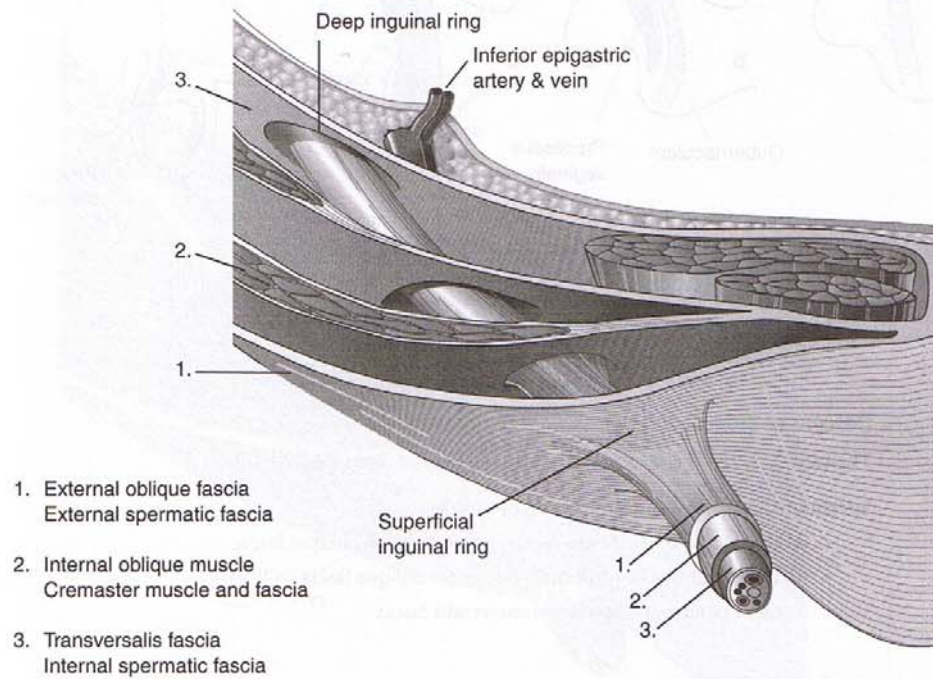


Figure III-3-4. Inguinal Canal

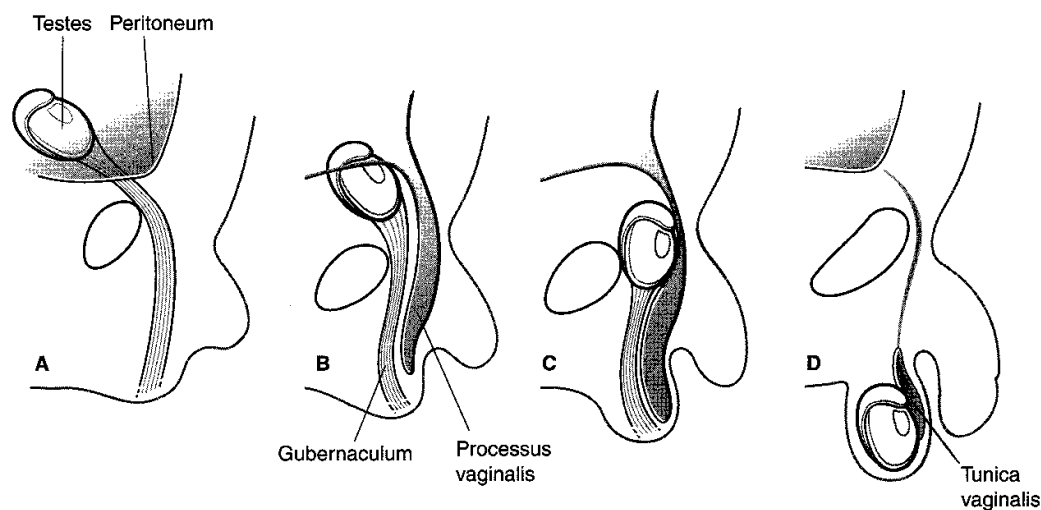


Figure III-3-5. Descent of the Testes

Clinical Correlate

Both **direct** and **indirect** inguinal hernias pass through the **superficial** inguinal ring.

Only **indirect** inguinal hernias pass through the deep inguinal ring.

Direct inguinal hernias usually pass through the inguinal triangle:

Lateral border: inferior epigastric vessels

Medial border: rectus femoris

Inferior border: inguinal ligament

Descent of the testes

The tunica vaginalis is a remnant of parietal peritoneum (Figure III-3-5):

Spermatic fascia—an abdominal wall derivative

- **External spermatic fascia**—external abdominal oblique fascia
- **Cremasteric fascia**—internal abdominal oblique fascia
- **Internal spermatic fascia**—transversalis fascia

Groin Hernias

Inguinal hernias

The most common type of hernia in men and women (Figure III-3-6):

- **Direct**: emerges through the posterior wall of the inguinal canal medial to the inferior epigastric vessels.
- **Indirect**: passes through the deep ring lateral to the inferior epigastric vessels, courses through the inguinal canal. A persistent process vaginalis often results in a congenital indirect inguinal hernia.

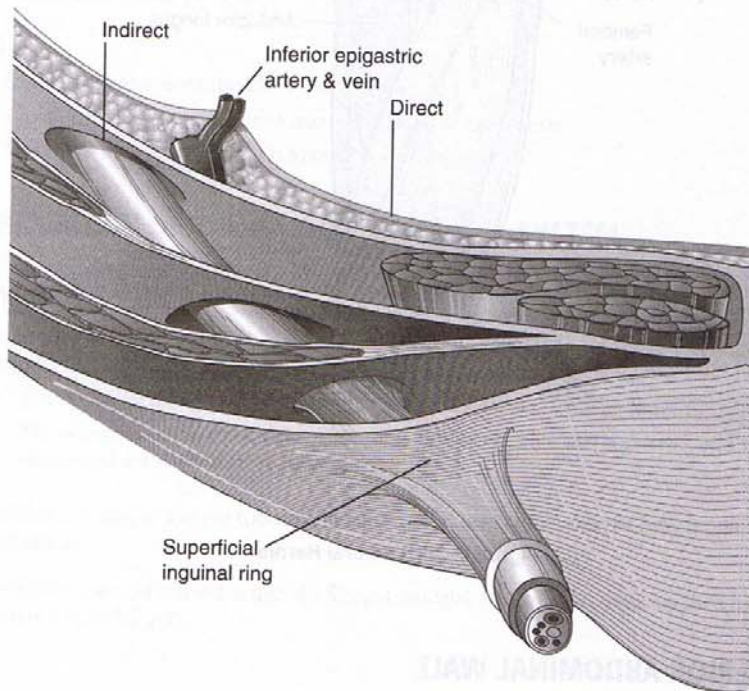


Figure III-3-6. Inguinal Hernia

Femoral hernias

Most often occur in women (Figure III-3-7).

Clinical Correlate

Inguinal hernias pass **above** the inguinal ligament.

Femoral hernias pass **below** the inguinal ligament.

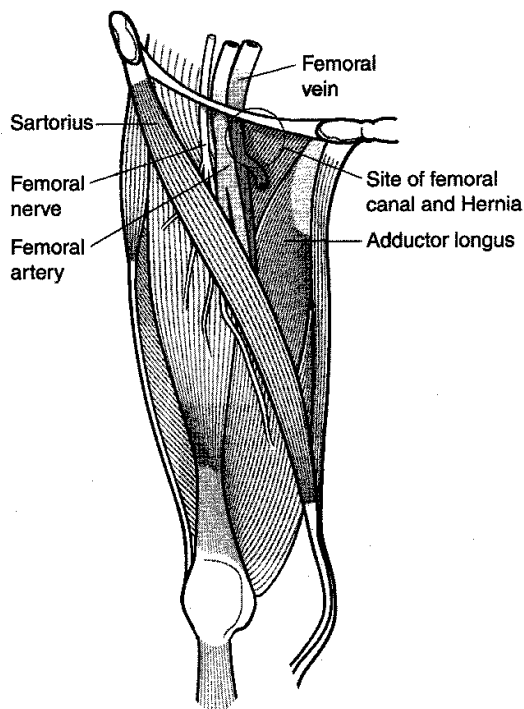


Figure III-3-7. Femoral Hernia

POSTERIOR ABDOMINAL WALL

The posterior abdominal wall is located behind the posterior layer of the parietal peritoneum.

Osteology

The bony structure of the posterior wall includes many of the same features as the anterior wall of the abdomen and bony landmarks from the thorax and the lower limb.

- Five lumbar vertebrae (L1 through L5)
- Iliac crest
- Iliac fossa
- Twelfth pair of ribs
- Lesser trochanter of femur

Muscles

Quadratus lumborum

The quadratus lumborum extends upward from the iliac crest to the inferior border of the 12th rib. It stabilizes the 12th rib during inspiration.

Psoas major

The psoas major arises from the transverse processes of the lumbar vertebrae.

Insertion, along with iliacus, is on the lesser trochanter of the femur.

It is the chief flexor of the hip.

Iliacus

The iliacus originates from the iliac fossa.

It joins with the psoas major to insert on the lesser trochanter.

Together with psoas major, it is known as the iliopsoas.

EMBRYOLOGY OF THE GASTROINTESTINAL SYSTEM

Primitive Gut Tube

The primitive gut tube is formed by incorporation of the yolk sac into the embryo during cranial-caudal and lateral folding (Figure III-3-8).

- The epithelial lining and glands of the mucosa are derived from **endoderm**.
- The lamina propria, muscularis mucosae, submucosa, muscularis externa, and adventitia/serosa are derived from **mesoderm**.

The epithelial lining of the gut tube proliferates rapidly and obliterates the lumen followed by recanalization.

The primitive gut tube is divided into the foregut, midgut, and hindgut, each supplied by a specific artery (Table III-3-1).

Table III-3-1. Adult Structures Derived From Each of the Three Divisions of the Primitive Gut Tube

Foregut (Celiac Trunk)	Midgut (Superior Mesenteric Artery)	Hindgut (Inferior Mesenteric Artery)
Esophagus	Duodenum 2nd, 3rd, 4th part	Transverse colon (distal third)
Stomach	Jejunum	Descending colon
Duodenum 1st and 2nd parts	Ileum	Sigmoid colon
Liver	Cecum	Rectum
Pancreas	Appendix	Anal canal (upper part)
Biliary apparatus	Ascending colon	
Gall bladder	Transverse colon (proximal two thirds)	
Pharyngeal pouches*		
Lungs*		
Thyroid*		

* These are derivatives of the primitive gut tube but not part of the gastrointestinal tract per se.

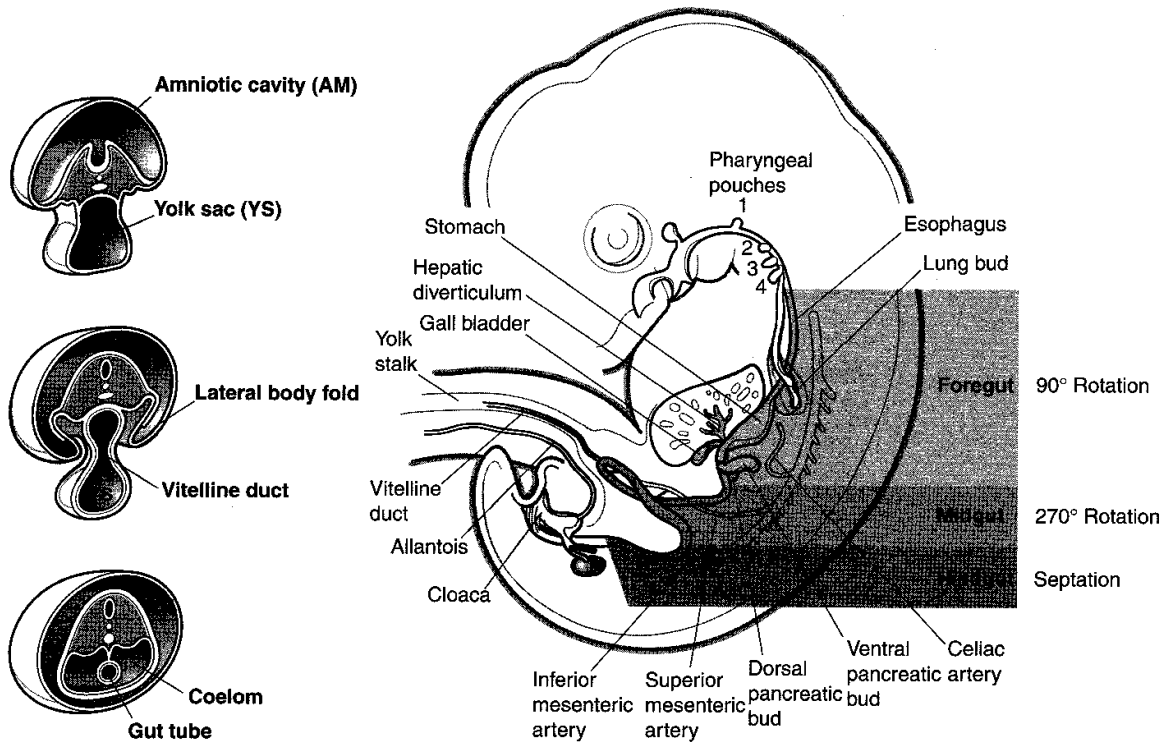


Figure III-3-8. Development of the Gastrointestinal tract

Hypertrophic Pyloric Stenosis

Occurs when the muscularis externa hypertrophies, causing a narrow pyloric lumen. This condition is associated with projectile, nonbilious vomiting and a small knot at the right costal margin.

Extrahepatic Biliary Atresia

Occurs when the lumen of the biliary ducts is occluded owing to incomplete recanalization. This condition is associated with jaundice, white-colored stool, and dark-colored urine.

Annular Pancreas

Occurs when the ventral and dorsal pancreatic buds form a ring around the duodenum, thereby causing an obstruction of the duodenum.

Duodenal Atresia

Occurs when the lumen of the duodenum is occluded owing to failed recanalization. This condition is associated with polyhydramnios, bile-containing vomitus, and a distended stomach.

Omphalocele

Occurs when the midgut loop fails to return to the abdominal cavity, forming a light gray shiny sac at the base of the umbilical cord filled with loops of small intestine.

Ileal (Meckel) Diverticulum

Occurs when a remnant of the vitelline duct persists, thereby forming a blind pouch on the antimesenteric border of the ileum. This condition is often asymptomatic but occasionally becomes inflamed if it contains ectopic gastric, pancreatic, or endometrial tissue, which may produce ulceration.

Vitelline Fistula

Occurs when the vitelline duct persists, thereby forming a direct connection between the intestinal lumen and the outside of the body at the umbilicus. This condition is associated with drainage of meconium from the umbilicus.

Malrotation of Midgut

Occurs when the midgut undergoes only partial rotation and results in abnormal position of abdominal viscera. This condition may be associated with **volvulus** (twisting of intestines).

Colonic Aganglionosis (Hirschsprung Disease)

Results from the failure of neural crest cells to form the myenteric plexus in the sigmoid colon and rectum. This condition is associated with loss of peristalsis, fecal retention, and abdominal distention.

ABDOMINAL CAVITY

Liver

The hepatic diverticulum evaginates from the endodermal lining of the ventral wall of the gut tube in the region of the second portion of the duodenum. This diverticulum enters the ventral mesentery. The distal end of the diverticulum becomes the liver and gall bladder; the proximal part becomes the biliary duct system. The portion of the ventral mesentery between the liver and gut tube becomes the lesser omentum, and the portion between the liver and ventral body wall becomes the falciform ligament.

Pancreas

The pancreas develops from two pancreatic diverticula (buds), which evaginate from the endodermal lining of the gut tube in the region of the second portion of the duodenum. The dorsal pancreatic bud grows into the dorsal mesentery. The ventral pancreatic bud initially grows into the ventral mesentery but subsequently leaves the ventral mesentery, rotates around the gut tube to enter the dorsal mesentery. The two pancreatic buds fuse together to form a single pancreas but retain two separate ducts that enter the gut tube.

Spleen

The spleen develops in the dorsal mesentery of the stomach (dorsal mesogastrium). The spleen arises from cells of the mesentery, which migrate into the plane between the layers of the mesentery. The mesentery covering the spleen becomes the visceral peritoneum of the spleen. The mesentery between the spleen and the gut tube becomes the gastrosplenic ligament. The mesentery between the spleen and the dorsal body wall becomes the splenorenal ligament (most of which subsequently fuses to become parietal peritoneum).

Secondary Retroperitonealization

Most of the gut tube retains only a dorsal mesentery. The absence of a ventral mesentery allows for mobility of the gut. Parts of the gut tube (most of the duodenum, ascending colon, descending colon, part of rectum) fuse with the body wall by way of fusion of visceral peritoneum with parietal peritoneum. This results in the organ becoming secondarily retroperitoneal and the visceral peritoneum covering the organ being renamed as the parietal peritoneum. The mesentery attaching to the organ also is renamed as the parietal peritoneum, and vessels within the mesentery become secondarily retroperitoneal.

Rotations of the Gut

The abdominal foregut rotates 90 degrees around its own long axis such that the dorsal side rotates to the left and the ventral side rotates to the right. This results in the spleen being on the left and the lesser omentum being on the right. This rotation creates the omental bursa (lesser sac). The communication between the lesser sac and the greater sac is the epiploic foramen (of Winslow).

The midgut develops an intestinal loop, which herniates into the umbilical cord. While in the umbilical cord and during retraction from the umbilical cord, the midgut rotates 270 degrees around an anteroposterior axis (marked by the superior mesenteric artery), which is a counter-clockwise rotation, as viewed from the ventral side. This rotation results in the jejunum being on the left, and the ileum and cecum being on the right. It also causes the colon to assume the shape of an inverted "U".

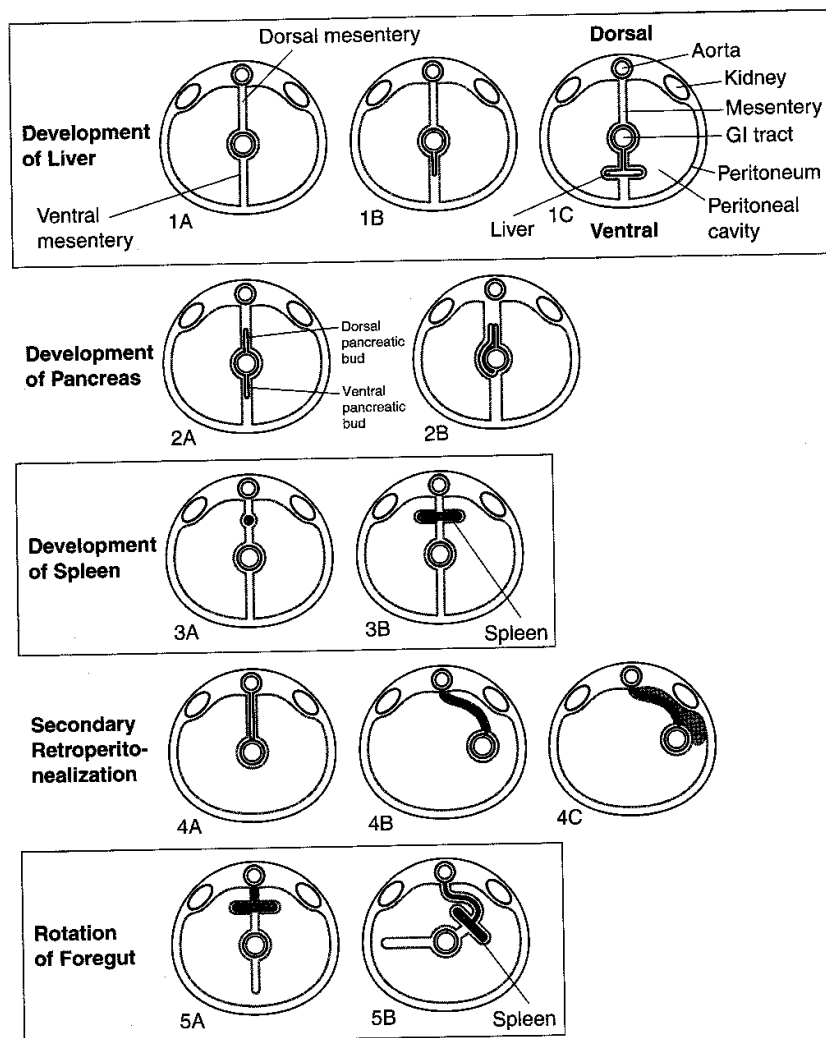


Figure III-3-9. Cross-Sectional View of the Abdominal Viscera

ABDOMINAL VISCERA AND PERITONEUM

Gastrointestinal (GI) System

Peritoneum

The serous membrane related to the viscera of the abdominal cavity. It is divided into two layers (Figure III-3-9).

Parietal Layer

The parietal layer lines the body wall and covers the retroperitoneal organs.

Visceral Layer

The visceral layer is composed of two parts:

- Covering of the surface of the peritoneal organs.
- Mesentery—a double layer of peritoneum that suspends a part of the GI tract from the body wall. Allows for the passage of vessels, nerves, and lymphatics. Includes the terms *omentum*, *meso*, and *ligament*.

Peritoneal cavity

The peritoneal cavity is the potential space located between the parietal and visceral layers.

Viscera

Viscera are classified as:

Peritoneal organs—have a mesentery and are almost completely enclosed in peritoneum. These organs are mobile.

Retroperitoneal organs—are partially covered with peritoneum and are immobile or fixed organs.

Peritoneal cavity and mesenteries

Epiploic Foramen of Winslow

An opening into omental bursa (Figures III-3-10 and III-3-11).

A finger in the epiploic foramen that presses:

- Anteriorly—touches hepatoduodenal ligament and the portal vein
- Posteriorly—touches inferior vena cava

In A Nutshell

Major Peritoneal Organs

- Stomach
- Liver and gallbladder
- Spleen
- Beginning of duodenum
- Tail of pancreas
- Jejunum
- Ileum
- Appendix
- Transverse colon
- Sigmoid colon

Major Secondary Retroperitoneal Organs

- Most of duodenum
- Most of pancreas
- Ascending colon
- Descending colon
- Upper rectum

Major Primary Retroperitoneal Organs

- Kidney
- Adrenal gland
- Ureter
- Aorta
- Inferior vena cava
- Lower rectum
- Anal canal

Note: Cecum is sometimes peritoneal and sometimes secondarily retroperitoneal.

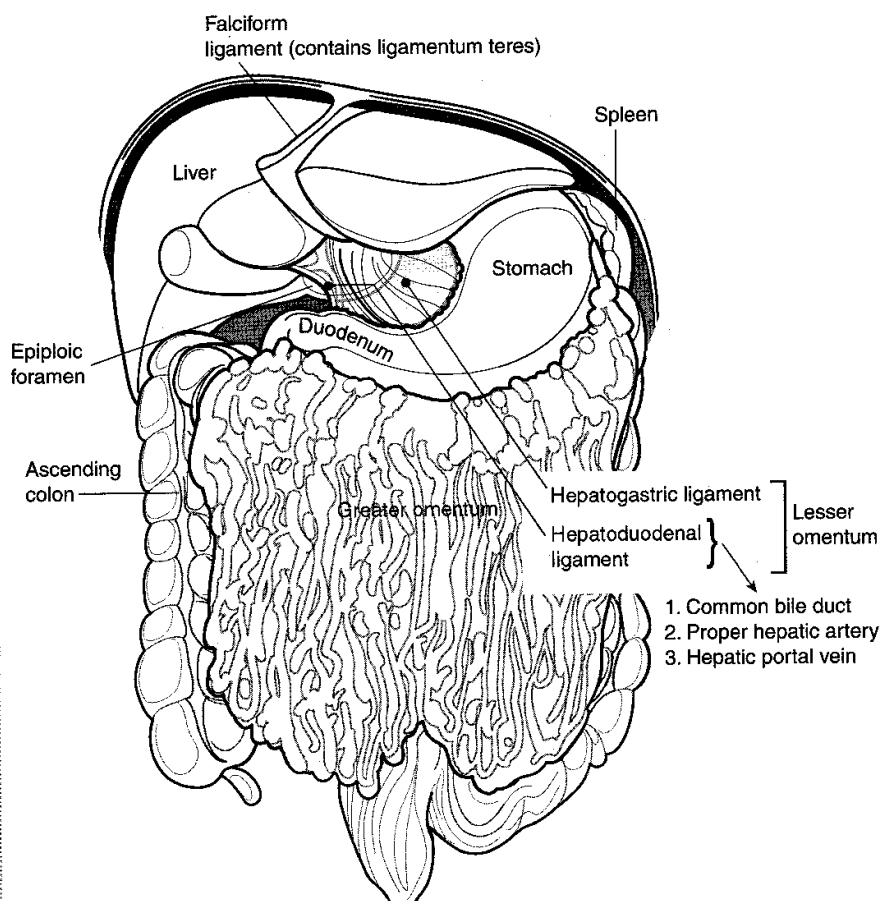


Figure III-3-10. Peritoneal Membranes

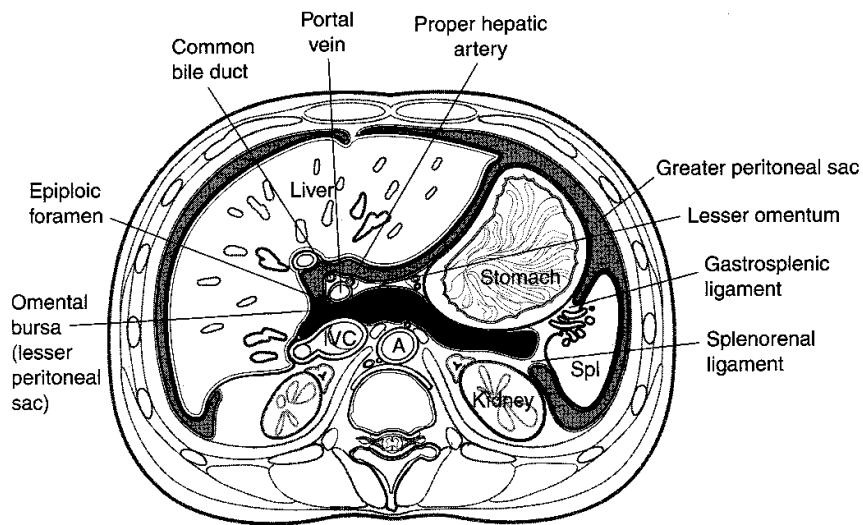


Figure III-3-11. Greater and Lesser Peritoneal Sacs

Liver

The liver is invested by peritoneum (i.e., the coronary ligament and the right and left triangular ligaments) except over the bare area that lies in direct contact with the diaphragm. It lies mostly in the right hypochondrium and is protected by the rib cage.

The liver has two surfaces: a superior, diaphragmatic surface and an inferior, visceral surface (Figure III-3-12).

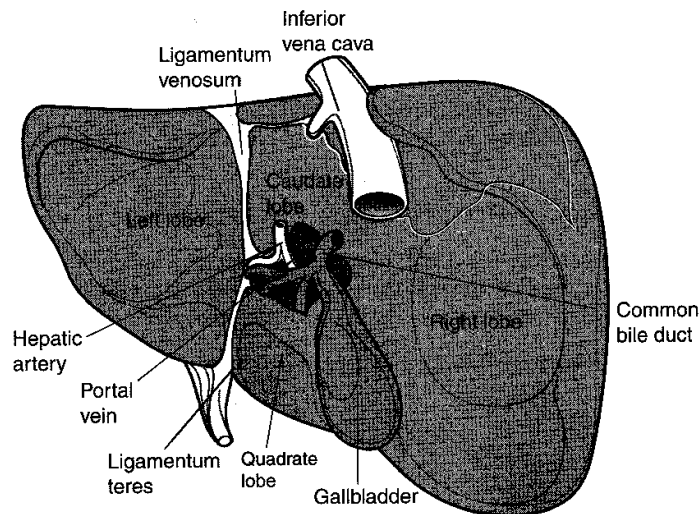


Figure III-3-12. Visceral Surface of the Liver

The liver is divided into two lobes of unequal size by the falciform ligament.

- Fissures for the ligamentum teres and the ligamentum venosum, the porta hepatis, and the fossa for the gallbladder further subdivide the right lobe into the right lobe proper, the quadrate lobe, and the caudate lobe.
- The quadrate and caudate lobes are anatomically part of the right lobe but functionally part of the left. They receive their blood supply from the left branches of the portal vein and hepatic artery and secrete bile to the left hepatic duct.

The liver has a central hilus, or porta hepatis, which receives venous blood from the portal vein and arterial blood from the hepatic artery.

- The central hilus also transmits the common bile duct, which collects bile produced by the liver.
- These structures, known collectively as the portal triad, are located in the hepatoduodenal ligament, which is the right free border of the lesser omentum.

The hepatic veins drain the liver by collecting blood from the liver sinusoids and returning it to the inferior vena cava.

Gallbladder

The gallbladder lies in a fossa on the visceral surface of the liver to the right of the quadrate lobe.

It stores and concentrates bile, which enters and leaves through the cystic duct. The cystic duct joins the common hepatic duct to form the common bile duct.

Pancreas

The ventral pancreatic diverticulum becomes the major pancreatic duct (of Wirsung), and the dorsal pancreatic diverticulum becomes the minor pancreatic duct (of Santorini) (Figures III-3-13 and III-3-14).

The inferior portion of the head of the pancreas and the uncinate process develop from the ventral bud, and the superior portion of the head and the neck, body, and tail of the pancreas develop from the dorsal bud.

Most of the pancreas is secondarily retroperitoneal, but the distal part of the tail of the pancreas remains peritoneal in the splenorenal ligament. The tip of the tail of the pancreas reaches the hilus of the spleen.

Both pancreatic ducts open into the second portion of the duodenum.

The head of the pancreas receives its blood supply from the superior and inferior pancreaticoduodenal arteries. This region is an important region for **collateral circulation** because there are anastomoses between these branches of the celiac trunk and superior mesenteric artery.

The body and tail of the pancreas receive their blood supply from the splenic artery.

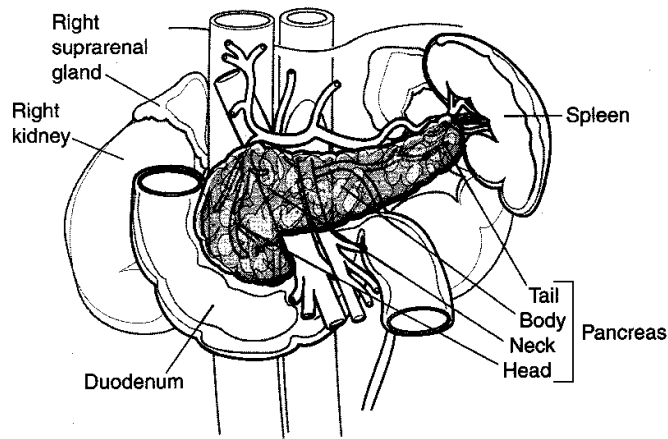


Figure III-3-13. Adult Pancreas

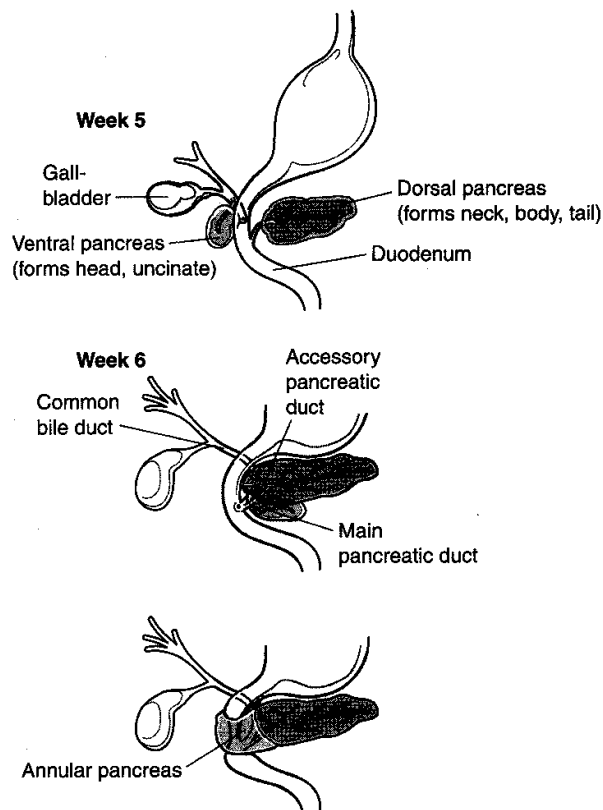


Figure III-3-14. Development of the Pancreas and Duodenum

Spleen

The spleen is a peritoneal organ in the upper left quadrant that is related to the left 9th, 10th, and 11th ribs. Fracture of these ribs may lacerate the spleen.

Inasmuch as the spleen lies above the costal margin, a normal-sized spleen is not palpable. An enlarged spleen may be palpated below the left costal margin.

The splenic artery and vein reach the hilus of the spleen by traversing the splenorenal ligament.

Stomach

The stomach has a lesser curvature, which is connected to the porta hepatis of the liver by the lesser omentum, and a greater curvature from which the greater omentum is suspended.

The cardiac region receives the esophagus.

The dome-shaped upper portion of the stomach, which is normally filled with air, is the fundus.

The main center portion of the stomach is the body.

The pyloric portion of the stomach has a thick muscular wall and narrow lumen that leads to the duodenum.

Duodenum

The duodenum is C-shaped, has four parts, and is located retroperitoneally except at the beginning.

It receives the common bile duct and pancreatic duct in its second (descending) part. The common opening for these structures is the hepatopancreatic ampulla (of Vater). Smooth muscle in the wall of the ampulla is known as the sphincter of Oddi. Note that the foregut terminates at the point of entry of the common bile duct or the anterior intestinal portal; the remainder of the duodenum is part of the midgut.

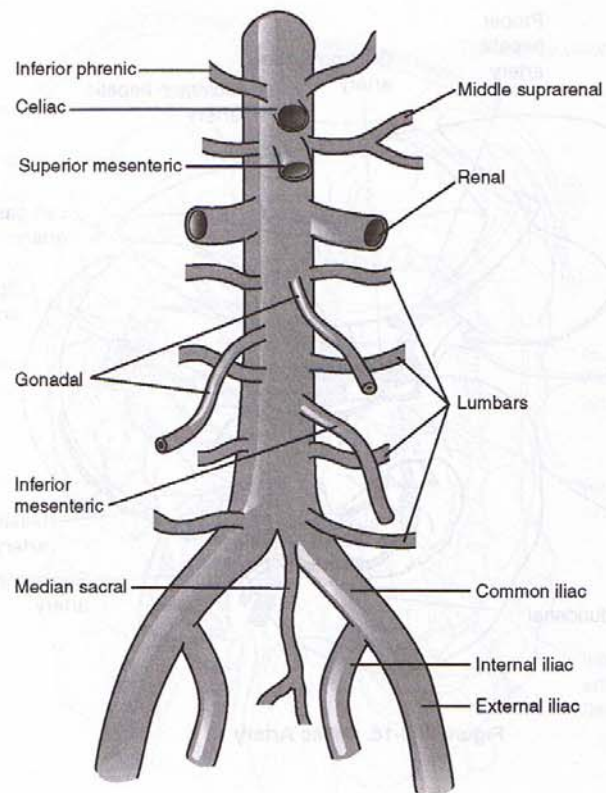


Figure III-3-15. Visceral and Parietal Branches of the Abdominal Aorta

Celiac and superior mesenteric arteries

Branches of the celiac and superior mesenteric arteries form a collateral circulation around the duodenum and the head of the pancreas (Figure III-3-16).

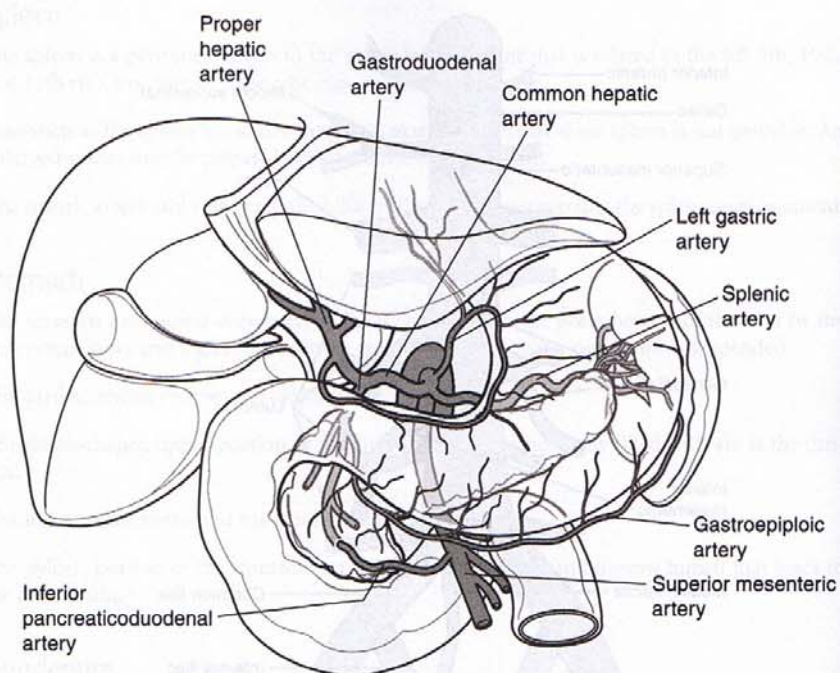


Figure III-3-16. Celiac Artery

Jejunum and Ileum

The jejunum begins at the duodenojejunal junction and comprises two fifths of the remaining small intestine. The beginning of the ileum is not clearly demarcated; it consists of the distal three fifths of the small bowel.

The jejunoileum is suspended from the posterior body wall by the mesentery proper. Although the root of the mesentery is only 9 inches long, the mobile part of the small intestine is approximately 22 feet in length.

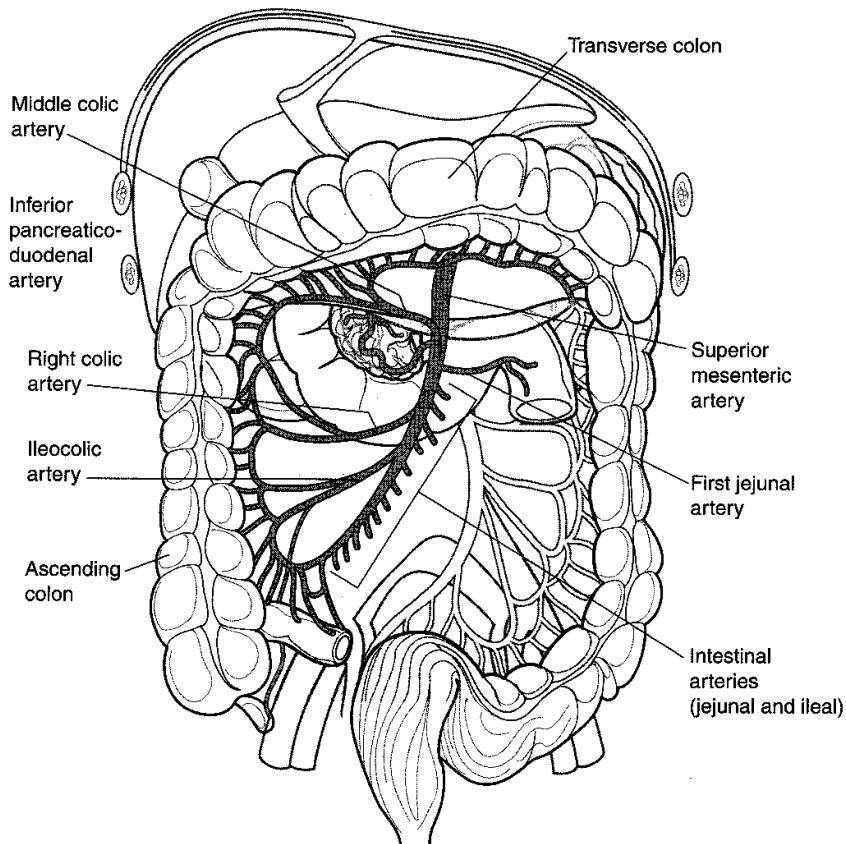


Figure III-3-17. Distribution of Superior Mesenteric Artery

Colon

Cecum

The cecum is the first part of the colon, or large intestine, and begins at the ileocecal junction (Figure III-3-17).

It is a blind pouch, which often has a mesentery, and gives rise to the vermiform appendix. The appendix has its own mesentery, the mesoappendix.

Ascending colon

The ascending colon lies retroperitoneally and lacks a mesentery. It is continuous with the transverse colon at the right (hepatic) flexure of colon.

Transverse colon

The transverse colon has its own mesentery called the transverse mesocolon.

It becomes continuous with the descending colon at the left (splenic) flexure of colon.

Note that the midgut terminates at the junction of the proximal two thirds and distal one third of the transverse colon (posterior intestinal portal).

Descending colon

The descending colon lacks a mesentery. It joins the sigmoid colon where the large bowel crosses the pelvic brim.

Sigmoid colon

The sigmoid colon is suspended by the sigmoid mesocolon. It is the terminal portion of the large intestine and enters the pelvis to continue as the rectum.

Rectum

The superior one third of the rectum is covered by peritoneum anteriorly and laterally. It is the fixed, terminal, straight portion of the hindgut.

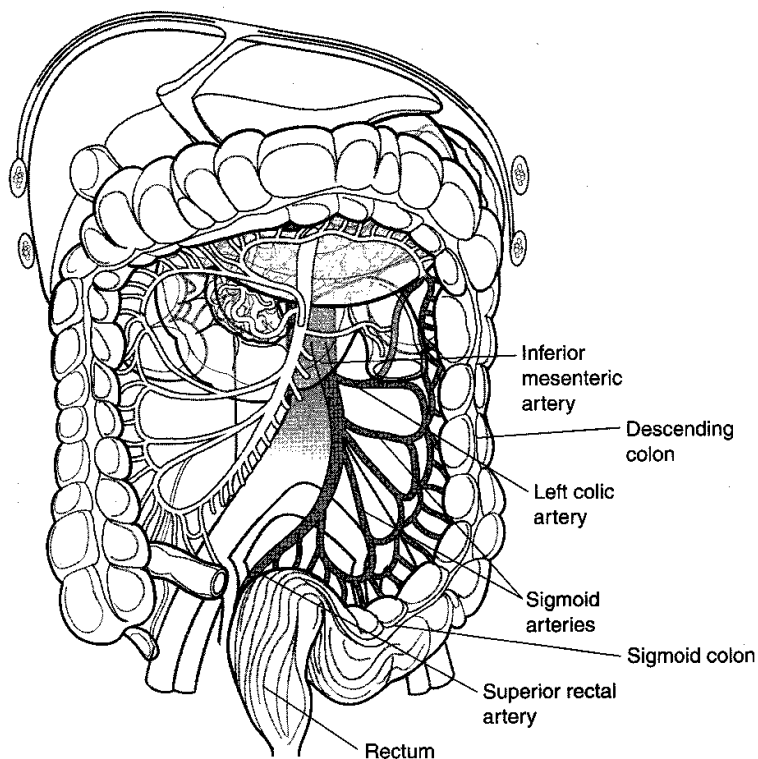


Figure III-3-18. Distribution of Inferior Mesenteric Artery

EMBRYOLOGY OF KIDNEYS AND URETER

Renal development is characterized by three successive, slightly overlapping kidney systems (Figure III-3-19).

Pronephros

During week 4, segmented nephrotomes appear in the cervical intermediate mesoderm of the embryo. These structures grow laterally and canalize to form nephric tubules. Successive tubules grow caudally and unite to form the pronephric duct, which empties into the cloaca. The first tubules formed regress before the last ones are formed. By the end of the fourth week, the pronephros disappears.

Mesonephros

In week 5, the mesonephros appears as S-shaped tubules in the intermediate mesoderm of the thoracic and lumbar regions of the embryo.

- The medial end of each tubule enlarges to form a Bowman's capsule into which a tuft of capillaries, or glomerulus, invaginates.
- The lateral end of each tubule opens into the mesonephric (Wolffian) duct, an intermediate mesoderm derivative.
- Mesonephric tubules function temporarily and degenerate by the beginning of the third month. The mesonephric duct persists in the male as the ductus epididymidis, ductus deferens, and the ejaculatory duct.

Metanephros

During week 5, the metanephros, or permanent kidney, develops from two sources: the **ureteric bud**, a diverticulum of the mesonephric duct, and the **metanephric mass**, from intermediate mesoderm of the lumbar and sacral regions.

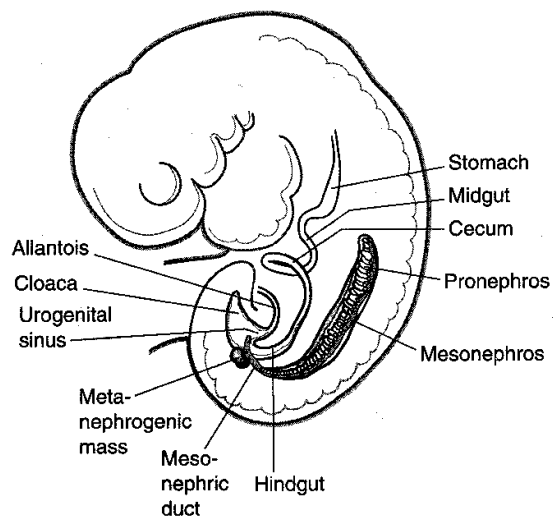


Figure III-3-19. Pronephros, Mesonephros, and Metanephros

Development of the Urinary System

The ureteric bud penetrates the metanephric mass, which condenses around the diverticulum to form the metanephrogenic cap (Figure III-3-20). The bud dilates to form the renal pelvis, which subsequently splits into the cranial and caudal major calyces. Each major calyx buds into the metanephric tissue to form the minor calyces. One to 3 million collecting tubules develop from the minor calyces, thus forming the renal pyramids.

Penetration of collecting tubules into the metanephric mass induces cells of the tissue cap to form nephrons, or excretory units.

- The proximal nephron forms Bowman's capsule, whereas the distal nephron connects to a collecting tubule.
- Lengthening of the excretory tubule gives rise to the proximal convoluted tubule, the loop of Henle, and the distal convoluted tubule.

The kidneys develop in the pelvis but appear to ascend into the abdomen as a result of fetal growth of the lumbar and sacral regions. With their ascent, the ureters elongate, and the kidneys become vascularized by lateral splanchnic arteries, which arise from the abdominal aorta.

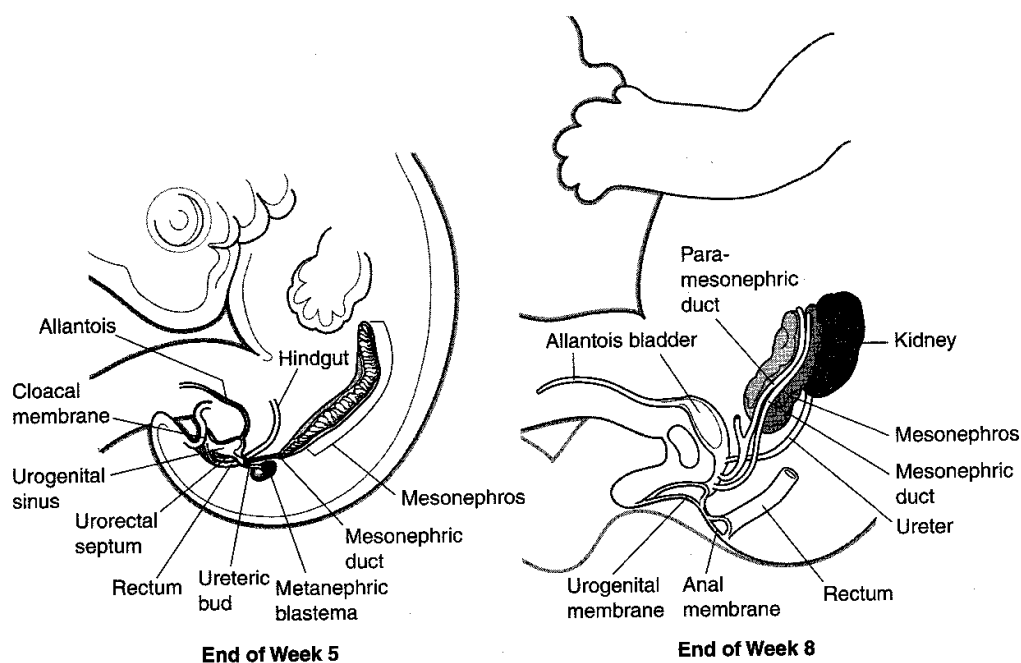


Figure III-3-20. Development of the Urinary System

EMBRYOLOGY OF BLADDER AND URETHRA

The urorectal septum divides the cloaca into the anorectal canal and the urogenital sinus by week 7.

- The upper and largest part of the urogenital sinus becomes the urinary bladder, which is initially continuous with the allantois. As the lumen of the **allantois** becomes obliterated, a fibrous cord, the **urachus**, connects the apex of the bladder to the umbilicus. In the adult, this structure becomes the **median umbilical ligament**.
- The mucosa of the trigone of the bladder is formed by the incorporation of the caudal mesonephric ducts into the dorsal bladder wall. This mesodermal tissue is eventually replaced by endodermal epithelium so that the entire lining of the bladder is of endodermal origin.
- The smooth muscle of the bladder is derived from splanchnic mesoderm.

The male urethra is anatomically divided into three portions: prostatic, membranous, and spongy (penile).

- The prostatic urethra, membranous urethra, and proximal penile urethra develop from the narrow portion of the urogenital sinus below the urinary bladder.
- The distal spongy urethra is derived from the ectodermal cells of the glans penis.

The female urethra is derived from two sources. The upper two thirds develop from the mesonephric ducts, and the lower portion is derived from the urogenital sinus.

Congenital Abnormalities

Renal agenesis

Failure of one or both kidneys to develop because of early degeneration of the ureteric bud. Agenesis is fairly common in the unilateral form but leads to death shortly after birth in the bilateral form.

Renal cysts

The formation of thin-walled, fluid-filled cysts from blind tubules, perhaps arising from improper linkage between the collecting ducts and distal convoluted tubules.

Pelvic and horseshoe kidney

Pelvic kidney is caused by a failure of one kidney to ascend. Horseshoe kidney is a fusion of both kidneys at their ends and failure of the fused kidney to ascend.

Double ureter

Caused by the early splitting of the ureteric bud or the development of two separate buds.

Patent urachus

Failure of the allantois to be obliterated. It causes urachal fistulas or sinuses. Remnants of the allantoic stalk may give rise to urachal cysts. In male children with congenital valvular obstruction of the prostatic urethra or in older men with enlarged prostates, a patent urachus may cause drainage of urine through the umbilicus.

KIDNEYS AND URETER

Kidney's Relation to the Posterior Abdominal Wall

Both kidneys are in contact with the diaphragm, psoas major, and quadratus lumborum (Figures III-3-21 and III-3-22).

- Right kidney—contacts the above structures and the 12th rib
- Left kidney—contacts the above structures and the 11th and 12th ribs

Ureter's Relation to the Posterior Abdominal Wall

The ureter lies on the anterior surface of the psoas major.

Clinical Correlate

Blockage by Renal Calculi

The most common sites of ureteral constriction susceptible to blockage by renal calculi are:

- Where the renal pelvis joins the ureter
- Where the ureter crosses the pelvic inlet
- Where the ureter enters the wall of the urinary bladder

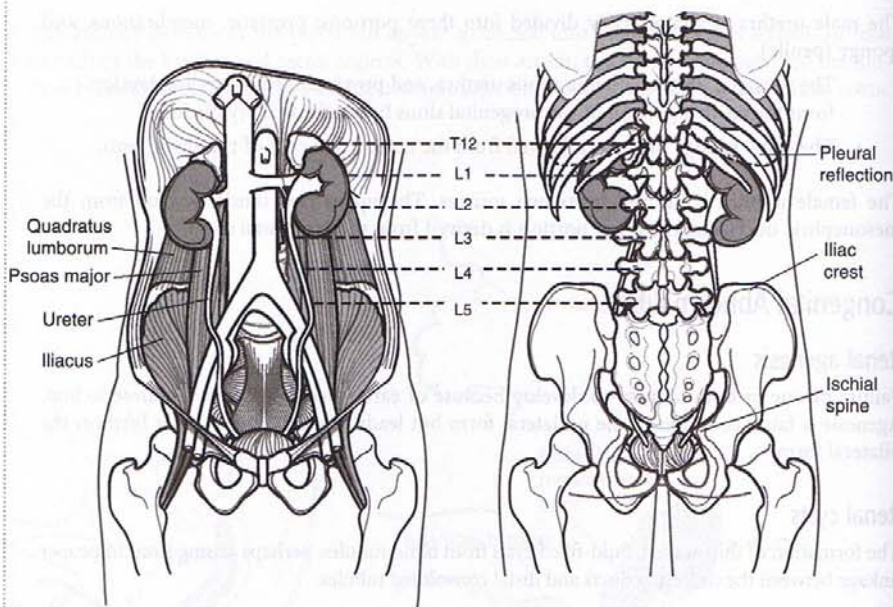


Figure III-3-21. Muscles of the Posterior Abdominal Wall

Figure III-3-22. Bony Landmarks of the Posterior Abdominal Wall

Kidneys

The kidneys are a pair of bean-shaped organs approximately 12 cm long. They extend from vertebral level T12 to L3 when the body is in the erect position. The right kidney is positioned slightly lower than the left because of the mass of the liver.

Internal structure

Within the dense, connective tissue of the renal capsule, the kidney substance is divided into an outer cortex and an inner medulla (Figure III-3-23):

- **Cortex**—contains glomeruli, Bowman's capsules, and proximal and distal convoluted tubules. It forms renal columns, which extend between medullary pyramids.

- **Medulla**—consists of 10 to 18 striated pyramids and contains collecting ducts and loops of Henle. The apex of each pyramid ends as a papilla where collecting ducts open.
- **Calyces**—the minor calyces receive one or more papillae and unite to form major calyces, of which there are two to three per kidney.
- **Renal pelvis**—the dilated upper portion of the ureter that receives the major calyces.

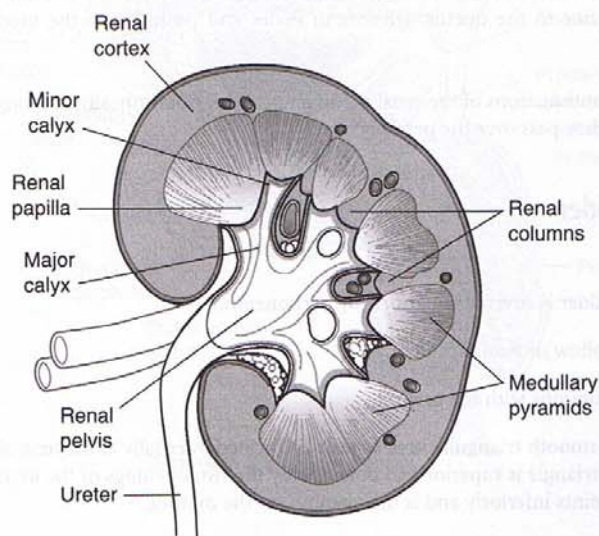


Figure III-3-23. Internal Structures of the Kidney

Arterial supply

The paired renal arteries are branches of the abdominal aorta.

- Interlobar arteries travel in renal columns in the cortical areas between pyramids.
- Arcuate arteries run parallel to bases of pyramids.
- Interlobular arteries are branches of arcuate arteries.
- Afferent arterioles lead to capillary tufts of glomeruli.

Venous drainage

Follows the same pattern as the arteries.

- The right renal vein enters the inferior vena cava.
- The left renal vein receives the left gonadal vein, the left suprarenal vein, and the left inferior phrenic vein, and may receive a root of the hemiazygos vein before crossing anterior to the aorta to join the inferior vena cava.

Lymphatic drainage

The kidneys drain to the lumbar nodes.

Clinical Correlate

Testicular Varicocele

A left renal tumor with infiltration into the renal vein would result in back pressure in the left gonadal vein, resulting in a varicocele of the left testis.

Note

The renal arteries are "end arteries," i.e., there is insufficient collateral flow to maintain perfusion in the case of occlusion.

Innervation

Primarily sympathetic with postganglionic cell bodies located in the renal plexus.

- Preganglionic sympathetic fibers are from splanchnic nerves.
- Pain afferents from the renal pelvis travel in splanchnic nerves.

Ureters

Ureters are fibromuscular tubes that connect the kidneys to the urinary bladder in the pelvis. They run posterior to the ductus deferens in males and posterior to the uterine artery in females.

They begin as continuations of the renal pelvis and run retroperitoneally, crossing the external iliac arteries as they pass over the pelvic brim.

Urinary Bladder

Structure

The urinary bladder is covered superiorly by peritoneum.

The body is a hollow muscular cavity.

The neck is continuous with the urethra.

The trigone is a smooth triangular area of mucosa located internally at the base of the bladder. The base of the triangle is superior and bounded by the two openings of the ureters. The apex of the trigone points inferiorly and is the opening for the urethra.

Blood supply

The bladder is supplied by vesicular branches of the internal iliac arteries.

The vesicular venous plexus drains to internal iliac veins.

Lymphatics

Drain to the external and internal iliac nodes.

Innervation

Parasympathetic innervation is from sacral segments S2, S3, and S4. The preganglionic parasympathetic fibers travel in pelvic splanchnic nerves to reach the detrusor muscle.

Sympathetic innervation is through preganglionic fibers, which are derived from T11 through L2.

Urethra

The male urethra is a muscular tube approximately 20 cm in length. The urethra in men extends from the neck of the bladder through the prostate gland (prostatic urethra) to the urogenital diaphragm of the perineum (membranous urethra), and then to the external opening of the glans (penile or spongy urethra) (Figure III-3-24).

The female urethra is approximately 4 cm in length and extends from the neck of the bladder to the external urethral orifice of the vulva (Figure III-3-25).

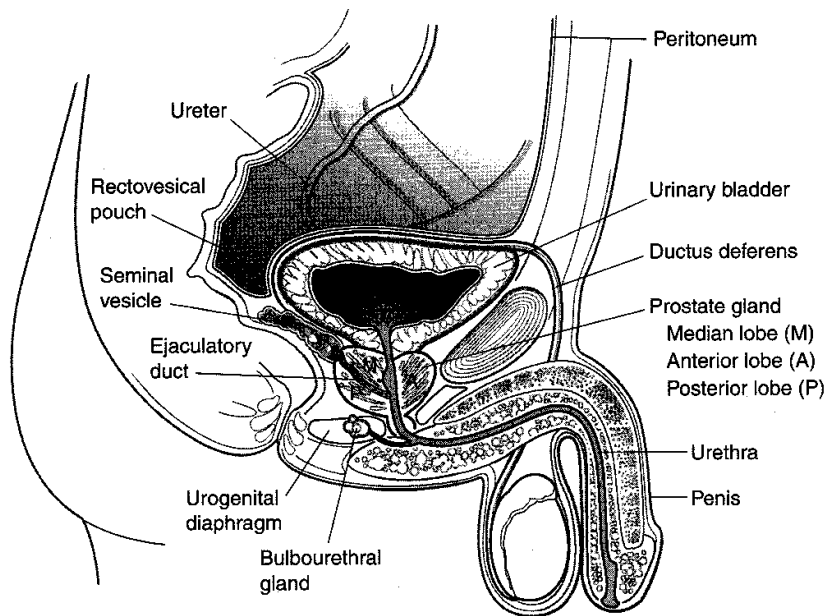


Figure III-3-24. Male Pelvis

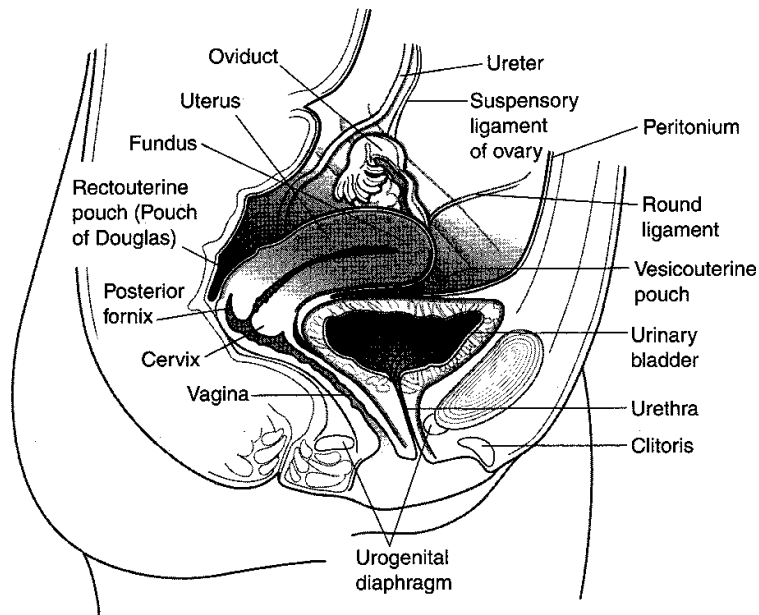


Figure III-3-25. Female Pelvis

Clinical Correlate

Hypertrophic Prostate Gland

An enlarged prostate gland will compress the urethra. The patient will complain of the urge to urinate often and has difficulty with starting urination.

Because the prostate gland is enclosed in a dense connective tissue capsule, hypertrophy will compress the prostatic portion of the urethra.

PELVIC DIAPHRAGM

Pelvic and urogenital (UG) diaphragms are illustrated in Figure III-3-26.

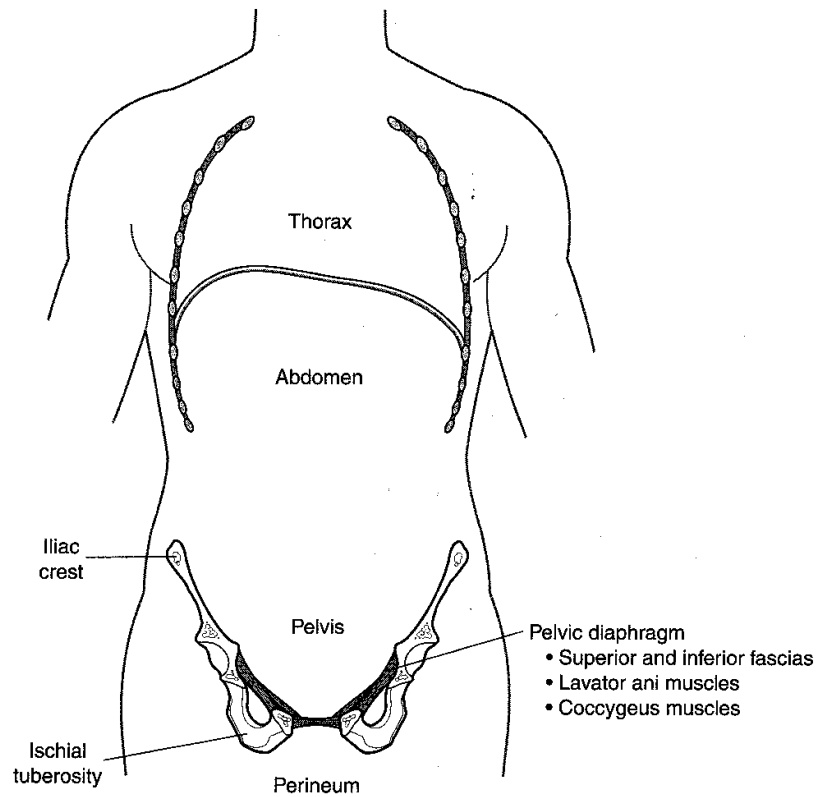


Figure III-3-26. Pelvic Diaphragm

PELVIC FLOOR AND PERINEUM

The floor of the pelvis is formed by the pelvic diaphragm. This diaphragm is formed by two layers of fascia with a middle layer of skeletal muscle. The muscles forming the middle layer are the levator ani and coccygeus muscles. The levator ani acts as a muscular sling for the rectum and marks the boundary between the rectum and anal canal.

The region below the pelvic diaphragm is the perineum. The perineum contains the ischioanal fossa, which is the fat-filled region below the pelvic diaphragm, which surrounds the anal canal. The urogenital diaphragm is in the perineum and extends between the two ischiopubic rami. The urogenital diaphragm (like the pelvic diaphragm) is composed of two layers of fascia with a middle layer of skeletal muscle.

Deep Perineal Pouch (Space)

The deep perineal pouch is the middle (muscle) layer of the urogenital diaphragm. It contains:

- Sphincter urethrae muscle—serves as external sphincter of the urethra
- Deep transverse perineal muscle
- Bulbourethral (Cowper) gland (in the male only)—duct enters bulbar urethra

Superficial Perineal Pouch (Space)

The superficial perineal pouch is the region below the urogenital diaphragm and is enclosed by the superficial perineal (Colles) fascia. It contains:

- Crura of penis or clitoris—erectile tissue
- Bulb of penis (in the male)—erectile tissue; contains urethra
- Bulbs of vestibule (in the female)—erectile tissue; in lateral walls of vestibule
- Ischiocavernosus muscle—skeletal muscle that covers crura of penis or clitoris
- Bulbospongiosus muscle—skeletal muscle that covers bulb of penis or bulbs of vestibule
- Greater vestibular (Bartholin) gland (in female only)—homologous to Cowper gland

Male

Crura of penis are continuous with the corpora cavernosa of the penis.

Bulb of penis is continuous with corpus spongiosus of the penis (contains urethra).

Corpora cavernosa and corpus spongiosus form the shaft of the penis.

Female

Crura of the clitoris are continuous with the corpora cavernosa of the clitoris.

Bulbs of vestibule are separated from the vestibule by the labia minora.

Urethra and vagina empty into the vestibule.

Duct of greater vestibular glands enters the vestibule.

Clinical Correlate

In the male, injury to the bulb of the penis may result in extravasation of urine from the urethra into the superficial perineal space. From this space, urine may pass into the scrotum, into the penis, and onto the anterior abdominal wall in the plane deep to Scarpa fascia.

Clinical Correlate

Laceration of Membranous or Penile Urethra

Accumulation of fluid in the scrotum, around the penis, and in the anterolateral abdominal wall is indicative of a laceration of either the membranous or penile urethra. This can be caused by trauma to the perineal region (saddle injury) or laceration of the urethra during catheterization.

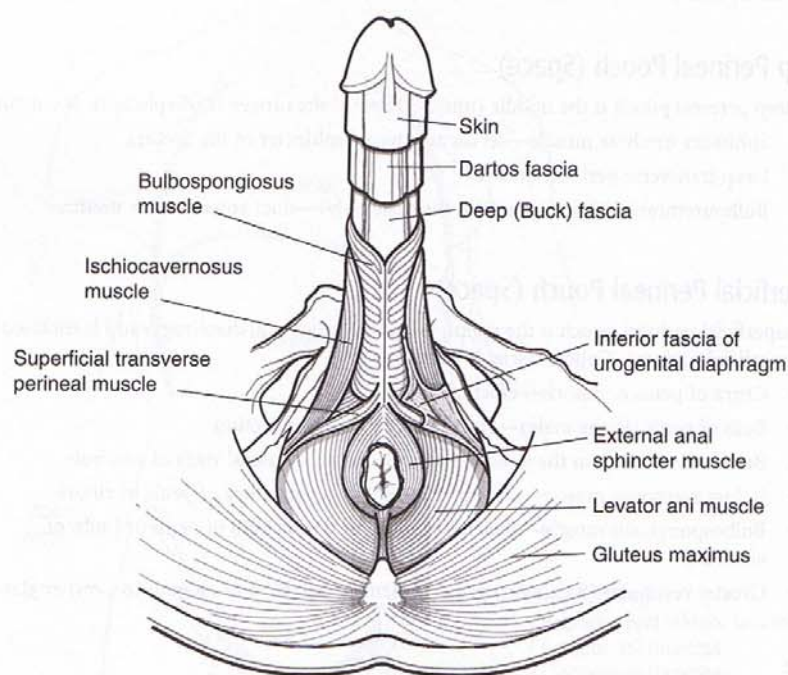


Figure III-3-27

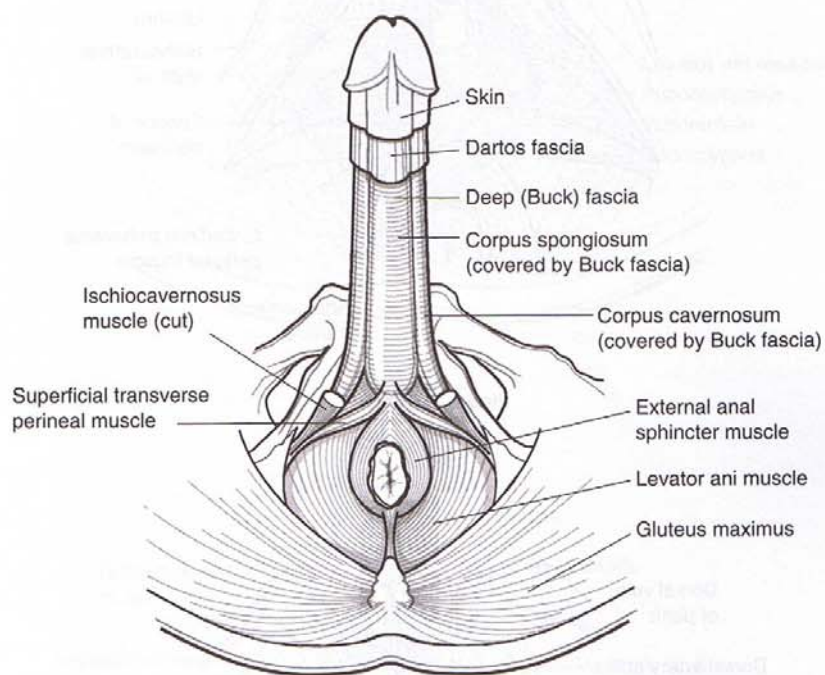


Figure III-3-28

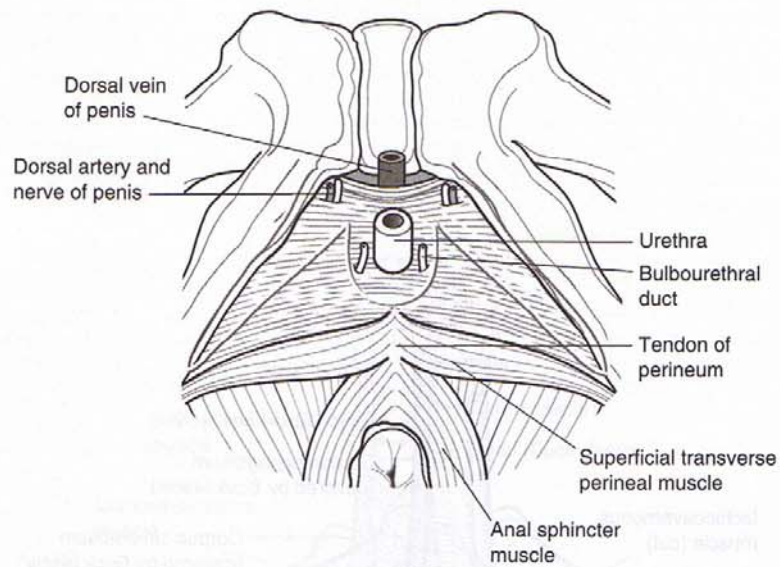


Figure III-3-29

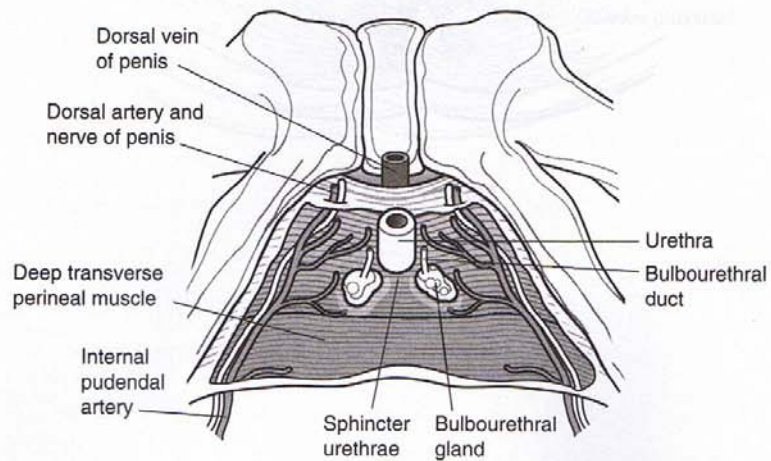


Figure III-3-30

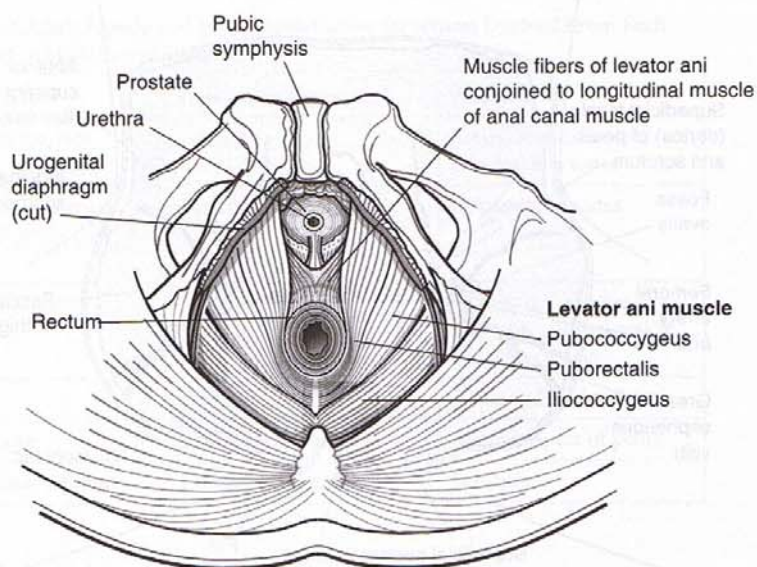


Figure III-3-31

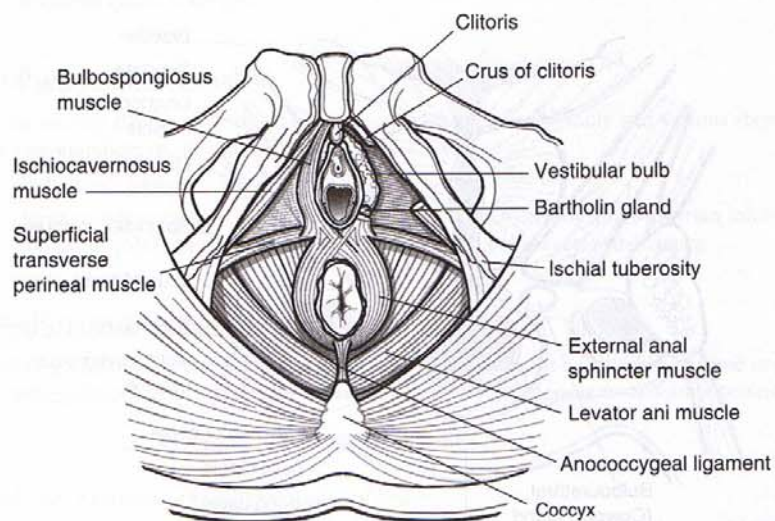


Figure III-3-32

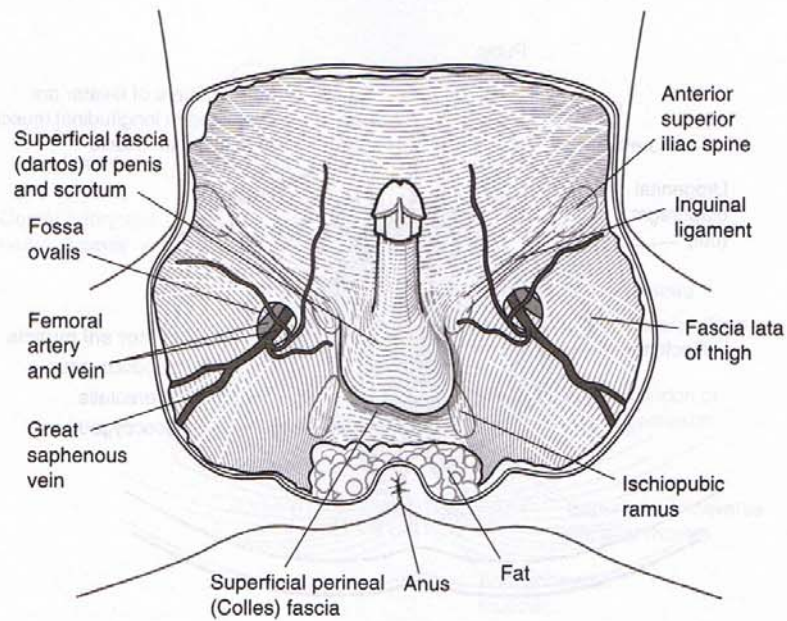


Figure III-3-33

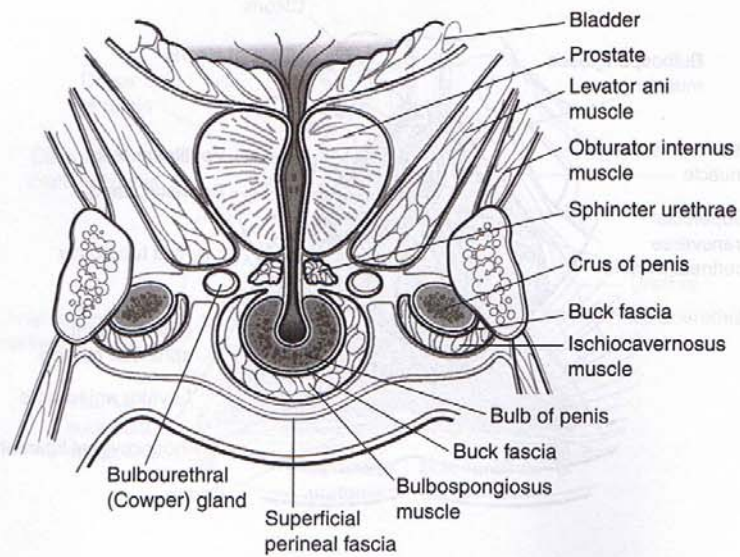


Figure III-3-34

EMBRYOLOGY OF THE REPRODUCTIVE SYSTEM

Table III-3-2. Adult Female and Male Reproductive Structures Derived From Each Precursor of the Indifferent Embryo

Adult Female	Indifferent Embryo	Adult Male
Ovary, follicles, rete ovarii	Gonads	Testes, seminiferous tubules, rete testes
Uterine tubes, uterus, cervix and upper part of vagina	Paramesonephric ducts	Appendix of testes
Duct of Gartner	Mesonephric ducts	Epididymis, ductus deferens, seminal vesicle, ejaculatory duct
Clitoris	Phallus	Glans and body of penis
Labia minora	Urogenital folds	Ventral aspect of penis
Labia majora	Labioscrotal swellings	Scrotum

Female Pseudo-Intersexuality

Characterized by having ovarian (but no testicular) tissue histologically and masculinization of the female external genitalia.

- Individuals have a 46,XX genotype.
- Most common cause is **congenital adrenal hyperplasia**, a condition in which the fetus produces excess androgens.

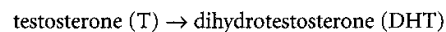
Male Pseudo-Intersexuality

Characterized by having testicular (but no ovarian) tissue histologically and various stages of stunted development of the male external genitalia.

- Individuals have a 46,XY genotype.
- Most common cause is inadequate production of testosterone and Müllerian inhibiting factor (MIF) by the fetal testes. This is due to a 5 α -reductase deficiency.

5 α -Reductase 2 Deficiency

Caused by a mutation in the **5 α -reductase 2 gene** that renders 5 α -reductase 2 enzyme underactive. Normally, 5 α -reductase catalyzes the conversion of testosterone to dihydrotestosterone.



The deficiency produces the following clinical findings:

- Underdevelopment of the penis and scrotum (microphallus, hypospadias, and bifid scrotum) and prostate gland.
- The epididymis, ductus deferens, seminal vesicle, and ejaculatory duct are normal.

These clinical findings have led to the inference that DHT is essential in the development of the penis and scrotum (external genitalia) and prostate gland in genotypic XY fetus.

At puberty, these individuals demonstrate a striking virilization owing to an increased T:DHT ratio. This increase is diagnostic (normal, 5; 5 α -reductase 2 deficiency, 20–60).

Complete Androgen Insensitivity (CAIS; or Testicular Feminization Syndrome)

Occurs when a fetus with a 46,XY genotype develops testes and female external genitalia with a rudimentary vagina; the uterus and uterine tubes are generally absent.

- Testes may be found in the labia majora and are surgically removed to circumvent malignant tumor formation.
- These individuals present as normal-appearing females, and their psychosocial orientation is female despite their genotype.
- Most common cause is a mutation in the **androgen receptor (AR) gene** that renders the AR inactive.

Hypospadias

Occurs when the urethral folds fail to fuse completely, resulting in the external urethral orifice opening onto the **ventral** surface of the penis.

It is generally associated with a poorly developed penis that curves ventrally, known as **chordee**.

Epispadias

Occurs when the external urethral orifice opens onto the **dorsal** surface of the penis.

It is generally associated with exstrophy of the bladder.

Undescended Testes (Cryptorchidism)

Occurs when the testes fail to descend into the scrotum. This normally occurs within 3 months after birth.

- Bilateral cryptorchidism results in sterility.
- The undescended testes may be found in the abdominal cavity or in the inguinal canal.

Hydrocele of the Testes

Occurs when a small patency of the processus vaginalis remains so that peritoneal fluid can flow into the processus vaginalis.

Results in a fluid-filled cyst near the testes.

MALE PELVIC VISCERA

Sagittal Section

The position of organs and peritoneum in the male pelvis is illustrated in Figure III-3-23.

FEMALE PELVIC VISCERA

Sagittal Section

The position of organs and peritoneum in the female pelvis is illustrated in Figure III-3-24.

Clinical Correlate

Culdoscopy is the procedure of entering the pelvic cavity via the posterior fornix for observation or surgery.

The sampling of intraperitoneal fluid provides important diagnostic information on several gynecologic conditions such as pelvic inflammatory disease (PID) and ectopic pregnancy. This is usually accomplished by performing a procedure known as culdocentesis, during which a needle is passed through the posterior vaginal fornix into the rectouterine pouch to obtain a sample of the fluid for analysis.

During an improperly performed abortion a speculum might not be used to widen the vagina to view the cervical opening. In such a case an instrument could penetrate the posterior wall of the vagina and damage blood vessels and introduce an infection. You are most likely to see a victim of this procedure in the emergency department after the woman has suddenly collapsed and has severe vaginal bleeding.

Uterus and Broad Ligament

Figure III-3-35 illustrates a posterior view of the female reproductive tract.

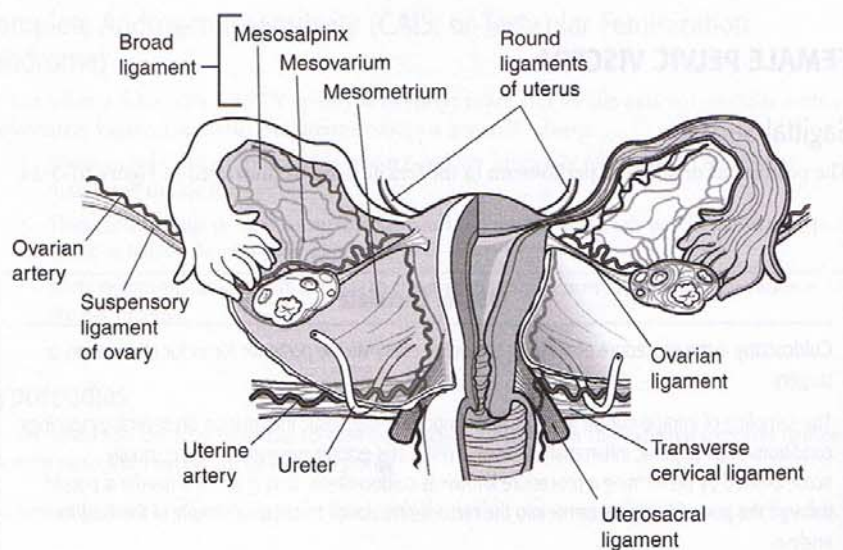


Figure III-3-35

ABDOMINAL VASCULATURE

Arterial Supply

Abdominal aorta

- The most common site for an abdominal aneurysm is in the area between the renal arteries and the bifurcation of the abdominal aorta. Signs include decreased circulation to the lower limbs and pain radiating down the back of the lower limbs.
- The most common site of atherosclerotic plaques is at the bifurcation of the abdominal aorta.

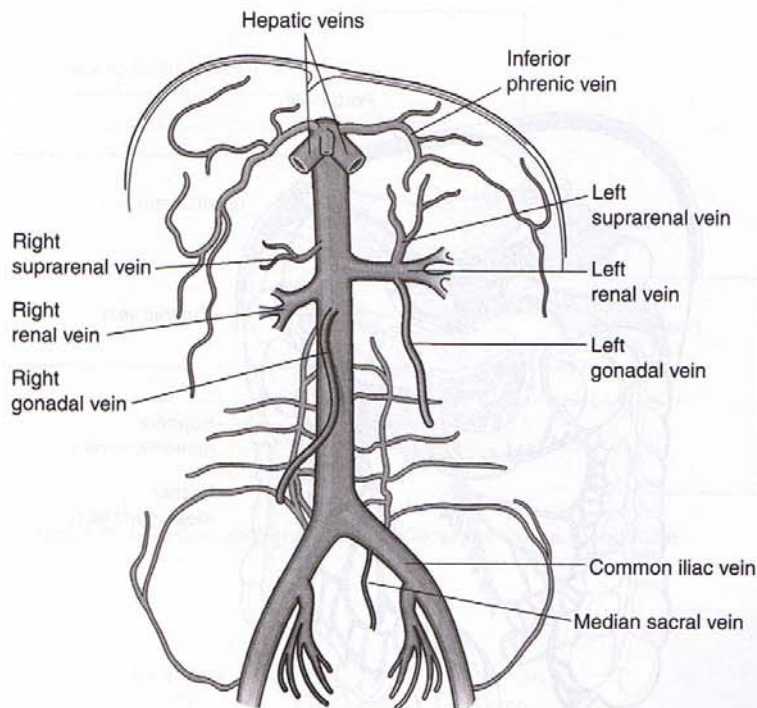


Figure III-3-36. Inferior Vena Cava (IVC) and Tributaries

Venous Drainage

The drainage of the inferior vena cava and its tributaries is shown in Figure III-3-36.

Hepatic portal system

GI tract veins to liver sinusoids to hepatic veins (Figure III-3-37).

- The hepatic portal vein is formed by the union of the superior mesenteric and splenic veins (posterior to the neck of the pancreas).
- The inferior mesenteric vein enters near the area of the junction of the superior mesenteric and splenic veins.
- The hepatic portal vein also receives gastric veins from the stomach.

The portal vein drains into the liver sinusoids, which drain to the hepatic vein, which then goes into the inferior vena cava and ultimately into the right atrium (Figure III-3-38).

Portosystemic Anastomoses

If there is an obstruction to flow through the portal system (portal hypertension), blood can flow in a retrograde direction (because of the absence of valves in the portal system) and pass through anastomoses to reach the caval system. Sites for these anastomoses include the esophageal veins, rectal veins, thoracoepigastric veins, and retroperitoneal veins. Enlargement of these veins may result in esophageal varices, hemorrhoids, and a caput medusae.

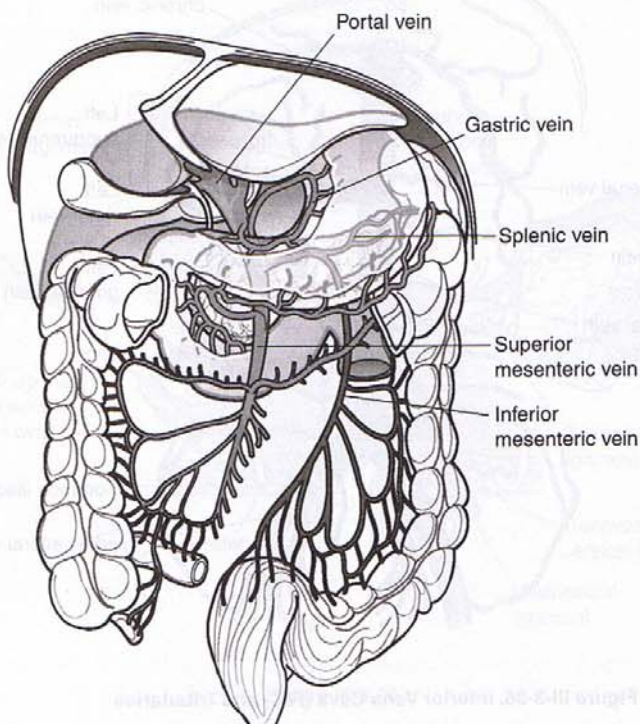


Figure III-3-37. Hepatic Portal System

Table III-3-3. Sites of Anastomoses Between the Portal and Caval Systems and Clinical Signs of Portal Hypertension

Sites of anastomoses	Portal	Caval	Clinical signs
1. Umbilicus	Paraumbilical veins	Superficial veins of the anterior abdominal wall	Caput medusa
2. Rectum	Superior rectal veins (inferior mesenteric vein)	Middle and inferior rectal veins (internal iliac vein)	Internal hemorrhoids
3. Esophagus	Gastric veins	Veins of the lower esophagus which drain into the azygos system	Esophageal varices
4. Retroperitoneal organs	Tributaries of the superior and inferior mesenteric veins	Veins of the posterior abdominal wall	Not clinically relevant

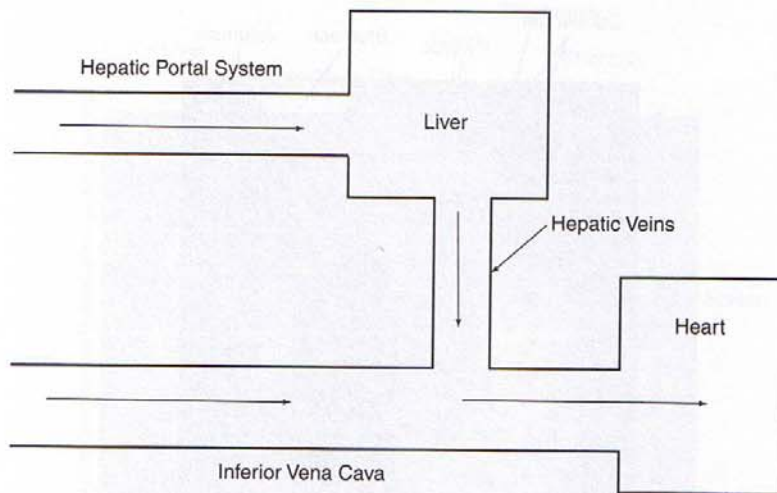


Figure III-3-38. Comparison of Normal Caval and Portal Blood Flow

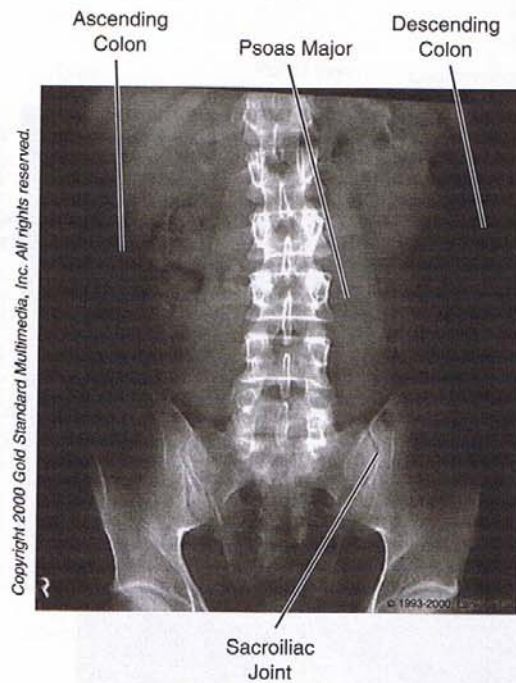


Figure III-3-39. Anteroposterior View of Abdomen

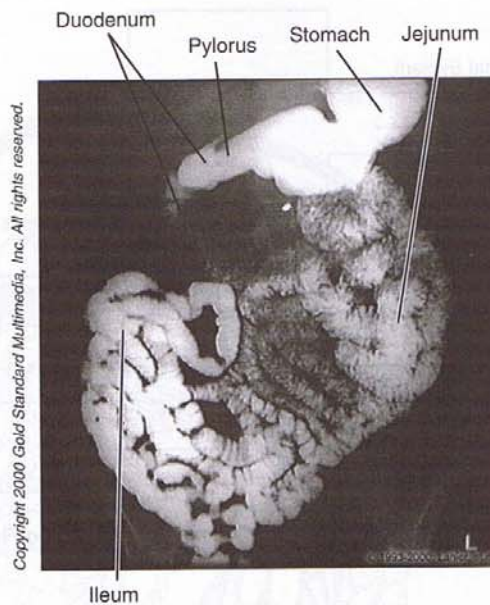


Figure III-3-40. Abdomen: Upper GI, Small Bowel

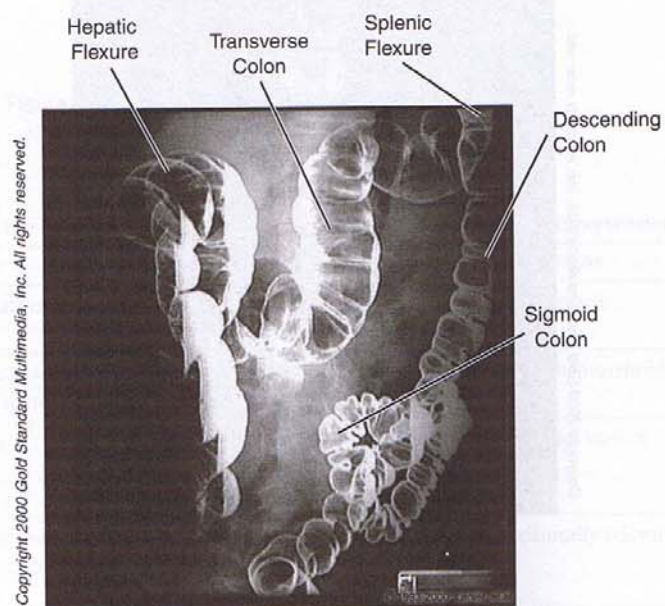


Figure III-3-41. Abdomen: Barium Enema

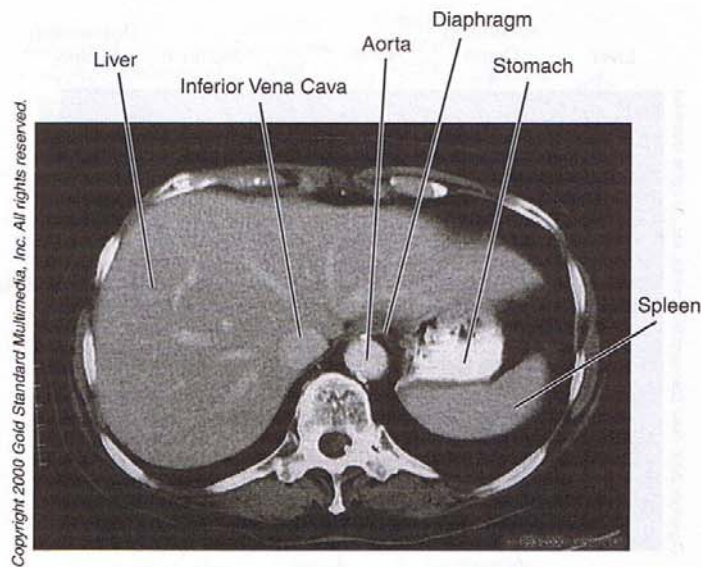


Figure III-3-42. Abdomen: CT, T₁₁

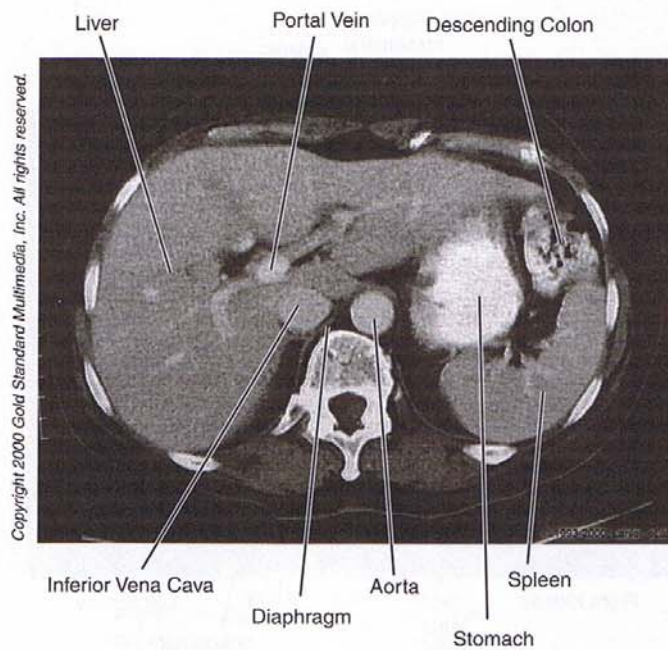


Figure III-3-43. Abdomen: CT, T₁₂

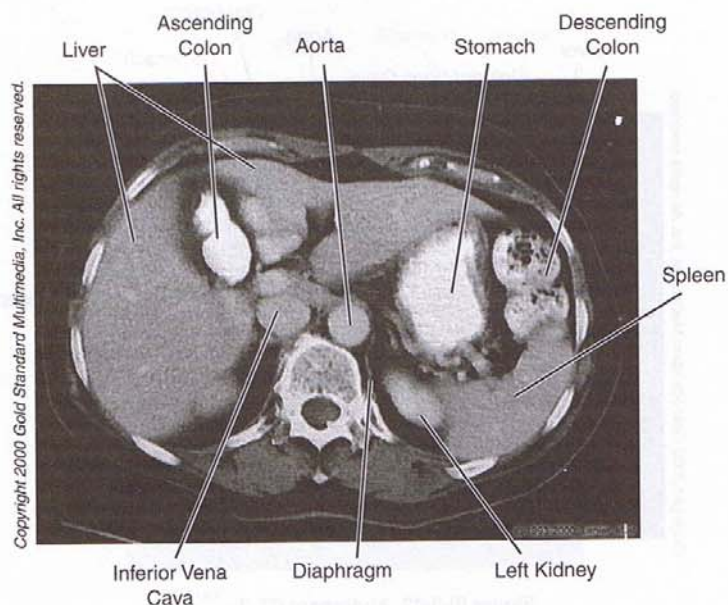


Figure III-3-44. Abdomen: CT, T₁₂

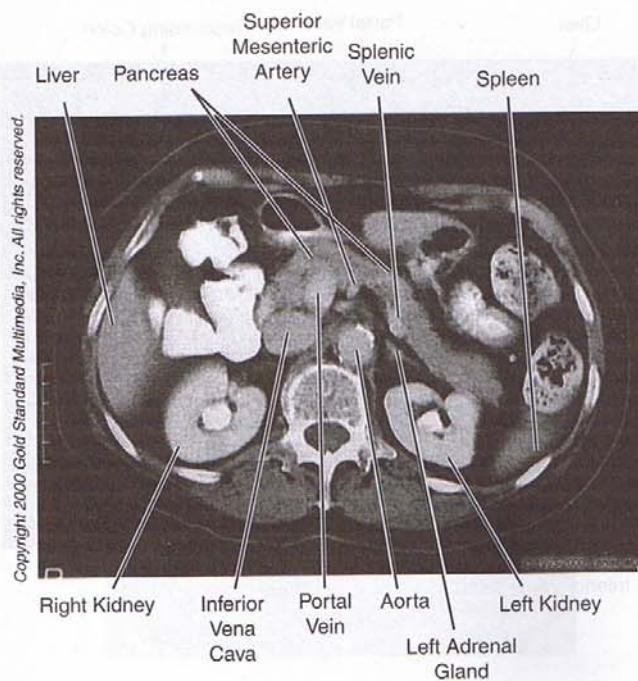


Figure III-3-45. Abdomen: CT, L₁

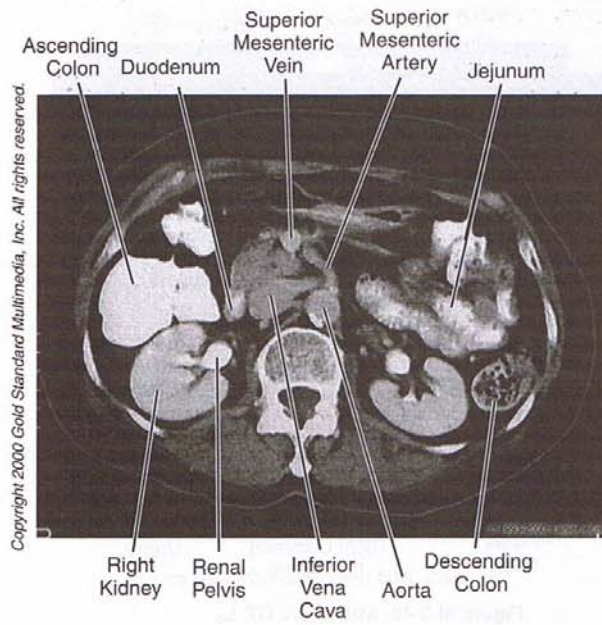


Figure III-3-46. Abdomen: CT, L₂

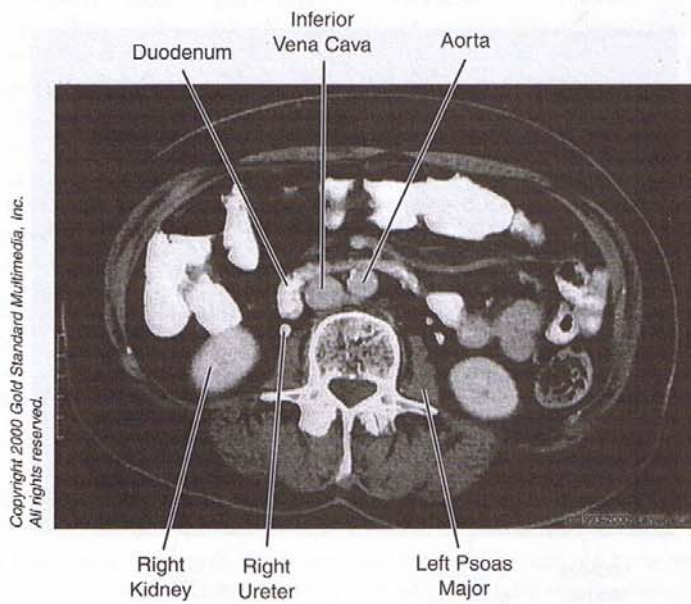


Figure III-3-47. Abdomen: CT, L₃

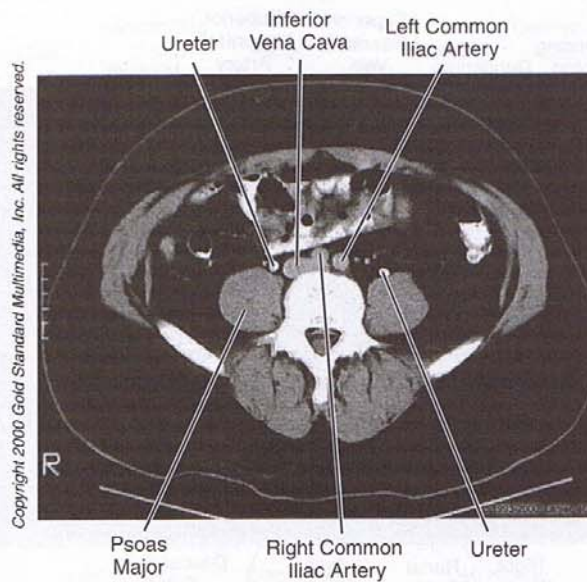


Figure III-3-48. Abdomen: CT, L₄

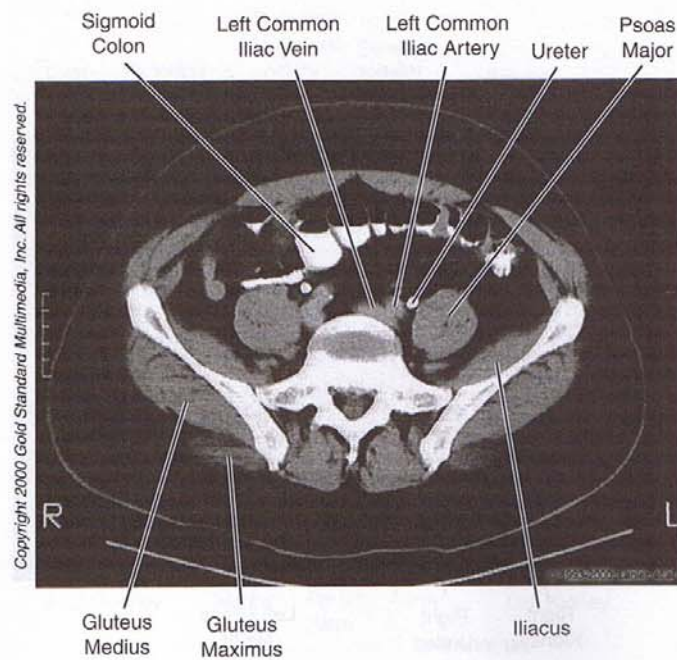


Figure III-3-49. Abdomen: CT, S₁

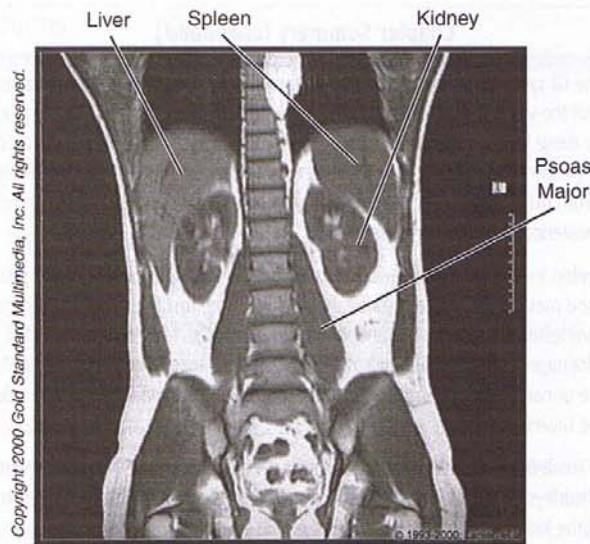


Figure III-3-50. Abdomen: MRI, Coronal

Chapter Summary

Abdomen

The abdominal wall consists primarily of three flat muscles (external oblique, internal oblique, and transversus abdominis muscles), rectus abdominis muscle, and the transversalis fascia. The inguinal canal contains the round ligament in the female and the spermatic cord in the male. The inguinal canal is an oblique canal through the lower abdominal wall beginning with the deep inguinal ring laterally and the superficial inguinal ring medially. Weakness of the walls of the canal can result in two types of inguinal hernias: direct and indirect. A direct hernia emerges through the posterior wall of the inguinal canal medial to the inferior epigastric vessels. Indirect hernias pass through the deep inguinal ring lateral to the inferior epigastric vessels and courses through the inguinal canal to reach the superficial inguinal ring. A persistent processus vaginalis often results in a congenital indirect inguinal hernia.

The gastrointestinal system develops from the primitive gut tube formed by the incorporation of the yolk sac into the embryo during body foldings. The gut tube is divided in the foregut, midgut, and hindgut. Defects in the development of the gastrointestinal tract include annular pancreas, duodenal atresia, Meckel diverticulum, and Hirschsprung disease.

The foregut, midgut, and hindgut are supplied by the celiac trunk, superior mesenteric artery, and the inferior mesenteric artery, respectively. These arteries and their branches reach the viscera mainly by coursing in different parts of the visceral peritoneum. Venous return from the abdomen is provided by the tributaries of the inferior vena cava, except for the GI tract. Blood flow from the GI tract is carried by the hepatic portal system to the liver before returning to the inferior vena cava by the hepatic veins. Diseases of the liver result in obstruction of flow in the portal system and portal hypertension. Four collateral portal-caval anastomoses develop to provide retrograde venous flow back to the heart: esophageal, rectal, umbilical, and retroperitoneal.

(Continued)

Chapter Summary (continued)

The viscera of the GI system are covered by the peritoneum, which is divided into a parietal layer lining the body wall and the visceral layer extending from the body wall and covering the surface of the viscera. Between these layers is the potential space called the peritoneal cavity. The peritoneal cavity is divided into the greater peritoneal sac and the lesser peritoneal sac (omental bursa). Entrance into the omental bursa from the greater sac is the epiploic foramen that is bound anteriorly by the lesser omentum and posteriorly by the inferior vena cava.

The kidneys develop from intermediate mesoderm by three successive renal systems: pronephros, mesonephros, and metanephros. The mesonephric kidney is the first functional kidney that develops during the first trimester. The final or metanephric kidney develops from two sources: the ureteric bud that forms the drainage part of the kidney and the metanephric mass that forms the nephron of the adult kidney. The urinary bladder develops from the urogenital sinus, which is formed after division of the cloaca by the urorectal septum.

The kidneys are located against the posterior abdominal wall between the T12 and L3 vertebrae. Posterior to the kidneys lie the diaphragm and the psoas major and quadratus lumborum muscles. The superior pole of the kidney lies against the parietal pleura posteriorly. The ureters descend the posterior abdominal wall on the ventral surface of the psoas major muscle and cross the pelvic brim to enter the pelvic cavity.

Pelvis

The pelvic cavity contains the inferior portions of the GI and urinary systems along with the reproductive viscera. The pelvic viscera and their relationships are shown for the male and female pelvis in Figures III-3-24 and III-3-25, respectively. There are two important muscular diaphragms related to the floor of the pelvis and the perineum: the pelvic diaphragm and the urogenital diaphragm, respectively. Both of these consist of two skeletal muscle components under voluntary control and are innervated by somatic fibers of the lumbosacral plexus. The pelvic diaphragm forms the floor of the pelvis where it supports the weight of the pelvic viscera and forms a sphincter for the anal canal. The urogenital diaphragm is located in the perineum (deep perineal space) and forms a sphincter for the urethra. Both diaphragms are affected by an epidural injection.

The broad ligament of the female is formed by three parts: the mesosalpinx, which is attached to the uterine tube, the mesovarium attached to the ovary, and the largest component, the mesometrium, attached to the lateral surface of the uterus. In the base of the broad ligament, the ureter passes inferior to the uterine artery just lateral to the cervix. The ovarian ligament is a lateral extension of the broad ligament extending upward to the lateral pelvic wall. This ligament contains the ovarian vessels, lymphatics, and autonomic nerves.

Perineum

The perineum is the area between the thighs bounded by the pubic symphysis, ischial tuberosity, and coccyx. The area is divided into two triangles. Posteriorly, the anal triangle contains the anal canal, external anal sphincter, and the pudendal canal that contains the pudendal nerve and internal pudendal vessels. Anteriorly is the urogenital triangle containing the external and deep structures of the external genitalia. The urogenital triangle is divided into two spaces. The superficial perineal space contains the root structures of the penis and clitoris, associated muscles, and the greater vestibular gland in the female. The deep perineal space is formed by the urogenital diaphragm and contains the bulbourethral gland in the male.

Review Questions

1. Which structure supplied by a branch of the celiac artery is not derived from foregut endoderm?
 - (A) Head of the pancreas
 - (B) Pyloric duodenum
 - (C) Cystic duct
 - (D) Liver hepatocytes
 - (E) Body of the spleen

2. An infant presents with an omphalocele at birth. Which of the following applies to this condition?
 - (A) It is also seen in patients with aganglionic megacolon.
 - (B) It results from a failure of resorption of the vitelline duct.
 - (C) It results from herniation at the site of regression of the right umbilical vein.
 - (D) It is caused by failure of recanalization of the midgut part of the duodenum.
 - (E) It is caused by a failure of the midgut to return to the abdominal cavity after herniation into the umbilical stalk.

3. A stillborn infant succumbed as a result of oligohydramnios caused by bilateral renal agenesis. Which of the following would most likely be observed in an autopsy?
 - (A) Club foot
 - (B) Urachal cyst
 - (C) Berry aneurysms
 - (D) Situs inversus
 - (E) Gastroschisis

4. Other than the spleen, occlusion of the splenic artery at its origin will most likely affect the blood supply to which structure?
 - (A) Jejunum
 - (B) Body of the pancreas
 - (C) Lesser curvature of the stomach
 - (D) Duodenum distal to the entrance of the common bile duct
 - (E) Fundus of the stomach

5. A 38-year-old banker with a history of heartburn suddenly experiences excruciating pain in the epigastric region of the abdomen. Surgery is performed immediately upon admission to the emergency room. There is evidence of a ruptured ulcer in the posterior wall of the stomach. Where will a surgeon first find the stomach contents?
 - (A) Greater peritoneal sac
 - (B) Cul-de-sac of Douglas
 - (C) Omental bursa
 - (D) Paracolic gutter
 - (E) Between the parietal peritoneum and the posterior body wall

6. At birth, an infant presents with a stomach that has herniated into the diaphragm. Where is the defect that resulted in the herniation?
 - (A) Esophageal hiatus
 - (B) Hiatus for the inferior vena cava
 - (C) Pleuroperitoneal membrane
 - (D) Septum transversum
 - (E) Right crus
7. An infant born with Down syndrome presents with bilious vomiting. What congenital defect does the infant have?
 - (A) Pyloric stenosis
 - (B) Meckel diverticulum
 - (C) Omphalocele
 - (D) Gastroschisis
 - (E) Duodenal atresia
8. A patient with cirrhosis of the liver presents with esophageal varices. Increased retrograde pressure in which veins caused the varices?
 - (A) Paraumbilical
 - (B) Splenic
 - (C) Azygous
 - (D) Gastric
 - (E) Superior mesenteric
9. Seminal fluid has entered the ejaculatory duct. Where will the fluid next be found?
 - (A) Penile urethra
 - (B) Epididymis
 - (C) Ductus deferens
 - (D) Prostatic urethra
 - (E) Urogenital diaphragm
10. A healthy 3-year-old male patient experiences a hernial sac protruding from the anterior abdominal wall about halfway between the anterior superior iliac spine and the pubic tubercle. Pulsations of an artery are palpated medial to the protrusion site through the abdominal wall. Which layer of the anterior abdominal wall will first be traversed by the hernia?
 - (A) Rectus sheath
 - (B) External oblique aponeurosis
 - (C) Inguinal ligament
 - (D) Transversalis fascia
 - (E) Cremasteric fascia

11. After surgical repair of a hernia, the patient experiences numbness in the skin on the anterior aspect of the scrotum. What nerve may have been lesioned during the herniorrhaphy?
(A) Femoral
(B) Obturator
(C) Ilioinguinal
(D) Iliohypogastric
(E) Pudendal
12. A 23-year-old female secretary in good health suddenly doubles over with pain in the area of the umbilicus. She feels warm and uneasy and has no appetite. That night the pain seems to have moved to the lower right abdominal region, and she calls her family doctor who then arranges for an ambulance to pick her up and take her to the hospital. Which nerves, perceived in the area of the umbilicus, most likely carried the painful sensations into the CNS?
(A) Vagus nerves
(B) Lesser splanchnic nerves
(C) Pudendal nerves
(D) Iliohypogastric nerves
(E) Greater splanchnic nerves
13. A male infant is born with hypospadias. What caused the defect?
(A) Degeneration of the ureteric bud
(B) Failure of the urethral folds to fuse
(C) Absence of androgen receptors in the external genitalia
(D) 5 alpha-reductase 2 deficiency
(E) Inadequate production of müllerian inhibitory substance
14. A 62-year-old male patient presents with difficulty initiating and stopping urination and polyuria. Cystourethroscopy reveals hypertrophy and trabeculation of the bladder. Which of the following might you expect in this patient?
(A) A hydrocele
(B) Urine leaking from the umbilicus
(C) Urinary incontinence due to weakness of the sphincter urethrae muscle
(D) A varicocele
(E) Difficulty in emission
15. The cause of the prostatic hypertrophy is due to an adenocarcinoma. During prostatic surgery, the nerves that innervate the prostate are lesioned. Which of the following is most likely to be seen in the patient?
(A) Inability to have a voluntary erection
(B) Inability to contract the levator ani muscle
(C) Altered sensation in skin of the perineum
(D) Fecal incontinence
(E) Retrograde ejaculation into the bladder

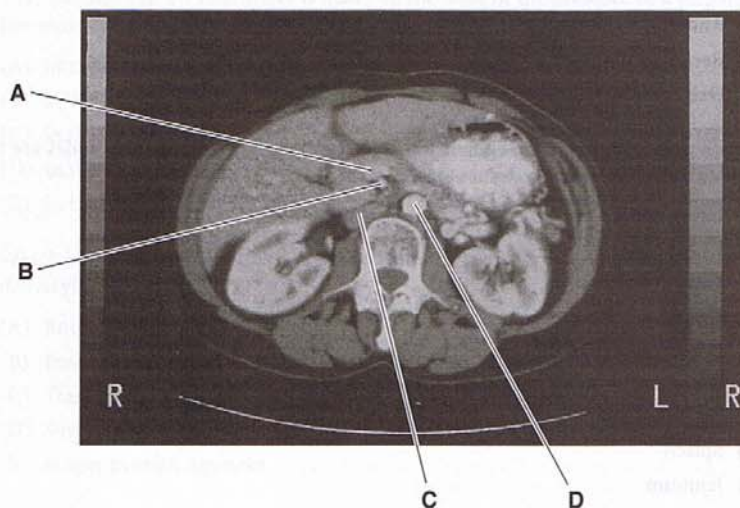
16. A mass has compressed an internal iliac artery at its branch point from the common iliac artery. Which of the following structures will not require collateral circulation to maintain an adequate arterial blood supply?
 - (A) Bladder
 - (B) Prostate
 - (C) Testis
 - (D) Uterus
 - (E) Corpus spongiosum
17. An obstetric resident is preparing to do a nerve block to anesthetize the perineum during delivery. What structure does the resident need to palpate to perform this procedure?
 - (A) Pubic tubercle
 - (B) Ischial spine
 - (C) Ischial tuberosity
 - (D) Cervix
 - (E) Sacrotuberous ligament
18. The obstetric nerve block is performed successfully and results in urinary incontinence. The anesthetized muscle is located in the
 - (A) urogenital diaphragm
 - (B) superficial perineal pouch
 - (C) pelvic diaphragm
 - (D) external genitalia
 - (E) trigone of the bladder
19. Muscles in which of the following regions contract during the Valsalva maneuver to help increase intra-abdominal pressure?
 - (A) Gluteal
 - (B) Posterior abdominal wall
 - (C) Pelvic diaphragm
 - (D) Urogenital diaphragm
 - (E) Superficial perineal pouch
20. CT cross-sectional imaging at the level of the L2 vertebra reveals parts of the gut that are pressed against the posterior abdominal wall. Which part of the GI tract might be seen normally in this position?
 - (A) Transverse colon
 - (B) Descending colon
 - (C) Duodenum proximal to the entrance of the common bile duct
 - (D) Ileum
 - (E) Sigmoid colon

21. An infant is born with a congenital diaphragmatic hernia. Which of the following are you most likely to see in this newborn infant?
 - (A) Renal agenesis
 - (B) Poor upper limb development
 - (C) Craniofacial anomalies
 - (D) Pulmonary hypoplasia
 - (E) Polycystic kidney disease
22. A CT reveals carcinoma in the body of the pancreas. Which blood vessel that courses immediately posterior to the body of the pancreas is the most likely to be compressed?
 - (A) Splenic artery
 - (B) Abdominal aorta
 - (C) Portal vein
 - (D) Splenic vein
 - (E) Renal vein
23. A young individual with fully developed female external genitalia presents with bilateral inguinal masses. Karyotyping reveals that the individual is 46 XY. What is the cause of the pseudointersexuality?
 - (A) Adrenal hyperplasia
 - (B) Inadequate production of testosterone
 - (C) Inactive androgen receptors in the external genitalia
 - (D) Failure of Sertoli cells to produce müllerian inhibitory substance
 - (E) Absence of an SRY gene on the Y chromosome
24. You evaluate a patient's prostate during a digital rectal exam. Which of the following structures may also be palpated during such an exam?
 - (A) Superior gluteal artery
 - (B) Epididymis
 - (C) Bulbourethral glands
 - (D) Seminal vesicle
 - (E) Penile urethra
25. The transitional epithelium lining the urethra and the bladder is derived from
 - (A) mesoderm
 - (B) endoderm
 - (C) wall of the yolk sac
 - (D) urogenital ridge
 - (E) paramesonephric duct

26. A young female patient in the emergency room complains of intense pain in the lower right part of the abdominal wall. She appears to be in a state of shock and shows signs of an internal hemorrhage. A vaginal exam reveals that the patient's cervix is soft, and the patient indicates that she missed her last period. Your diagnosis is that of an ectopic pregnancy. Which is the most likely site of the ruptured implantation?
- (A) Cervix of the uterus
 - (B) Body of the uterus
 - (C) Ampulla of the uterine tube
 - (D) Posterior fornix of the vagina
 - (E) Isthmus of the uterine tube
27. Your diagnosis in the case above is made on the basis of the presence of a palpable fluid-like mass. The mass is located
- (A) in the posterior fornix of the vagina
 - (B) in the broad ligament
 - (C) in the lesser peritoneal sac
 - (D) in the rectouterine pouch
 - (E) in the vesicouterine pouch
28. Which of the following structures helps prevent uterine prolapse after a normal vaginal delivery?
- (A) Round ligament of the uterus
 - (B) Broad ligament
 - (C) Transverse cervical ligament
 - (D) Suspensory ligament
 - (E) Proper ovarian ligament
29. A patient has a penetrating ulcer of the posterior wall of the first part of the duodenum. Which blood vessel is subject to erosion?
- (A) Common hepatic artery
 - (B) Gastroduodenal artery
 - (C) Proper hepatic artery
 - (D) Celiac artery
 - (E) Anterior inferior pancreaticoduodenal artery
30. Your patient has been diagnosed with a carcinoma localized to the head and neck of the pancreas. Another clinical sign would be
- (A) esophageal varices
 - (B) hemorrhoids
 - (C) a caput medusa
 - (D) increased pressure in the hepatic veins
 - (E) enlarged right supraclavicular lymph nodes

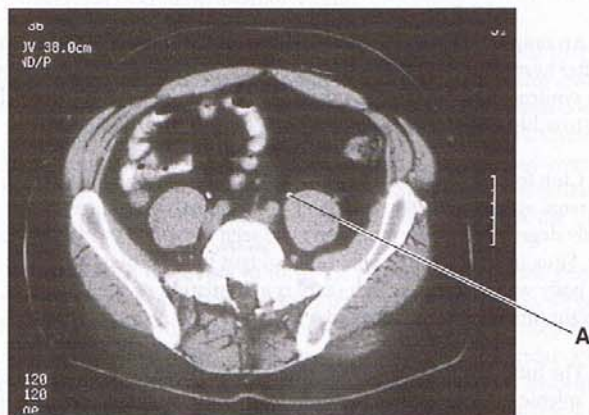
31. Which structure can be palpated anterior to the cervix during a pelvic exam?
 - (A) Pelvic diaphragm
 - (B) Cardinal ligament
 - (C) Ovary
 - (D) Ureter
 - (E) Trigone of bladder
32. A young male suffers a traumatic injury that lacerates the penile urethra. Urine leaks out into the perineum. Where else might the extravasated urine be found?
 - (A) Ischioanal fossa
 - (B) Anterior thigh
 - (C) Anterior abdominal wall
 - (D) Rectovesical pouch
 - (E) Deep perineal pouch
33. A male patient develops malignant testicular carcinoma. Which lymph nodes are most likely to be involved first by a metastasis?
 - (A) Internal iliac
 - (B) External iliac
 - (C) Superficial inguinal
 - (D) Para-aortic
 - (E) Deep inguinal
34. Which of the following structures develops in the ventral mesentery?
 - (A) Spleen
 - (B) Jejunum
 - (C) Head of the pancreas
 - (D) Transverse colon
 - (E) Stomach
35. A female patient presents with a femoral hernia. Which structure is the surgeon most likely to see just lateral to the hernial sac?
 - (A) Femoral nerve
 - (B) Sartorius muscle
 - (C) Femoral vein
 - (D) Femoral artery
 - (E) Adductor longus muscle
36. Failure of fusion of the paramesonephric ducts gives rise to a bicornuate uterus. What else may show a congenital defect?
 - (A) Ureters
 - (B) Bladder
 - (C) Upper part of the vagina
 - (D) Labia minora
 - (E) Vestibule

37. An adult man with adult polycystic kidney disease (APKD) suddenly collapses and dies. The cause of death can be attributed to
- (A) occlusive stroke
 - (B) ruptured berry aneurysm
 - (C) pulmonary embolism
 - (D) obstructive hydrocephalus
 - (E) myocardial infarction
38. In the following cross-sectional image, which of the labeled structures will drain into the hepatic portal vein?



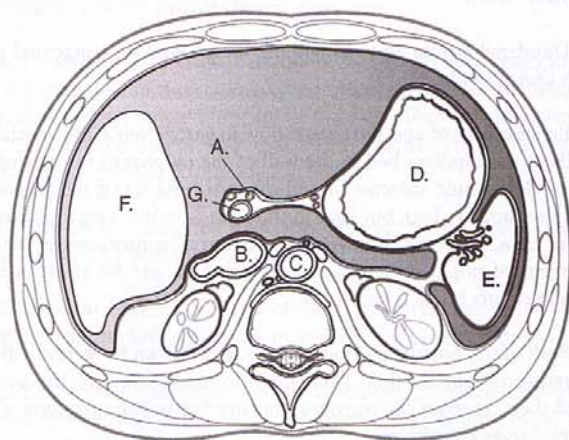
- (A) A
- (B) B
- (C) C
- (D) D

39. In the following cross-sectional image, the structure labeled at "A" is derived from:



- (A) cardinal vein
- (B) urogenital sinus
- (C) mesonephric duct
- (D) paramesonephric duct
- (E) vitelline vein

40. The structure indicated by the arrow at "A"



- (A) drains into the inferior vena cava
- (B) transports bile to the lumen of the duodenum
- (C) will be dilated in portal hypertension
- (D) supplies oxygenated blood to liver sinusoids
- (E) supplies structures derived from the midgut

Answers and Explanations

1. **Answer: E.** The spleen is a hemopoietic and lymph organ derived from mesoderm.
2. **Answer: E.** An omphalocele is caused by a failure of the midgut to return to the abdominal cavity after herniation into the umbilical stalk. Choices A and D may be seen in infants with Down syndrome; choice D is the specific cause of duodenal atresia. Choice C is the cause of gastroschisis, and Choice B results in a Meckel diverticulum.
3. **Answer: A.** Club foot, facial anomalies, and pulmonary hypoplasia are three features seen in bilateral renal agenesis (Potter sequence). Urachal cyst may be seen if the allantois fails to completely degenerate. Berry aneurysms are seen in patients with adult polycystic kidney disease. Situs inversus is seen when the midgut fails to rotate properly. Gastroschisis is a ventral body wall defect in which there is a herniation of the midgut at a weak point where the right umbilical vein regressed.
4. **Answer: B.** The fundus of the stomach is supplied by short gastric branches of the splenic artery. The splenic artery supplies the body and tail of the pancreas, part of the greater curvature of the stomach, and the spleen. The jejunum, part of the head of the pancreas, and the duodenum distal to the entrance of the common bile duct are supplied by the superior mesenteric artery, and the lesser curvature and the pyloric antrum are supplied by the right and left gastric arteries.
5. **Answer: C.** The omental bursa, or lesser peritoneal sac, lies directly posterior to the proximal part of the duodenum and the stomach and would be the first site where stomach contents would be found.
6. **Answer: C.** A defect in a pleuroperitoneal membrane (usually the left) is the typical site of a congenital diaphragmatic hernia where the membrane fails to close one of the pericardioperitoneal canals.
7. **Answer: E.** Duodenal atresia and aganglionic megacolon are congenital defects seen in patients with Down syndrome.
8. **Answer: D.** Enlargement of and retrograde flow in gastric veins, in particular the left gastric veins, dilates the capillary bed in the wall of the esophagus in cases of portal hypertension. Blood flow would increase in and dilate tributaries of the azygous vein on the other side of the capillary bed, but flow in this vein is in the typical direction toward the superior vena cava. Paraumbilical vein engorgement contributes to a caput medusa. Splenic enlargement might present with splenomegaly, and backflow in to the superior mesenteric vein occurs but is asymptomatic.
9. **Answer: D.** Both of the ejaculatory ducts empty sperm from the epididymis by way of the ductus deferens and seminal fluid from the seminal vesicle into the prostatic urethra. Seminal fluid then traverses the membranous urethra in the urogenital diaphragm and penile urethra during ejaculation.
10. **Answer: D.** The patient has an indirect inguinal hernia, which emerges from the anterior abdominal wall through the deep inguinal ring. The deep ring is a fault in the transversalis fascia; this layer will be penetrated first by the hernia.

11. **Answer: C.** The ilioinguinal nerve, which provides sensation to the medial thigh and anterior scrotum, passes through the superficial inguinal ring and is subject to injury because it is in the operation field of the herniorrhaphy.
12. **Answer: B.** The lesser splanchnic nerves are sympathetic nerves that carry visceral sensations from inflamed or stretched gastrointestinal structures (in this case the appendix) into the CNS. Lesser splanchnic nerves arise from the T9–T12 spinal cord segments and provide sympathetic innervation to midgut structures, which include the appendix. Visceral pain arising from affected midgut structures is referred over the same dermatomes of spinal segments, which provide the sympathetic innervation. In this case of appendicitis, the involvement of the area of the umbilicus includes the T10 dermatome.
13. **Answer: B.** These folds must fuse to form the ventral aspect of the penis and scrotum. Here, the penile urethra opens onto the ventral aspect of the penis. Degeneration of the ureteric bud is a cause of oligohydramnios. Absence of androgen receptors in the external genitalia and 5 alpha-reductase 2 deficiency are causes of testicular feminization syndrome and stunted growth of male external genitalia, respectively. Inadequate production of müllerian inhibitory substance is also caused by a 5 alpha-reductase 2 deficiency.
14. **Answer: E.** Compression of the prostatic urethra may also compress the ejaculatory duct and limit flow of seminal fluid from the ampulla of the ductus deferens and seminal vesicle through the ejaculatory duct and into the prostatic urethra. A hydrocele is caused by a small fluid accumulation in a patent remnant of the processus vaginalis. Urine leaking from the umbilicus might occur only if a patent urachus is present. In older men, compression of the prostatic urethra results in an increase in urinary pressure and filling of a patent urachus. Retrograde flow of the urine through the patent urachus may result in leaking of urine from the umbilicus. Urinary incontinence due to weakness of the sphincter urethrae muscle may be caused by a lesion of the pudendal nerve. A varicocele is an accumulation of venous blood in the pampiniform plexus of the testicular vein, which may be caused by compression of the left renal vein.
15. **Answer: A.** Prostate surgery may affect the branches of pelvic splanchnic nerves, which innervate the prostate and then course to the erectile tissues of the penis. The levator ani is innervated by skeletal motor branches from S2–S4. The pudendal nerve carries general sensation from the perineum and innervates external anal and urethral sphincters. Sympathetic nerves prevent retrograde ejaculation.
16. **Answer: C.** The testis is supplied by a direct branch of the abdominal aorta. All other choices are supplied by branches of the internal iliac artery.
17. **Answer: B.** The ischial spine is palpated through the lateral wall of the vagina to guide the needle to the pudendal nerve at the point where it crosses the spine.
18. **Answer: A.** The skeletal sphincter urethrae or external urethral sphincter muscle is the bladder sphincter muscle under voluntary control and is innervated by the pudendal nerve. This muscle is located in the urogenital diaphragm.
19. **Answer: C.** Muscles in the pelvic diaphragm (levator ani) contract to increase intra-abdominal pressure during the Valsalva maneuver.
20. **Answer: B.** Of the five choices, only the descending colon is retroperitoneal and would be a likely choice to be seen immediately adjacent to the posterior abdominal wall.

21. **Answer: D.** Herniation of abdominal structures into the fetal thorax may impede lung development.
22. **Answer: D.** The splenic vein courses posterior to the body of the pancreas on its way to drain into the superior mesenteric vein.
23. **Answer: C.** This is a case of complete androgen insensitivity syndrome (CAIS) in which a mutation in the androgen receptor gene renders the androgen receptors inactive. Thus, despite a male karyotype, the external genitalia are female, but testes develop and attempt to descend through the inguinal canals.
24. **Answer: D.** The seminal vesicles lie on the posterior wall of the bladder and can be evaluated in a digital rectal exam.
25. **Answer: B.** The urogenital ridge and the paramesonephric duct are both derived from mesoderm, and primordial gametes are the only significant cell type derived from the wall of the yolk sac.
26. **Answer: C.** The ampulla of the uterine tube is the most common site of both fertilization and ectopic implantation.
27. **Answer: D.** Blood and fluid from a burst tubal pregnancy will accumulate in the pouch of Douglas.
28. **Answer: C.** The transverse cervical or cardinal ligaments are condensations of fascia in the base of the broad ligaments, which help prevent prolapse.
29. **Answer: B.** The gastroduodenal artery, a direct branch of the common hepatic artery, courses immediately posterior to the duodenum and is subject to erosion.
30. **Answer: B.** Carcinoma of the pancreas in the head may compress the portal vein at its origin. The portal vein is formed when the splenic vein joins with the superior mesenteric vein. The inferior mesenteric vein joins the splenic vein just prior to the point at which the splenic joins the superior mesenteric vein. Increased venous pressure in the inferior mesenteric vein is a cause of hemorrhoids.
31. **Answer: E.** The trigone of the bladder is directly anterior to the uterine cervix.
32. **Answer: C.** The fascia covering the penile urethra covers the superficial perineal pouch and is continuous with the deep fascia lining the anterior abdominal wall.
33. **Answer: D.** Gonadal carcinomas metastasize initially to para-aortic nodes.
34. **Answer: C.** The ventral pancreas, which forms most of the head of the pancreas, develops in the ventral mesentery as an outgrowth of the hepatic diverticulum. The hepatic diverticulum, including the biliary apparatus, develops in the ventral mesentery of the foregut.
35. **Answer: C.** The femoral vein lies immediately lateral to the femoral canal, the site of protrusion of a femoral hernia.

36. **Answer: C.** The upper part of the vagina is formed by a fusion of the paramesonephric ducts.
37. **Answer: B.** Berry aneurysms and mitral valve prolapse are extrarenal manifestations of APKD.
38. **Answer: A.** The superior mesenteric vein joins with the splenic vein to form the hepatic portal vein.
39. **Answer: C.** The structure that contains contrast material is the ureter, which courses inferiorly on the anterior surface of the psoas major muscle. It is derived from the ureteric bud, which is an outgrowth of the mesonephric duct.
40. **Answer: D.** The structure at "A" is the proper hepatic artery, which supplies oxygenated blood to the liver.

Upper Limb

4

BRACHIAL PLEXUS

Lesions of the Brachial Plexus

Upper trunk (C5, C6)

Erb's paralysis affects axillary, suprascapular, and musculocutaneous nerves (Figure III-4-1). Loss of intrinsic muscles of the shoulder. Loss of muscles of the anterior arm. Arm is medially rotated and adducted. The forearm is extended and pronated. Sign is "waiter's tip."

Lower trunk (C8, T1)

Thoracic outlet syndrome. Loss of all the muscles of the forearm and hand. Sign is combination of "claw hand" and "ape hand." May include a Horner syndrome.

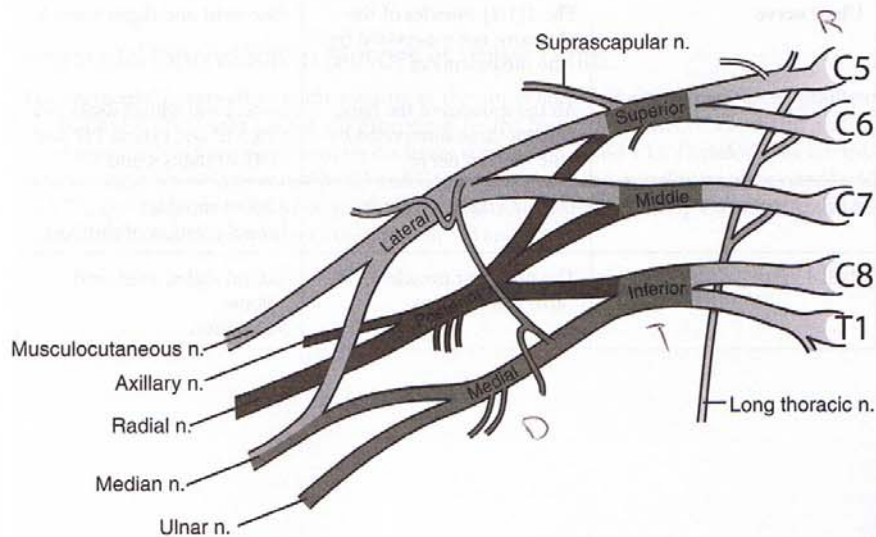


Figure III-4-1. The Brachial Plexus

MUSCLE INNERVATION

Terminal Nerves of Upper Limbs

The motor innervation by the five terminal nerves of the arm muscles is summarized in Table III-4-1.

Table III-4-1. The Motor Innervation by the Five Terminal Nerves

Terminal Nerve	Muscles Innervated	Primary Actions
Musculocutaneous nerve	All the muscles of the anterior compartment of the arm	Flex elbow Supination (biceps brachii)
Median nerve	All the muscles of the anterior compartment of the forearm except 1 [1/2] muscles (flexor carpi ulnaris and the ulnar [1/2] of the flexor digitorum profundus) The 3 thenar compartment muscles and the 1st and 2nd lumbricals	Flex wrist and digits Pronation Opposition (opponens pollicis) Flex MP and extend PIP and DIP of digits 2 and 3
Ulnar nerve	The 1[1/2] muscles of the forearm not innervated by the median nerve All the muscles of the hand except those innervated by the median nerve	Flex wrist and digits 4 and 5 Abduct and adduct digits 2–5 Flex MP and extend PIP and DIP of digits 4 and 5.
Axillary nerve	Deltoid and teres minor	Abduct shoulder Lateral rotation of shoulder
Radial nerve	The posterior muscles of the arm and forearm	Extend digits, wrist, and elbow Supination

Collateral Nerves

In addition to the five terminal nerves, there are several collateral nerves that arise from the brachial plexus proximal to the terminal nerves (i.e., from the rami, trunks, or cords). These nerves innervate proximal limb muscles (shoulder girdle muscles). Table III-4-2 summarizes the collateral nerves.

Table III-4-2. The Collateral Nerves of the Brachial Plexus

Collateral Nerve	Muscles or Skin Innervated
Dorsal scapular nerve	Rhomboids
Long thoracic nerve	Serratus anterior
Suprascapular nerve	Supraspinatus and infraspinatus
Lateral pectoral nerve	Pectoralis major
Medial pectoral nerve	Pectoralis major and minor
Upper subscapular nerve	Subscapularis
Middle subscapular (thoracodorsal) nerve	Latissimus dorsi
Lower subscapular nerve	Subscapularis and teres major
Medial brachial cutaneous nerve	Skin of medial arm
Medial antebrachial cutaneous nerve	Skin of medial forearm

Note

All the muscles that form the walls of the axilla are innervated by collateral nerves: the three posterior wall muscles are innervated by the three subscapular nerves; the two anterior wall muscles are innervated by the two pectoral nerves; and the medial wall muscle is innervated by the long thoracic nerve.

Segmental Innervation to Muscles of Upper Limbs

The **segmental innervation** to the muscles of the upper limbs has a **proximal–distal gradient**, i.e., the more proximal muscles are innervated by the higher segments (C5 and C6) and the more distal muscles are innervated by the lower segments (C8 and T1). Therefore, the intrinsic shoulder muscles are innervated by C5 and C6, the intrinsic hand muscles are innervated by C8 and T1, the distal arm and proximal forearm muscles are innervated by C6 and C7, and the more distal forearm muscles are innervated by C7 and C8.

SENSORY INNERVATION

The sensory innervation of the hand is summarized in Figure III-4-2.

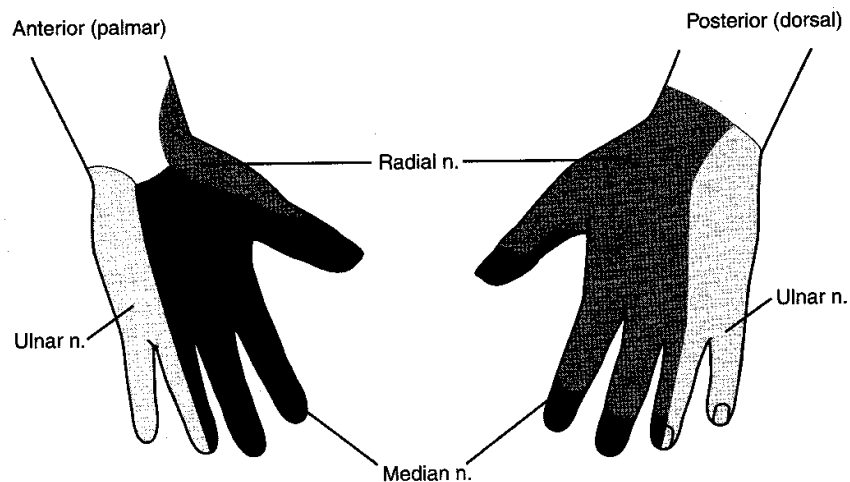


Figure III-4-2. Sensory Innervation of the Hand

NERVE INJURIES

Remember: Follow clues in the questions as to the location of the injury. An injury will manifest in symptoms distal to the site of injury.

Example: Radial nerve cut at the wrist. Sensory loss on the dorsum of the hand. No muscular loss as these are already innervated above the site of the lesion.

Thoughts on Muscle–Nerve Lesions

- Without specifically naming all the muscles, assign a function to the various compartments of the limbs. Example: posterior brachium = extension of the forearm and shoulder.
- List the nerve(s) that innervate those muscles or that area. Example: posterior brachium = radial nerve.
- You have an area of the limb, a function of the muscles within that area, and a nerve responsible for that function.

Now you can damage a nerve and note what function(s) is lost or weakened.

Radial nerve**At the Axilla**

Loss of extensors at the elbow, wrist, and digits; weakened extension at the shoulder; weakened supination. Sensory loss on posterior arm, forearm, and hand. Sign is "wrist drop." Shoulder dislocation may injure the radial nerve. Also, pressure on the floor of axilla may injure nerve (Saturday night palsy).

At the Elbow

Loss of extensors at the wrist and digits. Sensory loss on the posterior forearm and hand. Sign is "wrist drop." Fracture of the shaft of the humerus could lacerate the radial nerve, and the deficits would be the same as if the nerve were damaged at the level of the elbow.

At the Wrist

Sensory loss on the posterior hand (first dorsal web space).

Median nerve**At the Elbow**

Loss of flexion of the digits, thenar muscles, and lumbricals 1 and 2; weakened wrist flexion; ulnar deviation upon flexion of the wrist; loss of pronation. Sensory loss on lateral palm and digits 1, 2, and 3, and one half of 4. Sign is "ape or simian hand" and "flattening of the thenar eminence."

At the Wrist

Loss of function of the thenar muscles and lumbricals 1 and 2; "clawing" of digits 2 and 3. Sensory loss on palmar surface of digits 1, 2, and 3, and one-half of 4. Sign is "ape or simian hand" and "flattening of thenar eminence." Carpal tunnel compression or wrist laceration.

Ulnar nerve**At the Elbow (medial epicondyle)**

Weakened wrist flexion; radial deviation upon flexion of the wrist; loss of abduction and adduction of the digits; loss of hypothenar muscles and lumbricals 3 and 4. Weakened flexion of digits 4 and 5. Sensory loss on digits 5 and one half of 4. Sign is "claw hand."

At the Wrist

Loss of abduction and adduction of the digits; loss of the hypothenar muscles and lumbricals 3 and 4. Sensory loss on digits 5 and one half of 4. Sign is "claw hand."

Axillary nerve

Loss of abduction of the arm to the horizontal plane. The axillary nerve could be damaged with a fracture of the surgical neck of the humerus or dislocation of the shoulder.

Musculocutaneous nerve

Loss of elbow flexion and weakness in supination; loss of sensation on lateral aspect of the forearm.

ARTERIAL SUPPLY AND MAJOR ANASTOMOSES

Arterial Supply to the Upper Limb

Subclavian artery

Branch of brachiocephalic trunk on the right and aortic arch on the left (Figure III-4-3).

Axillary artery

From the first rib to the posterior edge of the teres major muscle.

- Superior thoracic artery
- Thoracoacromial artery
- Lateral thoracic artery—supplies mammary gland
- Subscapular artery—collateral to shoulder
- Posterior humeral circumflex artery—at surgical neck with axillary nerve
- Anterior humeral circumflex artery

Brachial artery

Profunda brachii artery with radial nerve in radial groove—at midshaft of humerus

Radial artery

Deep palmar arch.

Ulnar artery

Common interosseus artery.

Superficial palmar arch.

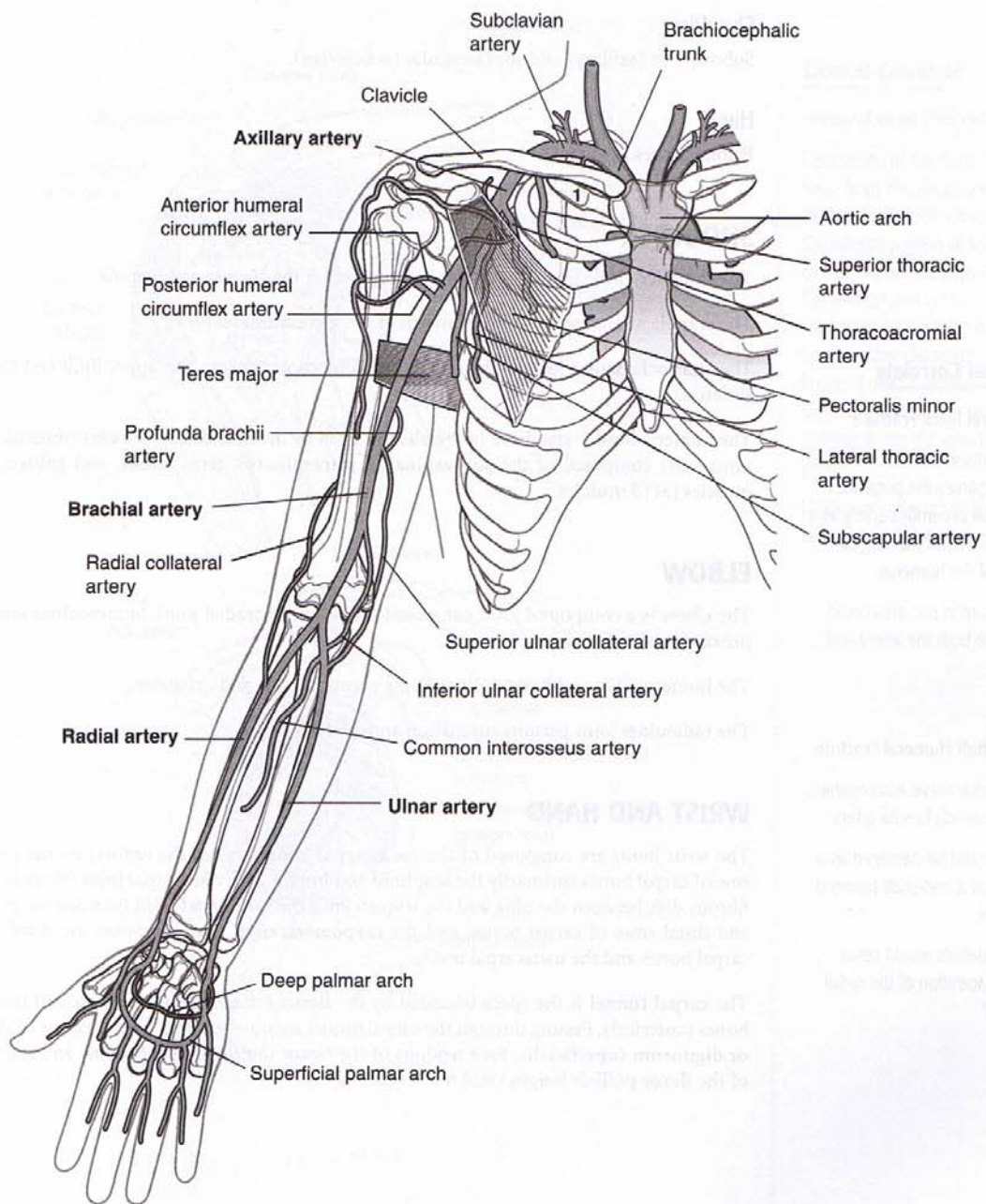


Figure III-4-3. Arterial Supply to the Upper Limb

Clinical Correlate

Humeral Neck Fracture

The axillary nerve accompanies the posterior humeral circumflex artery as it passes around the surgical neck of the humerus.

A fracture in this area could lacerate both the artery and nerve.

Mid-Shaft Humeral Fracture

The radial nerve accompanies the profunda brachii artery.

Both could be damaged as a result of a mid-shaft humeral fracture.

What deficits would result from laceration of the radial nerve?

Collateral Circulation

Shoulder

Subscapular (axillary) and suprascapular (subclavian).

Hand

Palmar arches.

SHOULDER

The shoulder girdle (pectoral girdle) is composed of the clavicle and scapula.

The scapula articulates with the humerus at the **glenohumeral joint**.

The **sternoclavicular joint** is the only bony connection between the upper limb and the axial skeleton.

The humeral head is stabilized in the glenoid fossa by the rotator cuff muscles (musculotendinous cuff) composed of the **supraspinatus**, **infraspinatus**, **teres minor**, and **subscapularis** muscles (SITS muscles).

ELBOW

The elbow is a compound joint composed of the humeroradial joint, humeroulnar joint, and proximal radioulnar joint.

The humeroradial and humeroulnar joints permit flexion and extension.

The radioulnar joint permits supination and pronation.

WRIST AND HAND

The wrist joints are composed of the **radiocarpal joint** between the radius and the proximal row of carpal bones (primarily the **scaphoid** and **lunate**), the **ulnocarpal joint** (there is a small fibrous disk between the ulna and the triquetrum), the **midcarpal joint** between the proximal and distal rows of carpal bones, and the **carpometacarpal joints** between the distal row of carpal bones and the metacarpal bones.

The **carpal tunnel** is the space bounded by the **flexor retinaculum** anteriorly and the carpal bones posteriorly. Passing through the carpal tunnel are nine tendons (four tendons of the **flexor digitorum superficialis**, four tendons of the **flexor digitorum profundus**, and the tendon of the **flexor pollicis longus**) and the **median nerve**.

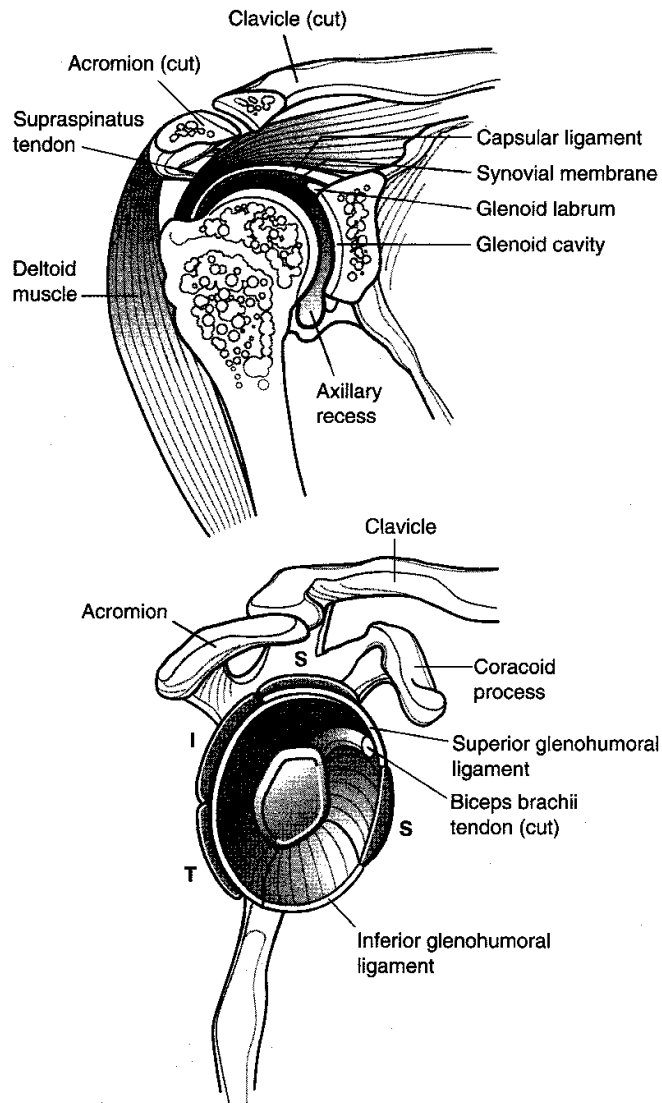


Figure III-4-4.

Clinical Correlate

Humeral Head Dislocation

Dislocation of the humeral head from the glenohumeral joint typically occurs through the inferior portion of the joint capsule where the capsule is the slackest and is not reinforced by a rotator cuff tendon. After dislocation, the humeral head is pulled superiorly and comes to lie anterior to the glenohumeral joint.

Dislocation may injure the axillary or radial nerve.

Clinical Correlate

Elbow Dislocation

Dislocation of the elbow typically involves posterior displacement of the ulna and anterior displacement of the humerus. This dislocation may damage the **ulnar nerve** as it passes behind the medial epicondyle, the **median nerve** as it passes anterior to the elbow, and the **brachial artery** as it passes anterior to the elbow.

Volkman Contracture

Compression of the brachial artery may result in ischemic contracture (Volkman's contracture) in the hand.

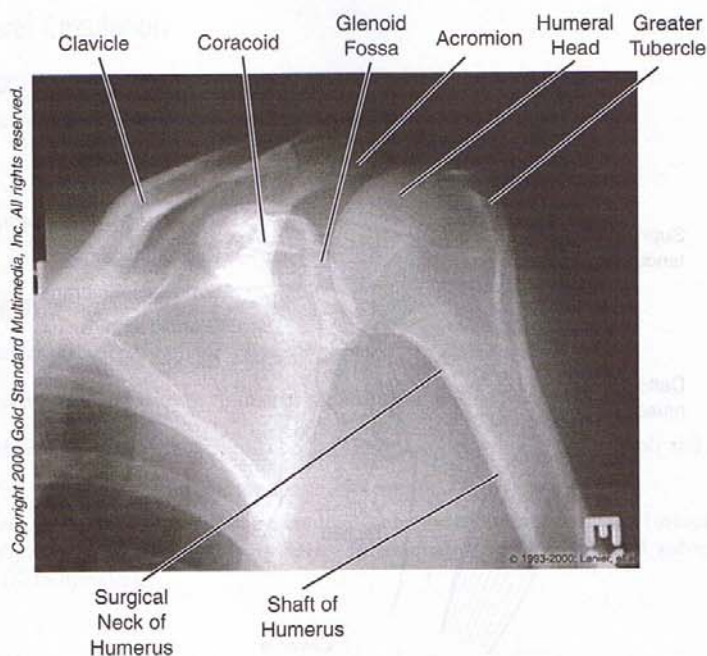


Figure III-4-5. Upper Extremities: Anteroposterior View of Shoulder (External Rotation)

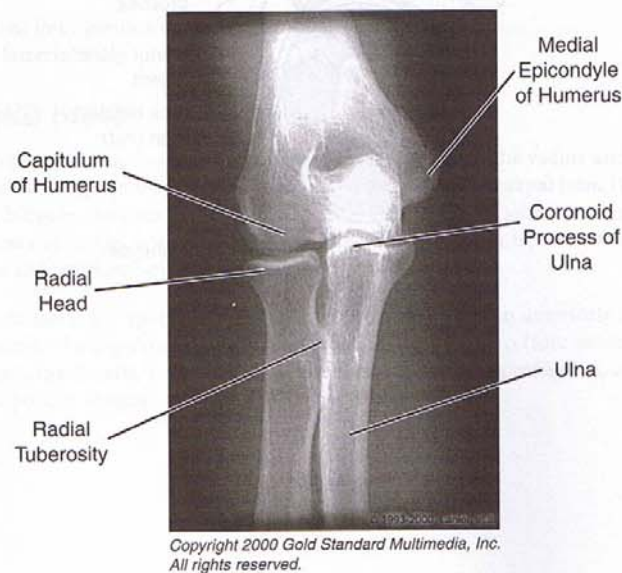


Figure III-4-6. Upper Extremities: Anteroposterior View of Elbow

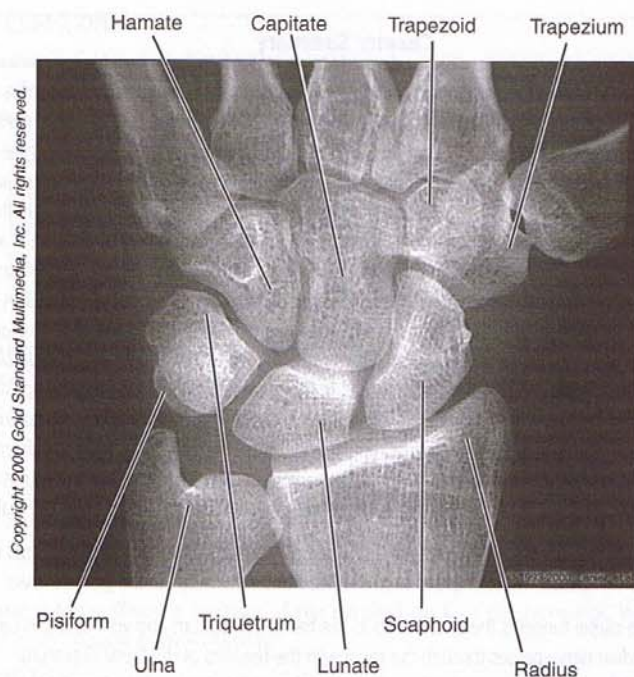
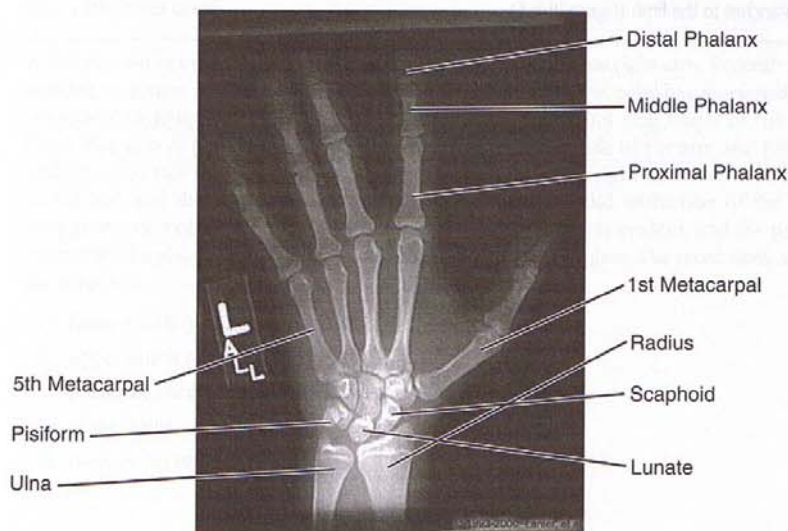


Figure III-4-7. Upper Extremities: Posteroanterior View of Wrist



Copyright 2000 Gold Standard Multimedia, Inc.
All rights reserved.

Figure III-4-8. Upper Extremities: Posteroanterior View of Wrist and Hand

Clinical Correlate

The **scaphoid** is the most frequently fractured of the carpal bones. This fracture may separate the proximal head of the scaphoid from its blood supply (which enters the bone at the distal head) and may result in **avascular necrosis** of the proximal head.

The **lunate** is the most commonly dislocated carpal bone (it dislocates anteriorly into the carpal tunnel and may compress the median nerve).

Clinical Correlate

Carpal Tunnel Syndrome

Results from compression of the median nerve within the tunnel.

Fracture of the Hook of the Hamate

A fall on the outstretched hand may fracture the hook of the hamate, which may damage the ulnar nerve as it passes into the hand.

Chapter Summary

The motor and sensory supply of the upper limb is provided by the brachial plexus. The plexus is formed by the ventral rami of spinal nerves C5–T1. These rami form superior, middle, and inferior trunks in the posterior triangle of the neck. Anterior and posterior division fibers from each of the three trunks enter the axilla and establish the innervation of the muscles in the anterior and posterior compartment of the limb. The compartments of the limb and their innervations are given in Table III-4-1. In the axilla, cords of the brachial plexus are formed and give rise to many of the named branches of the brachial plexus including the five terminal branches: musculocutaneous, median, ulnar, radial, and axillary nerves. Damage to the upper trunk (C5 and C6) of the brachial plexus (Erb paralysis) results in the arm being medially rotated and adducted with the forearm extended and pronated due to loss of the axillary, suprascapular, and musculocutaneous nerves. A lower trunk (C8 and T1) lesion causes a combined claw and ape hand. Other major lesions of branches of the brachial plexus include wrist drop (radial nerve), ape hand (median nerve), claw hand (ulnar nerve), loss of elbow flexion (musculocutaneous nerve), and loss of shoulder abduction (suprascapular and axillary nerves). Sensory supply from the palmar surface of the hand is supplied by the median nerve (laterally) and the ulnar nerve (medially) and on the dorsal surface of the hand by the radial nerve (laterally) and the ulnar nerve (medially).

The shoulder joint is supported by the rotator cuff muscles: supraspinatus, infraspinatus, teres minor, and subscapularis muscles. These muscles hold the head of the humerus in the glenoid fossa.

At the wrist, the carpal tunnel is the space deep to the flexor retinaculum and ventral to the carpal bones. The median nerve passes through the canal with the tendons of the flexor digitorum superficialis and flexor digitorum profundus and the tendon of the flexor pollicis longus muscle. There are no vessels in the carpal tunnel.

The arteries that supply blood to the upper limb are a continuation of the subclavian artery. The axillary, brachial, radial, ulnar, and the superficial and deep palmar arch arteries give rise to a number of branches to the limb (Figure III-4-3).

Review Questions

1. A patient experiences radial deviation of the hand at the wrist when he flexes the wrist and altered sensation in the skin covering the hypothenar eminence. What is the most likely cause of these symptoms?
 - (A) Fracture of the scaphoid bone
 - (B) Fracture of the medial epicondyle of the humerus
 - (C) Fracture of surgical neck of the humerus
 - (D) Fracture of the distal end of the radius
 - (E) Anterior and inferior dislocation of the head of the humerus
2. A patient develops a significant clawing of the fourth and fifth digits secondary to nerve injury. Which muscle has been weakened and therefore results in the clawing?
 - (A) Extensor digitorum
 - (B) Lumbrical
 - (C) Flexor digitorum superficialis
 - (D) Dorsal interosseous
 - (E) Flexor digiti minimi
3. A patient has suffered a fracture of the surgical neck of the humerus. Which muscle is most likely to have been weakened?
 - (A) Deltoid
 - (B) Supraspinatus
 - (C) Biceps brachii
 - (D) Teres major
 - (E) Latissimus dorsi
4. A 39-year-old man has suffered for many years from pains in his right arm. Recently, after moving to a new job that requires carrying heavy parcels, the pain has worsened, and occasional tingling and numbness is felt in the little finger and ring finger of the right hand. The area of pain in the limb is localized to the medial side of the arm and forearm and the ulnar side of the hand. General muscle strength in the right extremity is less than in the left, and there is particular weakness of opposition and adduction of the right thumb. Wasting of the right hypothenar and thenar eminence is evident, and the patient cannot hold a piece of paper between his index and middle fingers. The most likely site of the injury is
 - (A) lower trunk of the brachial plexus
 - (B) upper trunk of the brachial plexus
 - (C) posterior cord of the brachial plexus
 - (D) ulnar nerve
 - (E) median nerve

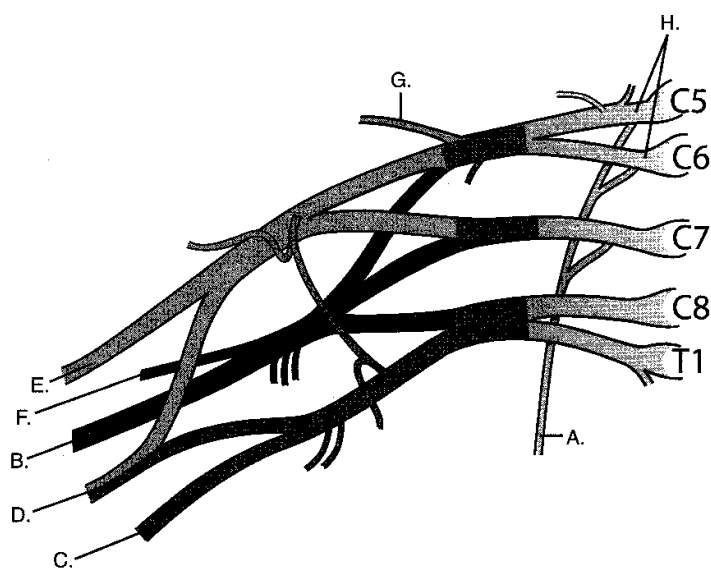
5. A man who uses hand tools for a living begins to develop pain and paresthesia in his right hand at night. The altered sensation is most evident on the palmar aspects of the index and middle fingers. What else are you most likely to see in this patient?
 - (A) Atrophy of the thenar eminence
 - (B) Weakness in extension of the thumb
 - (C) Radial deviation of the hand at the wrist during wrist flexion
 - (D) Altered sensation in skin over the anatomic snuffbox
 - (E) Inability to spread the fingers

6. A 20-year-old man stated that he was unable to raise his right arm. Questioning revealed that he had been involved in a motorcycle accident, at which time he had been thrown from the motorcycle and had hit his shoulder against a tree. The patient held his upper limb limply at his side, with the arm medially rotated and the hand pronated. Muscles covering the shoulder joint showed significant wasting. The most likely site of the injury is the
 - (A) lower trunk of the brachial plexus
 - (B) upper trunk of the brachial plexus
 - (C) posterior cord of the brachial plexus
 - (D) axillary nerve
 - (E) radial nerve

7. The axillary artery has become progressively occluded deep to the pectoralis minor muscle. Which pair of blood vessels would most likely provide a significant collateral circulation around the blockage?
 - (A) Posterior humeral circumflex artery and anterior humeral circumflex artery
 - (B) Subscapular artery and posterior humeral circumflex artery
 - (C) Subscapular artery and suprascapular artery
 - (D) Lateral thoracic artery and supreme thoracic artery
 - (E) Posterior humeral circumflex artery and profunda brachial artery

8. Your patient has fallen on his outstretched hand and has dislocated a carpal bone. The patient does not seek treatment, and several weeks later he begins to exhibit signs of nerve compression. The patient is most likely to present with which of the following conditions?
 - (A) Wrist drop
 - (B) Clawing of ring and index fingers
 - (C) Inability to spread and oppose the fingers
 - (D) Weakness in the ability to oppose the thumb
 - (E) Pain on the palmar aspects of the ring and little fingers

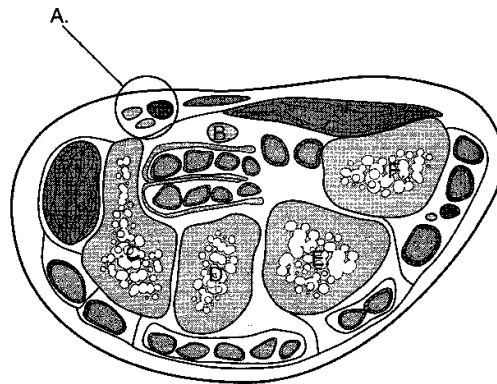
Questions 9 and 10 are based on the figure below.



9. A rock hits a 10-year-old child on the chest wall just below the axilla. Several days later, during gym class, the child has difficulty doing push-ups. Which letter in the figure above identifies the injured neural structure?
 - (A) A
 - (B) B
 - (C) C
 - (D) D
 - (E) E
 - (F) F
 - (G) G
 - (H) H

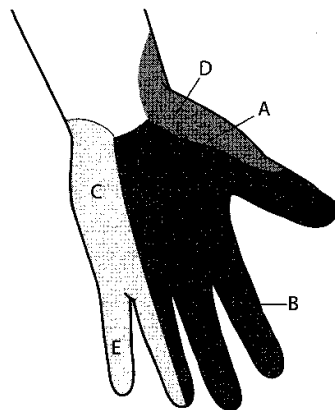
10. A humeral fracture results in wrist drop in your patient. Which letter in the figure above identifies the injured neural structure?
 - (A) A
 - (B) B
 - (C) C
 - (D) D
 - (E) E
 - (F) F
 - (G) G
 - (H) H

11. In the cross-section below, a lesion of a nerve at "A" would result in



Cross section of the wrist

- (A) paresthesia of the lateral aspect of the palm
 - (B) wrist drop
 - (C) paresthesia in skin over the anatomic snuffbox
 - (D) inability to press the pulp of the thumb against the pulp of the index finger
 - (E) inability to spread the fingers
12. Referring to the figure below, extension of the interphalangeal joints of the digit indicated by "E" is controlled by the



- (A) ulnar nerve
- (B) radial nerve
- (C) median nerve
- (D) axillary nerve
- (E) musculocutaneous nerve

Answers and Explanations

1. **Answer: B.** Fracture of the medial epicondyle of the humerus may compress the ulnar nerve. Fracture of the scaphoid bone produces pain over the anatomic snuffbox but no nerve compression. Fracture of surgical neck of the humerus might affect the axillary nerve. Fracture of the distal end of the radius might affect the radial nerve. Anterior and inferior dislocation of the head of the humerus might affect either the axillary or the radial nerve.
2. **Answer: B.** Loss of the medial two lumbrical muscles innervated by the ulnar nerve is the main reason for the clawing of digits 4 and 5. Lumbricals produce flexion at the metacarpophalangeal joints and extension at the interphalangeal joints; clawing results in extension at the metacarpophalangeal joints and flexion at the interphalangeal joints.
3. **Answer: A.** The deltoid is innervated by the axillary nerve, which courses near the surgical neck of the humerus.
4. **Answer: A.** The patient has a combination of signs that can be attributed to an ulnar nerve lesion and a median nerve lesion. The lower trunk of the brachial plexus contains C8 and T1 fibers, which are found in both the median and ulnar nerves and is the likely site of a single lesion affecting fibers in both nerves.
5. **Answer: A.** The man most likely has carpal tunnel syndrome affecting the median nerve. In addition to altered sensation over the palmar aspects of the lateral digits, median nerve compression may result in a loss of opposition due to atrophy of muscles in the thenar eminence.
6. **Answer: B.** The upper trunk of the brachial plexus has been lesioned, producing a waiter's tip position of the upper limb. Proximal musculature in the upper limb has been most affected.
7. **Answer: C.** An anastomosis between the suprascapular artery—a branch of the thyrocervical trunk and the subscapular, which branches from the axillary distal to the site of the blockage—will provide collateral circulation around the blockage.
8. **Answer: D.** The most commonly dislocated carpal bone is the lunate. The lunate typically dislocates anteriorly and compresses the median nerve, leading to altered sensation over the palmar aspects of the lateral digits and to a weakness in thumb opposition.
9. **Answer: A.** The injured nerve is at "A," the long thoracic nerve, which results in a winged scapula at rest, a severe weakness in the ability to protract the scapula.
10. **Answer: B.** The injured structure is the radial nerve indicated by the letter B.
11. **Answer: E.** A lesion of the ulnar nerve at the wrist may result in an inability to spread and oppose the fingers.
12. **Answer: A.** The ulnar nerve innervates two lumbricals and interosseous muscles, which extend at the interphalangeal joints.

Lower Limb

5

LUMBOSACRAL PLEXUS

The lumbosacral plexus is formed by the anterior rami of spinal nerves L1 through S4 (Figure III-5-1). The innervation of the lower limb arises from segments L2 through S3. The major nerves of the lower limb are the:

- **Femoral nerve**—posterior divisions of L2 through L4
- **Obturator nerve**—anterior divisions of L2 through L4
- **Tibial nerve**—anterior divisions of L4 through S3
- **Common peroneal (fibular) nerve**—posterior divisions of L4 through S2

The tibial nerve and common peroneal nerve travel together through the gluteal region and thigh in a common connective tissue sheath and together are called the **sciatic nerve**.

The common peroneal nerve divides in the proximal leg into the **superficial and deep peroneal nerves**.

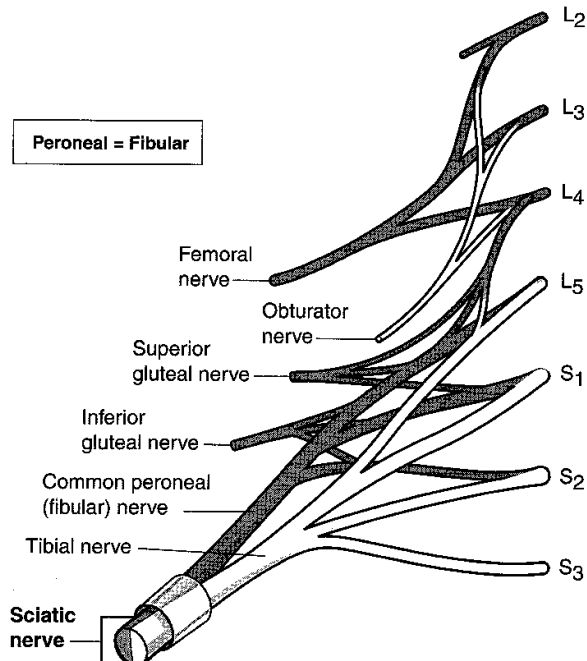


Figure III-5-1. Lumbosacral Plexus

Terminal Nerves of Lumbosacral Plexus

The terminal nerves of the lumbosacral plexus are described in Table III-5-1.

Table III-5-1. Terminal Nerves of Lumbosacral Plexus

Terminal Nerve	Origin	Muscles Innervated	Primary Actions
Femoral nerve	L2 through L4 posterior divisions	Anterior compartment of thigh (quadriceps femoris, sartorius, pectineus)	Extend knee
Obturator nerve	L2 through L4 anterior divisions	Medial compartment of thigh (gracilis, adductor longus, adductor brevis, anterior portion of adductor magnus)	Adduct thigh Medially rotate thigh
Tibial nerve	L4 through S3 anterior divisions	Posterior compartment of thigh (semimembranosus, semitendinosus, long head of biceps femoris, posterior portion of adductor magnus) Posterior compartment of leg (gastrocnemius, soleus, flexor digitorum longus, flexor hallucis longus, tibialis posterior) Plantar muscles of foot	Flex knee Extend thigh Plantar flex foot Flex digits Inversion
Common peroneal (fibular) nerve	L4 through S2 posterior divisions	Short head of biceps femoris	Flex knee
Superficial peroneal (fibular) nerve		Lateral compartment of leg (peroneus longus, peroneus brevis)	Eversion
Deep peroneal (fibular) nerve		Anterior compartment of leg (tibialis anterior, extensor hallucis, extensor digitorum, peroneus tertius)	Dorsiflex foot Extend digits Inversion

Collateral Nerves of Lumbosacral Plexus

The collateral nerves of the lumbosacral plexus (to the lower limb) are summarized in Table III-5-2.

Table III-5-2. Collateral Nerves of Lumbosacral Plexus

Collateral Nerve	Origin	Muscles or Skin Innervated	Primary Actions
Superior gluteal nerve	L4 through S1 posterior divisions	Gluteus medius, gluteus minimus, tensor fasciae latae	Stabilize pelvis
Inferior gluteal nerve	L5 through S2 posterior divisions	Gluteus maximus	Extension of hip Lateral rotation of thigh
Nerve to superior gemellus and obturator internus	L5 through S2 posterior divisions	Superior gemellus, obturator internus	Lateral rotation of thigh
Nerve to inferior gemellus and quadratus femoris	L4 through S1 posterior divisions	Inferior gemellus, quadratus femoris	Lateral rotation of thigh
Lateral femoral cutaneous nerve	L2 through L3 posterior divisions	Skin of anterolateral thigh	—
Posterior femoral cutaneous nerve	S1 through S2 posterior divisions and S2 through S3 anterior divisions	Skin of posterior thigh	—

Segmental Innervation to Muscles of Lower Limb

The **segmental innervation** to the muscles of the lower limb has a **proximal–distal gradient**, i.e., the more proximal muscles are innervated by the higher segments and the more distal muscles are innervated by the lower segments.

- The muscles that cross the **anterior side of the hip** are innervated by **L2 and L3**.
- The muscles that cross the **anterior side of the knee** are innervated by **L3 and L4**.
- The muscles that cross the **anterior side of the ankle** are innervated by **L4 and L5**.
- The muscles that cross the **posterior side of the hip** are innervated by **L4 and L5**.
- The muscles that cross the **posterior side of the knee** are innervated by **L5 and S1**.
- The muscles that cross the **posterior side of the ankle** are innervated by **S1 and S2**.

NERVE INJURIES AND ABNORMALITIES OF GAIT

Superior Gluteal Nerve

Causes loss of abduction of the limb; impairment of gait; patient cannot keep pelvis level when standing on one leg. Sign is "Trendelenburg gait."

Inferior Gluteal Nerve

Produces a weakened hip extension; patient has difficulty rising from a sitting position or climbing stairs.

Femoral Nerve

Induces weakened hip flexion; loss of extension of the knee. Sensory loss occurs on the anterior thigh, medial leg, and foot.

Obturator Nerve

Causes a loss of adduction of the thigh as well as sensory loss on medial thigh.

Sciatic Nerve

Brings about a weakened extension of the thigh; loss of flexion of the knee; and loss of function below the knee. Sensory loss on the posterior thigh, leg (except medial side), and foot is also observed.

Tibial nerve only

Causes a loss of flexion of the knee and digits; loss of plantar flexion; weakened inversion and sensory loss on the leg (except medial) and plantar foot.

Common peroneal nerve

Produces a combination of deficits of lesion of the deep and superficial peroneal nerves. Sign is "foot drop."

- Deep peroneal nerve—weakens inversion; loss of extension of the digits; loss of dorsiflexion "foot drop." Sensory loss on anterolateral leg and dorsum of the foot.
- Superficial peroneal nerve—loss of eversion of the foot. Sensory loss on dorsum of foot except the first web space.

Sensory Innervation of the Lower Leg and Foot

The salient features of the sensory innervation of the lower leg and foot are shown in Figure III-5-2.

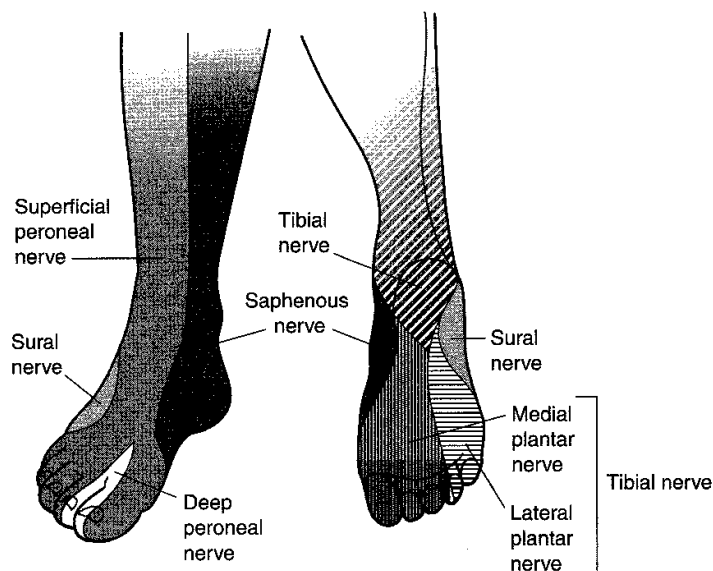


Figure III-5-2. Sensory Innervation of the Lower Leg and Foot

ARTERIAL SUPPLY AND MAJOR ANASTOMOSES

Figure III-5-3 illustrates the arterial supply to the legs.

External iliac artery

Femoral artery

Profunda femoris artery

Medial circumflex femoral artery

Lateral circumflex femoral artery

Popliteal artery

Anterior tibial artery

Dorsalis pedis artery

Posterior tibial artery

Peroneal artery

Lateral plantar

Plantar arterial arch

Medial plantar artery

Obturator artery

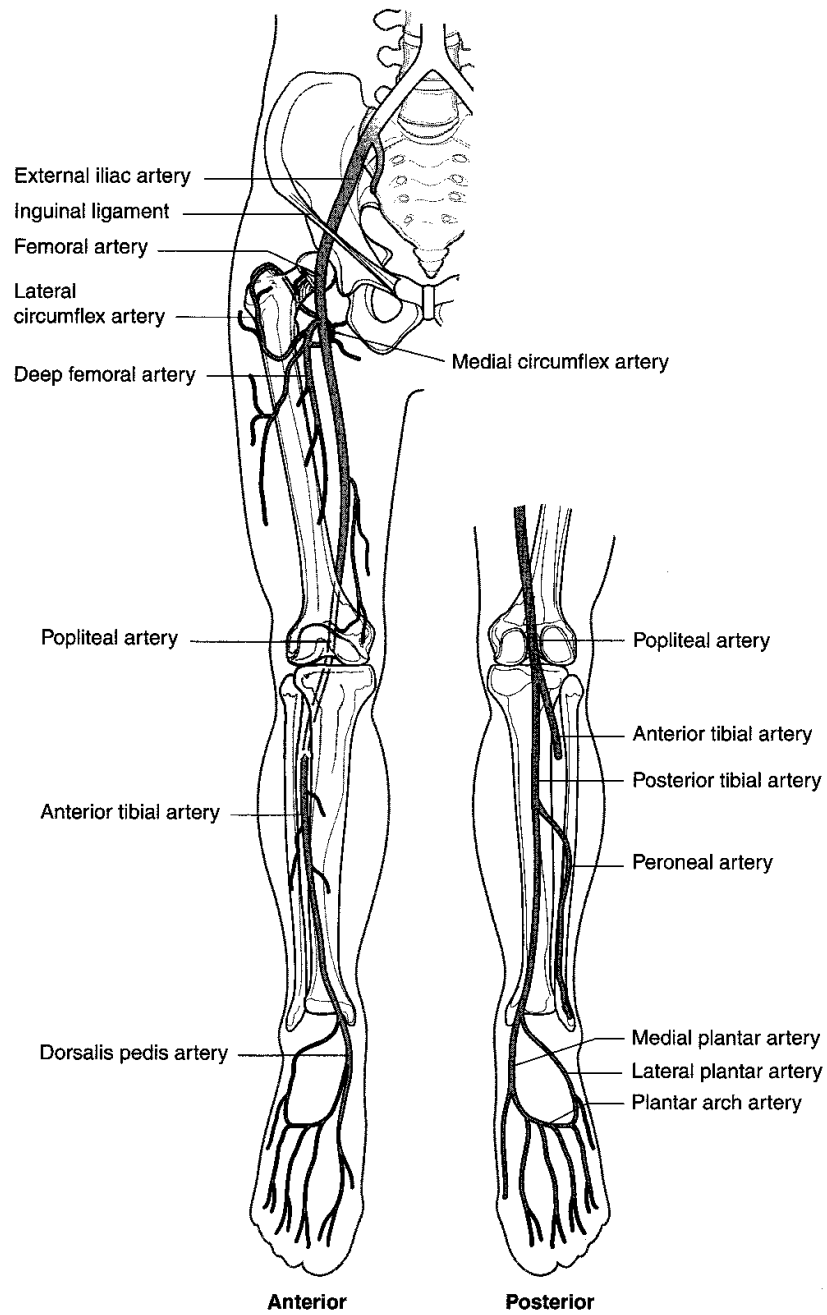


Figure III-5-3. Arterial Supply to the Lower Limb

HIP

The hip joint is formed by the **head of the femur** and the **acetabulum**.

The fibrous capsule of the hip joint is reinforced by three ligamentous thickenings: **iliofemoral ligament**, **ischiofemoral ligament**, and **pubofemoral ligament**.

Most of the blood supply to the head of the femur (arising mostly from the medial femoral circumflex artery) ascends along the neck of the femur. Fracture of the femoral neck can compromise this blood supply and lead to **avascular necrosis of the head of the femur**.

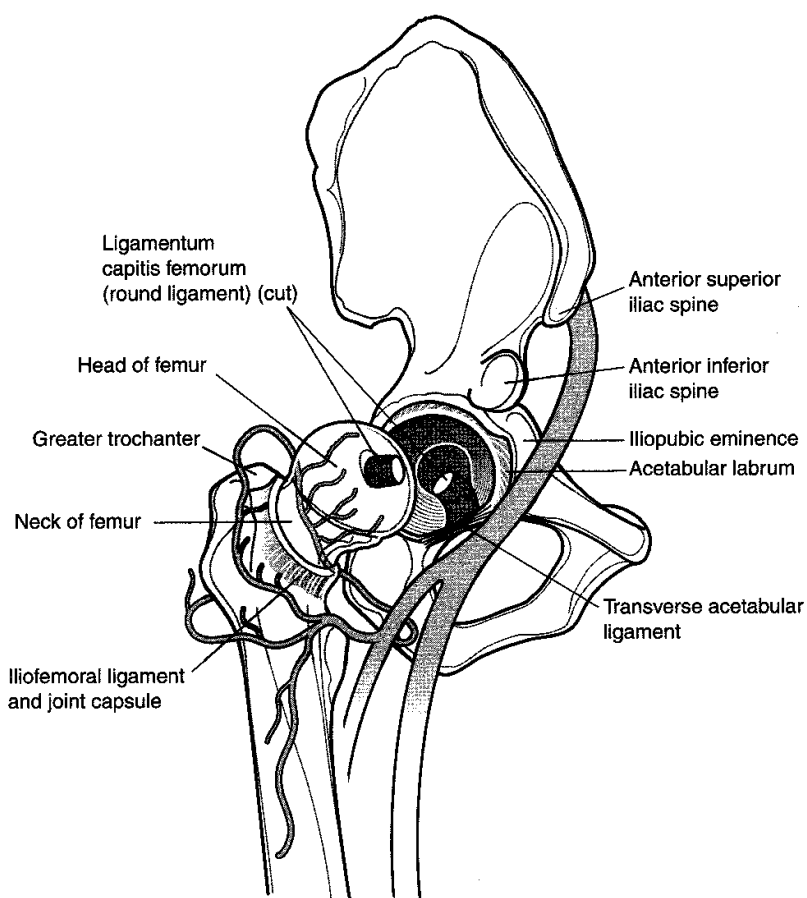


Figure III-5-4. Hip

FEMORAL TRIANGLE

The femoral triangle is bounded by the inguinal ligament and the sartorius and adductor longus muscles.

Within the triangle are the femoral sheath (containing the femoral artery and vein) and the femoral nerve (which is outside of the femoral sheath).

Passing under the inguinal ligament (from lateral to medial) are the: femoral nerve, femoral artery, femoral vein, an empy space within the femoral sheath called the femoral canal, and an inguinal lymph node within the femoral canal (NAVEL). The femoral canal is the site of femoral hernias.

POPLITEAL FOSSA

The popliteal fossa is a diamond-shaped region bounded by the **biceps femoris** superolaterally, the **semimembranosus** and **semitendinosus** superomedially, and the two heads of the **gastrocnemius** inferolaterally and inferomedially.

The floor of the fossa is formed by (from superior to inferior) the **popliteal surface of the femur**, the **knee joint capsule**, and the **popliteus muscle**.

Within the fossa (from posterior to anterior) are the **tibial nerve**, **popliteal vein**, and **popliteal artery**. Note that the artery is the deepest structure and closest to the femur. It may be endangered by a fracture of the supracondylar region of the femur.

The **common peroneal nerve** is in the lateral part of the fossa and lies against the tendon of the biceps femoris. As the tendon of the biceps femoris inserts on the head of the fibula, the common peroneal nerve wraps around the lateral surface of the fibular neck. In this location, the nerve may be damaged by trauma to the fibular head or neck.

KNEE JOINT

The knee joint is formed by the articulations of the medial and lateral femoral condyles, the medial and lateral tibial condyles (plateaus), and the patella.

Medially and laterally, the knee joint capsule is strengthened by the medial and lateral collateral ligaments. These ligaments resist abduction and adduction, respectively.

There are two major intracapsular ligaments: the anterior and posterior cruciate ligaments. These are named according to the site of inferior attachment of the ligament on the tibia, i.e., the anterior cruciate ligament attaches to the tibia anterior to the posterior cruciate ligament. These ligaments prevent anterior and posterior displacement of the tibia on the femur, respectively. The tests for the integrity of these ligaments are the anterior and posterior drawer signs (anterior drawer sign indicates damage to the anterior cruciate ligament).

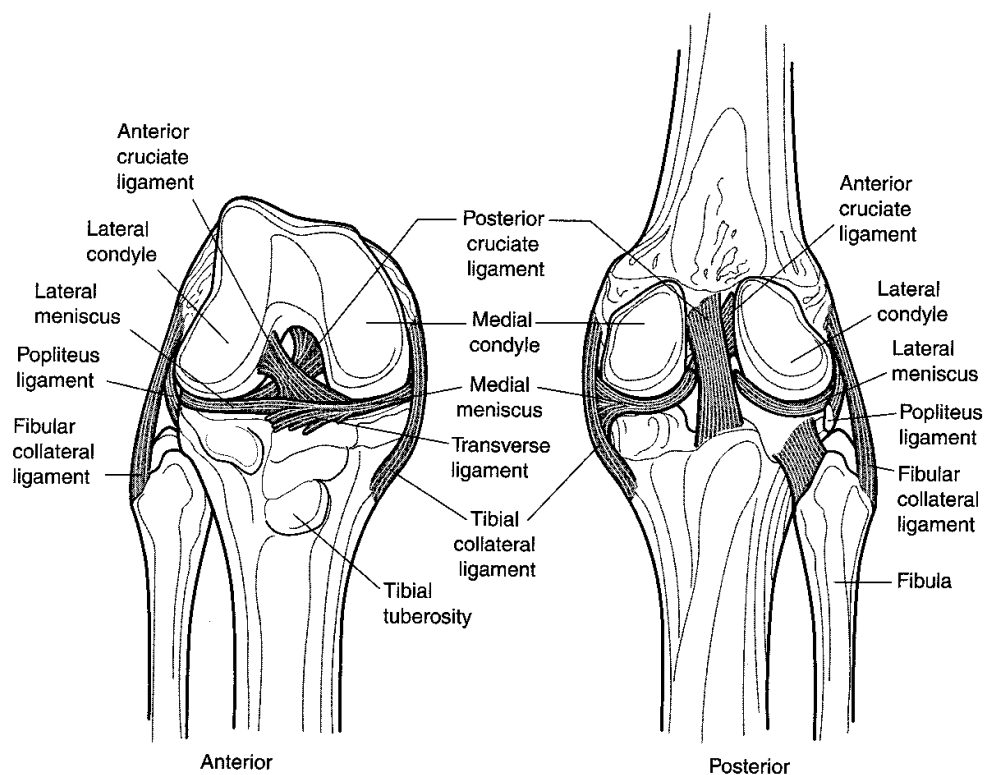


Figure III-5-5. Structures of the Knee

The medial and lateral menisci are wedge-shaped fibrous and fibrocartilaginous structures between the femoral condyles and the tibial plateaus. The medial meniscus is C-shaped, more firmly anchored to the tibia, and attached to the medial collateral ligament. The lateral meniscus is O-shaped, less firmly anchored to the tibia, and not attached to the lateral collateral ligament. Therefore, the medial meniscus is more commonly injured than the lateral meniscus. The "triad" knee injury is composed of tears of the medial collateral ligament, medial meniscus, and anterior cruciate ligament.

ANKLE JOINT

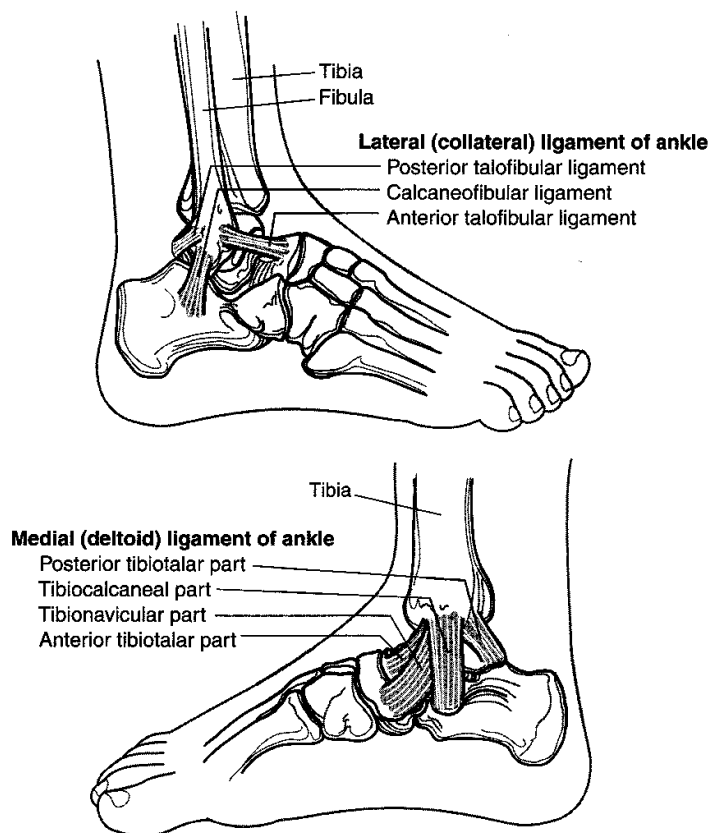


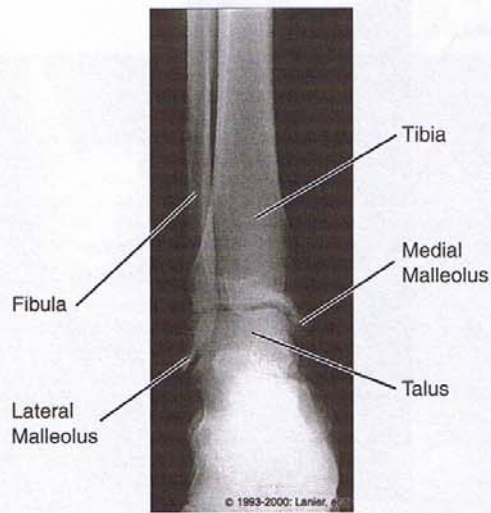
Figure III-5-6. Structures of the Ankle

There are three anklebone joints: the **talocrural joint**, the **subtalar joint**, and the **transverse tarsal joint**.

The **talocrural joint** is formed by the distal ends of the **tibia and fibula** and the **talus**. The movements at this joint are **dorsiflexion and plantar flexion**. The **medial collateral (deltoid) ligament** and the **lateral collateral ligament** prevent abduction and adduction, respectively. These are the ligaments commonly sprained in eversion and inversion ankle injuries, respectively. Ankle injuries occur mostly when the ankle is plantar flexed.

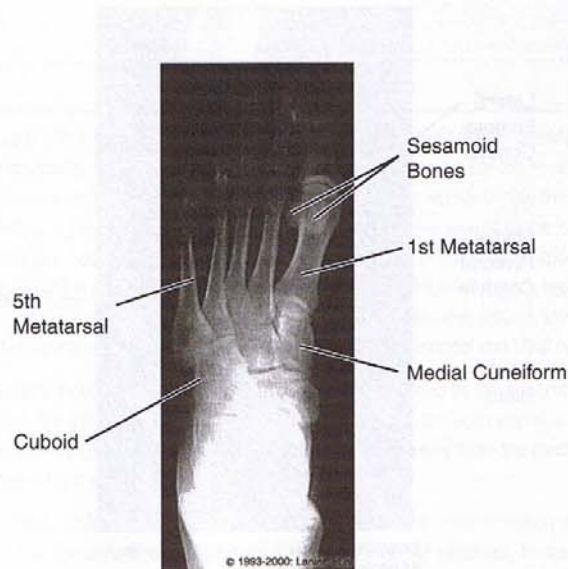
The **subtalar joint** is a compound joint formed by the **talocalcaneal joint** and the talocalcaneal part of the **talocalcaneonavicular joint**. Inversion and eversion are permitted at this joint.

The **transverse tarsal joint** is a compound joint formed by the **talocalcaneonavicular joint** and the **calcaneocuboid joint**. Inversion and eversion are also permitted at this joint.



Copyright 2000 Gold Standard Multimedia, Inc.
All rights reserved.

Figure III-5-7. Lower Extremities: Anteroposterior View of Ankle



Copyright 2000 Gold Standard Multimedia, Inc.
All rights reserved.

Figure III-5-8. Lower Extremities: Anteroposterior View of Foot

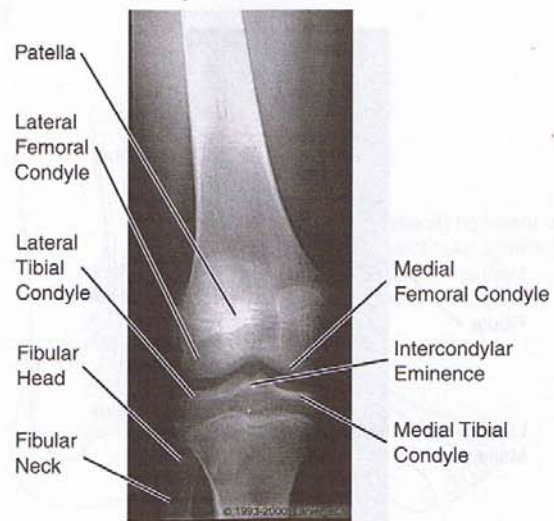


Figure III-5-9. Lower Extremities: Anteroposterior View of Knee

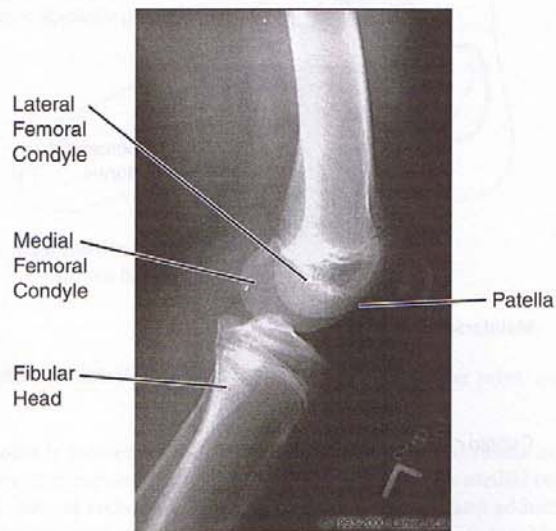


Figure III-5-10. Lower Extremities: Lateral Knee

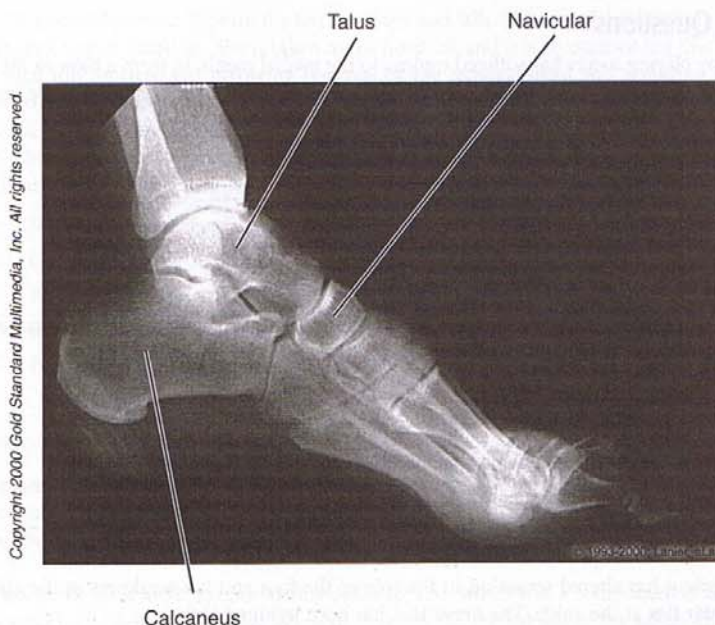


Figure III-5-11. Lower Extremities: Lateral Foot

Chapter Summary

The lumbosacral plexus is formed by the ventral rami of spinal nerves L1–S4, which provide the major motor and sensory innervation for the lower limb. The primary named nerves are the femoral, obturator, tibial, and common peroneal (superior and deep) nerves. The nerves supply the major muscular compartments of the lower limb (Table III-5-1). The major nerve lesions of the lower limb include Trendelenburg gait (superficial gluteal nerve), difficulty standing or climbing (inferior gluteal nerve), loss of knee extension (femoral nerve), loss of hip adduction (obturator nerve), loss of knee flexion and plantar flexion (tibial nerve), foot drop (common or deep peroneal nerves), loss of eversion (common or superficial peroneal nerves), and loss of inversion (deep peroneal and tibial nerves).

The sensory supply from most of the dorsal surface of the foot is provided by the superficial peroneal nerve, except between the great and second toes, which is supplied by the deep peroneal nerve. On the sole of the foot, sensory supply is provided by the medial plantar nerve from the medial toes and the lateral plantar nerve from the lateral toes.

Blood supply to the lower limb is mostly derived from the femoral artery, a continuation of the external iliac artery. The named arterial branches to the limb include the obturator, femoral, popliteal, anterior and posterior tibial arteries, and the plantar arterial arch. Their branches and distributions are given on Figure III-5-3.

The articulation of the knee joint is formed by the condyles of the femur and tibia. This joint is strengthened by the medial and lateral collateral ligaments, the anterior and posterior cruciate ligaments, and the medial and lateral menisci.

Review Questions

1. A boy playing soccer has suffered trauma to the medial meniscus from a blow to the lateral aspect of the knee. The knee is unstable. What other structure is most likely to be injured?
 - (A) Deltoid ligament
 - (B) Lateral meniscus
 - (C) Anterior cruciate ligament
 - (D) Patellar ligament
 - (E) Fibular collateral ligament
2. A woman wearing high heels has fallen and twisted her ankle. Part of which ligament was most likely stretched?
 - (A) Deltoid ligament
 - (B) Medial ligament
 - (C) Plantar calcaneonavicular ligament
 - (D) Lateral ligament
 - (E) Long plantar ligament
3. A patient has altered sensation in the sole of the foot and has weakness in the ability to plantar flex at the ankle. The nerve that has been lesioned is the
 - (A) common peroneal
 - (B) sural
 - (C) saphenous
 - (D) femoral
 - (E) tibial
4. An active mountain climber develops pain in the buttock and tingling and numbness in the lower limb as a result of hypertrophy of the piriformis muscle. Which region of the lower limb is most likely to be a site of the altered sensation?
 - (A) Posterior thigh
 - (B) Lateral leg
 - (C) Medial thigh
 - (D) Sole of the foot
 - (E) Gluteal region
5. A football player has suffered severe trauma to the lateral part of the left leg just below the knee. He drags his left toe when he walks and cannot feel the dorsum of the foot. Which of the following will still be intact?
 - (A) Dorsiflexion
 - (B) Inversion
 - (C) Eversion
 - (D) Cutaneous sensation of the medial leg
 - (E) Cutaneous sensation between the great toe and the second toe

6. A 75-year-old woman slips on the kitchen floor and falls. She complains of pain in her left hip and cannot stand up. She is taken to the hospital, and it is recommended that she have a total hip replacement involving removal of the femoral head and replacing it with a prosthesis. The surgeon indicates that this procedure is necessary because of interruption of the predominant blood supply to the head of the femur. Which blood vessel gives rise to a branch that is the major source of arterial blood supply to the head and neck of the femur?
- (A) Superior gluteal artery
 - (B) Obturator artery
 - (C) Profunda femoral artery
 - (D) Inferior gluteal artery
 - (E) Femoral artery

Answers and Explanations

1. **Answer: C.** Blows to the lateral aspect of the knee typically injure one or more of the components of the "terrible triad." The triad includes the medial collateral ligament, the medial meniscus, and the anterior cruciate ligament.
2. **Answer: D.** Most ankle sprains are inversion sprains, which tear a component of the lateral ligament. The deltoid or medial ligament supports the medial side of the ankle. The plantar calcaneonavicular ligament helps maintain the medial longitudinal arch of the foot; the long plantar ligament helps maintain the lateral longitudinal arch of the foot.
3. **Answer: E.** The tibial nerve provides cutaneous sensation in the sole of the foot and innervates most of the muscles (including the gastrocnemius and soleus) that plantar flex the foot at the ankle.
4. **Answer: B.** Active athletes who use their gluteal muscles extensively may present with hypertrophy of the piriformis muscle. In some individuals, the common peroneal component of the sciatic nerve courses through this muscle rather than emerging inferior to it. The hypertrophy compresses the nerve, leading to the altered sensation in the area of distribution of the superficial peroneal nerve.
5. **Answer: D.** Cutaneous sensation of the medial leg is provided by the saphenous nerve, a branch of the femoral nerve that would be unaffected by this lesion, which has lacerated the common peroneal nerve.
6. **Answer: C.** The medial circumflex artery provides most of the blood supply to the head and neck of the femur and is typically a direct branch of the profunda femoral artery.

Head and Neck

6

NECK

General Features

The neck can be divided into two compartments: an anterior or visceral part containing the hyoid bone, pharynx, esophagus, larynx, and associated cartilages, and a posterior or vertebral compartment consisting mostly of muscles associated with cervical vertebrae and the ventral rami of the cervical plexus and brachial plexus. Both compartments are partially covered by two superficial muscles, the trapezius and the sternocleidomastoid, which serve to divide each side of the neck into anterior and posterior triangles (Figure III-6-1).

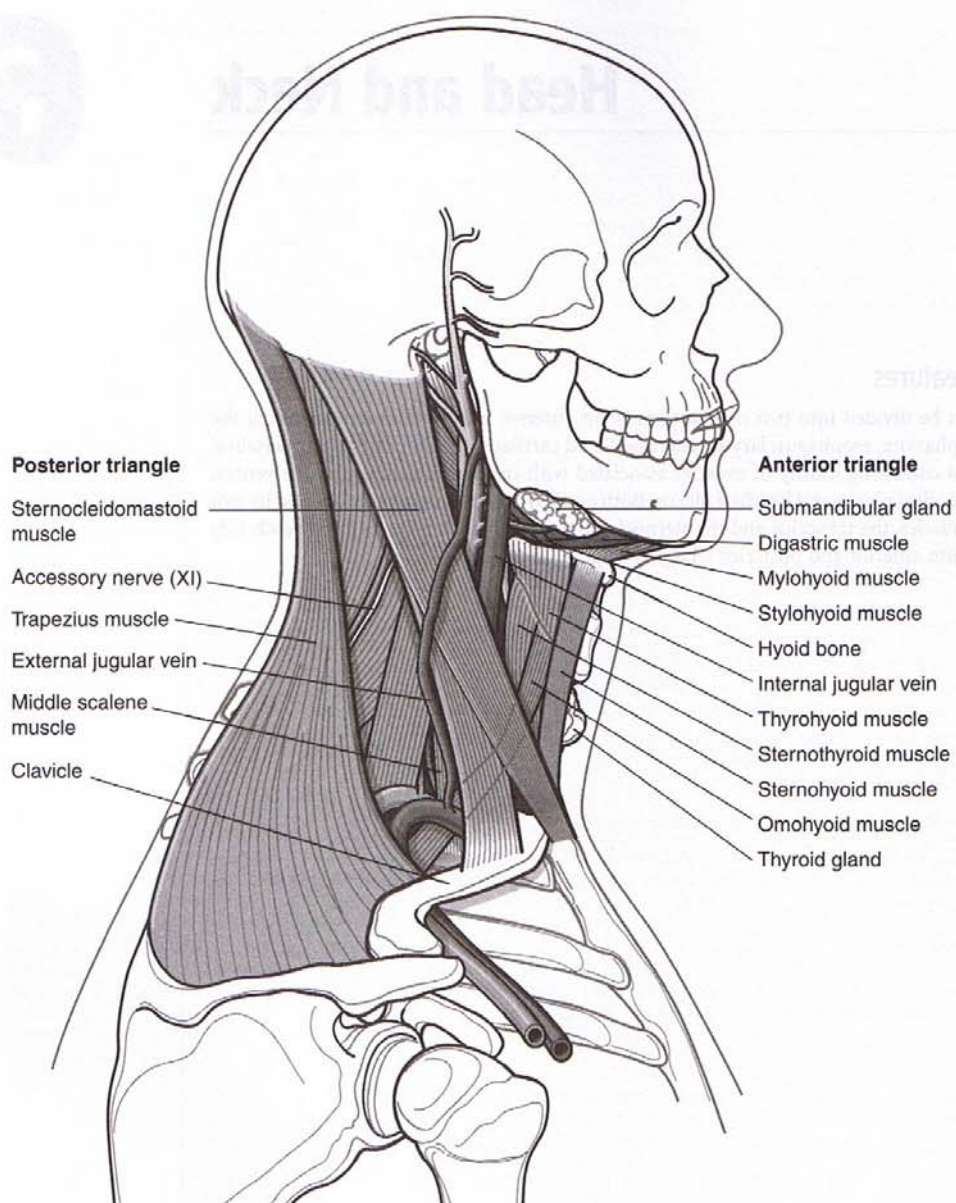


Figure III-6-1. Triangles of the Neck

Posterior Triangle

The posterior triangle is bounded by the trapezius muscle, the sternocleidomastoid muscle, and the clavicle.

In the floor of the triangle are the anterior scalene, middle scalene, posterior scalene, levator scapulae, and splenius capitis muscles.

The three trunks of the brachial plexus and the subclavian artery pass through the narrow scalene interval in the floor of the posterior triangle, which lies between the anterior and middle scalene muscles, then under the clavicle, before they enter the axilla (Figure III-6-2).

The accessory nerve (cranial nerve XI) innervates the sternocleidomastoid muscle, then crosses the middle of the posterior triangle to pass under the trapezius muscle, which it also innervates.

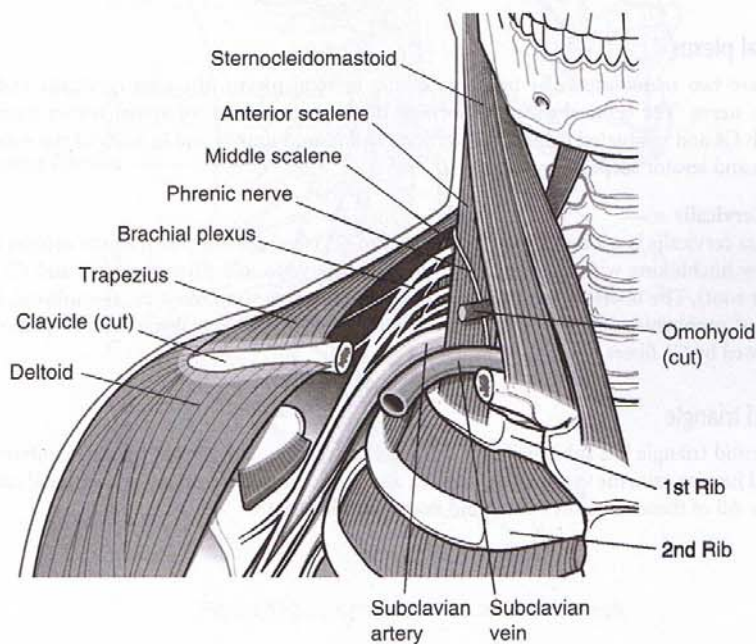


Figure III-6-2. Posterior Triangle of the Neck

Also in the posterior triangle are the phrenic nerve (formed from the ventral rami of cervical spinal segments C3, C4, and C5), which lies on the anterior surface of the anterior scalene muscle.

In the posterior triangle cutaneous branches of the cervical plexus (great auricular, lesser occipital, transverse cervical, and supraclavicular nerves) emerge at the midpoint of the sternocleidomastoid muscle. These nerves supply the skin of the neck and posterior scalp.

Clinical Correlate

Accessory Nerve in the Posterior Triangle

Lesions of the accessory nerve in the posterior triangle result in paralysis and wasting of the trapezius and weakness in elevating the shoulder. If the nerve is injured as it leaves the skull through the jugular foramen, the sternocleidomastoid will also be affected, resulting in a weakness in the ability to turn the head to the opposite side.

In the superior part of the scalene interval, the upper trunk of the brachial plexus may be compressed, causing weakness of shoulder and arm muscles. In the inferior part of the interval, the lower trunk of the plexus may be compressed by a cervical rib or an apical lung (Pancoast) tumor, causing sensory deficits and weakness of muscles in the hand.

Anterior Triangle

The anterior triangle is bounded by the anterior border of the sternocleidomastoid muscle, the anterior midline, and the body of the mandible (Figure III-6-1). Subdivisions of the anterior triangle contain the strap muscles, the submandibular gland, the common carotid, internal carotid and external carotid arteries, and parts of cranial nerves X and XII. The strap muscles consist of a series of five pairs of muscles which have attachments to bony or cartilaginous structures adjacent to the midline beginning at the sternum and extending to the underside of the mandible. Strap muscles act on the mandible, hyoid bone, and thyroid cartilage.

Cervical plexus

There are two major muscular branches of the cervical plexus, the ansa cervicalis and the phrenic nerve. The cervical plexus is formed by the ventral rami of spinal nerves from C1 through C4 and is situated behind the sternocleidomastoid muscle and in front of the scalenus medius and levator scapulae muscles.

Ansa Cervicalis

The ansa cervicalis is a loop formed by fibers from C1 (the superior root), which courses inferiorly by hitchhiking with fibers of the hypoglossal nerve to join fibers from C2 and C3 (the inferior root). The fibers of the ansa are distributed to three strap muscles (sternohyoid, both bellies of omohyoid, and sternothyroid). The thyrohyoid and geniohyoid are strap muscles innervated by C1 fibers.

Clinical Correlate

The most significant artery of the external carotid system is the middle meningeal artery. It arises from the maxillary artery in the infratemporal fossa and enters the skull through the foramen spinosum to supply skull and dura. Lacerations of this vessel result in an epidural hematoma.

Carotid triangle

The carotid triangle is a subdivision of the anterior triangle. The carotid triangle contains the internal jugular vein, the vagus nerve (CN X), and the common or internal and external carotid arteries. All of these structures are found in the carotid sheath.

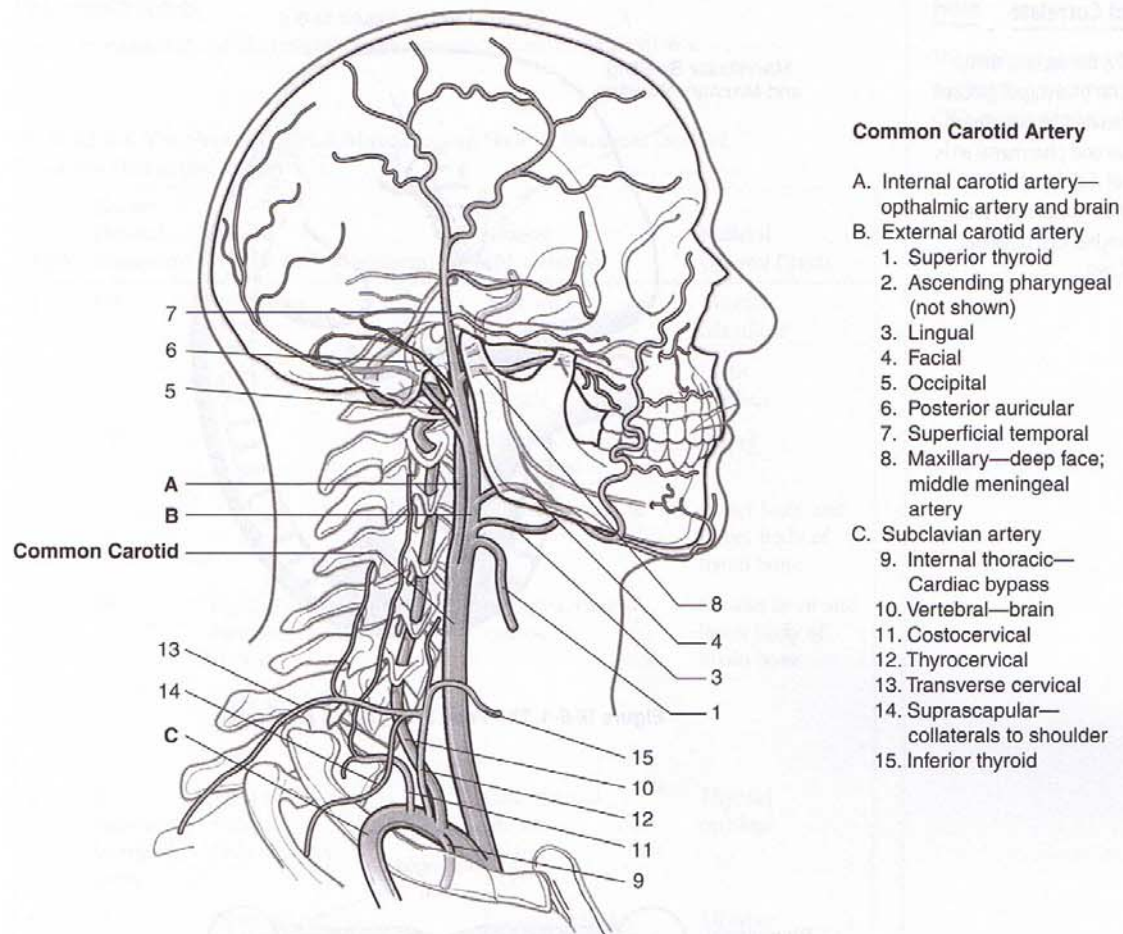


Figure III-6-3. Arteries to the Head and Neck

HEAD

Embryology of Pharynx, Tongue, and Palate

Pharyngeal apparatus

The pharyngeal apparatus consists of pharyngeal arches (1, 2, 3, 4, and 6), pouches (1, 2, 3, and 4), and grooves (1, 2, 3, and 4). The anatomic associations relating to these structures, in the fetus and adult, are summarized in Figures III-6-4 and III-6-5.

Table III-6-1 summarizes the relationships among the nerves, arteries, muscles, and skeletal elements derived from the pharyngeal arches, and Table III-6-2 shows which adult structures are derived from the various pouches.

Clinical Correlate

Normally, the second, third, and fourth pharyngeal grooves are obliterated by overgrowth of the second pharyngeal arch. Failure of a cleft to be completely obliterated results in a branchial cyst or lateral cervical cyst.

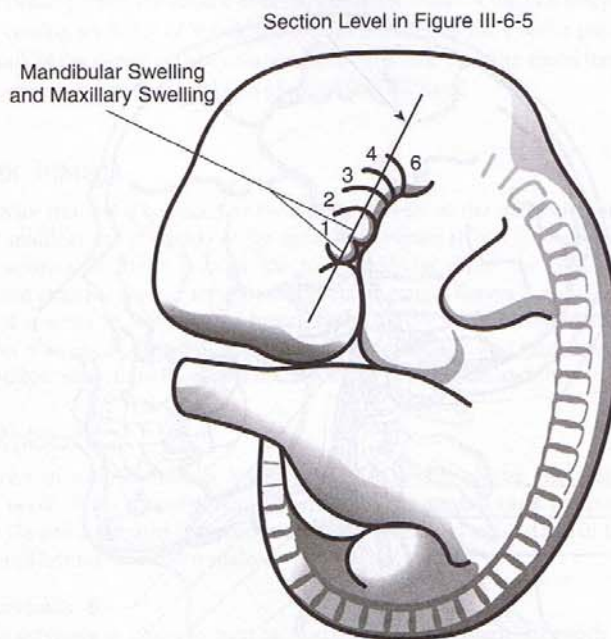


Figure III-6-4. The Fetal Pharyngeal Apparatus

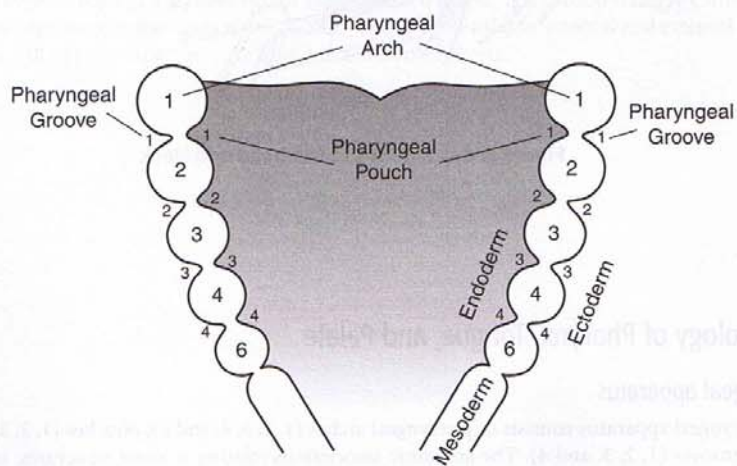


Figure III-6-5. Section Through the Developing Pharynx

Pharyngeal arches

The components of the pharyngeal arches are summarized in Table III-6-1.

Table III-6-1. The Neural, Arterial, Muscular, and Skeletal Elements Derived From the Pharyngeal Arches

Arch	Nerve* (Neural Ectoderm)	Artery (Aortic Arch Mesoderm)	Muscle (Mesoderm)	Skeletal (Neural Crest)
1	V3		Muscles of mastication	Maxilla Mandible
			Tensor tympani muscle	Incus Malleus
2	VII		Muscles of facial expression	Stapes
			Stapedius muscle	Lesser horn and upper body of hyoid bone
3	IX	Right and left common carotid arteries	Stylopharyngeus muscle	Greater horn and lower body of hyoid bone
		Right and left internal carotid arteries		
4	X Superior laryngeal nerve	Right subclavian artery Arch of aorta	Cricothyroid muscle Palate Pharynx	Thyroid cartilage
6	X Recurrent laryngeal nerve	Right and left pulmonary arteries	Intrinsic muscles of larynx (except cricothyroid muscle)	All other laryngeal cartilages
		Ductus arteriosus		

*Note: Nerve is not derived from pharyngeal arch. It grows into the arch.

The ocular muscles (III, IV, VI) and the tongue muscles (XII) do not derive from pharyngeal arch mesoderm but from mesoderm of the occipital somites.

Note

The origins of pharyngeal and palatine muscles innervated by CN X is controversial.

Pharyngeal pouches

The anatomic structures relating to the pharyngeal pouches are summarized in Figure III-6-6.

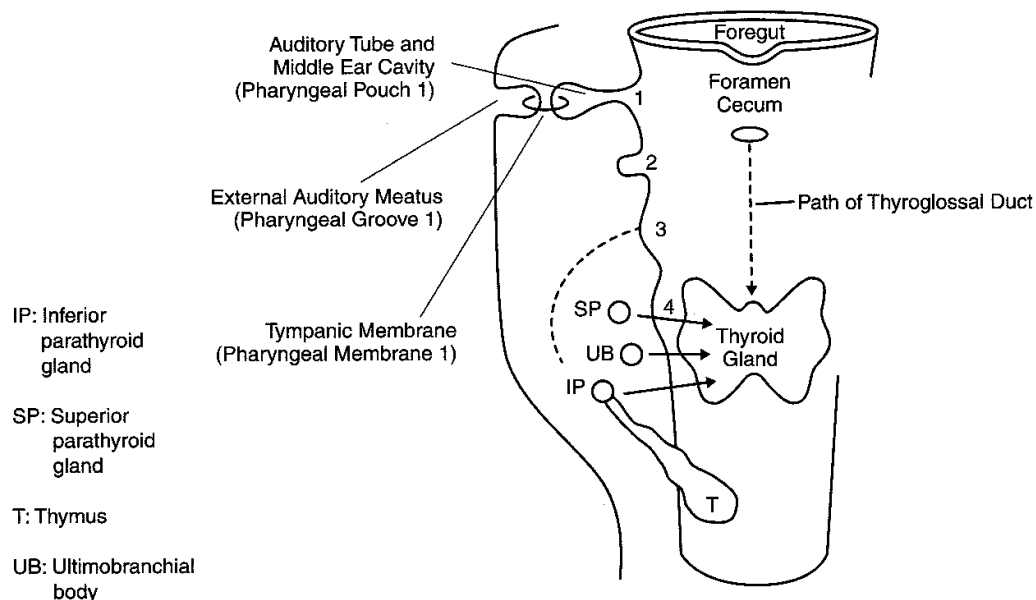


Figure III-6-6. Fetal Pharyngeal Pouches

Clinical Correlate

The DiGeorge sequence presents with immunologic problems, hypocalcemia, and may be combined with cardiovascular defects (persistent truncus arteriosus), abnormal ears, and micrognathia.

The adult structures derived from the fetal pharyngeal pouches are summarized in Table III-6-2.

Table III-6-2. Adult Structures Derived From the Fetal Pharyngeal Pouches

Pouch	Adult Derivatives
1	Epithelial lining of auditory tube and middle ear cavity
2	Epithelial lining of crypts of palatine tonsil
3	Inferior parathyroid gland (IP)
	Thymus (T)
4	Superior parathyroid gland (SP)
	Ultimobranchial body (UB)

Neural crest cells migrate into the ultimobranchial body to form parafollicular (C) cells of the thyroid.

Pharyngeal grooves

Pharyngeal groove 1 gives rise to the epithelial lining of **external auditory meatus**.

All other grooves are obliterated.

Thyroid Gland

The thyroid gland develops from the **thyroid diverticulum**, which forms in the midline, in the floor of the foregut. The thyroid diverticulum migrates caudally to its adult anatomic position but remains connected to the foregut via the **thyroglossal duct**, which is later obliterated. The former site of the thyroglossal duct is indicated in the adult by the **foramen cecum**.

Tongue and Palate

The **anterior two thirds of the tongue** is associated with **pharyngeal arch 1**. General sensation is carried by the lingual branch of CN V. Taste sensation is carried by **chorda tympani of CN VII** (Figure III-6-7).

The **posterior one third of the tongue** is associated with **pharyngeal arch 3**. General sensation and taste are carried by CN IX.

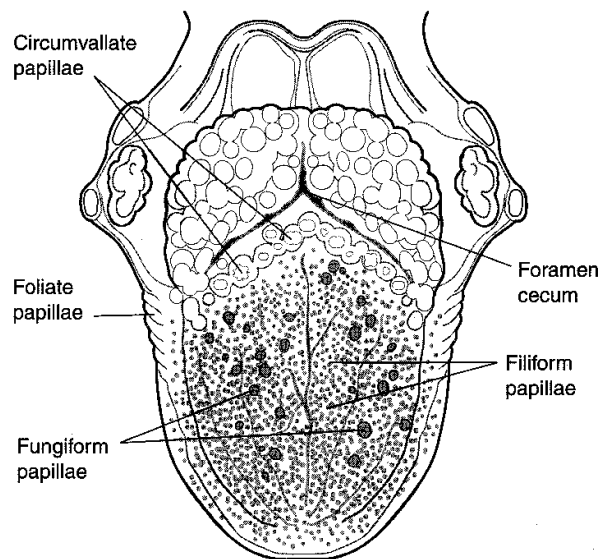


Figure III-6-7. Tongue

Intrinsic and extrinsic muscles of the tongue are derived from myoblasts that migrate into the tongue region from **occipital somites**. Motor innervation is supplied by CN XII (Figure III-6-8).

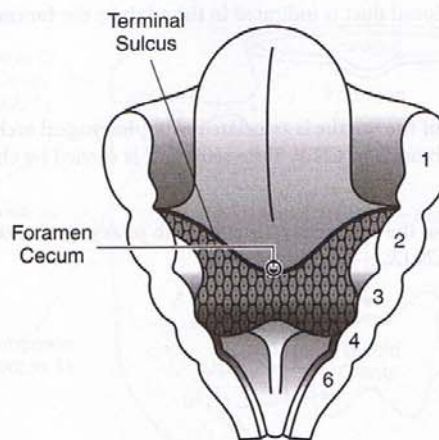


Figure III-6-8. The Tongue

Clinical Correlate

Cleft lip occurs when the maxillary prominence fails to fuse with the medial nasal prominence.

Cleft palate occurs when the palatine shelves fail to fuse with each other or the primary palate.

Development of the Face and Palate

The face develops from the frontonasal prominence, a pair of maxillary prominences, and a pair of mandibular prominences.

Intermaxillary segment and primary palate

The intermaxillary segment forms when the two medial nasal prominences fuse together at the midline and gives rise to the **philtrum of the lip**, **four incisor teeth**, and **primary palate** of the adult (Figure III-6-9). The primary palate forms anterior to the incisive foramen.

Secondary palate

The secondary palate forms from outgrowths of the maxillary prominences called **palatine shelves**, which fuse in the midline, posterior to the incisive foramen.

The primary and secondary palate fuse at the **incisive foramen** to form the definitive palate.

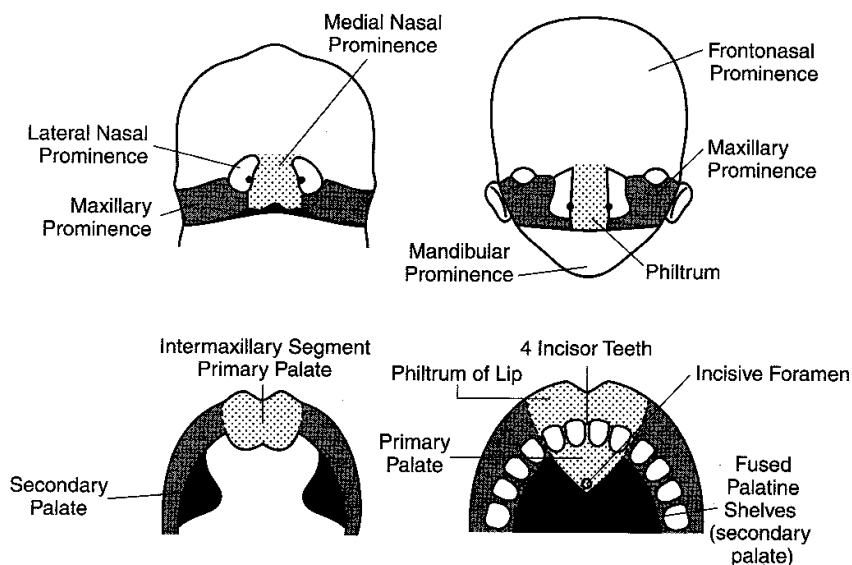


Figure III-6-9. Palate and Face Development

Clinical Considerations

First arch syndrome results from abnormal formation of pharyngeal arch 1 because of faulty migration of neural crest cells, causing facial anomalies. Two well-described syndromes are Treacher Collins syndrome and Pierre Robin sequence. Both defects involve neural crest cells.

Pharyngeal fistula occurs when pouch 2 and groove 2 persist, thereby forming a fistula generally found along the anterior border of the sternocleidomastoid muscle.

Pharyngeal cyst occurs when pharyngeal grooves that are normally obliterated persist, forming a cyst usually located at the angle of the mandible.

Ectopic thyroid, parathyroid, or thymus results from abnormal migration of these glands from their embryonic position to their adult anatomic position. Ectopic thyroid tissue is found along the midline of the neck. Ectopic parathyroid or thymus tissue is generally found along the lateral aspect of the neck. May be an important issue during neck surgery.

Thyroglossal duct cyst or fistula occurs when parts of the thyroglossal duct persist, generally in the midline near the hyoid bone. The cyst may also be found at the base of the tongue (lingual cyst).

DiGeorge sequence occurs when pharyngeal pouches 3 and 4 fail to differentiate into the parathyroid glands and thymus. Neural crest cells are involved.

Clinical Correlate

Robin sequence presents with a triad of poor mandibular growth, cleft palate, and a posteriorly placed tongue.

Treacher Collins syndrome also presents with mandibular hypoplasia, zygomatic hypoplasia, down-slanted palpebral fissures, colobomas, and malformed ears.

CRANIUM

Clinical Correlate

Cribriform plate fractures may result in dysosmia and rhinorrhea (CSF).

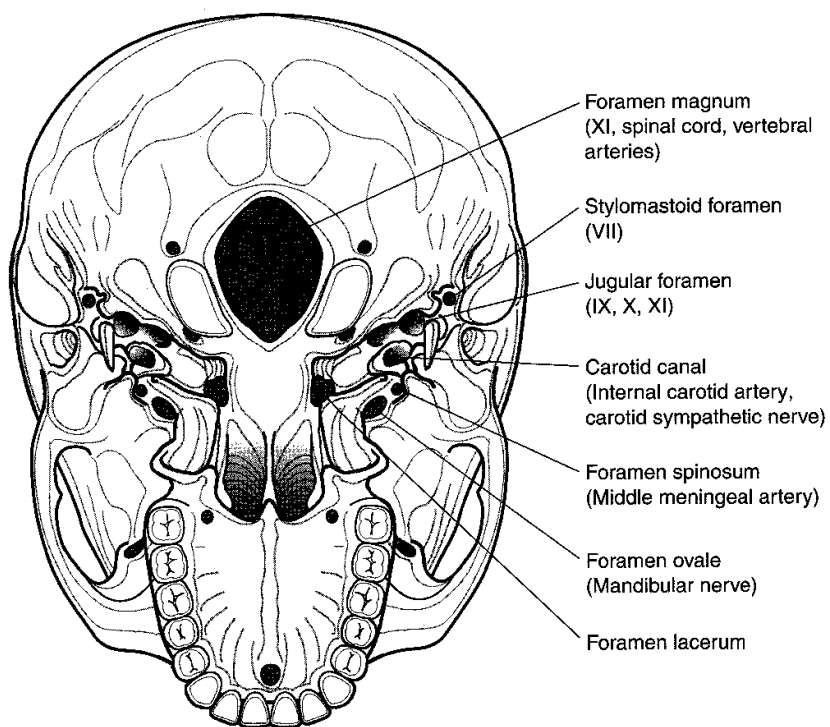


Figure III-6-10. Foramina: Base of Skull

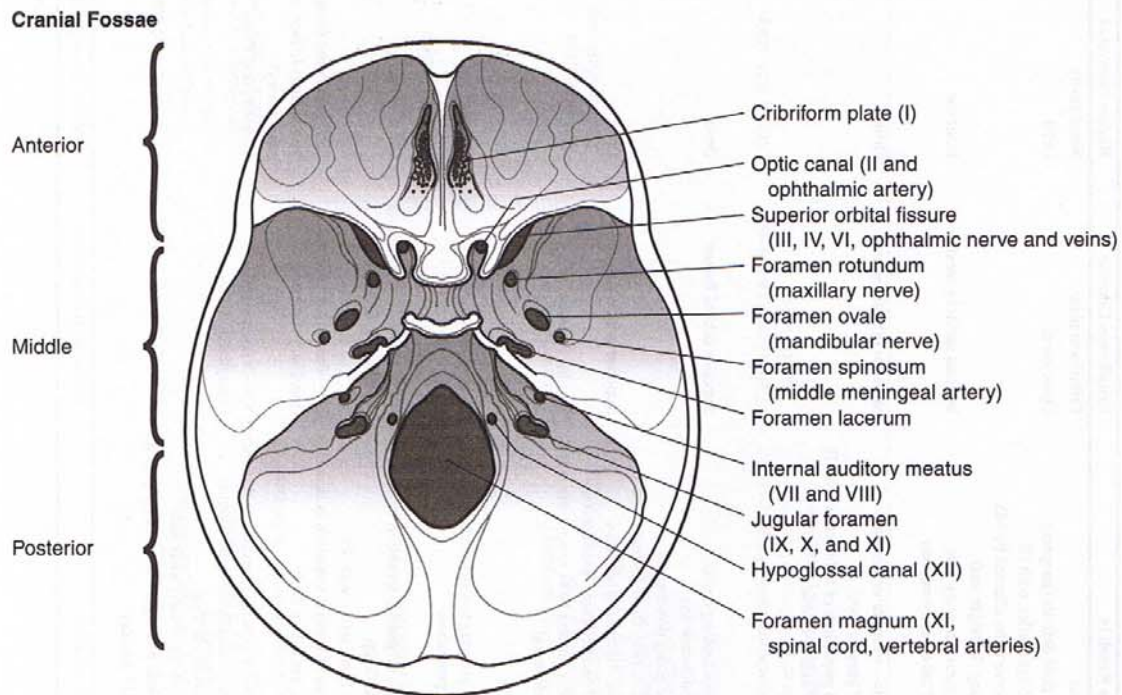


Figure III-6-11. Foramina: Cranial Fossae

Clinical Correlate

Jugular foramen syndrome may be caused by a tumor pressing on CN IX, X, and XI. Patients present with hoarseness, dysphagia (CN IX and X), loss of sensation over the oropharynx and posterior one third of the tongue (CN IX), trapezius and sternocleidomastoid weakness (CN XI). The nearby CN XII may be involved producing tongue deviation to the lesioned side.

Table III-6-3. Cranial Nerves: Functional Features

CN	Name	Type	Function	Lesions Result in	Exits/Enters Cranium	Region Innervated
I	Olfactory	Sensory	Smells	Anosmia	Cribriform plate	Nasal cavity
II	Optic	Sensory	Sees (optic nerve is really a tract of CNS with meninges)	Visual field deficits (anopsia) Loss of light reflex with III Only nerve to be affected by MS (swinging flashlight test)	Optic canal	Orbit
VIII	Vestibulocochlear	Sensory	Hears Linear acceleration (gravity) Angular acceleration (head turning)	Sensorineural hearing loss Loss of balance, nystagmus	Internal auditory meatus	Inner ear
III	Oculomotor	Motor	Moves eyeball in all directions Adduction (medial rectus) most important action Constricts pupil (sphincter pupillae) Accommodates (ciliary muscle) Raises eyelid (levator palpebrae superioris)	Diplopia—external strabismus Loss of parallel gaze Dilated pupil, loss of light reflex with II Loss of near response Ptosis	Superior orbital fissure	Orbit
IV	Trochlear	Motor	Superior oblique—depresses and abducts eyeball (makes eyeball look down and out) Intorts	Weakness locking down with adducted eye Trouble going down stairs Head tilts away from lesioned side	Superior orbital fissure	Orbit
VI	Abducens	Motor	Lateral rectus—abducts eyeball	Diplopia—internal strabismus Loss of parallel gaze, "pseudoptosis"	Superior orbital fissure	Orbit
XI	Accessory	Motor	Turns head to opposite side (sternocleidomastoid) Elevates and rotates scapula (trapezius)	Weakness turning head to opposite side Shoulder droop	Jugular foramen	Neck
XII	Hypoglossal	Motor	Moves tongue (styloglossus, hyoglossus, genioglossus, and intrinsic—palatoglossus is by X)	Tongue pointing toward same (affected) side on protrusion	Hypoglossal canal	Tongue
V	Trigeminal Ophthalmic (V1)	Mixed	General sensation (touch, pain, temperature) of forehead/scalp/cornea	V1—loss of general sensation in skin of forehead/scalp Loss of blink reflex with VII	V1—superior orbital fissure (ophthalmic division)	Orbit and scalp
	Maxillary (V2)		General sensation of palate, nasal cavity, maxillary face, maxillary teeth	V2—loss of general sensation in skin over maxilla, maxillary teeth	V2—foramen rotundum (maxillary division)	Pterygopalatine fossa (leave by openings to face, oral and nasal cavity)
	Mandibular (V3)		General sensation of anterior two thirds of tongue, mandibular face, mandibular teeth Motor to muscles of mastication (temporalis, masseter, medial and lateral pterygoids) and anterior belly of digastric, mylohyoid, tensor tympani, tensor palati	V3—loss of general sensation in skin over mandible, mandibular teeth, tongue, weakness in chewing Jaw deviation toward weak side Trigeminal neuralgia—intractable pain in V2 or V3 territory	V3—foramen ovale (mandibular division)	Infratemporal Fossa

(Continued)

Table III-6-3. Cranial Nerves: Functional Features (*continued*)

CN Name	Type	Function	Lesions Result in	Exits/Enters Cranium	Region Innervated
VII Facial	Mixed	To muscles of facial expression, posterior belly of digastric, stylohyoid, stapedius Tastes anterior two thirds of tongue/palate Salivates (submandibular, sublingual glands) Tears (lacrimal gland) Makes mucus (nasal and palatine glands) Senses pharynx, carotid sinus/body Salivates (parotid gland) Tastes and senses posterior one third of tongue Motor to one muscle—stylopharyngeus	Corner of mouth droops, can't close eye, can't wrinkle forehead, loss of blink reflex, hyperacusis Alteration or loss of taste (ageusia) Eye dry and red Bell palsy—lesion of nerve in facial canal	Internal auditory meatus	Face, nasal, and oral cavity (branches leave skull in stylomastoid foramen, petrotympanic fissure, or hiatus of facial canal)
IX Glossopharyngeal	Mixed	Senses pharynx, carotid sinus/body Salivates (parotid gland) Tastes and senses posterior one third of tongue Motor to one muscle—stylopharyngeus	Loss of gag reflex with X	Jugular foramen	Neck Pharynx/tongue
X Vagus	Mixed	To muscles of palate and pharynx for swallowing except tensor palati (V) and stylopharyngeus (IX) To all muscles of larynx (phonates) Senses larynx and laryngopharynx Senses larynx and GI tract To GI tract smooth muscle and glands in foregut and midgut	Nasal speech, nasal regurgitation Dysphagia, palate droop Uvula pointing away from affected side Hoarseness/fixed vocal cord Loss of gag reflex with IX Loss of cough reflex	Jugular foramen	Neck Pharynx/larynx Thorax, abdomen
Sympathetics to head	Motor	Raises eyelid (superior tarsal muscle) Dilates pupil Innervates sweat glands of face and scalp Constricts blood vessels in head	Horner syndrome: eyelid droop (ptosis), constricted pupil (miosis), loss of sweating (anhidrosis), flushed face	Carotid canal on internal carotid artery	Orbit, face, scalp

Venous Drainage of the Brain and the Dural Venous Sinuses

Dural venous sinuses

The dural venous sinuses receive cerebral veins from the brain and drain the venous blood mainly into the internal jugular vein (Figures III-6-12 and III-6-13). The **superior sagittal sinus** is located in the midsagittal plane along the superior aspect of the falx cerebri. It drains into the confluence of the sinuses. Arachnoid granulations protrude through the walls of the superior sagittal sinus. The arachnoid granulations transmit CSF from the subarachnoid space into the venous circulation. The superior sagittal sinus drains into the confluents of the sinuses.

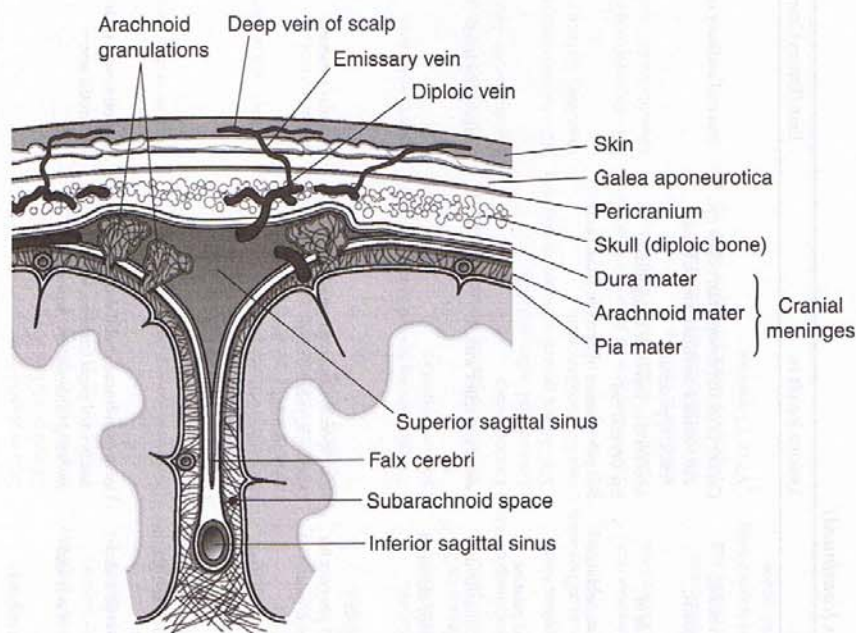


Figure III-6-12. Coronal Section of the Dural Sinuses

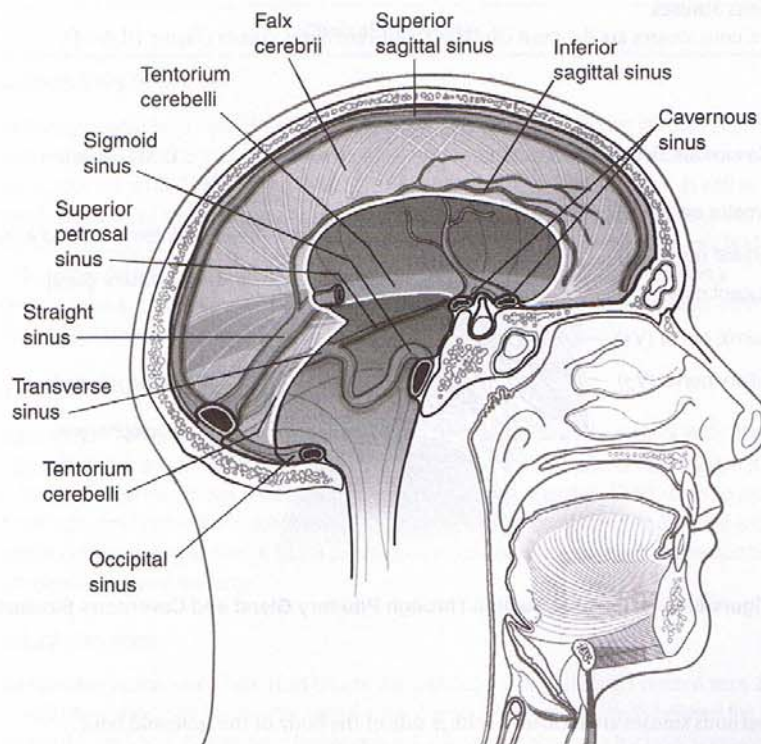


Figure III-6-13. Dural Venous Sinuses

The **inferior sagittal sinus** is located in the midsagittal plane, near the inferior margin of the falx cerebri. It terminates by joining with the great cerebral vein to form the straight sinus at the junction of the falx cerebri and tentorium cerebelli.

The **straight sinus** is formed by the union of the inferior sagittal sinus and the great cerebral vein. It usually terminates by draining into the confluens of sinuses (or into the transverse sinus).

The **occipital sinus** is found in the attached border of the tentorium cerebelli. It drains into the confluens of sinuses.

The **confluens of sinuses** is formed by the union of the superior sagittal, straight, and occipital sinuses. It drains into the two transverse sinuses.

The **transverse sinuses** drain venous blood from the confluens of sinuses into the sigmoid sinuses. Each sigmoid sinus joins with an inferior petrosal sinus to drain into the internal jugular vein below the jugular foramen.

Cavernous Sinuses

The cavernous sinuses are the most clinically significant dural sinuses (Figure III-6-14).

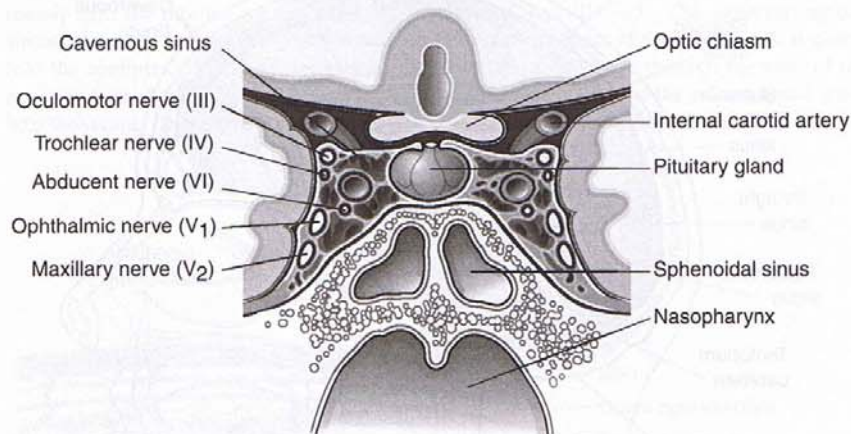


Figure III-6-14. Coronal Section Through Pituitary Gland and Cavernous Sinuses

The cavernous sinuses are located on either side of the body of the sphenoid bone.

Each sinus receives blood from some of the cerebral veins, ophthalmic veins, and the sphenoparietal sinus.

Each cavernous sinus drains into a transverse sinus via the superior petrosal sinus, into the internal jugular vein via the inferior petrosal sinus, and by emissary veins through the foramen ovale into the pterygoid venous plexus.

Clinical Correlate**Cavernous Sinus Thrombosis**

Infection can spread from veins of the face into the cavernous sinuses, producing infection and thrombosis. Such infection may involve the cranial nerves, which course through the cavernous sinus. Cranial nerves III, IV, and VI and the ophthalmic and maxillary divisions of CN V, as well as the internal carotid artery and its periarterial plexus of postganglionic sympathetic fibers traverse the cavernous sinus. All of these cranial nerves course in the lateral wall of the sinus except for CN VI, which courses through the middle of the sinus. As a result, CN VI is typically affected first in a cavernous sinus thrombosis or by an aneurysm of the internal carotid artery, with the other nerves being affected later.

Subarachnoid Hemorrhage

A subarachnoid hemorrhage results from a rupture of a berry aneurysm in the circle of Willis. The most common site is in the anterior part of the circle of Willis. A common site for an aneurysm is at the branch point of the anterior cerebral and anterior communicating arteries. Other common sites are in the proximal part of the middle cerebral artery, or at the junction of the internal carotid and posterior communicating arteries. A typical presentation associated with a subarachnoid hemorrhage is the onset of a severe headache.

Subdural Hematoma

A subdural hematoma results from head trauma that tears superficial ("bridging") cerebral veins at the point where they enter the superior sagittal sinus. A venous hemorrhage results between the dura and the arachnoid. If acute, large hematomas result in signs of elevated intracranial pressure such as headache and nausea. Small or chronic hematomas are often seen in elderly or chronic alcoholic patients. Over time, herniation of the temporal lobe, coma, and death may result if the venous blood is not evacuated.

Epidural Hematoma

An epidural hematoma results from trauma to the lateral aspect of the skull, which lacerates the middle meningeal artery. Arterial hemorrhage rapidly occurs in the space between the dura and the skull. The head trauma is associated with a momentary loss of consciousness followed by a lucid (asymptomatic) period of up to 48 hours. The patient then develops symptoms of elevated intracranial pressure such as headache, nausea, and vomiting, combined with neurologic signs such as hemiparesis. Herniation of the temporal lobe, coma, and death may result if the arterial blood is not evacuated.

Clinical Correlate

An emmetropic cornea achieves refraction with no refractive error. A flat cornea has too little refractive power and focuses an object behind the retina, resulting in hyperopia or far-sightedness. Corneas that are too round have too much refractive power, focusing an object in front of the retina, resulting in myopia or near-sightedness. An irregularly shaped cornea forms distorted images known as astigmatism. Lenses correct for defects in corneal shape, allowing the cornea to become emmetropic. Corneal transplants are performed if opacities reduce the transparency of the cornea.

Clinical Correlate

Glaucoma results from a blockage or restriction of aqueous drainage into the canals of Schlemm. This increases the intraocular pressure in the entire eyeball and results in a decrease in axoplasmic flow in the optic nerve.

Clinical Correlate

Over time, the lens becomes less elastic, reducing the ability to focus on near objects, a condition known as presbyopia.

The lens, like the cornea, can develop opacities known as cataracts. Lens replacements restore visual clarity but not accommodation.

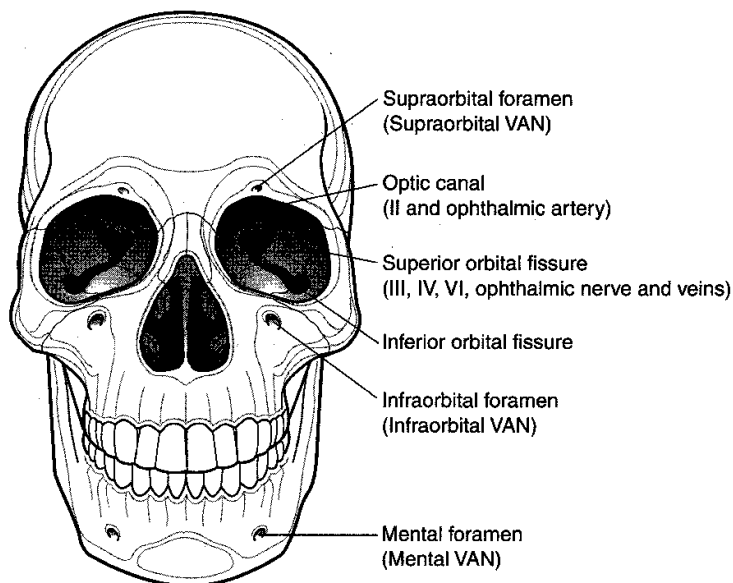


Figure III-6-15. Front of Skull

- The optic canal (Figure III-6-15) transmits the optic nerve and ophthalmic artery.
- The superior orbital fissure (Figure III-6-15) contains the superior ophthalmic veins, which communicate with the cavernous sinus in the middle cranial fossa, and transmits branches of the oculomotor, trochlear, and abducens nerves and branches of the ophthalmic division of the trigeminal nerve (CN V1).
- The optic nerve innervates the retina; the oculomotor, trochlear, and abducens nerves innervate muscles that move the eyeball; and the oculomotor nerve innervates muscles involved in accommodation and a muscle that elevates the eyelid.
- Branches of the ophthalmic division of the trigeminal nerve carry general sensation from the eyeball and from the face adjacent to the orbit.

Orbital muscles and their innervation

In the orbit, there are six extraocular muscles, which move the eyeball (Figure III-6-16). A seventh muscle, the levator palpebrae superioris, elevates the upper eyelid. Four of the six extraocular muscles, the superior, inferior, and medial rectus, and the inferior oblique, plus the levator palpebrae superioris, are innervated by the oculomotor nerve (CN III). The superior oblique muscle is the only muscle innervated by the trochlear nerve (CN IV), and the lateral rectus is the only muscle innervated by the abducens nerve (CN VI). The levator palpebrae superioris is composed of skeletal muscle innervated by the oculomotor nerve (CN III) and smooth muscle (the superior tarsal muscle) innervated by sympathetic fibers. Sympathetic fibers reach the orbit from a plexus on the internal carotid artery of postganglionic axons that originate from cell bodies in the superior cervical ganglion.

In addition to the superior tarsal part of the levator palpebrae superioris, there are three other smooth muscles in the orbit, the dilator and constrictor pupillae and the ciliary muscle. The iris

contains the dilator pupillae (radial) muscle and the sphincter pupillae (circular) constrictor muscle, which have antagonistic effects on the diameter of the pupil. The dilator pupillae muscle is innervated by preganglionic sympathetic fibers from the upper thoracic spinal cord and postganglionic sympathetics from the superior cervical ganglion. The constrictor pupillae muscle is innervated by preganglionic parasympathetic fibers from the nucleus of Edinger Westphal, which exit the midbrain in CN III, and by postganglionic parasympathetic fibers from the ciliary ganglion.

The ciliary muscle is a smooth muscle that, when contracted, relaxes the suspensory ligament of the lens, allowing the lens to "round up" for near vision. Contraction of the ciliary muscle is part of the accommodation reflex under control of parasympathetic fibers in the oculomotor (CN III) nerve.

The orbit also contains the **lacrimal gland**; parasympathetic innervation to the gland comes from the facial nerve by way of the pterygopalatine ganglion.

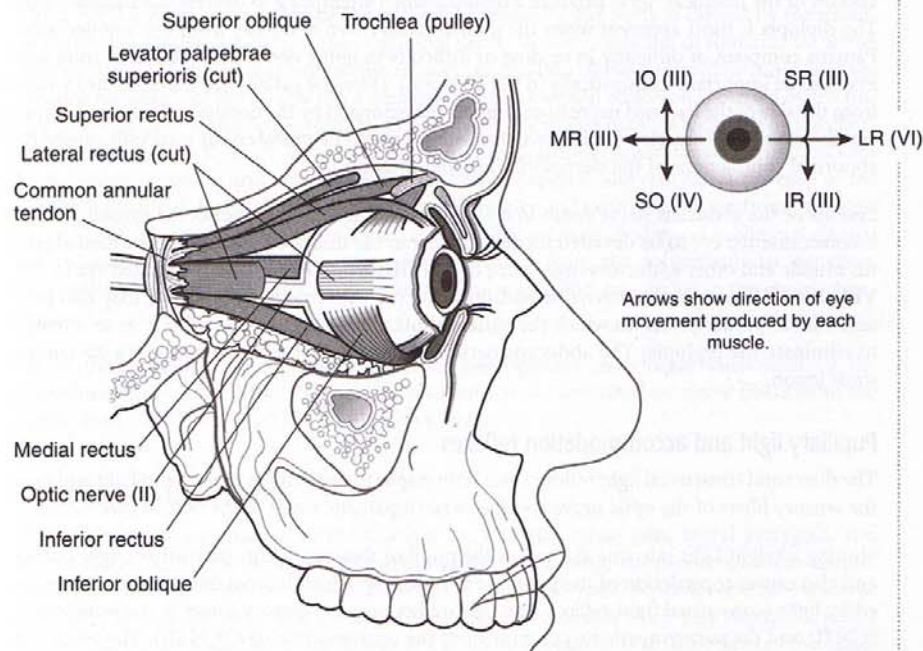


Figure III-6-16. Muscles of the Eye

Clinical Features

Examination of the eyes can be used to evaluate the three cranial nerves that innervate muscles which move the eyeball (CN III, IV, and VI), sensory fibers of the trigeminal (CN V) and motor fibers of the facial nerve (CN VII) through the blink reflex, the optic nerve (CN II) and parasympathetic fibers of CN III through the pupillary light reflex, and the sympathetic fibers to the head.

Clinical Correlate

All three of the ocular nerves (CN III, IV, and VI) and the ophthalmic division of CN V traverse the cavernous sinus on their way either to or from the superior fissure. All but the abducens nerve course in the lateral wall of the sinus. The abducens nerve courses through the middle of the sinus adjacent to the internal carotid artery, and, as a result, an internal strabismus may precede a complete ophthalmoplegia on the affected side combined with altered sensation in the forehead, scalp, and over the bridge of the nose.

Clinical Correlate

Argyll Robertson pupils may be seen in patients with tabes dorsalis caused by tertiary neurosyphilis. Tabetic patients present with pain, paresthesias, and polyuria.

Lesions of the oculomotor nerve (CN III) present most dramatically in a weakness in the ability to adduct the eyeball. The eyeball will be deviated laterally, and it will be abducted and slightly depressed by the unopposed actions of the lateral rectus and superior oblique. Clinically, the lateral deviation of the eye is known as an external strabismus. CN III lesions also cause a ptosis combined with a dilated pupil (mydriasis), a loss of accommodation, and a loss of the motor limb of the pupillary light reflex, resulting in a loss of the ability to constrict the pupil on the affected side. Fibers in the oculomotor nerve are organized so that parasympathetic fibers lie external to those that supply the extraocular muscles. Therefore, compressive lesions (e.g., temporal lobe herniation, aneurysms) tend to involve the parasympathetic fibers first, producing mydriasis and loss of the pupillary light reflex before paralysis of the extraocular muscles. In contrast, vascular disease (e.g., diabetes mellitus) often affects the deeper fibers, causing ptosis and paralysis of the extraocular muscles while sparing the pupil. Common causes of peripheral CN III lesions include berry aneurysms (most often involving the posterior communicating artery) and compression secondary to a subdural or epidural hematoma caused by head trauma and herniation of the temporal lobe under the free edge of tentorium cerebelli.

Lesions of the trochlear nerve produce a diplopia when attempting to depress the adducted eye. The diplopia is most apparent when the patient looks down and away from the lesioned side. Patients complain of difficulty in reading or difficulty in going down stairs. A loss of intorsion may also be important diagnostically in CN IV lesions. Here, the patient tilts his or her head away from the side of the lesioned nerve to counteract the extorsion by the unopposed inferior oblique and inferior rectus muscles. In children, the head tilt might be mistaken for torticollis caused by abnormal contractions of the sternocleidomastoid muscle.

Lesions of the abducens nerve result in a weakness in the ability to abduct the eyeball. CN VI lesions cause the eye to be deviated medially owing to the unopposed action of the medial rectus muscle and other adductors innervated by CN III. Clinically, a medially deviated eye in CN VI lesions is known as an internal strabismus. Patients with internal strabismus may also present with a "pseudoptosis" in which the patient shuts the eye on the affected side in an attempt to eliminate the diplopia. The abducens nerve may be the first nerve affected in a cavernous sinus lesion.

Pupillary light and accommodation reflexes

The direct and consensual light reflex causes both pupils to constrict in response to light and uses the sensory fibers of the optic nerve and the parasympathetic fibers of the oculomotor nerve.

Shining a bright light into one eye causes the pupil of that eye to constrict (direct light reflex) and also causes constriction of the pupil in the other eye, which has not been directly stimulated by light (consensual light reflex). The light reflex uses the sensory fibers in the optic nerve (CN II) and the parasympathetic component of the oculomotor nerve (CN III). The reflex has both direct and consensual components. Light stimulating one retina sends impulses into one optic nerve but into both optic tracts through the partial crossing at the optic chiasm. Both optic tracts send impulses to nuclei in the pretectal region of the midbrain, which in turn project back to both Edinger Westphal nuclei, causing both pupils to constrict. By separately testing the effects of light in each eye, localization of a lesion to either the optic or oculomotor nerve can be determined. The accommodation reflex or near response uses both skeletal motor and parasympathetic fibers in the oculomotor nerve. Movement of an object toward the patient results in a bilateral pupillary constriction, a rounding up of the lens (parasympathetic fibers), and convergence (skeletal motor fibers to both medial rectus muscles).

Pupillary defects

Defects in the response of both pupils to light can be caused by lesions to either the afferent or efferent limbs of the light reflex. An afferent pupillary defect may result from lesions to the optic nerve and can be evaluated using the swinging flashlight test. When light is presented to the normal eye, both pupils will constrict, but when the flashlight is swung to the affected eye, the affected pupil will paradoxically dilate. Lesions to the oculomotor nerve will cause an efferent pupillary defect. Light presented to either eye will cause the pupil on the normal side to constrict, but the affected pupil will not. In Argyll Robertson pupils, there is a bilateral loss of pupillary constriction in response to light, but both pupils react normally in accommodation. The location of the lesion resulting in the Argyll Robertson pupils is thought to be inside the mid-brain affecting neurons governing the pupillary response but sparing those controlling the near response.

INNERVATION OF ORAL CAVITY

The general sensory innervation of the oral cavity, including the teeth, is carried by the maxillary and mandibular divisions of the trigeminal nerve. Sensory branches of four cranial nerves (CN V3, VII, IX, and X) contribute to the sensory innervation of the tongue. The mucosa of the anterior two thirds of the tongue has a dual innervation. General sensation is carried by the lingual nerve of CN V3, and taste except for taste buds on the vallate papillae is carried by the chorda tympani of CN VII. In the posterior one third, the glossopharyngeal nerve carries fibers for both general sensation and taste including the vallate papillae. The mucosa at the base of the tongue (in front of the epiglottis) receives general sensory and taste innervation from the vagus nerve (CN X). Serous glands in the tongue (as well as the submandibular and sublingual glands) are supplied by postganglionic parasympathetic axons from the submandibular ganglion. Preganglionic parasympathetics to the submandibular ganglion are carried in the chorda tympani of CN VII.

All of the muscles of the tongue except the palatoglossus muscle are innervated by the hypoglossal nerve (CN XII). The palatoglossus muscle is innervated by nerve fibers from the vagus nerve (CN X) through the pharyngeal plexus.

Muscles of Mastication

There are four major muscles of mastication: the masseter, temporalis, lateral pterygoid, and medial pterygoid. All but the masseter lie in the infratemporal fossa. The masseter, temporalis, and medial pterygoid muscles elevate the mandible. The lateral pterygoid depresses and protrudes the mandible. The medial and lateral pterygoids protrude the mandible when they contract together and deviate the mandible from side to side in a grinding motion. The anterior belly of the digastric and the mylohyoid are suprahyoid muscles, which also act as muscles of mastication by depressing the mandible. Muscles in the infratemporal fossa and, in general, muscles that move the mandible are innervated by the mandibular nerve of the trigeminal (CN V3). Skin over the mandible plus mucosa of the anterior two thirds of the tongue and adjacent oral cavity is innervated by sensory fibers of CN V3.

Clinical Correlate

Lesions of the hypoglossal nerve result in deviation upon protrusion of the tongue toward the side of the injured nerve combined with fasciculations and atrophy.

Clinical Correlate

Lesions to the glossopharyngeal nerve usually occur in conjunction with the vagus (see below) and accessory nerves in jugular foramen syndrome and present reliably only with sensory deficits. The typical CN IX signs include a depressed sensory limb of the gag reflex as a result of a loss of all sensations on the affected side of the posterior one third of the tongue and in the wall of the oropharynx.

Middle ear infections may involve the preganglionic parasympathetic axons destined to innervate the otic ganglion and ultimately affect the secretory activity of the parotid gland. A reduction in parotid secretions into the oral cavity is difficult to evaluate, because the submandibular and sublingual salivatory glands, which are innervated by the facial nerve, are contributing to the content of saliva.

Clinical Correlate

Lesions of the trigeminal nerve are usually associated with altered sensation and pain. Trigeminal neuralgia (*tic douloureux*) is characterized by episodes of sharp stabbing pain that radiate over the territory supplied by sensory branches of the maxillary or mandibular divisions of the trigeminal nerve. Branches of the ophthalmic division are rarely involved. The pain occurs most frequently in two areas. In most cases of neuralgia, pain radiates over the mandible, extending around the temporomandibular joint, then deep to the external ear, whereas in other cases, pain radiates up the nostril into and around the orbit. The pain is frequently triggered by moving the mandible, smiling, or yawning, or by cutaneous or mucosal stimulation, and it may be caused by pressure on or interruption of the blood supply to the trigeminal ganglion. Lesions to the motor fibers in the trigeminal nerve result in a weakness of muscles of mastication and a deviation of the jaw toward the side of the injured nerve.

INNERVATION OF PALATE

All the muscles of the soft palate except for the tensor veli palatini receive their motor innervation from the vagus nerve (CN X). The tensor veli palatini muscle is innervated by the mandibular nerve (CN V3). The inferior aspect of the hard and soft palates receives general sensory innervation from branches of the maxillary nerve (CN V2). Secretomotor (postganglionic parasympathetic) fibers reach mucous glands in the palate from postganglionic cell bodies in the pterygopalatine ganglion.

Muscles of the Pharynx

The pharynx is composed of skeletal muscles that form a circular layer and a longitudinal layer. Three muscles, the superior, middle, and inferior constrictor muscles, form the outer circular layer. These muscles overlap one another posteriorly. The inner longitudinal muscle layer of the pharynx is formed by three longitudinal muscles—the salpingopharyngeus, stylopharyngeus, and palatopharyngeus—which expand and insert into the pharyngeal wall. These three longitudinal muscles function by elevating the pharynx during swallowing.

The pharynx is innervated mainly by the glossopharyngeal nerve (CN IX) and the vagus nerve (CN X). All of the pharyngeal muscles are innervated by motor branches of the vagus nerve except for the stylopharyngeus, which is innervated by the glossopharyngeal nerve. Sensory innervation of the nasopharynx is provided by the maxillary division of the trigeminal nerve and by branches of the glossopharyngeal nerve. Sensory innervation of the oropharynx is provided by branches of the glossopharyngeal nerve. Sensory innervation of the laryngopharynx is provided by the vagus nerve.

Gag Reflex

The gag reflex stimulates sensory fibers of the glossopharyngeal nerve (CN IX) in the oropharyngeal mucosa, followed by contraction of the pharyngeal musculature and elevation of the palate. The vagus (CN X) nerve is the motor limb of the gag reflex, inasmuch as muscles that elevate the palate and constrict the pharynx are innervated by its motor fibers. Testing the sensory fibers of CN IX in the wall of the oropharynx or in the posterior one third of the tongue is the most useful way of testing CN IX because evaluation of its skeletal or parasympathetic components is difficult.

Cough Reflex

The cough reflex functions to expel substances from the vestibule of the larynx. The vagus nerve serves as both the afferent and efferent components of the cough reflex through sensory fibers in the internal branch of the superior laryngeal nerve of CN X and the motor fibers in the recurrent laryngeal nerve of CN X.

Cardiac Reflexes

Just distal to the origin of the internal carotid artery from the common carotid, there is a dilatation of the wall of the internal carotid artery, which contains the carotid sinus.

In the carotid sinus are baroreceptors for monitoring blood pressure. These receptors are innervated by visceral sensory branches of the glossopharyngeal and vagus nerves. Stimulation of these nerves causes a reflex firing of the parasympathetic fibers in the vagus nerve, resulting in a decrease in the rate and force of cardiac contraction as well as peripheral vasodilation and a decline in blood pressure. In some individuals, light pressure over the carotid sinus can cause fainting.

At the origin of the external and internal carotid arteries is the carotid body, which is a chemoreceptor for oxygen and carbon dioxide. It is also innervated by sensory branches from the glossopharyngeal and vagus nerves. In the carotid body reflex, changes are detected by chemoreceptors in the carotid body and cause alterations in respiratory rate.

LARYNX

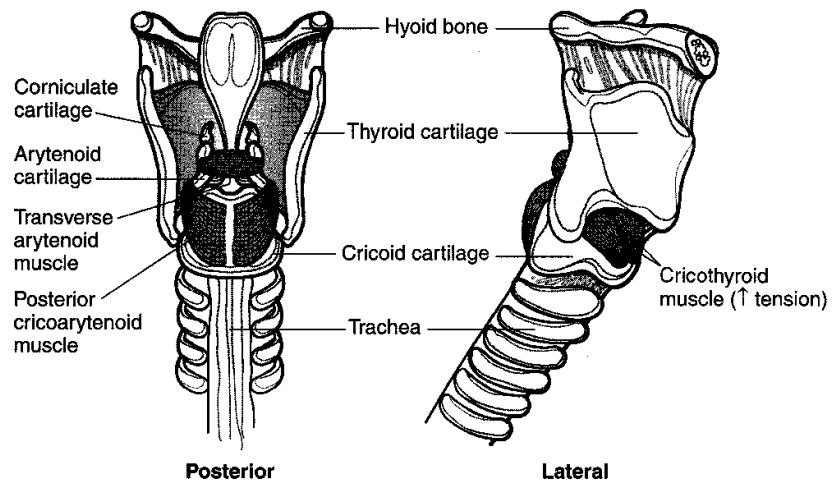
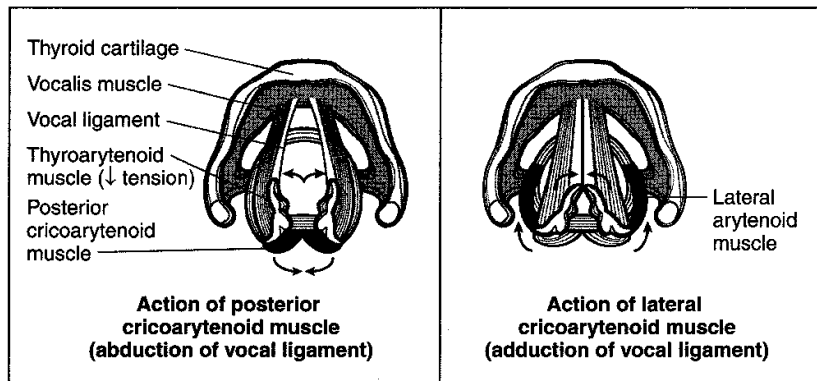


Figure III-6-17. Larynx

Muscles of the Larynx

Two pairs of antagonistic skeletal muscles act on the vocal ligaments, resulting in changes in the position and tension of the vocal folds in the glottis.

The first pair, the lateral cricoarytenoid and posterior cricoarytenoid muscles, acts on the vocal ligament through attachments to the arytenoid cartilage.

These muscles rotate the arytenoid cartilages and cause the vocal ligaments to be abducted or adducted, resulting in the rima glottidis being opened or closed.

The lateral cricoarytenoid muscle adducts the vocal ligaments. Full adduction of the vocal ligaments causes the vocal folds to meet in the midline, closing off the air passage during swallowing. When the vocal ligaments are partially adducted, air passing between the vocal folds causes the folds to vibrate during phonation.

The posterior cricoarytenoid is the only muscle that abducts the ligaments by rotating the arytenoid cartilages in a direction opposite to that caused by the action of the lateral cricoarytenoid muscles.

The second pair of muscles, the thyroarytenoid and cricothyroid, relax and tense the vocal ligaments, respectively. Contraction of the thyroarytenoid muscles pulls the arytenoid cartilages closer to the thyroid and relaxes the vocal ligaments. The vocalis muscle, which is the medial part of the thyroarytenoid, adjusts the tension on small segments of the vocal ligament. The cricothyroid muscles, which lie on the anterior aspect of the larynx between the cricoid and thyroid, tense the vocal ligament by rocking the superior aspect of the thyroid anteriorly at its articulation with the cricoid, increasing the distance between the thyroid and arytenoid cartilages.

Two branches of the vagus nerve innervate all muscles of the larynx and carry sensory fibers from the laryngeal mucosa.

The recurrent laryngeal nerve (inferior laryngeal nerve) innervates all muscles of the larynx except for the cricothyroid and provides sensory innervation of the laryngeal mucosa below the vocal folds.

The superior laryngeal nerve through its external and internal branches provides the remainder of motor and sensory innervation of the larynx.

- The external branch of the superior laryngeal nerve innervates the cricothyroid muscle and sends fibers to supply the inferior constrictor muscle of the pharynx.
- The internal branch of the superior laryngeal nerve provides sensory innervation of laryngeal mucosa above the vocal folds.

Clinical Correlate

Lesions of the vagus nerve result in a drooping of the palate ipsilateral to the injured nerve and a deviation of the uvula to the opposite side. Dysphagia, a difficulty in swallowing, and nasal speech may also be evident and may be accompanied by nasal regurgitation of liquids.

Vagus nerve lesions, which include laryngeal nerves, also result in a paralysis of the vocal cord musculature. The cord will assume a fixed position midway between abduction and adduction, resulting in speech that is hoarse and weak. Vagus nerve lesions may also result in a loss of the motor limb of the gag reflex and the cough reflex.

Lesions of the superior laryngeal nerve are largely asymptomatic, because its fibers are mainly sensory. If the motor fibers to the cricothyroid are affected in the external branch, there may be some mild hoarseness and a slight decrease in vocal strength.

Both recurrent laryngeal nerves are susceptible to injury in surgical procedures involving the thyroid gland. Lesions of a recurrent laryngeal nerve result in a fixed vocal cord and transient hoarseness. Evaluation of the vagus nerve includes examination of palatal movements when the patient says "Aah," because the palate moves during vocalization. The left recurrent laryngeal nerve is injured more frequently than the right owing to its longer course through the superior mediastinum and the neck. The right recurrent laryngeal nerve is found only in the neck.

Muscles

Table III-6-4 summarizes the skeletal muscles innervated by cranial nerves.

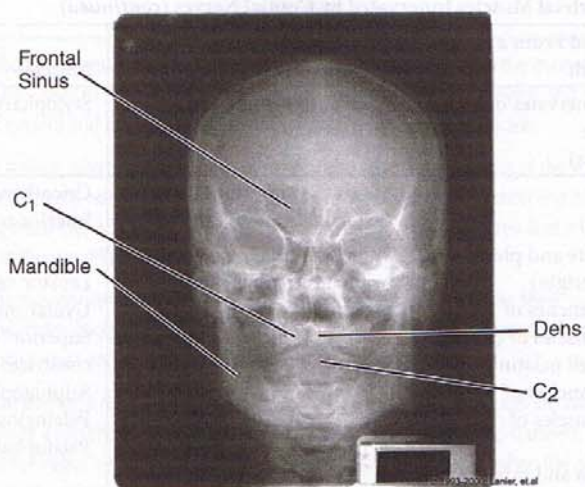
Table III-6-4. Skeletal Muscles Innervated by Cranial Nerves

Muscles Derived From a Pharyngeal Arch	Cranial Nerve	Muscles	Skeletal Elements
1st arch—mandibular (V3 innervates muscles that move mandible plus two tensors)	Trigeminal Mandibular Nerve (V3)	Four muscles of mastication: Masseter Temporalis Lateral pterygoid Medial pterygoid, plus Digastric (anterior belly) Mylohyoid Tensor tympani Tensor veli palatini	Mandibular process Maxillary process (Meckels cartilage) Malleus Incus Sphenomandibular ligament
2nd arch—hyoid (VII innervates muscles that change the shape of an opening on the face)	Facial (VII)	Orbicularis oculi Orbicularis oris Buccinator and others, plus Digastric (posterior belly) Stylohyoid Stapedius	Hyoid (superior part) Styloid process Stapes Stylohyoid ligament

(Continued)

Table III-6-4. Skeletal Muscles Innervated by Cranial Nerves (*continued*)

Muscles Derived From a Pharyngeal Arch	Cranial Nerve	Muscles	Skeletal Elements
3rd arch (IX innervates only one muscle, the stylopharyngeus)	Glossopharyngeal (IX)	Stylopharyngeus	Hyoid (inferior part)
4th arch Muscles of palate and pharynx (controversial origin) (pharyngeal branches of X innervate all muscles of palate except tensor veli palatini) (pharyngeal branches of X innervate all muscles of pharynx except stylopharyngeus and inferior constrictor)	Vagus (X) superior laryngeal (external branch) Vagus (X) pharyngeal branches to pharyngeal plexus	Cricothyroid Inferior constrictor Levator veli palatini Uvular muscle Superior/ middle constrictors Salpingopharyngeus Palatoglossus Palatopharyngeus	Thyroid cartilage
5th arch	Lost		
6th arch (recurrent laryngeal of X innervates all intrinsic muscles of larynx except cricothyroid) Muscles of myotome origin (XI innervates two muscles that shrug shoulder or turn head) Occipital myotome muscles (XII innervates all tongue muscles ending in -glossus except palatoglossus) Preotic myotome muscles (III innervates all muscles that move the eyeball except superior oblique and lateral rectus)	Vagus (X) recurrent laryngeal Accessory (XI) Hypoglossal (XII) Oculomotor (III) Trochlear (IV) Abducens (VI)	Lateral cricoarytenoid Posterior cricoarytenoid Transverse arytenoid Oblique arytenoid Thyroarytenoid (vocalis) Aryepiglottics Inferior constrictor Trapezius Sternocleidomastoid Genioglossus Hyoglossus Styloglossus Superior, inferior, and medial rectus; inferior oblique, levator palpebrae superioris Superior oblique Lateral rectus	Cricoid, arytenoid, corniculate, cuneiform cartilages Scapula Skull



Copyright 2000 Gold Standard Multimedia, Inc.
All rights reserved.

Figure III-6-18. Head and Neck: Posteroanterior View of Skull

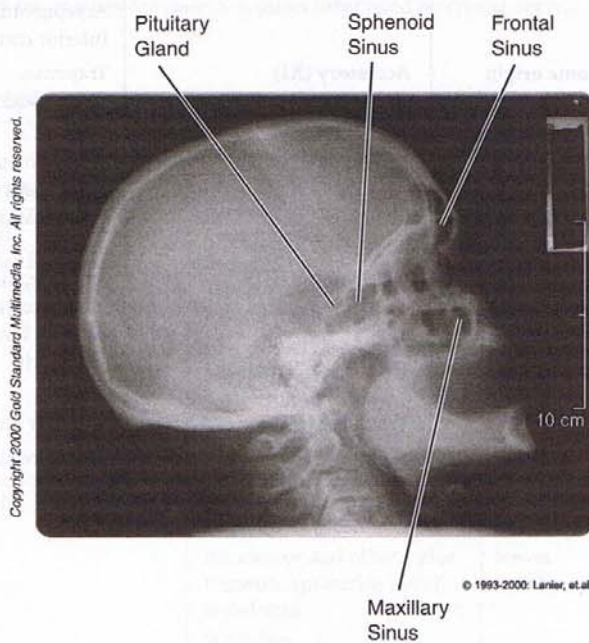


Figure III-6-19. Head and Neck: Lateral Skull

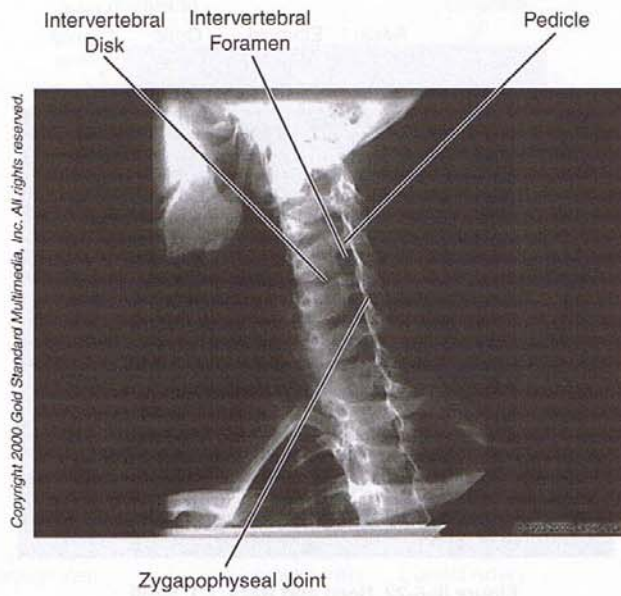


Figure III-6-20. Head and Neck: Oblique Cervical Spine

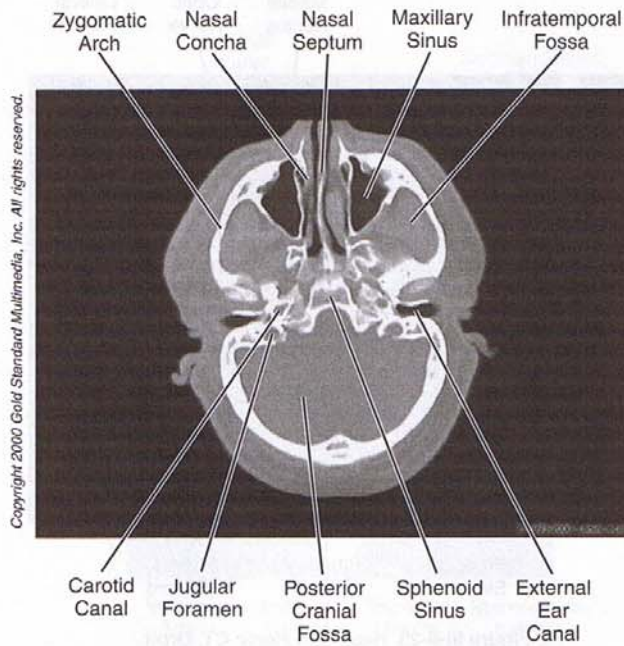


Figure III-6-21. Head and Neck: CT, Skull

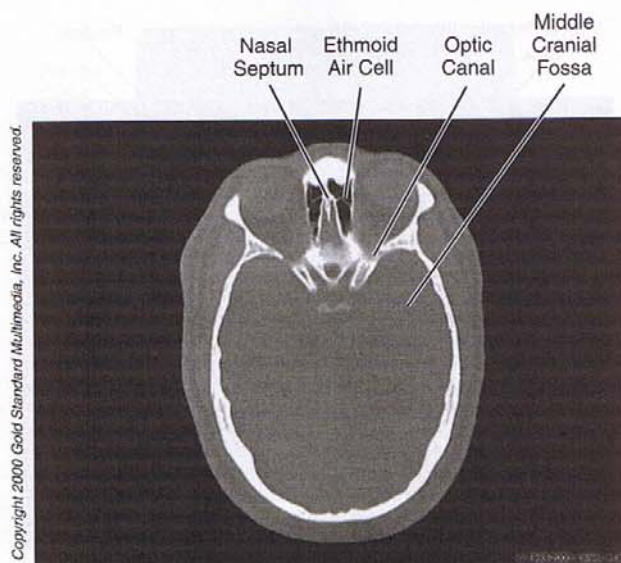


Figure III-6-22. Head and Neck: CT, Skull

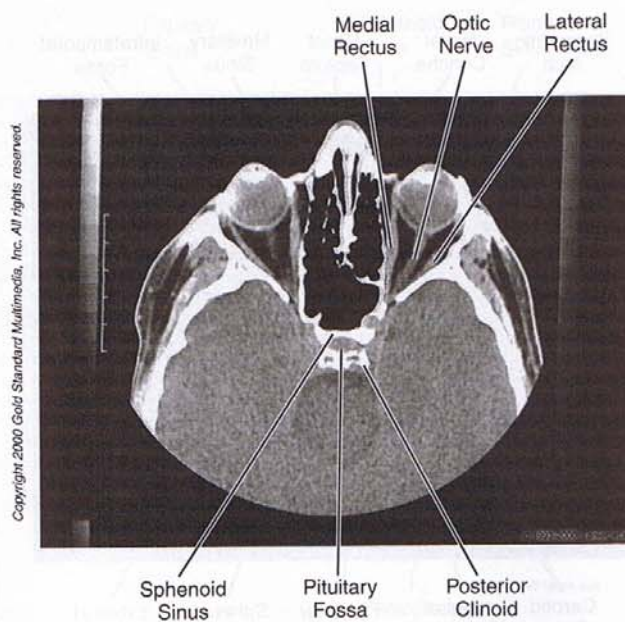


Figure III-6-23. Head and Neck: CT, Orbit

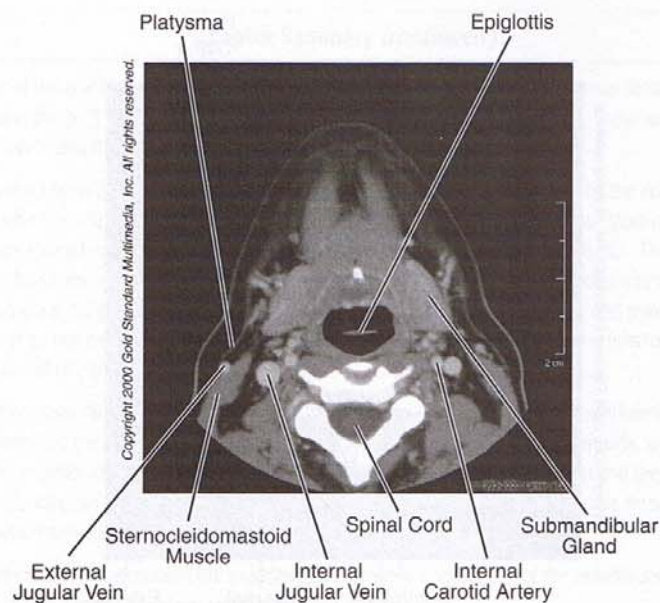


Figure III-6-24. Head and Neck: CT, Neck at C₂ Vertebra

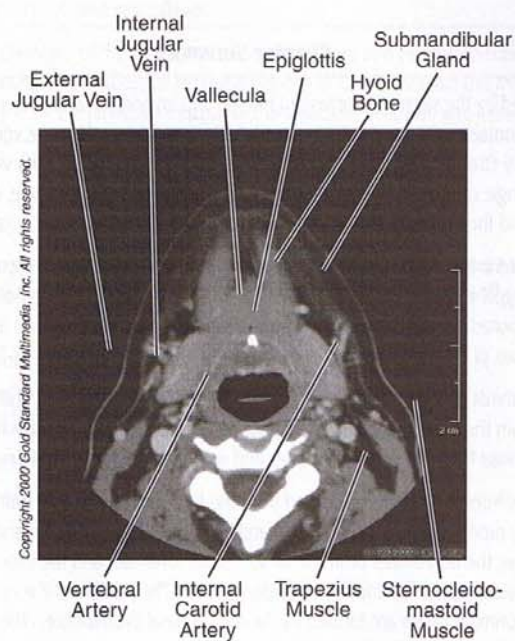
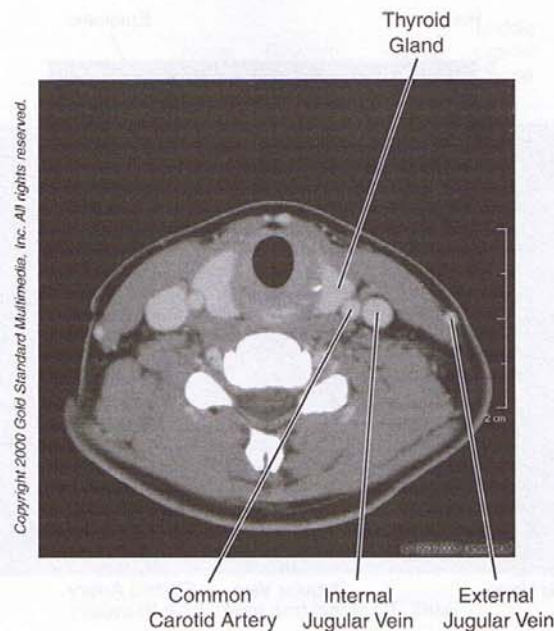


Figure III-6-25. Head and Neck: CT, Neck at C₃

Figure III-6-26. Head and Neck: CT, Neck at C₅

Chapter Summary

The neck is divided by the sternocleidomastoid muscle into an anterior and posterior triangle. The anterior triangle contains vascular structures (carotid artery and internal jugular vein), cranial nerve X, and the respiratory (trachea and larynx) and digestive (pharynx and esophagus) visceral structures. The posterior triangle contains the muscles associated with the cervical vertebrae, cranial nerve XI, cervical plexus, and the origins of the brachial plexus.

Many structures of the head and neck develop from the branchial (pharyngeal) apparatus. The apparatus consists of pharyngeal arches, pouches, and grooves. The grooves are composed of ectoderm, the pouches are composed of endoderm, and the arches are composed of mesoderm and neural crest cells. The adult derivatives of the arches and pouches are given in Tables III-6-1 and III-6-2, respectively.

The anterior two-thirds of the tongue develops from the first pharyngeal arch, and the posterior one-third develops from the third pharyngeal arch. The muscles of the tongue derive from myoblasts that migrate into the head from the occipital somites and are innervated by cranial nerve XII.

The face develops from five structures derived from the first pharyngeal arch: frontonasal prominence, a pair of maxillary prominences, and a pair of mandibular prominences. The mandibular prominences form the lower jaw, the frontonasal prominence forms the forehead, and the maxillary prominences form the cheek, lateral upper lip, and the secondary palate. The midline of the upper lip, the nasal septum, and the primary palate are formed by the medial nasal prominence. The primary and secondary palate fuse to form the definite palate.

(Continued)

Chapter Summary (continued)

The floor of the cranial cavity is divided into the anterior, middle, and posterior cranial fossae. The openings in the skull provide for passage of the cranial nerves and blood vessels. These are listed in Figures III-6-11 and III-6-15.

Venous return from the brain and other structures of the cranial vault is provided by the dural venous sinuses, which ultimately drain into the internal jugular vein at the jugular foramen. Most of these sinuses are located in the folds of the dura mater (falx cerebri and tentorium cerebelli). The major ones are the superior and inferior sagittal and the transverse, sigmoid, and cavernous sinuses. The cavernous sinus is significant because cranial nerves III and IV and the ophthalmic and maxillary divisions of cranial nerve V course in the lateral wall of the cavernous sinus, and the internal carotid artery and cranial nerve VI are found in the lumen.

The orbit contains the ocular muscles, eyeball, and transmits the optic nerve and ophthalmic artery. CN VI innervates the lateral rectus muscle, CN IV innervates the superior oblique muscle, and the remaining muscles are innervated by CN III. The ciliary muscle of accommodation and the sphincter pupillae are supplied by the parasympathetic fibers of CN III, while the dilator pupillae muscle receives sympathetic innervations.

The infratemporal fossa contains the muscles of mastication, distributions of the mandibular nerve and maxillary artery, the otic ganglion, and the chorda tympani.

The pharynx is the fibromuscular tube that is divided into three parts and serves both respiratory and digestive functions. The sensory supply for the three parts are CN IX from the nasopharynx and oropharynx and CN X from the laryngopharynx. Motor innervation is provided by CN X to five muscles of the pharynx and CN IX to the stylopharyngeus muscle. These sensory and motor innervations provide the basis of the cough and gag reflexes.

The muscles and the cartilages of the larynx serve both respiratory and phonation functions. Two branches (recurrent laryngeal and superior laryngeal nerves) of CN X innervate the muscles of the larynx and are sensory from the laryngeal mucosa of the vestibule, ventricle, and infraglottic cavity.

Review Questions

1. Your young female patient has repeated episodes of viral and fungal infections, and her blood serum exam reveals hypocalcemia. Which of the following will be also be seen in this patient?
 - (A) Fewer thyroid follicles
 - (B) No palatine tonsil
 - (C) A smaller than normal paracortex in many lymph nodes
 - (D) Mandibular hypoplasia
 - (E) A cleft palate

2. Your patient has been diagnosed with multiple sclerosis. Which of the following neural structures will most likely be affected by this disease?
 - (A) Dorsal root ganglia
 - (B) Optic nerves
 - (C) Ulnar nerves
 - (D) Superior cervical ganglia
 - (E) Facial nerves
3. A CT cross-sectional image of the thorax reveals an absence of an anterior mediastinum shadow in a patient diagnosed with the DiGeorge sequence. What else will be missing in the patient?
 - (A) Thyroid gland
 - (B) Palatine tonsil
 - (C) Malleus and incus
 - (D) Parathyroid gland
 - (E) Adrenal medulla
4. An infection develops in a dural sinus lateral to the body of the sphenoid bone in the floor of the middle cranial fossa. Which neurological observation might you expect the patient to exhibit initially on the affected side?
 - (A) Ptosis
 - (B) Dilated pupil
 - (C) Medial strabismus
 - (D) Altered sensation in skin of the forehead
 - (E) Hemianopsia
5. An apical lung tumor has compressed structures that pass through the scalene interval and cross the first rib. This patient would most likely exhibit
 - (A) weakness in abduction at the shoulder
 - (B) Horner syndrome
 - (C) weakness in protracting the scapula
 - (D) hemidiaphragmatic weakness
 - (E) a Babinski sign
6. A 25-year-old man was stuck in the face during a fight. He is brought to the emergency room where he can no longer close his mouth. Pain is intense in the right side of his jaw, and bloodstained saliva drips from his mouth. The patient indicates that he cannot feel the skin of his chin or lower lip on the side of the fracture. Radiology reveals a mandibular fracture. The posterior part of the mandible may be displaced superiorly by contractions of which muscle?
 - (A) Digastric
 - (B) Buccinator
 - (C) Masseter
 - (D) Lateral pterygoid
 - (E) Orbicularis oris

7. The altered sensation in the above patient is due to laceration of branches of the
 - (A) facial nerve
 - (B) cervical nerves
 - (C) maxillary nerve
 - (D) mandibular nerve
 - (E) great auricular nerve

8. A 15-year-old boy falls from his bicycle and hits his head. His initial examination in the emergency room is normal, but later in the day, he becomes noticeably lethargic. He is brought back to the ER where he is too drowsy to answer the examiner's questions. His right pupil is 7 mm, and his left pupil is 4 mm. Patellar tendons reflexes are brisker on the left, and a Babinski sign can be elicited on the left. CT imaging reveals that a pool of blood has displaced the right temporal lobe to the left. The hematoma is evacuated, and a blood vessel is cauterized. Through which opening did the lacerated blood vessel enter the cranial cavity?
 - (A) Foramen spinosum
 - (B) Stylomastoid foramen
 - (C) Foramen lacerum
 - (D) Carotid canal
 - (E) Jugular foramen

9. A tumor in the superior mediastinum impinges upon the arch of the aorta and compresses a nerve. Which of the following is most likely to be observed in the patient?
 - (A) Dysphagia
 - (B) Weakness in the ability to tense the vocal cord
 - (C) Altered sensation in the larynx above the vocal cord
 - (D) Weakness in the ability to elevate the hyoid bone
 - (E) Weakness in the ability to abduct the vocal cord

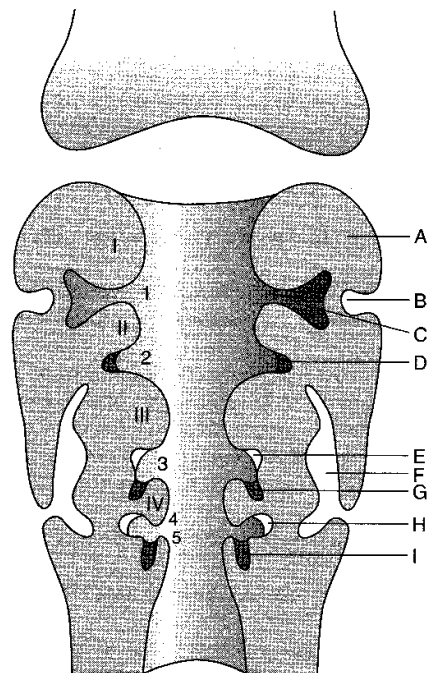
10. An infant has a bilateral cleft lip. Which processes failed to fuse?
 - (A) Lateral nasal prominences with the maxillary prominences
 - (B) Maxillary prominences with the intermaxillary segment
 - (C) Palatine shelves from each maxillary prominence
 - (D) Medial nasal prominences from each side
 - (E) Frontonasal prominence with each maxillary prominence

11. An infant has mandibular hypoplasia and a conductive hearing loss. The defect is in the development of the
 - (A) first pharyngeal arch
 - (B) second pharyngeal arch
 - (C) first pharyngeal pouch
 - (D) ectoderm of the head
 - (E) first somite

12. An infant has a small lump on the anterior aspect of the thyroid cartilage near the midline. You describe this as the pyramidal lobe of the thyroid gland. The pyramidal lobe is a remnant of the
 - (A) thyrocervical cyst
 - (B) first pharyngeal pouch
 - (C) second pharyngeal pouch
 - (D) thyroglossal duct
 - (E) sulcus terminalis
13. Which of the following is derived from the third aortic arch?
 - (A) Maxillary artery
 - (B) Left subclavian artery
 - (C) Right common carotid artery
 - (D) Left pulmonary artery
 - (E) Ductus arteriosus
14. Your patient has been diagnosed with jugular foramen syndrome, which is caused by a tumor compressing nerves passing through the jugular foramen. Which of the following autonomic deficits is the patient most likely to present with?
 - (A) Loss of sweating on the side of the face
 - (B) Reduction in parotid gland secretions
 - (C) A dilated pupil
 - (D) An eye that is dry and red
 - (E) A ptosis
15. If the jugular foramen syndrome were severe enough to cause a destructive lesion to all of the nerve fibers passing through the jugular foramen, where would you expect to see retrograde chromatolysis?
 - (A) Superior salivatory nucleus
 - (B) Solitary nucleus
 - (C) Spinal nucleus of V
 - (D) Nucleus of Edinger Westphal
 - (E) Nucleus ambiguus
16. A tumor has compressed structures traversing the superior orbital foramen. Where is the patient most likely to experience pain and altered sensation?
 - (A) Mucosa of the nasal cavity
 - (B) Mucosa of the nasopharynx
 - (C) Skin over the maxilla
 - (D) Skin of the anterior scalp and dorsum of the nose
 - (E) Mucosa of the oral cavity

17. A tumor in the superior orbital foramen erodes through the floor of the orbit. Where will the surgeon find the tumor?
- (A) Sphenoid sinus
 - (B) Nasal cavity
 - (C) Oral cavity
 - (D) Maxillary sinus
 - (E) Ethmoid sinus

Questions 18 and 19 are based on the figure below.



18. In the figure below, which of the letters indicates a location of tonsillar lymphatic tissue?
- (A) A
 - (B) B
 - (C) C
 - (D) D
 - (E) E
 - (F) F
 - (G) G
 - (H) H
 - (I) I

19. In the figure above, which of the following roman numerals indicates a structure that gives rise to the stapes and the styloid process?
- (A) I
 - (B) II
 - (C) III
 - (D) IV

Answers and Explanations

1. **Answer: C.** The patient has the DiGeorge sequence, which results from improper development of the third and fourth pharyngeal pouches. The thymus and parathyroid glands that develop in these two pouches would be absent; as a result, there would be few T cells in the paracortex of lymph nodes.
2. **Answer: B.** Multiple sclerosis affects only axons in the CNS that have myelin sheaths formed by oligodendrocytes. The optic nerve is a direct outgrowth of the CNS and is the only nerve that falls into this category. All other nerves are in the PNS and have their myelin sheaths formed by Schwann cells.
3. **Answer: D.** The parathyroid gland will be missing in this patient.
4. **Answer: C.** The patient has an infection in the cavernous sinus. The first nerve to be affected would be the abducens nerve resulting in a medially deviated eyeball.
5. **Answer: B.** Apical lung tumors may compress the lower trunk of the brachial plexus, in particular the T1 ventral ramus. Preganglionic sympathetic axons, which leave the spinal cord in the T1 ventral ramus and synapse in the superior cervical ganglion, provide innervation to the face, scalp, and orbit. A complete lesion of these fibers disrupts sympathetic innervation to the face, scalp, and orbit and results in Horner syndrome.
6. **Answer: C.** The only muscle among the choices that elevates the mandible is the masseter.
7. **Answer: D.** Skin of the chin is innervated by branches of the mandibular nerve (V3).
8. **Answer: A.** The middle meningeal artery is typically lacerated in lateral skull trauma, which results in an epidural hematoma. This blood vessel enters the skull through the foramen spinosum.
9. **Answer: E.** The tumor has compressed the left vagus nerve just prior to the branch point of the left recurrent laryngeal nerve. The left recurrent laryngeal nerve innervates all of the muscles of the left side of the larynx except for the cricothyroid, resulting in a weakness in the ability to abduct the left vocal cord. The left recurrent laryngeal nerve also innervates mucosa below the vocal fold, which would also be affected. The superior laryngeal nerve innervates the cricothyroid muscle, which tenses the vocal cord, and innervates mucosa above the vocal fold. The vagus nerve does not innervate muscles that act on the hyoid, and vagal branches to pharyngeal muscles used in swallowing are given off in the neck.
10. **Answer: B.** Maxillary prominences have failed to fuse with each side of the intermaxillary segment.

11. **Answer: A.** The mandible, the malleus, and the incus all are derived from the first pharyngeal arch.
12. **Answer: D.** The thyroid develops in the midline by utilizing a thyroglossal duct that descends in the midline from the apex of the sulcus terminalis in the tongue.
13. **Answer: C.** The third aortic arch gives rise to the common carotid arteries.
14. **Answer: B.** CN IX carries preganglionic parasympathetic axons, which traverse the jugular foramen, synapse in the otic ganglion, and provide secretomotor innervation to the parotid gland.
15. **Answer: E.** Cut axons result in retrograde changes in the neuronal cell bodies in the nucleus ambiguus.
16. **Answer: D.** Branches of the Ophthalmic division of V traverse the superior orbital foramen and carry general sensation from the skin of the anterior scalp and dorsum of the nose.
17. **Answer: D.** The maxillary sinus lies inferior to the orbit.
18. **Answer: D.** The palatine tonsil develops in the second pharyngeal pouch.
19. **Answer: B.** The stapes and styloid process are derived from the second pharyngeal arch.

SECTION IV

Neuroscience

Peripheral Nervous System

1

CELLULAR ELEMENTS

The peripheral nervous system (PNS) contains cranial and spinal nerves that consist of neurons that give rise to axons, which grow out of the neural tube, and neurons derived from neural crest cells. Skeletal motor neurons and axons of preganglionic autonomic neurons are derived from the neural tube (Figures IV-1-1, -2, -3, -4, -5, and -6).

Neural crest cells form sensory neurons and postganglionic autonomic neurons. The neuronal cell bodies of these neurons are found in ganglia. Therefore, all ganglia found in the PNS contain either sensory or postganglionic autonomic neurons and are derived from neural crest cells.

Chromaffin cells are neural crest cells, which migrate into the adrenal medulla to form postganglionic sympathetic neurons.

Schwann cells are glial cells that make myelin for PNS axons. Unlike oligodendrocytes, which make CNS myelin, individual Schwann cells myelinate only a small part of a single axon. At the junction between two Schwann cells, there are discontinuities in the myelin called nodes of Ranvier. Here, action potentials skip from node to node in saltatory conduction.

Clinical Correlate

Peripheral neuropathies such as Guillain-Barré syndrome affect PNS myelinated axons.

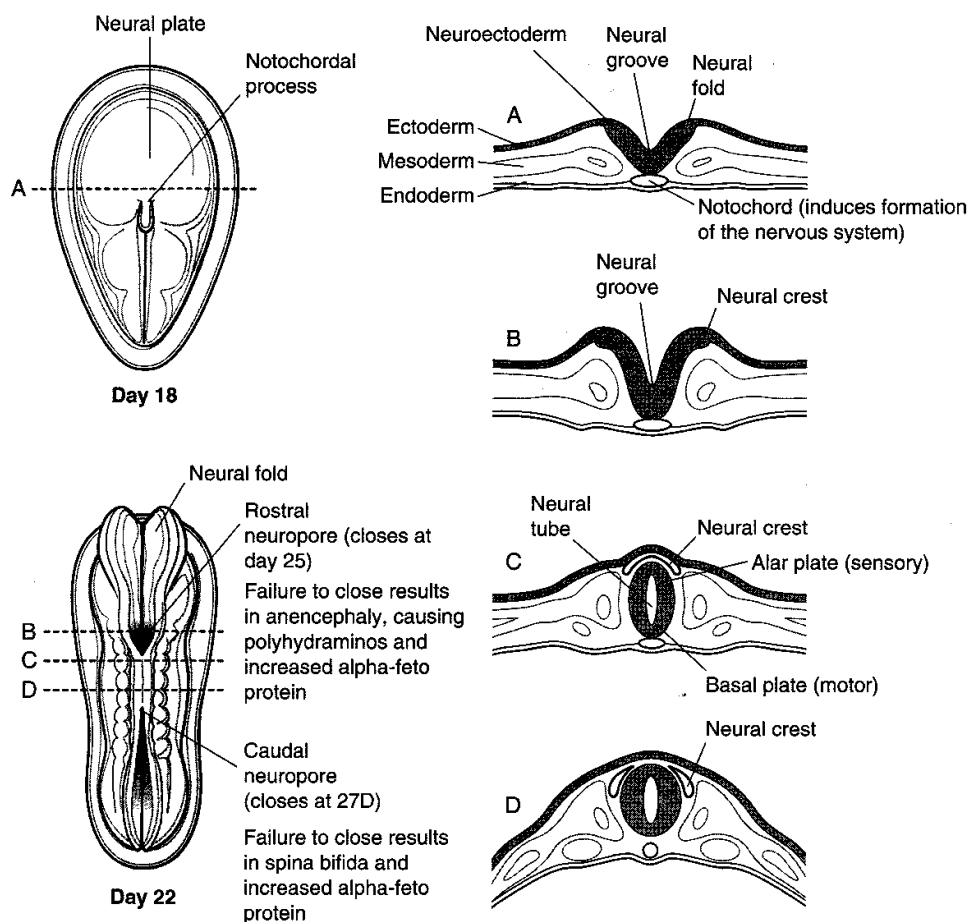
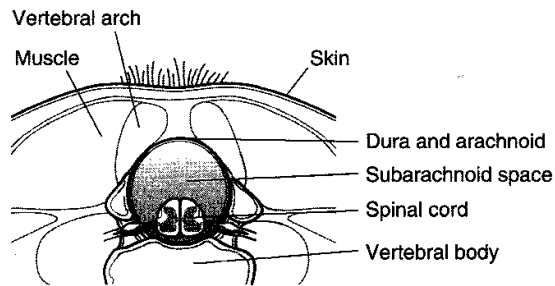


Figure IV-1-1. Third Week Neurulation

Clinical Correlate

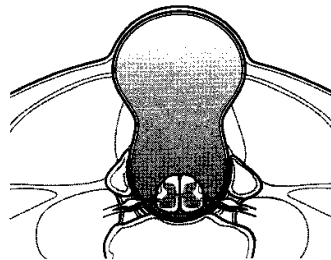
Reduced levels of alpha-feto protein are seen in mothers of fetuses with Down syndrome.

A. Spina bifida occulta:
a defect in the vertebral
arches; asymptomatic

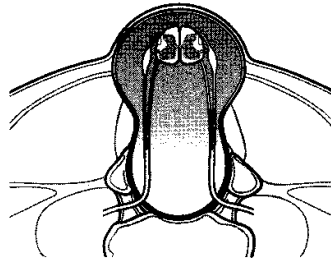


Cystic

B. Spina bifida with meningocele: occurs
when the meninges project
through the vertebral defect;
elevated alpha-feto protein
levels



C. Spina bifida with meningomyelocele:
occurs when the meninges
and spinal cord project
through the vertebral defect;
elevated alpha-feto protein
levels



C. Spina bifida with myeloschisis: results in
an open neural tube that lies
on the surface of the back;
most severe variation;
elevated alpha-feto protein
levels

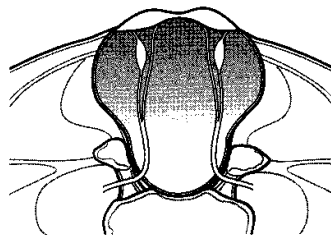


Figure IV-1-2. Malformations of the Vertebral Column or Spinal Cord

Table IV-1-1. Germ Layer Derivatives

Ectoderm	Mesoderm	Endoderm
Surface ectoderm Epidermis Hair Nails Inner ear, external ear Enamel of teeth Lens of eye Anterior pituitary (Rathke pouch) Parotid gland	Muscle Smooth Cardiac Skeletal Connective tissue All serous membranes Bone and cartilage Blood, lymph, cardiovascular organs Adrenal cortex Gonads and internal reproductive organs Spleen Kidney and ureter Dura mater	Forms epithelial parts of: Tonsils Thymus Pharynx Larynx Trachea Bronchi Lungs Urinary bladder Urethra Tympanic cavity Auditory tube GI tract Forms parenchyma of: Liver Pancreas Tonsils Thyroid gland Parathyroid glands Glands of the GI tract Submandibular gland Sublingual gland
Neuroectoderm Neural tube Central nervous system Retina and optic nerve Pineal gland Neurohypophysis Astrocytes Oligodendrocytes		
Neural crest Adrenal medulla Ganglia Sensory Autonomic Pigment cells Schwann cells Meninges Pia and arachnoid mater Pharyngeal arch cartilage Odontoblasts Parafollicular (C) cells Aorticopulmonary septum Endocardial cushions		

Yolk sac derivatives:

- Primordial germ cells
- Early blood and blood vessels
- Epithelia of the gut not derived from endoderm

AUTONOMIC NERVOUS SYSTEM: GENERAL ORGANIZATION

The Autonomic Nervous System (ANS) is responsible for the motor innervation of smooth muscle, cardiac muscle, and glands of the body. The ANS is composed of two divisions: (1) sympathetic and (2) parasympathetic.

In both divisions there are two neurons in the peripheral distribution of the motor innervation.

1. Preganglionic neuron with cell body in CNS
2. Postganglionic neuron with cell body in a ganglion in the PNS

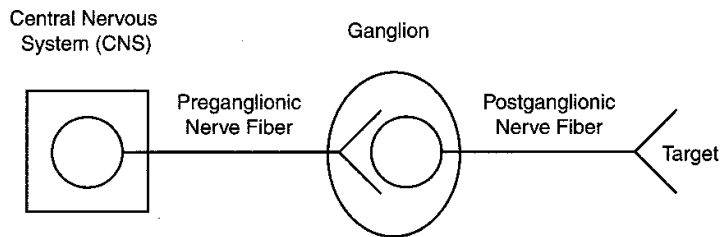


Figure IV-1-3. Autonomic Nervous System

Table IV-1-2. Sympathetic = Thoracolumbar Outflow

Origin	Site of Synapse	Innervation
Spinal cord levels T1-L2	Sympathetic chain ganglia (paravertebral ganglia)	Smooth muscle, cardiac muscle and glands of body wall and limbs, head and thoracic viscera.
Thoracic splanchnic nerves T5-12	Prevertebral ganglia (collateral) (e.g., celiac, aorticorenal superior mesenteric ganglia)	Smooth muscle and glands of the foregut and midgut
Lumbar splanchnic nerves L 1, 2	Prevertebral ganglia (collateral) (e.g., inferior mesenteric and pelvic ganglia)	Smooth muscle and glands of the pelvic viscera and hindgut

Clinical Correlate

Lesions at arrows result in Horner syndrome (ptosis, miosis, and anhidrosis).

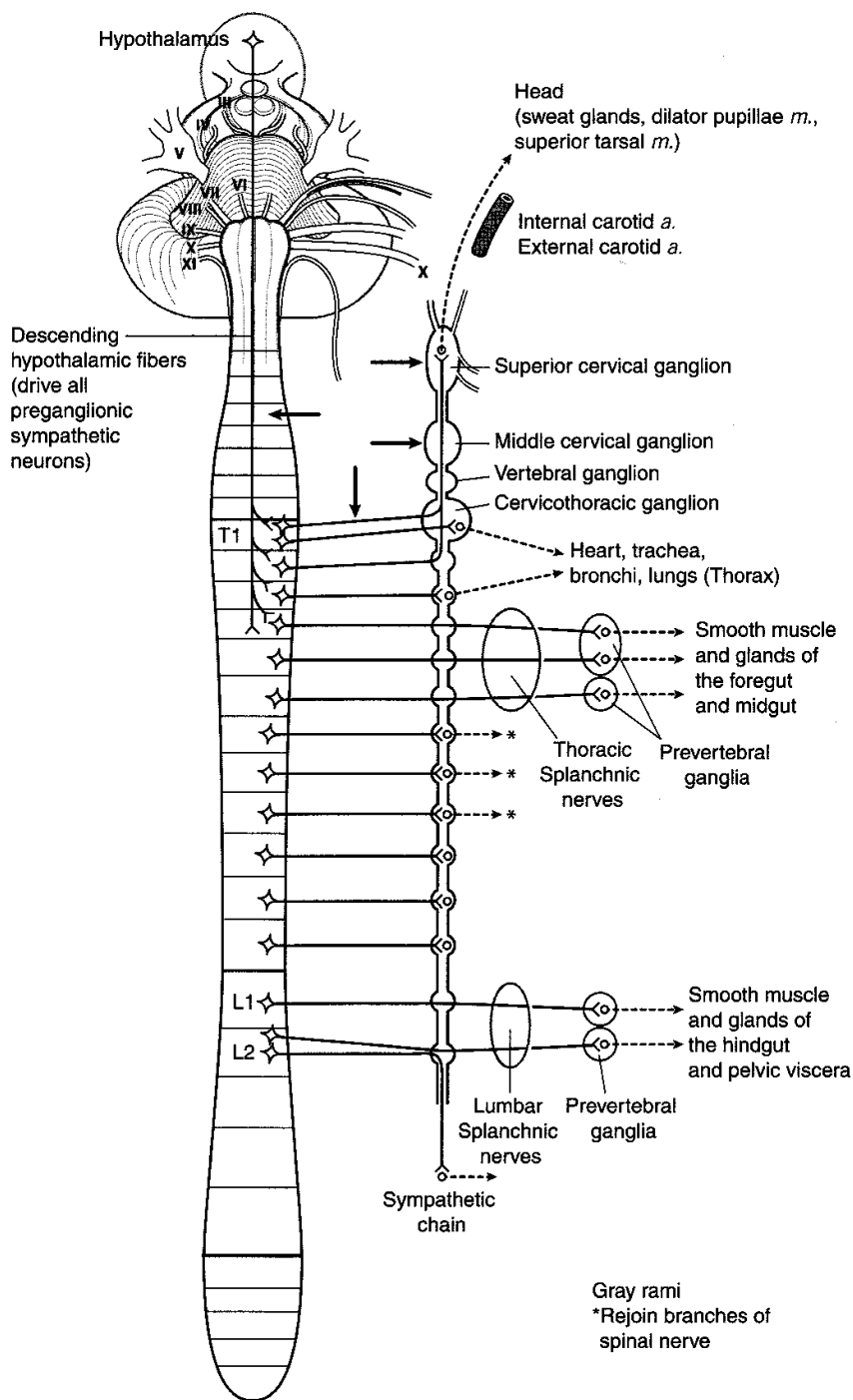


Figure IV-1-4. Overview of Sympathetic Outflow

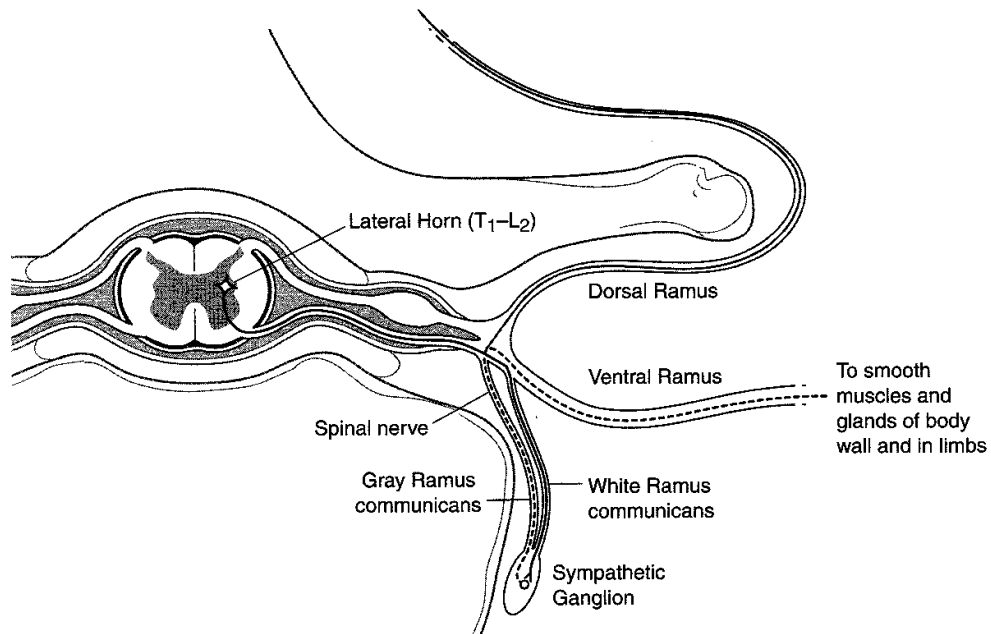


Figure IV-1-5. Cross Section of Spinal Cord Showing Sympathetic Outflow

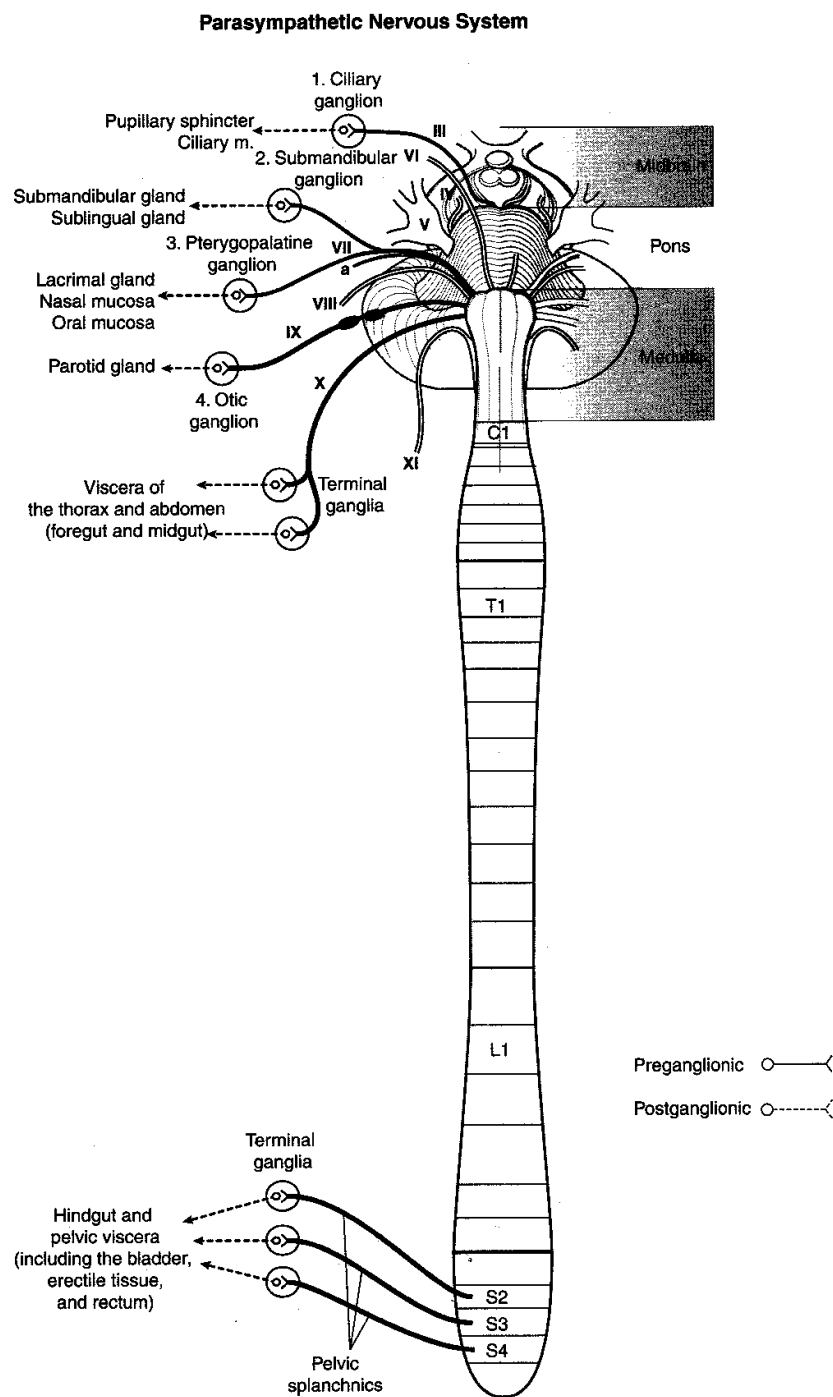


Figure IV-1-6. Overview of Parasympathetic Outflow

Table IV-1-3. Parasympathetic = Craniosacral Outflow

Origin	Site of Synapse	Innervation
Cranial nerves III, VII, IX	4 cranial ganglia	Glands and smooth muscle of the head
Cranial nerve X	Terminal ganglia (in or near the walls of viscera)	Viscera of the neck, thorax, foregut, and midgut
Pelvic splanchnic nerves S2, 3, 4	Terminal ganglia (in or near the walls of viscera)	Hindgut and pelvic viscera (including the bladder and erectile tissue)

Chapter Summary

The peripheral nervous system (PNS) consists of 12 pairs of cranial nerves, 31 pairs of spinal nerves with their related sensory and motor ganglia, and the peripheral part of the autonomic nervous system. The afferent and efferent neurons in the PNS convey somatic and visceral (autonomic) functions to and from the central nervous system (CNS).

Cells of Nervous System

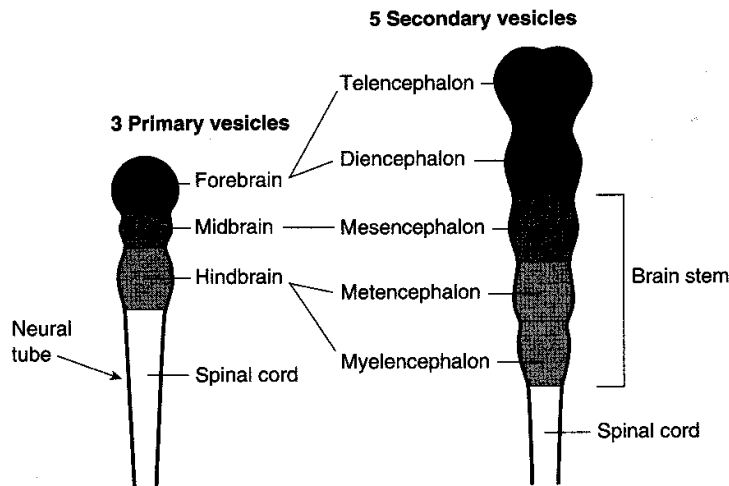
The basic functional cell for conducting motor and sensory functions within the nervous system is the neuron. Neurons in the CNS are myelinated by oligodendrocytes, and in the PNS neurons are myelinated by Schwann cells. Oligodendrocytes myelinate multiple axons but Schwann cells myelinate only a segment of one neuron.

The skeletal motor neurons and preganglionic motor neurons in the CNS develop from the neural tube, whereas the sensory neurons and postganglionic neurons located in sensory or motor ganglia, respectively, in the PNS derive from neural crest cells.

Neurulation and the development of the nervous system begin in the third week of development. As the primitive streak regresses caudally, the notochord develops in the midaxis of the embryo between the buccopharyngeal membrane and the cloacal membrane. The appearance of the notochord then induces the ectoderm overlying the notochord to form the neural plate composed of neuroectoderm cells. The neural plate is wide at the cranial end and tapers caudally. By the end of the third week, the lateral margins of the neural plate thicken and become elevated to form the neural folds with the neural groove located centrally between the two folds. The neural folds then grow over the midline and begin to fuse to form the neural tube. Closure of the neural tube begins in the cervical region and continues cranially and caudally. The cephalic (cranial neuropore) and the caudal (caudal neuropore) ends of the neural tube close last. Failure of closure of the cranial and caudal neuropores results in anencephaly and spina bifida. Alpha-feto protein levels are increased with the neural tube defects. During closure of the neural tube, neural crest cells are formed from neuroectoderm at the margins of the neural folds. The neural crest cells migrate throughout the embryo and form a number of cell types (Table IV-1-1).

Central Nervous System

2



Clinical Correlate

Remnants of Rathke pouch form craniopharyngiomas that compress optic chiasm.

Adult Derivatives		
	CNS	Ventricles
Telencephalon	Cerebral hemispheres and most of basal ganglia	Lateral ventricle
Diencephalon	Thalamus, pineal gland, neurohypophysis, hypothalamus, and the retina	Third ventricle
Mesencephalon	Midbrain	Cerebral aqueduct
Metencephalon	Pons and cerebellum	Fourth ventricle
Myelencephalon	Medulla	

Figure IV-2-1. Third Week: Derivatives of the Brain Vesicles

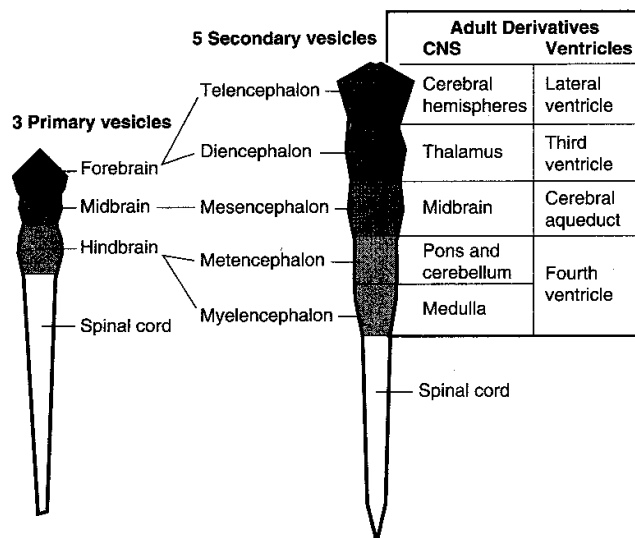


Figure IV-2-2

Clinical Correlate

Axonal polyneuropathies produce distal "glove and stocking" weakness or sensory deficits, and are related to axonal transport failure. Diabetes mellitus patients present with sensory neuropathies.

The roots of 31 spinal nerves enter or exit segmentally from the spinal cord.

The anterior pituitary (adenohypophysis) is an outgrowth of oral ectoderm (Rathke pouch) and is not derived from the CNS.

Clinical Correlate

Axons utilize anterograde and retrograde axonal transport to move subcellular elements toward or away from the axon terminal. Anterograde transport utilizes microtubules, is mediated by kinesin, and moves vesicles and protein to the axon terminal. Retrograde axonal transport also uses microtubules, is mediated by dynein, and transports lysosomes and recycled membrane. Exogenous substances such as herpesvirus, polio virus, rabies, and tetanus toxin affect neuron cell bodies as a result of retrograde axonal transport.

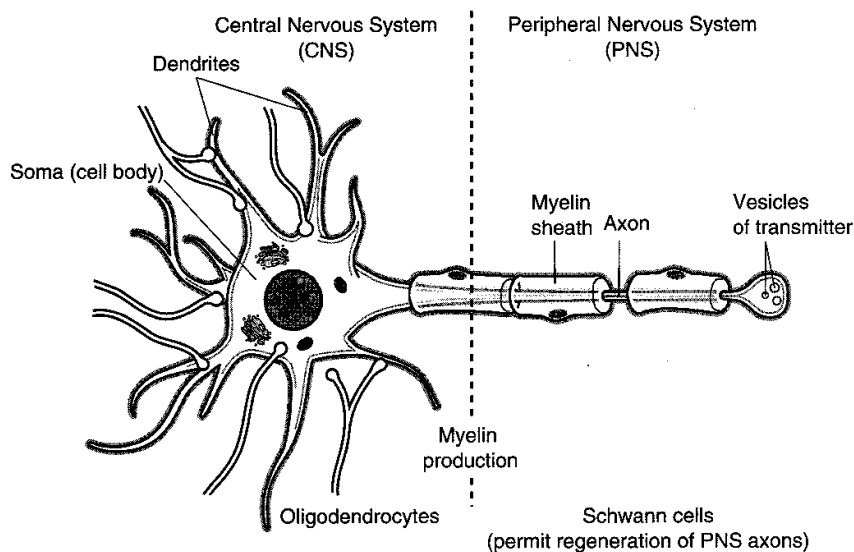


Figure IV-2-3. The Neuron

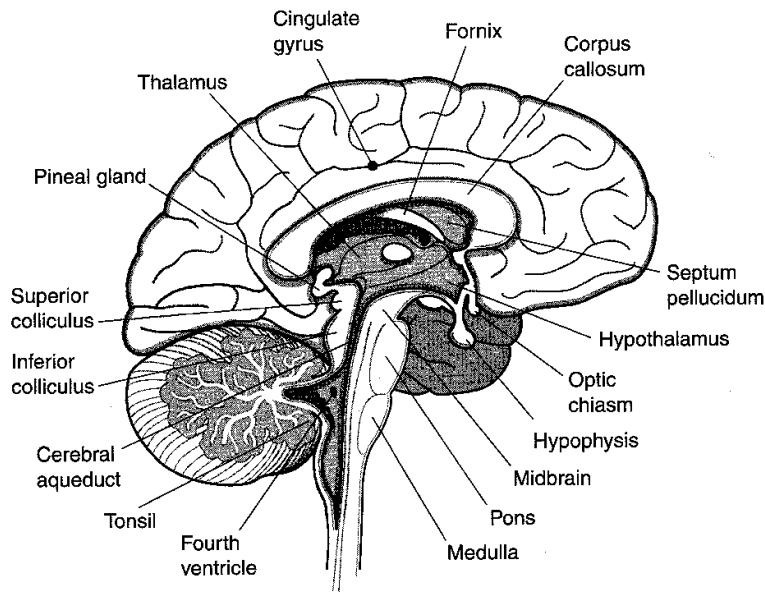


Figure IV-2-4. Brain: Sagittal Section

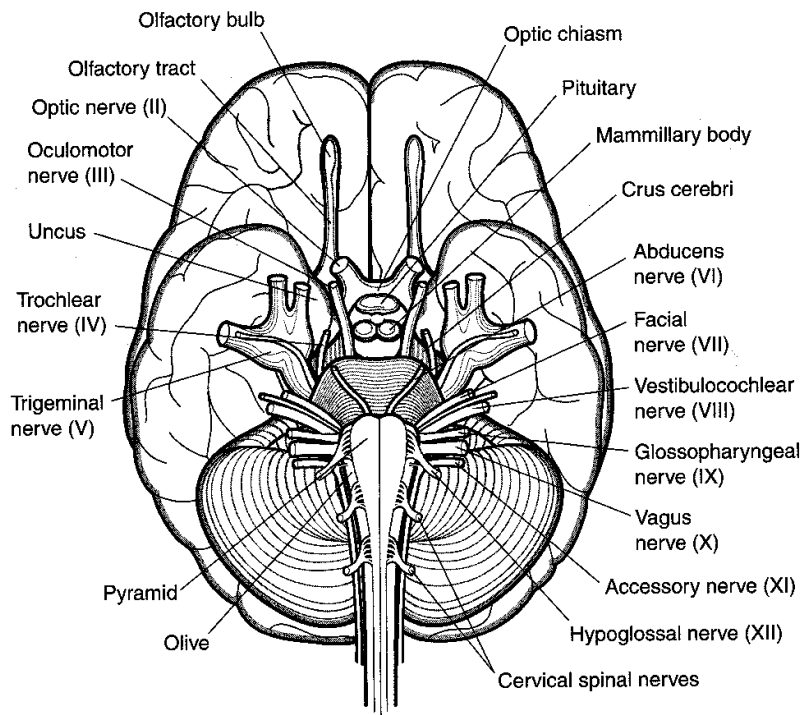


Figure IV-2-5. Brain: Inferior View

Clinical Correlate

Multiple sclerosis is a demyelinating disease, which affects CNS axons including the optic nerve, but not other nerves.

Cellular Elements

Neurons of the neural tube form all CNS interneurons, skeletal motoneurons, and preganglionic autonomic neurons.

Skeletal motoneurons and preganglionic autonomic neurons send their axons out of the CNS in cranial and spinal nerves.

Glial cells derived from the neural tube include ependymal cells, astrocytes, and oligodendrocytes.

Ependymal cells line the ventricles. Cilia on their luminal surfaces move CSF.

Astrocytes control the microenvironment of CNS neurons and participate in the blood-brain barrier. They also guide migrating cortical neurons in development and proliferate in response to CNS injury.

Oligodendrocytes form myelin for axons in the CNS. An individual oligodendrocyte is able to myelinate as many as 50 axons. In the CNS, myelination begins during the fourth month of development and continues into the second decade of life. Microglia are derived from mesoderm, migrate into the CNS, and act as scavengers to devour cellular debris after injury.

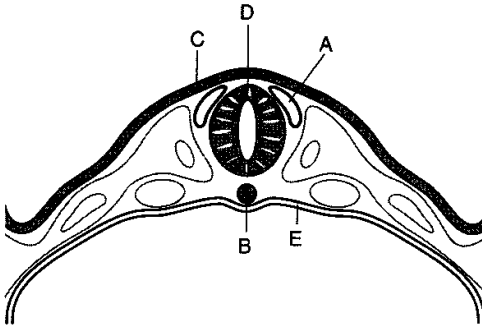
Chapter Summary

The neural tube forms three primary vesicles at its cranial end: (1) the forebrain (prosencephalon), (2) the midbrain, and (3) the hindbrain (rhombencephalon). These primary vesicles then develop into five secondary vesicles that form the adult derivatives of the brain. The telencephalon forms the cerebral hemispheres, the diencephalon forms the thalamus, the mesencephalon forms the midbrain, the metencephalon forms the pons and cerebellum, and the myelencephalon forms the medulla. The remainder of the neural tube forms the spinal cord. The lumen of the neural tube will develop into the ventricular system.

The typical neuron is the multipolar neuron. It consists of a cell body (soma), multiple dendrites, and a single axon. Axons utilize anterograde and retrograde axonal transport to move subcellular elements to and from the soma. Skeletal motor neurons, preganglionic autonomic neurons, and glial cells develop from the neural tube. Glial cells include astrocytes, oligodendrocytes, microglia, and ependymal cells.

Review Questions

1. Ultrasound imaging reveals a fetus that has spina bifida cystica with meningocele. What else might be expected?
 - (A) Higher than predicted levels of alpha-fetoprotein in amniotic fluid
 - (B) Oligohydramnios
 - (C) Club foot
 - (D) Pulmonary hypoplasia
 - (E) A tuft or hair in skin over the defect
2. Polyhydramnios is evident during a pregnancy. What might ultrasound imaging reveal in the fetus?
 - (A) Renal agenesis
 - (B) Spina bifida occulta
 - (C) Anencephaly
 - (D) Pulmonary hypoplasia
 - (E) Urachal cyst
3. A newborn infant presents with several vertebrae that lack spinous processes and a cyst covered by meninges protruding through the defect. What fluid will the cyst contain?
 - (A) Alpha-fetoprotein
 - (B) Venous blood
 - (C) Cerebrospinal fluid
 - (D) Serous fluid
 - (E) Amniotic fluid
4. Nerve terminals that synapse in the adrenal medulla utilize which neurotransmitter?
 - (A) Acetylcholine
 - (B) Epinephrine
 - (C) Norepinephrine
 - (D) Gamma amino butyric acid
 - (E) Dopamine
5. At which of the following sites would a lesion result in Horner syndrome?
 - (A) Cervical spinal cord
 - (B) Celiac ganglion
 - (C) Medial medulla
 - (D) Greater splanchnic nerve
 - (E) Infundibulum

6. Which of the following structures is derived from basal plate of the neural tube?
 - (A) Lateral geniculate body
 - (B) Substantia nigra
 - (C) Dorsal columns
 - (D) Superior colliculus
 - (E) Anterior hypothalamus
7. Which of the following structures is not derived from the diencephalon?
 - (A) Mammillary body
 - (B) Adenohypophysis
 - (C) Pineal gland
 - (D) Retina
 - (E) Subthalamic nucleus
8. In the figure below, a section through a four-week-old embryo, which lettered structure gives rise to hair cells in the inner ear?
 

- (A) A
- (B) B
- (C) C
- (D) D
- (E) E

Answers and Explanations

1. **Answer: A.** Defects in the body wall including all forms of spina cystica present with elevated levels of the alpha-fetoprotein in amniotic fluid. Clubfoot and pulmonary hypoplasia are seen in stillborn infants with oligohydramnios. A tuft or hair in skin over the defect is seen only in spina bifida occulta.
2. **Answer: C.** Anencephaly, the result of a failure of the rostral neuropore to close, will be accompanied by polyhydramnios in utero. With improper formation of rostral end of the brain, the fetus lacks the neural mechanism for swallowing and cannot reduce the amount of amniotic fluid in the amniotic sac.

3. **Answer: C.** The infant has a meningocele, which is a form of spina bifida cystica where the dura and arachnoid layers protrude through the defect. Deep to the arachnoid, an extension of the subarachnoid space in the cyst will contain cerebrospinal fluid.
4. **Answer: A.** All preganglionic sympathetic axons everywhere in the body, including those that synapse with chromaffin cells in the adrenal medulla, utilize acetylcholine as their neurotransmitter.
5. **Answer: A.** A lesion at the level of the cervical spinal cord might affect the descending hypothalamic fibers, which control all preganglionic sympathetic neurons, including those that provide sympathetic innervation to the face, scalp, and orbit.
6. **Answer: B.** The basal plate of the neural tube gives rise to motor neurons in the spinal cord and the brainstem. The only motor structure on the list is the substantia nigra, which is part of the basal ganglia and is found in the midbrain.
7. **Answer: B.** The adenohypophysis is derived from an outgrowth of oral ectoderm called Rathke's pouch. All other choices are derived from the diencephalon of the neural tube.
8. **Answer: C.** Hair cells in the vestibular and cochlear end organs are derived from ectoderm.

The Ventricular System

3

The brain and spinal cord float within a protective bath of cerebrospinal fluid (CSF), which is produced continuously by the choroid plexus within the ventricles of the brain.

Each part of the CNS contains a component of the ventricular system. There are four interconnected ventricles in the brain: two lateral ventricles, a third ventricle, and a fourth ventricle. A lateral ventricle is located deep within each cerebral hemisphere. Each lateral ventricle communicates with the third ventricle via an interventricular foramen (foramen of Monro). The third ventricle is found in the midline within the diencephalon and communicates with the fourth ventricle via the cerebral aqueduct (of Sylvius), which passes through the midbrain. The fourth ventricle is located between the dorsal surfaces of the pons and upper medulla and the ventral surface of the cerebellum. The fourth ventricle is continuous with the central canal of the lower medulla and spinal cord (Figure IV-3-1).

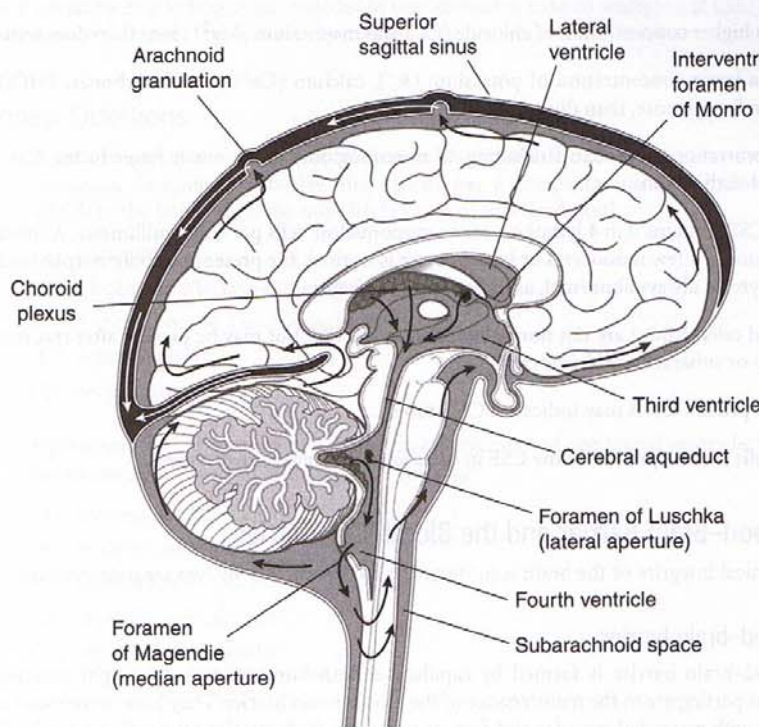


Figure IV-3-1. Sagittal Section of the Brain

Clinical Correlate**CSF Abnormalities**

Hydrocephalus is caused by an excess volume or pressure of CSF, producing ventricular dilatation.

Communicating hydrocephalus is caused by oversecretion of CSF without obstruction in the ventricles or by CSF circulation or absorption problems from the subarachnoid space. Choroid plexus papilloma is a possible cause of oversecretion, a tumor in the subarachnoid space limits circulation, or meningitis may limit absorption into the superior sagittal sinus.

Noncommunicating hydrocephalus is caused by obstruction to the CSF flow inside the ventricular system at a foramen of Monro, in the cerebral aqueduct, or in the fourth ventricle. CSF is prevented from exiting through the foramina of Magendie or Luschka in the fourth ventricle into the subarachnoid space.

Normal pressure hydrocephalus results when CSF is not absorbed by arachnoid villi and the ventricles are enlarged, pressing the cortex against the skull. Patients present with confusion, gait apraxia, and urinary incontinence.

CSF DISTRIBUTION, SECRETION, AND CIRCULATION

CSF fills the subarachnoid space and the ventricles of the brain. The average adult has 90 to 150 mL of total CSF, although 400 to 500 mL is produced daily. Only 25 mL of CSF is found in the ventricles themselves.

Approximately 70% of the CSF is secreted by the choroid plexus, which consists of glomerular tufts of capillaries covered by ependymal cells that project into the ventricles (the remaining 30% represents metabolic water production). The choroid plexus is located in parts of each lateral ventricle, the third ventricle, and the fourth ventricle.

CSF from the lateral ventricles passes through the interventricular foramina of Monro into the third ventricle. From there, CSF flows through the aqueduct of Sylvius into the fourth ventricle. The only sites where CSF can leave the ventricles and enter the subarachnoid space outside the CNS are through three openings in the fourth ventricle, two lateral foramina of Luschka and the median foramen of Magendie.

Within the subarachnoid space, CSF also flows up over the convexity of the brain and around the spinal cord. Almost all CSF returns to the venous system by draining through arachnoid granulations into the superior sagittal dural venous sinus.

Normal CSF is a **clear fluid**, isotonic with serum (290–295 mOsm/L).

The pH of CSF is 7.33 (arterial blood pH, 7.40; venous blood pH, 7.36).

Sodium ion (Na^+) concentration is equal in serum and CSF (≈ 138 mEq/L).

CSF has a higher concentration of chloride (Cl^-) and magnesium (Mg^{2+}) ions than does serum.

CSF has a lower concentration of potassium (K^+), calcium (Ca^{2+}), and bicarbonate (HCO_3^-) ions, as well as glucose, than does serum.

The concentration of protein (including all immunoglobulins) is much lower in the CSF as compared with serum.

Normal CSF contains 0 to 4 lymphocytes or mononuclear cells per cubic millimeter. Although the presence of a few monocytes or lymphocytes is normal, the presence of polymorphonuclear leukocytes is always abnormal, as in bacterial meningitis.

Red blood cells (RBCs) are not normally found in the CSF but may be present after traumatic spinal tap or subarachnoid hemorrhage.

Increased protein levels may indicate a CNS tumor.

Tumor cells may be present in the CSF in cases with meningeal involvement.

The Blood–Brain Barrier and the Blood–CSF Barrier

The chemical integrity of the brain is protected in a different way by two separate systems.

The blood–brain barrier

The blood–brain barrier is formed by capillary endothelium connected by tight junctions. Astrocytes participate in the maintenance of the blood–brain barrier. They have numerous long processes with expanded vascular end-feet, or pedicels, which attach to the walls of capillaries.

Water diffuses across the blood–brain barrier readily, but glucose, the primary energy source of the brain, requires carrier-mediated transport. Active transport systems are capable of pumping weak organic acids, halides, and extracellular K^+ out of the brain against their respective concentration gradients.

The blood–CSF barrier

Tight junctions located along the epithelial cells of the choroid plexus form the blood–CSF barrier. Transport mechanisms are similar to those described for the blood–brain barrier, although the ability of a substance to enter the CSF does not guarantee it will gain access to the brain.

Chapter Summary

The ventricular system is continuous throughout each part of the CNS and contains cerebrospinal fluid (CSF), which provides a protective bath for the brain and spinal cord. The system consists of two lateral ventricles in the cerebral hemispheres, a third ventricle in the midbrain, and a fourth ventricle in the pons and medulla. CSF is produced in the choroid plexuses of the lateral, third, and fourth ventricles. CSF leaves the fourth ventricle through the foramen of Magendie and the foramina of Luschka to enter the subarachnoid space. From the subarachnoid space, CSF returns to the venous system by passing through arachnoid granulations into the superior sagittal dural venous sinus.

Hydrocephalus results from excess volume and pressure of CSF, producing ventricular dilatation. Noncommunicating hydrocephalus is caused by obstruction to CSF flow inside the ventricular system, and communicating hydrocephalus is caused by oversecretion or reduced absorption of CSF.

Review Questions

1. A middle-aged patient develops persistent headaches that are resistant to over-the-counter analgesics. Imaging reveals that the patient has a noncommunicating hydrocephalus. Which of the following is the most likely cause of this condition?
 - (A) Glaucoma
 - (B) Meningitis affecting the arachnoid granulations
 - (C) A thrombosis in the cavernous sinus
 - (D) A pineal tumor
 - (E) An acoustic neuroma
2. Hydrocephalus has resulted in a patient in enlargement of one lateral ventricle. Which of the following is the most likely site of a blockage?
 - (A) Foramen of Luschka
 - (B) Foramen of Monroe
 - (C) Subarachnoid space
 - (D) Superior sagittal sinus
 - (C) Foramen of Magendie

3. The blood-brain barrier is maintained in part by
 - (A) oligodendrocytes
 - (B) astrocytes
 - (C) microglia
 - (D) neural crest cells
 - (E) Schwann cells
4. A communicating hydrocephalus may be caused by
 - (A) ependymoma in the fourth ventricle
 - (B) irritation of arachnoid villi
 - (C) a tumor in the third ventricle
 - (D) blockage of the foramen of Luschka
 - (E) blockage of the foramen of Munro

Answers and Explanations

1. **Answer: D.** A noncommunicating hydrocephalus results from a blockage limiting flow of CSF somewhere inside the ventricular system or its connections. The only choice indicating a blockage site inside the ventricular system is a stenosis of the aqueduct between the third and fourth ventricles caused by a pineal tumor.
2. **Answer: B.** Each lateral ventricle communicates with the third ventricle through a foramen of Munro. Blockage of one foramen of Monroe will result in the enlargement of a single lateral ventricle.
3. **Answer: B.** Foot processes of astrocytes cover the outside of cerebral blood vessels and contribute to the blood-brain barrier.
4. **Answer: B.** A communicating hydrocephalus may be caused by disruption of flow of CSF in the subarachnoid space or by limiting its return to the venous system. The only choice indicating a problem (in this example, absorption of CSF back into the venous system) is meningitis, which might limit flow from of CSF through the arachnoid villi into the superior sagittal dural venous sinus.

The Spinal Cord

4

GENERAL FEATURES

The spinal cord is housed in the vertebral canal. It is continuous with the medulla below the pyramidal decussation and terminates as the conus medullaris at the second lumbar vertebra of the adult. The roots of 31 pairs of spinal nerves arise segmentally from the spinal cord.

There are eight cervical pairs of spinal nerves (C1 through C8). The cervical enlargement (C5 through T1) gives rise to the rootlets that form the brachial plexus, which innervates the upper limbs.

There are 12 thoracic pairs of spinal nerves (T1 through T12). Spinal nerves emanating from thoracic levels innervate most of the trunk.

There are five lumbar pairs of spinal nerves (L1 through L5). The lumbar enlargement (L1 through S2) gives rise to rootlets that form the lumbar and sacral plexuses, which innervate the lower limbs.

There are five sacral pairs of spinal nerves (S1 through S5). Spinal nerves at the sacral level innervate part of the lower limbs and the pelvis.

There is one coccygeal pair of spinal nerves. The cauda equina consists of the dorsal and ventral roots of the lumbar, sacral, and coccygeal spinal nerves.

Inside the spinal cord, gray matter is centrally located and shaped like a butterfly. It contains neuronal cell bodies, their dendrites, and the proximal parts of axons. White matter surrounds the gray matter on all sides. White matter contains bundles of functionally similar axons called tracts or fasciculi, which ascend or descend in the spinal cord (Figures IV-4-1 and IV-4-2).

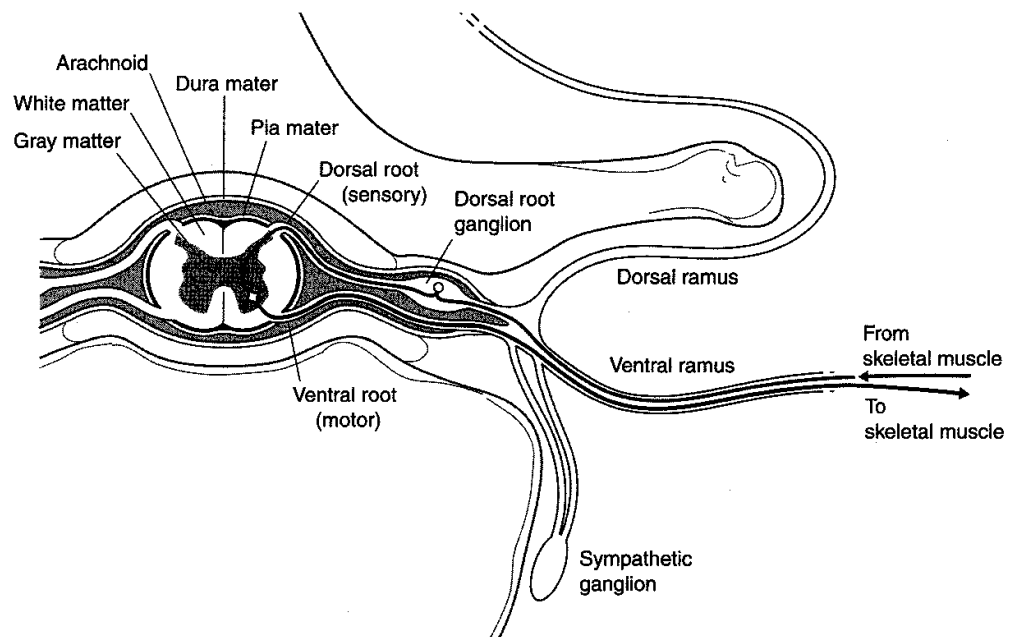


Figure IV-4-1. Cross-Section of Spinal Cord and the Components of a Spinal Nerve

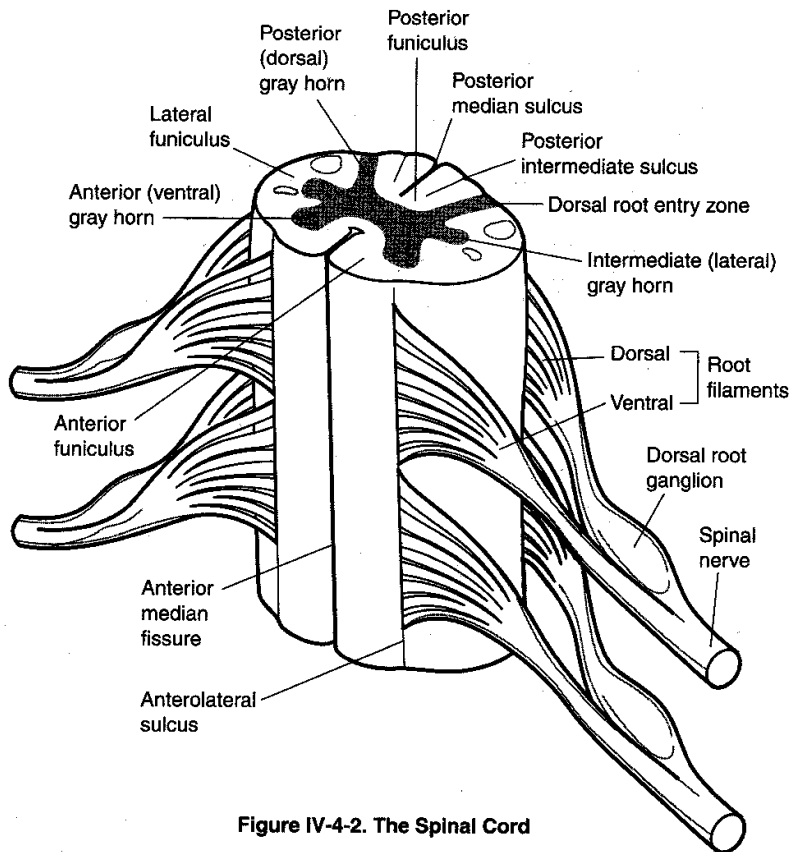


Figure IV-4-2. The Spinal Cord

The gray matter is organized into a dorsal horn, a ventral horn, and an intermediate zone.

Dorsal Horn

The dorsal horn is dominated by neurons that respond to sensory stimulation. All incoming sensory fibers in spinal nerves enter the dorsolateral part of the cord adjacent to the dorsal horn in a dorsal root. Neurons in the dorsal horn project to higher levels of the CNS to carry sensations to the brain stem, cerebral cortex, or cerebellum. Other dorsal horn neurons participate in reflexes.

Ventral Horn

The ventral horn contains alpha and gamma motoneurons. The alpha motoneurons innervate skeletal muscle (extrafusal fibers) by way of a specialized synapse at a neuromuscular junction, and the gamma motoneurons innervate the contractile intrafusal muscle fibers of the muscle spindle. Within the ventral horn, alpha and gamma motoneurons that innervate flexors are dorsal to those that innervate extensors. Alpha and gamma motoneurons that innervate the proximal musculature are medial to those that innervate the distal musculature. Axons of alpha and gamma motoneurons and axons of preganglionic autonomic neurons leave the cord by way of a ventral root.

Intermediate Zone

The intermediate zone of the spinal cord from T1 to L2 contains preganglionic sympathetic neuron cell bodies and Clarke nucleus, which sends unconscious proprioception to the cerebellum.

NEURAL SYSTEMS

There are three major neural systems in the spinal cord that use neurons in the gray matter and tracts or fasciculi of axons in the white matter. These neural systems have components that can be found at all levels of the CNS from the cerebral cortex to the tip of the spinal cord. An understanding of these three neural systems is essential to understanding the effects of lesions in the spinal cord, brain stem, and at higher levels of the CNS.

Motor Systems

Voluntary innervation of skeletal muscle

Upper and Lower Motoneurons

Two motoneurons, an upper motoneuron and a lower motoneuron, together form the basic neural circuit involved in the voluntary contraction of skeletal muscle everywhere in the body. The lower motoneurons are found in the ventral horn of the spinal cord and in cranial nerve nuclei in the brain stem. Axons of lower motoneurons of spinal nerves exit in a ventral root, then join the spinal nerve to course in one of its branches to reach and synapse directly at a neuromuscular junction in skeletal muscle. Axons of lower motoneurons in the brain stem exit in a cranial nerve.

To initiate a voluntary contraction of skeletal muscle, a lower motoneuron must be innervated by an upper motoneuron (Figure IV-4-3). The cell bodies of upper motoneurons are found in the brain stem and cerebral cortex, and their axons descend into the spinal cord in a tract to reach and synapse on lower motoneurons, or on interneurons, which then synapse on lower motoneurons. At a minimum, therefore, to initiate a voluntary contraction of skeletal muscle, two motoneurons, an upper and a lower, must be involved. The upper motoneuron innervates the lower motoneuron, and the lower motoneuron innervates the skeletal muscle.

The cell bodies of upper motoneurons are found in the red nucleus, reticular formation, and lateral vestibular nuclei of the brain stem, but the most important location of upper motoneurons is in the cerebral cortex. Axons of these cortical neurons course in the corticospinal tract.

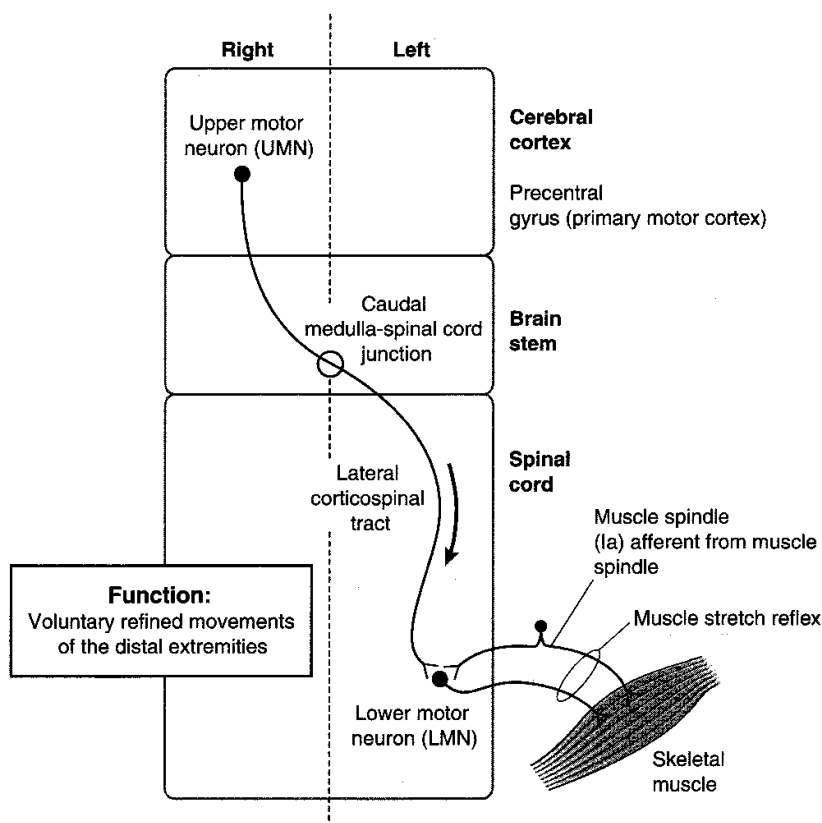


Figure IV-4-3. Corticospinal Tract: Descending Motor Pathway

Corticospinal Tract

The primary motor cortex, located in the precentral gyrus of the frontal lobe, and the premotor area, located immediately anterior to the primary motor cortex, give rise to about 60% of the fibers of the corticospinal tract (Figure IV-4-4). Primary and secondary somatosensory cortical areas located in the parietal lobe give rise to about 40% of the fibers of the corticospinal tract.

Fibers in the corticospinal tract leave the cerebral cortex in the internal capsule, which carries all axons in and out of the cortex. Corticospinal fibers then descend through the length of the brain stem in the ventral portion of the midbrain, pons, and medulla.

In the lower medulla, 80 to 90% of corticospinal fibers cross at the decussation of the pyramids and continue in the contralateral spinal cord as the lateral corticospinal tract. The lateral corticospinal tract descends the full length of the cord in the lateral part of the white matter. As it descends, axons leave the tract and enter the gray matter of the ventral horn to synapse on lower motoneurons.

Clinical Correlate

Lesions of the Corticospinal Tract

The crossing or decussation of axons of the corticospinal tract at the medulla/spinal cord junction has significant clinical implications. If lesions of the corticospinal tract occur above the pyramidal decussation, a weakness is seen in muscles on the contralateral side of the body; lesions below this level produce an ipsilateral muscle weakness. In contrast to upper motoneurons, the cell bodies of lower motoneurons are ipsilateral to the skeletal muscles that their axons innervate. A lesion to any part of a lower motoneuron will result in an ipsilateral muscle weakness at the level of the lesion.

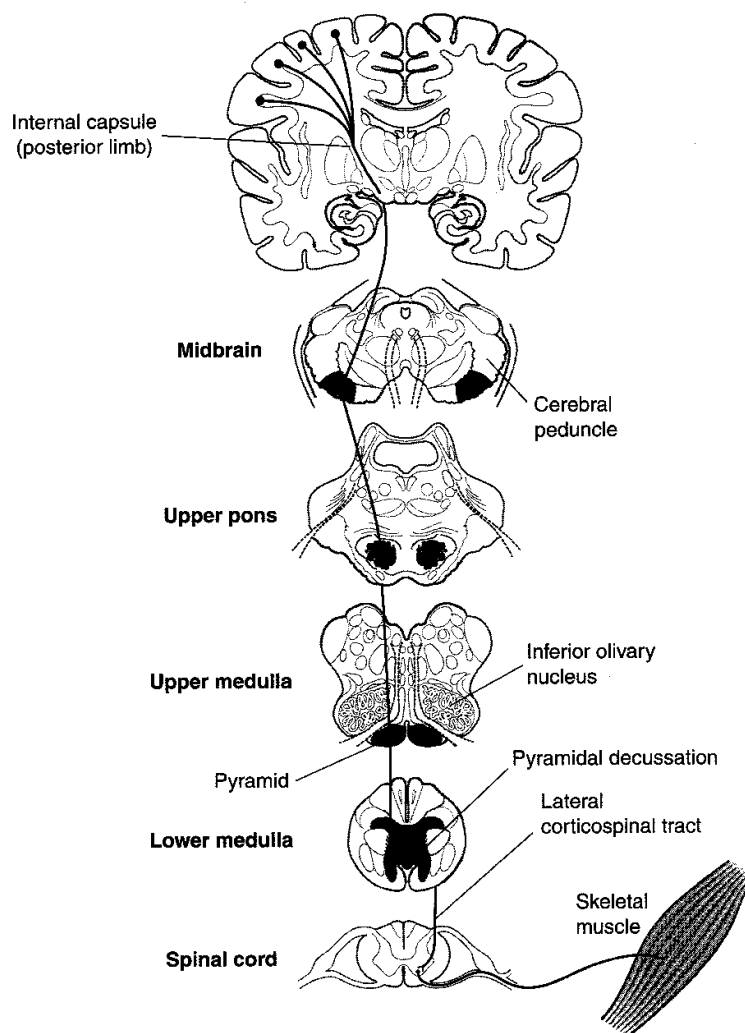


Figure IV-4-4. Corticospinal Tract

Clinical Correlate

Lesions to Ia afferent fibers or lower motoneurons produce areflexia.

Important muscle stretch reflexes to test are:

knee (L_2-L_4)

ankle (S_1)

biceps (C_5-C_6)

triceps (C_7-C_8)

Reflex innervation of skeletal muscle

A reflex is initiated by a stimulus of a sensory neuron, which in turn innervates a motoneuron and produces a motor response. In reflexes involving skeletal muscles, the sensory stimulus arises from receptors in the muscle, and the motor response is a contraction or relaxation of one or more skeletal muscles. In the spinal cord, lower motoneurons form the specific motor component of skeletal muscle reflexes. Upper motoneurons provide descending control over the reflexes.

Both alpha and gamma motoneurons are lower motoneurons that participate in reflexes. Alpha motoneurons are large cells in the ventral horn that innervate extrafusal muscle fibers. A single alpha motoneuron innervates a group of muscle fibers, which constitutes a motor unit, the basic unit for voluntary, postural, and reflex activity. Gamma motoneurons supply intrafusal muscle fibers, which are modified skeletal muscle fibers. The intrafusal muscle fibers form the muscle spindle, which acts as a sensory receptor in skeletal muscle stretch reflexes.

Both ends of the muscle spindle are connected in parallel with the extrafusal fibers, so these receptors monitor the length and rate of change in length of extrafusal fibers. Muscles involved with fine movements contain a greater density of spindles than those used in coarse movements.

Muscle stretch (myotatic) reflex

The muscle stretch (myotatic) reflex is the stereotyped contraction of a muscle in response to stretch of that muscle. The stretch reflex is a basic reflex that occurs in all muscles and is the primary mechanism for regulating muscle tone. Muscle tone is the tension present in all resting muscle. Tension is controlled by the stretch reflexes.

The best example of a muscle stretch or deep tendon reflex is the knee-jerk reflex. Tapping the patellar ligament stretches the quadriceps muscle and its muscle spindles. Stretch of the spindles activates sensory endings (Ia afferents), and afferent impulses are transmitted to the cord. Some impulses from stretch receptors carried by Ia fibers monosynaptically stimulate the alpha motoneurons that supply the quadriceps. This causes contraction of the muscle and a sudden extension of the leg at the knee. Afferent impulses simultaneously inhibit antagonist muscles through interneurons (in this case, hamstrings).

Inverse muscle stretch reflex

The inverse muscle stretch reflex monitors muscle tension. This reflex uses Golgi tendon organs (GTOs). These are encapsulated groups of nerve endings that terminate between collagenous tendon fibers at the junction of muscle and tendon. GTOs are oriented in series with the extrafusal fibers and respond to increases in force or tension generated in that muscle. Increases in force in a muscle increase the firing rate of Ib afferent neurons that innervate the GTOs, which, in turn, polysynaptically facilitate antagonists and inhibit agonist muscles.

Muscle tone and reflex activity can be influenced by gamma motoneurons and by upper motoneurons. Gamma motoneurons directly innervate the muscle spindles and regulate their sensitivity to stretch. Upper motoneurons innervate gamma motoneurons and also influence the sensitivity of muscle spindles to stretch. Stimulation of gamma motoneurons causes intrafusal muscle fibers located at the pole of each muscle spindle to contract, which activates alpha motoneurons, causing an increase in muscle tone.

Flexor withdrawal reflex

The flexion withdrawal reflex is a protective reflex in which a stimulus (usually painful) causes withdrawal of the stimulated limb. This reflex may be accompanied by a crossed extension reflex in which the contralateral limb is extended to help support the body.

Clinical Correlate

Upper Motoneuron Versus Lower Motoneuron Muscle Lesions

A fundamental requirement of interpreting the cause of motor weakness in neuroscience cases is the ability to distinguish between a lesion of an upper versus a lower motoneuron. Because a lesion to either an upper or a lower motoneuron produces a weakness in the ability to voluntarily contract skeletal muscles, the key to distinguishing an upper from a lower motoneuron lesion will be the condition of reflexes of the affected muscles (Figure IV-4-5).

A lesion of any part of a lower motoneuron will result in hypoactive muscle stretch reflexes and a reduction in muscle tone (hypotonicity) because lower motoneurons form the motor component of the reflex. Therefore, lower motoneuron lesions result in a paresis combined with suppressed or absent muscle stretch reflexes. An early sign of a lower motoneuron lesion is muscle fasciculations, which are twitches or contractions of groups of muscle fibers, that may produce a movement visible on the skin. Later, lower motoneuron lesions produce fibrillations, which are invisible 1- to 5-ms potentials, detected with electromyography. Muscles denervated by a lower motoneuron lesion undergo pronounced wasting or atrophy. The constellation of lower motoneuron lesion signs combining paresis with suppressed or absent reflexes, fasciculations, and atrophy is known as a **flaccid paralysis**. With few exceptions, lower motoneuron (LMN) lesions produce a flaccid paralysis ipsilateral and at the level of the lesion.

Neurologically, upper motoneurons including the corticospinal tract have a net overall inhibitory effect on muscle stretch reflexes. As a result, upper motoneuron lesions combine paresis of skeletal muscles with muscle stretch or deep tendon reflexes that are hyperactive or hypertonic. The hypertonia may be seen as decorticate rigidity (i.e., postural flexion of the arm and extension of the leg) or decerebrate rigidity (i.e., postural extension of the arm and leg) depending on the location of the lesion. Lesions above the midbrain produce decorticate rigidity; lesions below the midbrain produce decerebrate rigidity. Upper motoneuron lesions result in atrophy of weakened muscles only as a result of disuse, because these muscles can still be contracted by stimulating muscle stretch reflexes.

Upper motoneuron lesions are also accompanied by reversal of cutaneous reflexes, which normally yield a flexor motor response. The best known of the altered flexor reflexes is the **Babinski reflex**. The test for the Babinski reflex is performed by stroking the lateral surface of the sole of the foot with a slightly painful stimulus. Normally, there is plantar flexion of the big toe. With a lesion of the corticospinal tract, the Babinski reflex is present, which is characterized by extension of the great toe and fanning of the other toes. Two other flexor reflexes, the abdominal and cremasteric, are also lost in upper motoneuron lesions. The constellation of upper motoneuron lesion signs combining paresis with increases or hyperactive reflexes, disuse atrophy of skeletal muscles, and altered cutaneous reflexes is known as a spastic paresis.

In contrast to lower motoneuron lesions, lesions of upper motoneurons result in a **spastic paresis** that is ipsilateral or contralateral and below the site of the lesion. Upper motoneuron lesions anywhere in the spinal cord will result in an ipsilateral spastic paresis below the level of the lesion. Upper motoneuron lesions between the cerebral cortex and the medulla above the decussation of the pyramids will result in a contralateral spastic paresis below the level of the lesion.

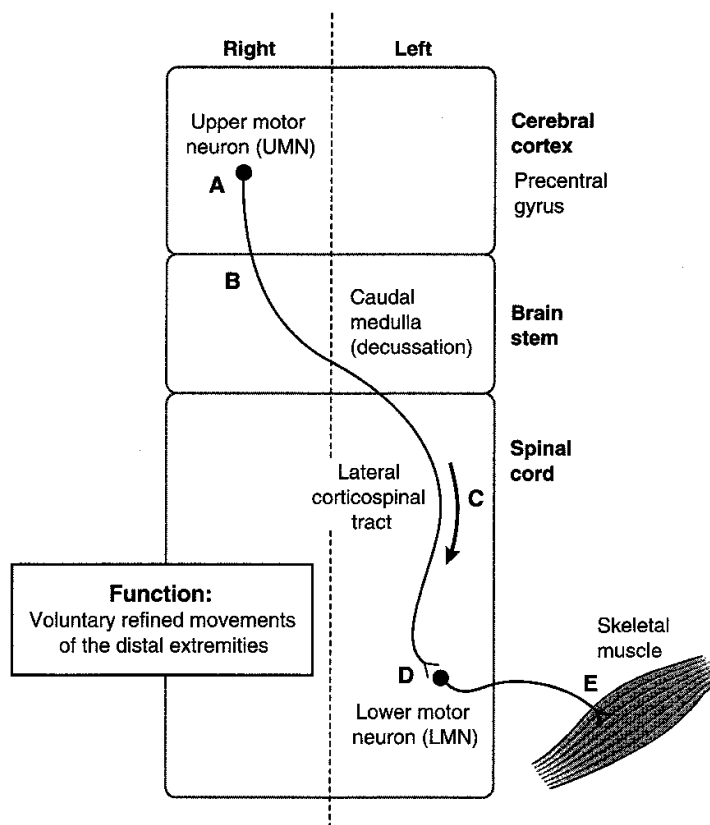


Figure IV-4-5. Upper Versus Lower Motor Neuron Lesions

Table IV-4-1. Upper Versus Lower Motoneuron Lesions

Upper Motor Neuron Lesion*	Lower Motor Neuron Lesion†
Spastic paralysis	Flaccid paralysis
Hyperreflexia	Areflexia
Babinski sign present	No Babinski
Increased muscle tone	Fasciculations
Muscle weakness	Decreased muscle tone
Disuse atrophy of muscles	Atrophy of muscle(s)
Decreased speed of voluntary movements	Loss of voluntary movements
Large area of the body involved	Small area of body affected

*Deficits contralateral or ipsilateral and below the lesion.

†Deficits ipsilateral and at the level of lesion.

Sensory Systems

Two sensory systems, the dorsal column–medial lemniscal system and the anterolateral (spinothalamic) system, use three neurons to convey sensory information from peripheral sensory receptors to conscious levels of cerebral cortex. In both systems, the first sensory neuron that innervates a sensory receptor has a cell body in the dorsal root ganglion and carries the information into the spinal cord in the dorsal root of a spinal nerve. The first neuron synapses with a second neuron in the brain stem or the spinal cord, and the axon of the second neuron crosses the midline and is carried in a tract in the CNS. The axon of the second neuron then synapses on a third neuron that is in the thalamus. The axon of the third neuron projects to primary somatosensory cortex (Figure IV-4-6).

Note

Legend to Figure

- 1 = first-order neuron in sensory ganglion
- 2 = second-order neuron in CNS (axon always crosses midline)
- 3 = third-order neuron in thalamus

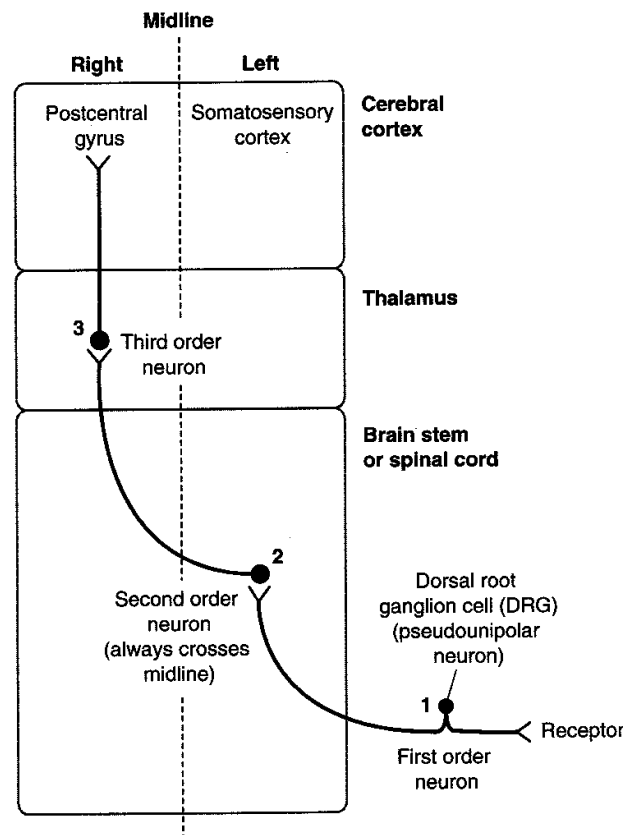


Figure IV-4-6. General Sensory Pathways

Dorsal column–medial lemniscal system

The dorsal column–medial lemniscal system carries sensory information for discriminative touch, joint position (kinesthetic or conscious proprioceptive) sense, vibratory, and pressure sensations from the trunk and limbs (Figures IV-4-7 and IV-4-8). The primary afferent neurons in this system have their cell bodies in the dorsal root ganglia, enter the cord via class II or A-beta

dorsal root fibers, and then coalesce in the fasciculus gracilis or fasciculus cuneatus in the dorsal funiculus of the spinal cord. The fasciculus gracilis, found at all spinal cord levels, is situated closest to the midline and carries input from the lower extremities and lower trunk. The fasciculus cuneatus, found only at upper thoracic and cervical spinal cord levels, is lateral to the fasciculus gracilis and carries input from the upper extremities and upper trunk. These two fasciculi form the dorsal columns of the spinal cord that carry the central processes of dorsal root ganglion cells and ascend the length of the spinal cord to reach their second neurons in the lower part of the medulla.

In the lower part of the medulla, fibers in the fasciculus gracilis and fasciculus cuneatus synapse with the second neurons found in the nucleus gracilis and nucleus cuneatus, respectively. Cells in these medullary nuclei give rise to fibers that cross the midline as internal arcuate fibers and ascend through the brain stem in the medial lemniscus. Fibers of the medial lemniscus terminate on cells of the ventral posterolateral (VPL) nucleus of the thalamus. From the VPL nucleus, thalamocortical fibers project to the primary somesthetic (somatosensory) area of the postcentral gyrus, located in the most anterior portion of the parietal lobe.

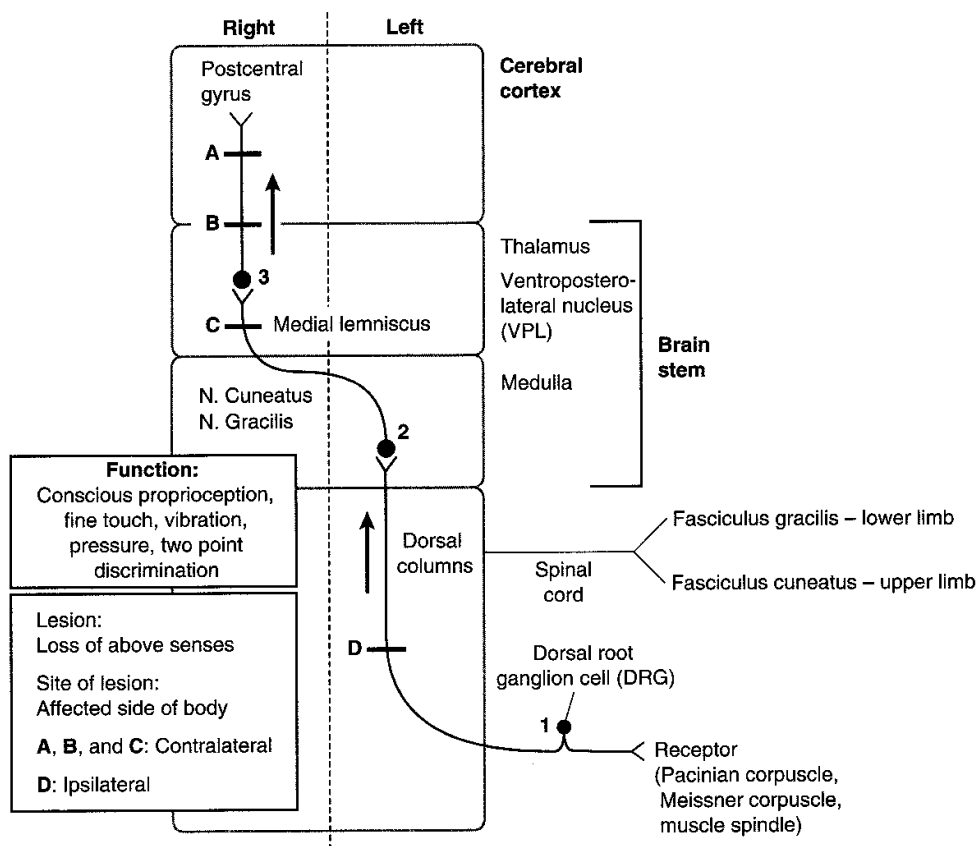


Figure IV-4-7. Dorsal Column Pathway-Medial Lemniscal System

Clinical Correlate

Lesions of the dorsal columns result in a loss of joint position sensation, vibratory and pressure sensations, and two-point discrimination. There is loss of the ability to identify the characteristics of an object, called astereognosis (e.g., size, consistency, form, shape), using only the sense of touch. Typically, dorsal column–medial lemniscal lesions are evaluated by testing vibratory sense using a 128-Hz tuning fork. Romberg sign is also used to distinguish between lesions of the dorsal columns and the midline (vermal area) of the cerebellum.

Romberg sign is tested by asking the patients to place their feet together. If there is a marked deterioration of posture (if the patient sways) with the eyes closed, this is a positive Romberg sign, suggesting that the lesion is in the dorsal columns (or dorsal roots of spinal nerves). With the eyes open, interruption of proprioceptive input carried by the dorsal columns can be compensated for by visual input to the cerebellum. Therefore, if the patient has balance problems and tends to sway with their eyes open, this is indicative of cerebellar damage.

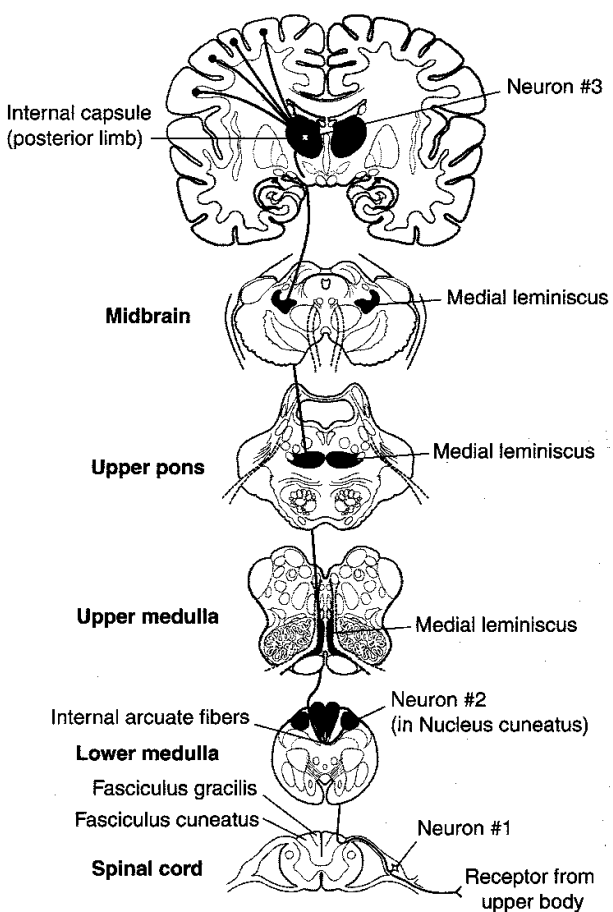


Figure IV-4-8. Dorsal Column Pathway-Medial Lemniscal System

Anterolateral (spinothalamic tract) system

The anterolateral system carries pain, temperature, and crude touch sensations from the extremities and trunk.

Pain and temperature fibers have cell bodies in the dorsal root ganglia and enter the spinal cord via A-delta and C or class III and class IV dorsal root fibers (Figure IV-4-9). Their fibers ascend or descend a couple of segments in the dorsolateral tract of Lissauer before entering and synapsing in the dorsal horn. The second neuron cell bodies are located in the dorsal horn gray matter. Axons from these cells cross in the ventral white commissure just below the central canal of the spinal cord and coalesce to form the spinothalamic tract in the ventral part of the lateral funiculus. The spinothalamic tract courses through the entire length of the spinal cord and the brain stem to terminate in the VPL nucleus of the thalamus. Cells in the VPL nucleus send pain and temperature information to the primary somatosensory cortex in the postcentral gyrus.

Clinical Correlate

Because the pain and temperature information crosses almost as soon as it enters the spinal cord, any unilateral **lesion of the spinothalamic tract** in the spinal cord or brain stem will result in a contralateral loss of pain and temperature. This is an extremely useful clinical sign because it means that if a patient presents with analgesia on one side of the trunk or limbs, the location of the lesion must be on the contralateral side of the spinal cord or brain stem. The analgesia begins 1 to 2 segments below the lesion and includes everything below that level (Figure IV-4-10).

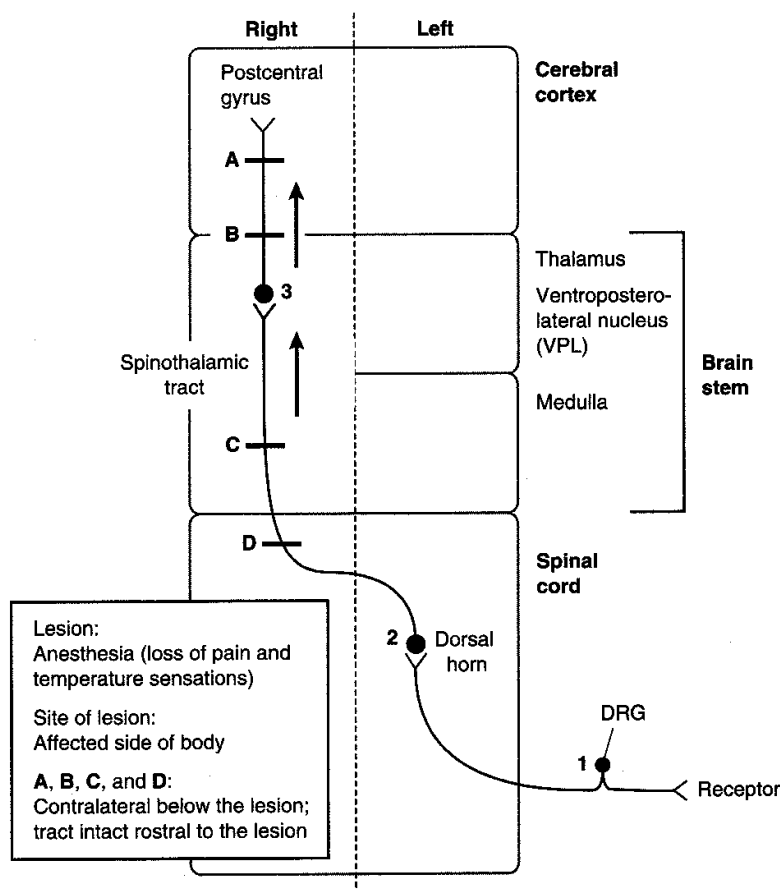


Figure IV-4-9. Spinothalamic Tract (Anterolateral System)

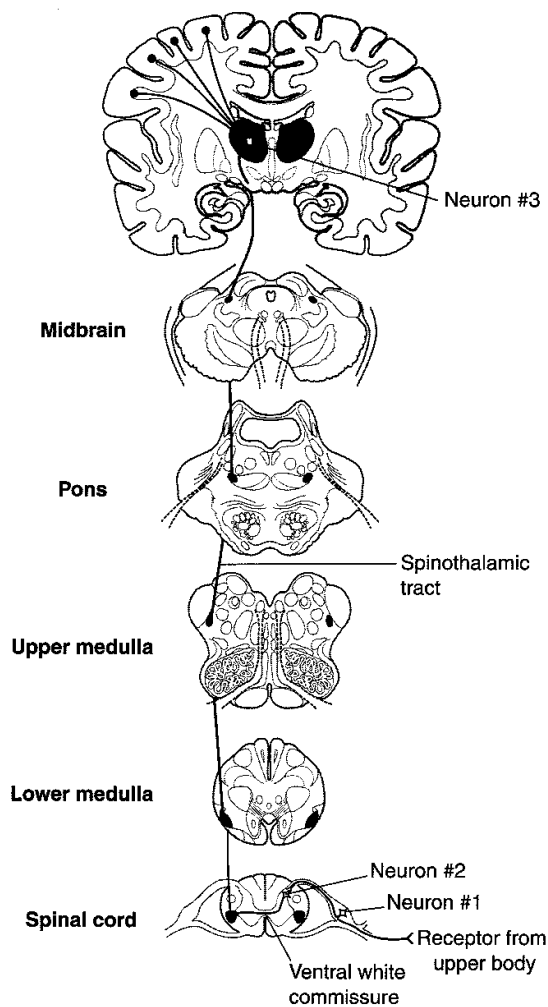


Figure IV-4-10. Lesions of the Spinothalamic Tract (Anterolateral System)

Spinocerebellar pathways

The spinocerebellar tracts mainly carry unconscious proprioceptive input from muscle spindles and GTOs to the cerebellum, where this information is used to help monitor and modulate movements. There are two major spinocerebellar pathways:

- Dorsal spinocerebellar tract—carries input from the lower extremities and lower trunk.
- Cuneocerebellar tract—carries proprioceptive input to the cerebellum from the upper extremities and upper trunk.

The cell bodies of the dorsal spinocerebellar tract are found in Clarke's nucleus, which is situated in the spinal cord from T1 to L2. The cell bodies of the cuneocerebellar tract are found in the medulla in the external cuneate nucleus (Figure IV-4-11).

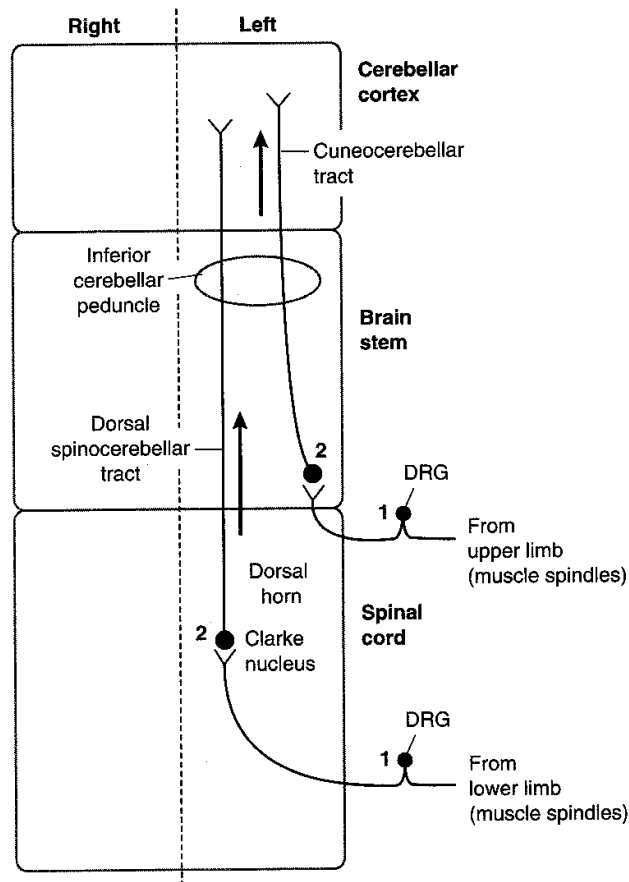


Figure IV-4-11. Spino-cerebellar Tracts

Clinical Correlate

Lesions that affect only the spino-cerebellar tracts are uncommon, but there are a group of hereditary diseases in which degeneration of spino-cerebellar pathways is a prominent feature. The most common of these is Friedreich ataxia, which is usually inherited as an autosomal recessive trait. The spino-cerebellar tracts, dorsal columns, corticospinal tracts, and cerebellum may be involved. Ataxia of gait is the most common initial symptom of this disease.

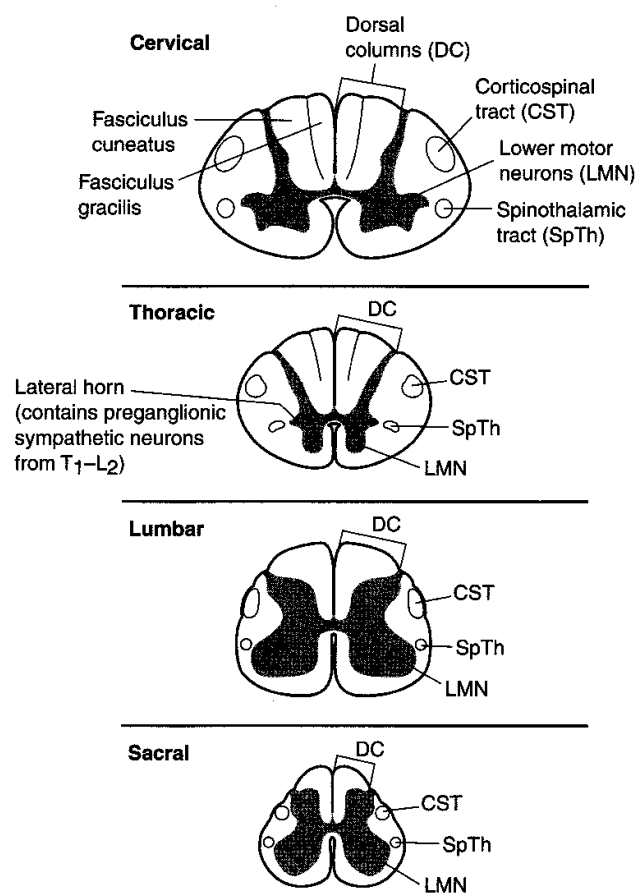


Figure IV-4-12. Spinal Cord: Levels

Spinal Cord Lesions

Figure IV-4-13 provides an overview of the spinal cord tracts, and Figures IV-4-14 and IV-4-15 show lesions at different sites, which are discussed below.

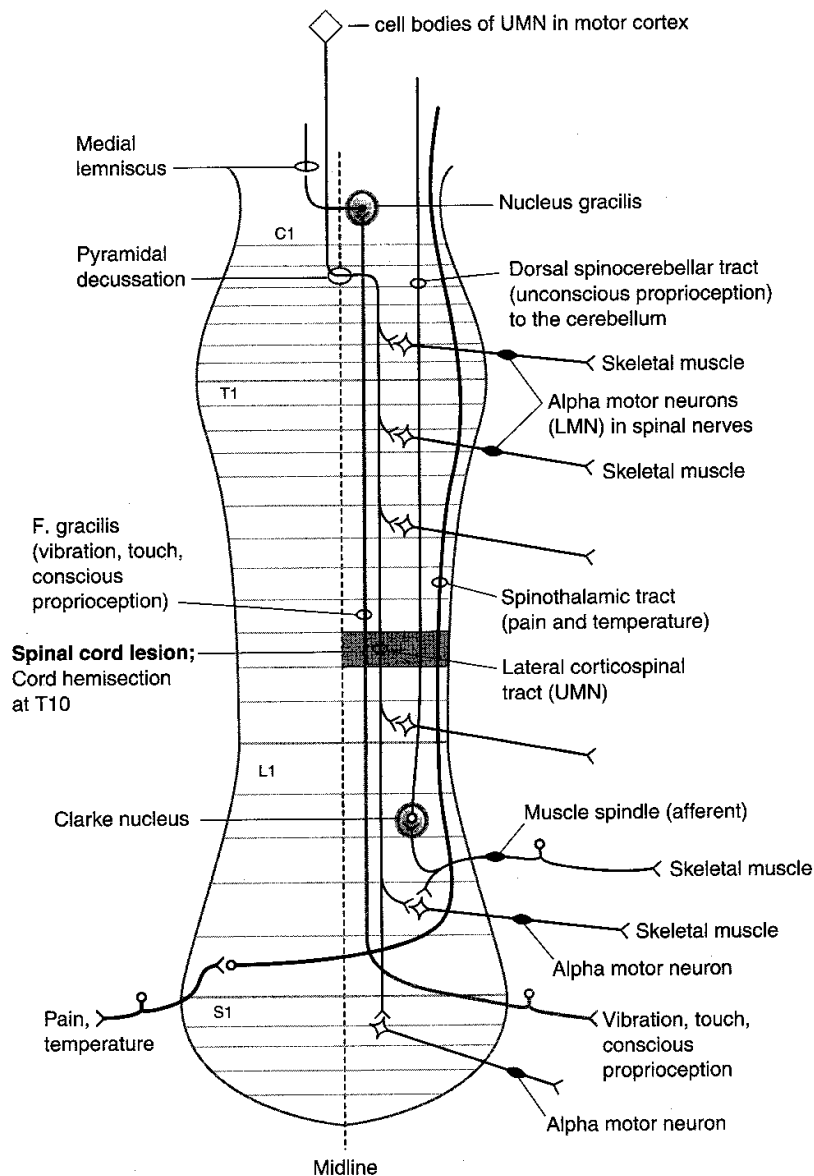
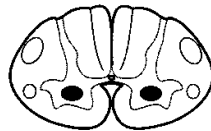

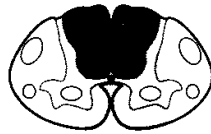
Figure IV-4-13. An Overview of the Spinal Cord Pathways

Brown-Séquard syndrome

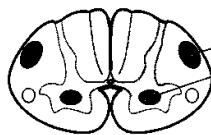Hemisection of the cord results in a lesion of each of the three main neural systems: the principal upper motoneuron pathway of the corticospinal tract, one or both dorsal columns, and the spinothalamic tract. The hallmark of a lesion to these three long tracts is that the patient presents with two ipsilateral signs and one contralateral sign. Lesion of the corticospinal tract results in an ipsilateral spastic paresis below the level of the injury. Lesion to the fasciculus gracilis or cuneatus results in an ipsilateral loss of joint position sense, tactile discrimination, and vibratory sensations below the lesion. Lesion of the spinothalamic tract results in a contralateral loss of pain and temperature sensation starting one or two segments below the level of the lesion. At the level of the lesion, there will be an ipsilateral loss of all sensation, including touch modalities as well as pain and temperature, and an ipsilateral flaccid paralysis in muscles supplied by the injured spinal cord segments (Figure IV-4-15).

**Polio**

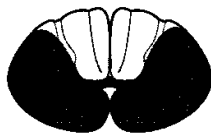
- a. Flaccid paralysis
- b. Muscle atrophy
- c. Fasciculations
- d. Areflexive

**Tabes dorsalis**

- a. Bilateral dorsal column signs below lesions
- b. Associated with late stage syphilis, plus
Romberg sign: sways with eyes closed
Argyle Robertson pupils

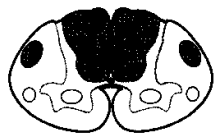
**Amyotrophic lateral sclerosis (ALS)**

- a. Progressive spinal muscular atrophy (ventral horn)
- b. Primary lateral sclerosis (corticospinal tract)
 - Spastic paralysis in lower limbs
 - Increased tone and reflexes
 - Flaccid paralysis in upper limbs

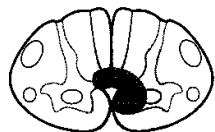
**Anterior spinal artery (ASA) occlusion**

- a. DC spared
- b. All else bilateral signs

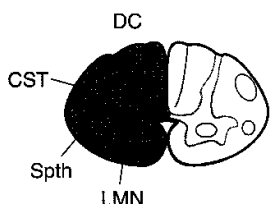
Figure IV-4-14. Lesions of the Spinal Cord I

**Subacute combined degeneration**

- a. Vitamin B12, pernicious anemia; (AIDS)
- b. Demyelination of the:
 - Dorsal columns
 - Spinocerebellar tracts
 - Corticospinal tracts (CST)

**Syringomyelia**

- a. Cavitation of the cord (usually cervical)
- b. Bilateral loss of pain and temperature at the level of the lesion
- c. As the disease progresses, there is muscle weakness; eventually flaccid paralysis and atrophy of the upper limb muscles due to destruction of ventral horn cells

**Hemisection: Brown-Séquard syndrome**

- a. DC: Ipsilateral loss of position and vibratory senses at and below level of the lesion
- b. Spinothalamic tract: Contralateral loss of P&T below lesion and bilateral loss at the level of the lesion
- c. CST: Ipsilateral paresis below the level of the lesion
- d. LMN: Flaccid paralysis at the level of the lesion
- e. Descending hypothalamics: Ipsilateral Horner syndrome (if cord lesion is above T₁)
 - Facial hemianhydrosis
 - Ptosis (slight)
 - Miosis

Figure IV-4-15. Lesions of the Spinal Cord II**Poliomyelitis**

Poliomyelitis results from a relatively selective destruction of lower motoneurons in the ventral horn by the poliovirus. The disease causes a flaccid paralysis of muscles with the accompanying hyporeflexia and hypotonicity. Some patients may recover most function, whereas others progress to muscle atrophy and permanent disability (Figure IV-4-14).

Amyotrophic lateral sclerosis

Amyotrophic lateral sclerosis (ALS, Lou Gehrig disease) is a relatively pure motor system disease that affects both upper and lower motoneurons. The disease typically begins at cervical levels of the cord and progresses either up or down the cord. Patients present with bilateral flaccid weakness of the upper limbs and bilateral spastic weakness of the lower limbs. Lower motoneurons in the brain stem nuclei may be involved later (Figure IV-4-14).

Occlusion of the anterior spinal artery

This artery lies in the anterior median sulcus of the spinal cord. Occlusion of the anterior spinal artery interrupts blood supply to the ventrolateral parts of the cord, including the corticospinal tracts and spinothalamic tracts. Below the level of the lesion, the patient exhibits a bilateral spastic paresis and a bilateral loss of pain and temperature (Figure IV-4-14).

Clinical Correlate

Syringomyelia may present with hydrocephalus and Arnold Chiari II malformation.

Clinical Correlate

Tabes patients present with paresthesias (pins and needles sensations), pain, polyuria, Romberg sign.

Clinical Correlate

Subacute combined degeneration patients present with paresthesias, bilateral spastic weakness, Babinski signs, and antibodies to intrinsic factor.

Syringomyelia

Syringomyelia is a disease characterized by progressive cavitation of the central canal, usually in the cervical spinal cord but may involve other cord regions or the medulla. Early in the disease, there is a bilateral loss of pain and temperature sensation in the hands and forearms as a result of the destruction of spinothalamic fibers crossing in the anterior white commissure. When the cavitation expands, lower motoneurons in the ventral horns are compressed, resulting in bilateral flaccid paralysis of upper limb muscles. A late manifestation of cavitation is **Horner syndrome**, which occurs as a result of involvement of descending hypothalamic fibers innervating preganglionic sympathetic neurons in the T1 through T4 cord segments. Horner syndrome consists of miosis (pupillary constriction), ptosis (drooping eyelids), and anhidrosis (lack of sweating) in the face (Figure IV-4-15).

Tabes dorsalis

Tabes dorsalis is one possible manifestation of neurosyphilis. It is caused by bilateral degeneration of the dorsal roots and secondary degeneration of the dorsal columns. There may be impaired vibration and position sense, astereognosis, paroxysmal pains, and ataxia, as well as diminished stretch reflexes or incontinence. Owing to the loss of proprioceptive pathways, individuals with tabes dorsalis are unsure of where the ground is and walk with a characteristic and almost diagnostic "high step stride" (Figure IV-4-14). Tabetic patients may also present with abnormal pupillary responses (Argyll Robertson pupils).

Subacute combined degeneration

Subacute combined degeneration is seen most commonly in cases of vitamin B12 deficiency, sometimes related to pernicious anemia. The disease is characterized by patchy losses of myelin in the dorsal columns and lateral corticospinal tracts, resulting in a bilateral spastic paresis and a bilateral alteration of touch, vibration, and pressure sensations below the lesion sites (Figure IV-4-15). Myelin in both CNS and PNS is affected.

Multiple sclerosis

Multiple sclerosis is a demyelinating disease of the CNS in which certain myelinated pathways, such as the optic nerve, dorsal columns, corticospinal tract, and medial longitudinal fasciculus (MLF) are affected. The illness is characterized by episodes of focal neurologic deficits that are separated in place and in time. The disease course is characterized by exacerbations and remissions. Patients may develop the following symptoms:

- Weakness or spastic paresis occurring from damage to the corticospinal tract.
- Monocular blindness or scotoma resulting from optic nerve damage.
- Paresthesias occurring from damage to the dorsal columns.
- Ataxia resulting from damage to cerebellar connections in the brain stem, dorsal columns, or spinocerebellar tracts.
- Diplopia most often occurring after damage to the MLF, a brain stem pathway connecting the cranial nerve nuclei that control extraocular movement with each other and with the cerebellum, vestibular nuclei, and cervical proprioceptive input.

Chapter Summary

The spinal cord is internally divided into 31 segments that give rise to 31 pairs of spinal nerves: 8 cervical, 12 thoracic, 5 lumbar, 5 sacral, and 1 coccygeal. Each segment is divided into an inner gray matter containing neuron cell bodies. The ventral horn of gray contains alpha and gamma motoneurons, the intermediate horn contains preganglionic neurons and Clarke nucleus, and the dorsal horn contains sensory neurons. The outer covering of the spinal cord is the white matter containing ascending and descending axons that form tracts located within funiculi.

Motor Pathways

The corticospinal tract is involved in the voluntary contraction of skeletal muscle, especially in the distal extremities. This tract consists of two neurons, an upper motor neuron, and a lower motor neuron. Most of the upper motor neurons have their cell bodies in the primary motor cortex and premotor cortex of the frontal lobe. These axons leave the cerebral hemispheres through the posterior limb of the internal capsule and descend medially through the midbrain, pons, and medulla. In the medulla, 80–90% of these fibers decussate at the pyramids and then descend in the spinal cord as the lateral corticospinal tract in the lateral funiculus of the white matter. These enter the ventral horn of gray at each cord segment and synapse upon the lower motor neurons. Axons of the lower neurons (final common pathway) leave via the ventral root of the spinal nerves and innervate the skeletal muscles. Lesions above the decussations (in the brain stem or cortex) produce contralateral deficits, and lesions below the decussations (in the spinal cord) produce ipsilateral findings. Patients with upper motor neuron lesions present with spastic paralysis, hyperreflexia, hypertonia, and a positive Babinski. Lower motor neuron lesions present with flaccid paralysis, areflexia, atonia, muscle atrophy, and fasciculations.

Sensory Pathways

Most sensory systems use three neurons to project sensory modalities to the cerebral cortex. The first neuron (primary afferent neuron) has its cell body in the dorsal root ganglion of the spinal nerve. This axon enters the spinal cord and either synapses in the spinal cord or the brain stem. The second neuron will decussate and project to the thalamus. The third neuron then projects from the thalamus to the somatosensory cortex of the parietal lobe.

Dorsal Column–Medial Lemniscal System

This pathway conducts sensory information for touch, proprioception, vibration, and pressure. The primary afferent neurons of this pathway have their cell bodies in the dorsal root ganglia. Their axons enter the spinal cord and ascend in the dorsal columns of the white matter as the fasciculus gracilis (from lower limb) or the fasciculus cuneatus (from upper limb). They synapse with the second neuron in the same named nuclei in the lower medulla. Axons of the second neuron decussate (internal arcuate fibers) and ascend the midline of the brain stem in the medial lemniscus to reach the VPL nucleus of the thalamus. The third neuron then projects through the posterior limb of the internal capsule to the somatosensory cortex. Lesions above the decussation (in the brain stem or cortex) produce contralateral loss of joint position, vibration, and touch, whereas lesions below decussations (in the spinal cord) produce ipsilateral deficits below the level of the lesion. A positive Romberg test indicates lesions of the dorsal columns.

(Continued)

Chapter Summary (continued)**Anterolateral (Spinothalamic) Tract**

The spinothalamic pathway carries pain and temperature sensations. The first neuron fibers enter the spinal cord and synapse in the dorsal horn with the second neurons. The first neuron often ascends or descends one or two segments before they synapse. The second neuron axons then decussate (ventral white commissure) and ascend the spinal cord as the spinothalamic tract in the lateral funiculus of the white matter. The spinothalamic tract ascends the lateral aspect of the brain stem and synapses in the VPL nucleus of the thalamus where the third neuron projects to the cortex. All lesions of the spinothalamic tract in the spinal cord, brain stem, or cortex produce contralateral loss of pain and temperature below the lesion. Note that a central cord lesion at the spinal canal (syringomyelia) produces bilateral loss of pain and temperature at the level of the lesion.

Lesions of the spinal cord that involve the above mentioned tracts include poliomyelitis, tabes dorsalis, amyotrophic lateral sclerosis, anterior spinal artery occlusion, subacute combined degeneration, syringomyelia, and Brown-Sequard syndrome.

Review Questions

1. Which of the following cells are found in the white matter of the spinal cord?
 - (A) Schwann cells
 - (B) Ependymal cells
 - (C) Oligodendrocytes
 - (D) Pyramidal cells
 - (E) Alpha motor neurons
2. A 50-year-old man begins to have problems typing on his computer keyboard and holding a hammer in his right hand. In the next month he realizes that his right hand and right arm are weaker than the left, but a few weeks later the left arm and hand also become weak. Two months later, his right hand can be held only in a claw like position, there is atrophy of the hypothenar eminence, and the right thumb is held in a position of extension. The patient also notices that he has trouble getting up from a chair and that he walks stiffly. Tendon reflexes in both lower limbs are elevated, and there are bilateral Babinski responses in both feet. The biceps and triceps tendon reflexes are virtually absent. Upon examination you note that he has nasal and slurred speech, there are wormlike fasciculations on the tongue, and there is visible twitching of muscle fibers beneath the skin of both forearms and chest. The patient has no pain or loss of sensation, and he maintains that bladder function is normal. The patient demonstrates signs consistent with
 - (A) Guillain Barré syndrome
 - (B) subacute combined degeneration
 - (C) multiple sclerosis
 - (D) myasthenia gravis
 - (E) amyotrophic lateral sclerosis

3. Cutting a ventral root of a spinal nerve may result in
 - (A) atrophy of skeletal muscle innervated by that nerve as a result of disuse
 - (B) increased activity of the muscle stretch reflexes involving denervated muscles
 - (C) a Babinski sign
 - (D) degeneration of dorsal root ganglion cells at the same segmental spinal cord level
 - (E) regeneration of the cut axons because their myelin sheaths are formed by Schwann cells

4. Your patient has fallen off of a ladder. A neurological exam conducted 2 weeks after the accident reveals that the individual has a complete hemisection of the *right* side of the spinal cord at the level of the T10 segment. In this case, the patient is most likely to exhibit
 - (A) a pain and temperature loss to in both the upper and lower limb on the left
 - (B) altered touch sensations from the right lower limb
 - (C) hyperactive stretch reflexes in the lower limb on the left
 - (D) absent stretch reflexes in the right upper limb
 - (E) Horner syndrome

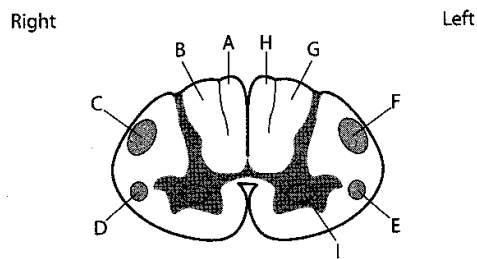
5. A 55-year-old man develops pain in both legs, altered sensation of touch in the soles of both feet, and increased tendencies to urinate, particularly at night. When he walks to the bus stop in the morning, his gait is unsteady. What else might you expect to observe in the patient?
 - (A) Pupils that accommodate but do not react to light
 - (B) Amyotrophic lateral sclerosis
 - (C) Hyperactive stretch reflexes
 - (D) Subacute combined degeneration
 - (E) Horner syndrome

6. Your patient, a 25-year-old woman, tells you that 6 months ago she had balance problems and numbness in her right hand, but the numbness subsided after a week or so. She is a secretary and thinks that she may have carpal tunnel syndrome. Today, you note that she has decreased vibratory sense in both the right hand and right leg, decreased pinprick sensation in the right lower limb, and that both of her right limbs are weak. Analysis of cerebrospinal fluid following lumbar tap reveals heterogeneous immunoglobulin G staining with oligoclonal banding. Which of the following might also be seen in the patient?
 - (A) Bilateral ptosis
 - (B) Blurry vision
 - (C) Claw hand
 - (D) Tic douloureux
 - (E) Foot drop

7. Your patient complains that he cannot tell the difference between hot or cold water when he washes his hands, and he also notes that both upper limbs tire easily. You note that the thenar eminences of both hands of the patient appear wasted. You suspect that the patient has
 - (A) amyotrophic lateral sclerosis
 - (B) tabes dorsalis
 - (C) poliomyelitis
 - (D) syringomyelia
 - (E) a Pancoast tumor
8. Your patient has lost the ability to discriminate between two points presented simultaneously to the skin of the left hand. Your neurological evaluation is most likely to reveal a lesion in the
 - (A) fasciculus cuneatus on the right side of the spinal cord at C2
 - (B) medial lemniscus on the right side of the pons
 - (C) dorsal columns on the right side of the spinal cord at T5
 - (D) fasciculus gracilis on the right side of the medulla
 - (E) spinothalamic tract left side of the spinal cord at C2
9. In a section through the T10 segment of the spinal cord, which of the following will *not* be present?
 - (A) Preganglionic sympathetic neurons
 - (B) Fasciculus gracilis
 - (C) Lower motor neurons
 - (D) Fasciculus cuneatus
 - (E) Dorsal spinocerebellar tract
10. A patient presents with muscle weakness, fasciculations, and suppressed reflexes. The most likely location of the lesion is in the
 - (A) dorsal horn
 - (B) ventral horn
 - (C) lateral horn
 - (D) dorsal column
 - (E) ventral white commissure
11. Contraction of the quadriceps femoris muscle and extension of the leg at the knee in the patellar tendon reflex is initiated by stimulation of
 - (A) Golgi tendon organs
 - (B) muscle spindles
 - (C) upper motor neurons
 - (D) Ia dorsal root fibers
 - (E) brain stem neurons

12. During repair of an aortic aneurysm, a patient awakes with neurological signs, which the neurologist attributed to temporary occlusion of the feeder arteries to the anterior spinal artery. Which of the following neurologic signs would you be least likely to observe in the patient?
- (A) Bilateral loss of pain and temperature below the site of the occlusion
 - (B) Bilateral weakness below the site of the occlusion
 - (C) Bilateral loss of vibratory sense below the site of the occlusion
 - (D) Increased urinary frequency
 - (E) Bilateral Babinski signs

Questions 13 and 14 are based on the following figure.



13. The figure above indicates several labeled structures in a section through the spinal cord. Which letter indicates a neural structure that would be affected in poliomyelitis?
- (A) A
 - (B) B
 - (C) C
 - (D) D
 - (E) E
 - (F) F
 - (G) G
 - (H) H
 - (I) I
14. The figure above indicates several labeled structures in a section through the spinal cord. Which of the following labeled structures carries pain and temperature sensations from the right leg?
- (A) A
 - (B) B
 - (C) C
 - (D) D
 - (E) E
 - (F) F
 - (G) G
 - (H) H
 - (I) I

15. In the same figure from question 14, if the structure at "G" were cut, where would you expect to find degenerating neuronal cell bodies as a result of retrograde chromatolysis?
(A) Nucleus cuneatus
(B) Dorsal root ganglia
(C) Ventral posterior lateral nucleus of the thalamus
(D) Postcentral gyrus
(E) Dorsal horn of the spinal cord gray matter

Answers and Explanations

1. **Answer: C.** Oligodendrocytes form myelin for all myelinated axons inside the CNS, including tracts in the white matter of the spinal cord.
2. **Answer: E.** The patient has a combination of upper and lower motor neurons signs characteristic of ALS. In this case, the ALS has affected the cervical enlargement first resulting in lower motor neurons signs in the upper limbs and upper motor signs in the lower limbs.
3. **Answer: E.** A ventral root contains axons of lower motor neurons and is found in the peripheral nervous system. Here all myelin is formed by Schwann cells, which promote regeneration of cut axons. Choices A, B, and C are signs attributable to upper motor neuron disease, and central and peripheral processes of dorsal root ganglion cells course in dorsal roots and would not be affected.
4. **Answer: B.** A hemisection of the spinal cord (Brown Sequard syndrome) produces an ipsilateral paresthesia below the lesion, in this case, below the T10 dermatome including the lower limb. Pain and temperature would be lost only in the lower limb on the left, hyperactive stretch reflexes would be seen in the right limb, absent stretch reflexes would be seen only at the level of the lesion and could not be demonstrated in this case, and Horner syndrome might seen in hemisections in the cervical cord.
5. **Answer: A.** The patient presents with the three "Ps" of tabes dorsalis; pain, paresthesia, and polyuria, characteristic of tabes dorsalis and caused by late-stage neurosyphilis. These patients may also present with Argyll Robertson pupils, which accommodate but do not constrict in response to light.
6. **Answer: B.** The optic nerves are the only nerves that have myelin formed by oligodendrocytes that degenerate in multiple sclerosis. MS is indicated by the neurological deficits separated by space and time and the oligoclonal banding. All of the other choices indicate deficits seen in lesions of cranial or spinal nerves, which have myelin formed by Schwann cells.
7. **Answer: D.** The patient has a bilateral loss of pain and temperature sensations in the hands at the level of the lesion and bilateral lower motor neuron weakness in the hand also at the level of the lesion, indicative of a syrinx at the level of the cervical enlargement of the cord. The bilateral pain and temperature loss is seen first, and as the syrinx expands, the lower motor neurons to muscles in the same regions are affected.
8. **Answer: B.** A lesion of the second-order crossed axons in the medial lemniscus on the right is the only choice that would result in a loss of two-point discrimination in the left hand.
9. **Answer: D.** The fasciculus cuneatus begins at about the T5 segment of the spinal cord.

10. **Answer: B.** The signs are all indicative of a lower motor neuron lesion involving alpha motor neurons situated in the ventral horn of the spinal cord.
11. **Answer: B.** Stimulation of muscle spindles in the quadriceps femoris muscle results in a reflex contraction of that muscle and extension of the leg at the knee.
12. **Answer: C.** The anterior spinal artery supplies the ventrolateral two thirds of the cord; only the dorsal columns, which convey sensations other than pain and temperature, will be unaffected.
13. **Answer: I.** The location of lower motor neurons affected in polio.
14. **Answer: E.** The spinothalamic tract on the left carries pain and temperature sensations from the right leg.
15. **Answer: B.** Axons in the fasciculus cuneatus have their cell bodies in dorsal root ganglia.

The Brain Stem

5

The brain stem is divisible into three continuous parts: the midbrain, the pons, and the medulla. The midbrain is most rostral and begins just below the diencephalon. The pons is in the middle and is overlain by the cerebellum.

The medulla is caudal to the pons and is continuous with the spinal cord.

The brain stem is the home of the origins or sites of termination of fibers in 9 of the 12 cranial nerves (CN).

CRANIAL NERVES

Two cranial nerves, the oculomotor and trochlear (CN III and IV), arise from the midbrain (Figure IV-5-1).

Four cranial nerves, the trigeminal, abducens, facial, and vestibulocochlear nerves (CN V, VI, VII, and VIII), enter or exit from the pons.

Three cranial nerves, the glossopharyngeal, vagus, and hypoglossal nerves (CN IX, X, and XII), enter or exit from the medulla. Fibers of the accessory nerve arise from the cervical spinal cord.

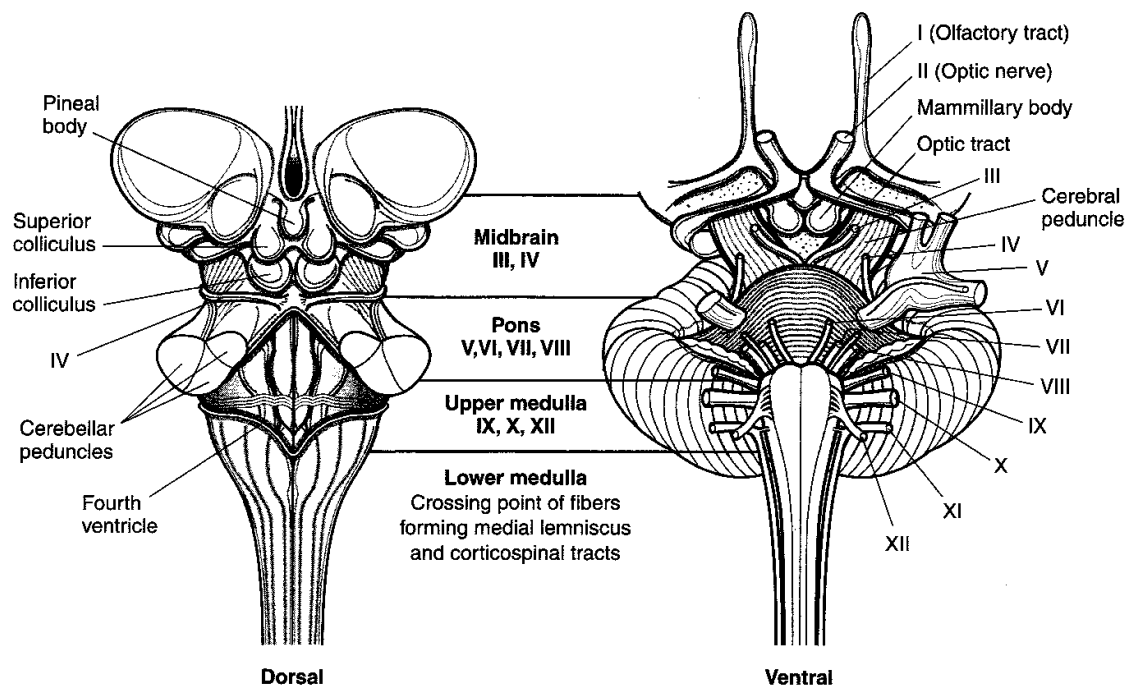


Figure IV-5-1. Brainstem and Cranial Nerve: Surface Anatomy

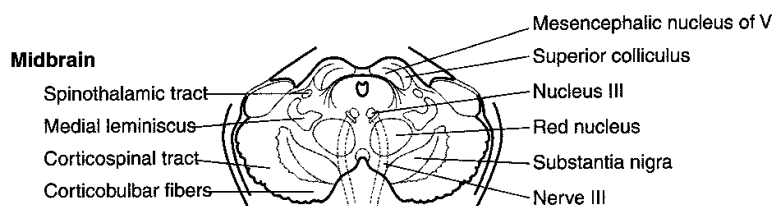
Clinical Correlate

Pineal tumors result in Parinaud syndrome: paralysis of upward gaze and noncommunicating hydrocephalus.

Clinical Correlate

Schwannomas typically affect VIII nerve fibers seen in neurofibromatosis type 2.

Afferent fibers of cranial nerves enter the CNS and terminate in relation to aggregates of neurons in sensory nuclei. Motor or efferent components of cranial nerves arise from motor nuclei. All motor and sensory nuclei that contribute fibers to cranial nerves are organized in a series of discontinuous columns according to the functional component that they contain. Motor nuclei are situated medially, closest to the midline, and sensory nuclei are situated lateral to the motor nuclei. A cranial nerve nucleus or nerve will be found at virtually every transverse sectional level of the brain stem (Figure IV-5-2).



Note

The descending hypothalamic fibers course with the spinothalamic tract.

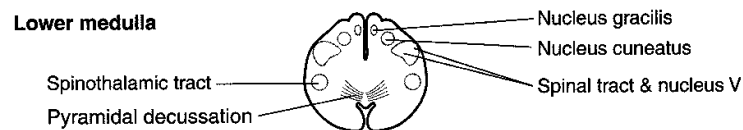
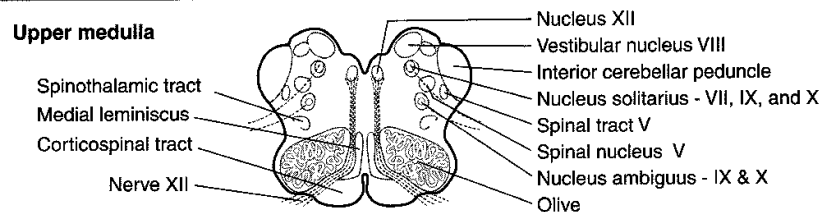
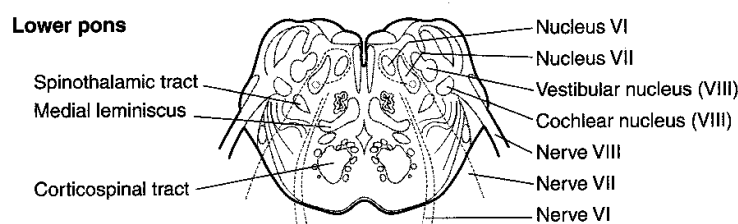
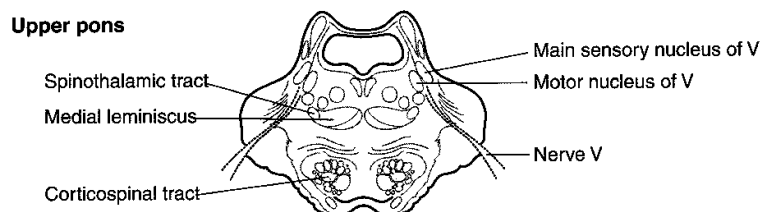


Figure IV-5-2. Brainstem: Cranial nerves and Identification of Sections

Table IV-5-1. Cranial Nerves: Functional Features

CN	Name	Type	Function	Lesions Result in	Exits/Enters Cranium	Region Innervated
I	Olfactory	Sensory	Smells	Anosmia	Cribriform plate	Nasal cavity
II	Optic	Sensory	Sees (optic nerve is really a tract of CNS with meninges)	Visual field deficits (anopia) Loss of light reflex with III Only nerve to be affected by MS (swinging flashlight test)	Optic canal	Orbit
VIII	Vestibulocochlear	Sensory	Hears Linear acceleration (gravity) Angular acceleration (head turning)	Sensorineural hearing loss Loss of balance, nystagmus	Internal auditory meatus	Inner ear
III	Oculomotor	Motor	Moves eyeball in all directions Adduction (medial rectus) most important action Constricts pupil (sphincter pupillae) Accommodates (ciliary muscle) Raises eyelid (levator palpebrae superioris)	Diplopia—external strabismus Loss of parallel gaze Dilated pupil, loss of light reflex with II Loss of near response Ptosis	Superior orbital fissure	Orbit
IV	Trochlear	Motor	Superior oblique—depresses eye	Weakness looking down with adducted eye Trouble going down stairs Head tilts away from lesioned side	Superior orbital fissure	Orbit
VI	Abducens	Motor	Intorts Lateral rectus—abducts eyeball	Diplopia—internal strabismus Loss of parallel gaze, "pseudoptosis"	Superior orbital fissure	Orbit
XI	Accessory	Motor	Turns head to opposite side (sternocleidomastoid) Elevates and rotates scapula (trapezius)	Weakness turning head to opposite side Shoulder droop	Jugular foramen	Neck
XII	Hypoglossal	Motor	Moves tongue (styloglossus, hyoglossus, genioglossus, and intrinsic—palatoglossus is by X)	Tongue pointing toward same (affected) side on protrusion	Hypoglossal canal	Tongue
V	Trigeminal	Mixed	General sensation (touch, pain, temperature) of forehead/scalp/cornea	V1—loss of general sensation in skin of forehead/scalp Loss of blink reflex with VII	V1—superior orbital fissure (ophthalmic division)	Orbit and scalp
	Maxillary (V2)		General sensation of palate, nasal cavity, maxillary face, maxillary teeth	V2—loss of general sensation in skin over maxilla, maxillary teeth	V2—foramen rotundum (maxillary division)	Pterygopalatine fossa (leave by openings to face, oral and nasal cavity) Infratemporal Fossa
	Mandibular (V3)		General sensation of anterior two thirds of tongue, mandibular face, mandibular teeth Motor to muscles of mastication (temporalis, masseter, medial and lateral pterygoids) and anterior belly of digastric, mylohyoid, tensor tympani, tensor palati	V3—loss of general sensation in skin over mandible, mandibular teeth, tongue, weakness in chewing Jaw deviation toward weak side Trigeminal neuralgia—intractable pain in V2 or V3 territory	V3—foramen ovale (mandibular division)	

(Continued)

Table IV-5-1. Cranial Nerves: Functional Features (*continued*)

CN Name	Type	Function	Lesions Result in	Exits/Enters Cranium	Region Innervated
VII Facial	Mixed	To muscles of facial expression, posterior belly of digastric, stylohyoid, stapedius Tastes anterior two thirds of tongue/palate Salivates (submandibular, sublingual glands) Tears (lacrimal gland) Makes mucus (nasal and palatine glands)	Corner of mouth droops, can't close eye, can't wrinkle forehead, loss of blink reflex, hyperacusis, Bell palsy—lesion of nerve in facial canal Alteration or loss of taste (ageusia)	Internal auditory meatus	Face, nasal, and oral cavity (branches leave skull in stylomastoid foramen, petrotympanic fissure, or hiatus of facial canal)
IX Glossopharyngeal	Mixed	Senses pharynx, carotid sinus/body Salivates (parotid gland) Tastes and senses posterior one third of tongue Motor to one muscle—stylopharyngeus	Loss of gag reflex with X	Jugular foramen	Neck Pharynx/tongue
X Vagus	Mixed	To muscles of palate and pharynx for swallowing except tensor palati (V) and stylopharyngeus (IX) To all muscles of larynx (phonates) Senses larynx and laryngopharynx Senses larynx and GI tract To GI tract smooth muscle and glands in foregut and midgut	Nasal speech, nasal regurgitation Dysphagia, palate droop Uvula pointing away from affected side Hoarseness/fixated vocal cord Loss of gag reflex with IX Loss of cough reflex	Jugular foramen	Neck Pharynx/larynx Thorax, abdomen
Sympathetics to head	Motor	Raises eyelid (superior tarsal muscle) Dilates pupil Innervates sweat glands of face and scalp Constricts blood vessels in head	Horner syndrome: eyelid droop (ptosis), constricted pupil (miosis), loss of sweating (anhidrosis), flushed face	Carotid canal on internal carotid artery	Orbit, face, scalp

NEURAL SYSTEMS

Each of the following five ascending or descending neural tracts, fibers, or fasciculi course through the brain stem and will be found at every transverse sectional level.

Medial Lemniscus

The medial lemniscus (ML) contains the axons from cell bodies found in the dorsal column nuclei (gracilis and cuneatus) in the caudal medulla and represents the second neuron in the pathway to the thalamus and cortex for discriminative touch, vibration, pressure, and conscious proprioception. The axons in the ML cross the midline of the medulla immediately after emerging from the dorsal column nuclei. Lesions in the ML, in any part of the brain stem, result in a loss of discriminative touch, vibration, pressure, and conscious proprioception from the **contralateral** side of the body.

Spinothalamic Tract (Part of Anterolateral System)

The spinothalamic tract has its cells of origin in the spinal cord and represents the crossed axons of the second neuron in the pathway conveying pain and temperature to the thalamus and cortex. Lesions of the spinothalamic tract, in any part of the brain stem, results in a loss of pain and temperature sensations from the **contralateral** side of the body.

Corticospinal Tract

The corticospinal tract controls the activity of lower motoneurons, and interneuron pools for lower motoneurons course through the brain stem on their way to the spinal cord. Lesions of this tract produce a spastic paresis in skeletal muscles of the body **contralateral** to the lesion site in the brain stem.

Descending Hypothalamic Fibers

The descending hypothalamic fibers arise in the hypothalamus and course without crossing through the brain stem to terminate on preganglionic sympathetic neurons in the spinal cord. Lesions of this pathway produce an ipsilateral **Horner syndrome**. Horner syndrome consists of miosis (pupillary constriction), ptosis (drooping eyelid), and anhidrosis (lack of sweating) in the face ipsilateral to the side of the lesion.

Descending hypothalamic fibers course with the spinothalamic fibers in the lateral part of the brain stem. Therefore, brain stem lesions producing Horner syndrome may also result in a **contralateral** loss of pain and temperature sensations from the limbs and body.

Medial Longitudinal Fasciculus

The medial longitudinal fasciculus is a fiber bundle interconnecting centers for horizontal gaze, the vestibular nuclei, and the nerve nuclei of CN III, IV, and VI, which innervate skeletal muscles that move the eyeball. This fiber bundle courses close to the dorsal midline of the brain stem and also contains vestibulospinal fibers, which course through the medulla to the spinal cord. Lesions of the fasciculus produce internuclear ophthalmoplegia and disrupt the vestibulo-ocular reflex.

MEDULLA

In the caudal medulla, two of the neural systems, the corticospinal and dorsal column–medial lemniscal pathways, send axons across the midline. The nucleus gracilis and nucleus cuneatus give rise to axons that decussate in the caudal medulla (the crossing axons are the internal arcuate fibers), which then form and ascend in the medial lemniscus.

The corticospinal (pyramidal) tracts, which are contained in the pyramids, course ventromedially through the medulla. Most of these fibers decussate in the caudal medulla just below the crossing of axons from the dorsal column nuclei, and then travel down the spinal cord as the (lateral) corticospinal tract.

The olives are located lateral to the pyramids in the rostral two thirds of the medulla. The olives contain the convoluted inferior olivary nuclei. The olivary nuclei send climbing (olivocerebellar) fibers into the cerebellum through the inferior cerebellar peduncle. The olives are a key distinguishing feature of the medulla.

The spinothalamic tract and the descending hypothalamic fibers course together in the lateral part of the medulla below the inferior cerebellar peduncle and near the spinal nucleus and tract of CN V.

Cranial Nerve Nuclei

Spinal nucleus of V

The spinal nucleus of the trigeminal nerve (CN V) is located in a position analogous to the dorsal horn of the spinal cord. The spinal tract of the trigeminal nerve lies just lateral to this nucleus and extends from the upper cervical cord (C2) to the point of entry of the fifth cranial nerve in the pons. Central processes from cells in the trigeminal ganglion conveying pain and temperature sensations from the face enter the brain stem in the rostral pons but descend in the spinal tract of CN V and synapse on cells in the spinal nucleus (Figure IV-5-3).

Solitary nucleus

The solitary nucleus receives the axons of all general and special visceral afferent fibers carried into the CNS by CN VII, IX, and X. These include both taste and visceral sensations carried by these cranial nerves. Taste and visceral sensory neurons all have their cell bodies in ganglia associated with CN VII, IX, and X outside the CNS.

Nucleus ambiguus

The nucleus ambiguus is a column of large motoneurons situated dorsal to the inferior olive. Axons arising from cells in this nucleus course in the ninth and tenth cranial nerves. The component to the ninth nerve is insignificant. In the tenth nerve, these fibers supply muscles of the soft palate, larynx, pharynx, and upper esophagus. A unilateral lesion will produce ipsilateral paralysis of the soft palate causing the uvula to deviate away from the lesioned nerve and nasal regurgitation of liquids, weakness of laryngeal muscles causing hoarseness, and pharyngeal weakness resulting in difficulty in swallowing.

Dorsal motor nucleus of CN X

These visceral motoneurons of CN X are located lateral to the hypoglossal nucleus in the floor of the fourth ventricle. This is a major parasympathetic nucleus of the brain stem, and it supplies preganglionic fibers innervating terminal ganglia in the thorax and the foregut and midgut parts of the gastrointestinal tract.

Clinical Correlate

The abducens nucleus is coexistent with the PPRF, the center for ipsilateral horizontal gaze. Lesions result in an inability to look to the lesion side, and may include a complete ipsilateral facial paralysis of the VIIth nerve fibers.

Hypoglossal nucleus

The hypoglossal nucleus is situated near the midline just beneath the central canal and fourth ventricle. This nucleus sends axons into the hypoglossal nerve to innervate all of the tongue muscles except the palatoglossus.

The accessory nucleus

The accessory nucleus is found in the cervical spinal cord. The axons of the spinal accessory nerve arise from the accessory nucleus, pass through the foramen magnum to enter the cranial cavity, and join the fibers of the vagus to exit the cranial cavity through the jugular foramen. As a result, intramedullary lesions do not affect fibers of the spinal accessory nerve. The spinal accessory nerve supplies the sternocleidomastoid and trapezius muscles.

The rootlets of the glossopharyngeal (CN IX) and vagus (CN X) nerves exit between the olive and the fibers of the inferior cerebellar peduncle. The hypoglossal nerve (CN XII) exits more medially between the olive and the medullary pyramid.

PONS

The pons is located between the medulla (caudally) and the midbrain (rostrally). The cerebellum overlies the pons. It is connected to the brain stem by three pairs of cerebellar peduncles. The fourth ventricle is found between the dorsal surface of the pons and the cerebellum. The ventral surface of the pons is dominated by fibers, which form a large ventral enlargement that carries fibers from pontine nuclei to the cerebellum in the middle cerebellar peduncle. This ventral enlargement is the key distinguishing feature of the pons.

The corticospinal tracts are more diffuse in the pons than in the medulla and are embedded in the transversely coursing fibers that enter the cerebellum in the middle cerebellar peduncle.

The medial lemniscus is still situated near the midline but is now separated from the corticospinal tracts by the fibers forming the middle cerebellar peduncle. The medial lemniscus has changed from a dorsoventral orientation in the medulla to a more horizontal orientation in the pons.

The spinothalamic tract and the descending hypothalamic fibers continue to course together in the lateral pons.

The lateral lemniscus, an ascending auditory pathway, is lateral and just dorsal to the medial lemniscus. The lateral lemniscus carries the bulk of ascending auditory fibers from both cochlear nuclei to the inferior colliculus of the midbrain.

The medial longitudinal fasciculus (MLF) is located near the midline just beneath the fourth ventricle.

Cranial Nerve Nuclei**Abducens nucleus**

The abducens nucleus is found near the midline in the floor of the fourth ventricle just lateral to the MLF.

Facial motor nucleus

The facial motor nucleus is located ventrolateral to the abducens nucleus. Fibers from the facial nucleus curve around the posterior side of the abducens nucleus (the curve forms the internal

genu of the facial nerve), then pass ventrolaterally to exit the brain stem at the pontomedullary junction.

Superior olivary nucleus

The superior olivary nucleus lies immediately ventral to the nucleus of CN VII and receives auditory impulses from both ears by way of the cochlear nuclei. The cochlear nuclei are found at the pontomedullary junction just lateral to the inferior cerebellar peduncle.

Vestibular nuclei

The vestibular nuclei are located near the posterior surface of the pons lateral to the abducens nucleus, and extend into the medulla.

Cochlear nuclei

The dorsal and ventral cochlear nuclei are found at the pontomedullary junction. All of the fibers of the cochlear part of the VIIIth nerve terminate here.

Trigeminal nuclei

Motor Nucleus—Pons

The motor nucleus of CN V is located in the pons just medial to the main sensory nucleus of the trigeminal and adjacent to the point of exit or entry of the trigeminal nerve fibers. These motor fibers supply the muscles of mastication (masseter, temporalis, and medial and lateral pterygoid; Figure IV-5-3).

Main Sensory Nucleus—Pons

The main sensory nucleus is located just lateral to the motor nucleus.

The main sensory nucleus receives tactile and pressure sensations from the face, scalp, oral cavity, nasal cavity, and dura.

Spinal Trigeminal Nucleus—Spinal cord to pons

The spinal trigeminal nucleus is a caudal continuation of the main sensory nucleus, extending from the mid pons through the medulla to the cervical cord. Central processes from cells in the trigeminal ganglion conveying pain and temperature sensations from the face descend in the spinal tract of V and synapse on cells in the spinal nucleus.

Mesencephalic Nucleus—Midbrain

The mesencephalic nucleus of CN V is located at the point of entry of the fifth nerve and extends into the midbrain. It receives proprioceptive input from joints, muscles of mastication, extraocular muscles, teeth, and the periodontium. Some of these fibers synapse monosynaptically on the motoneurons, forming the sensory limb of the jaw jerk reflex.

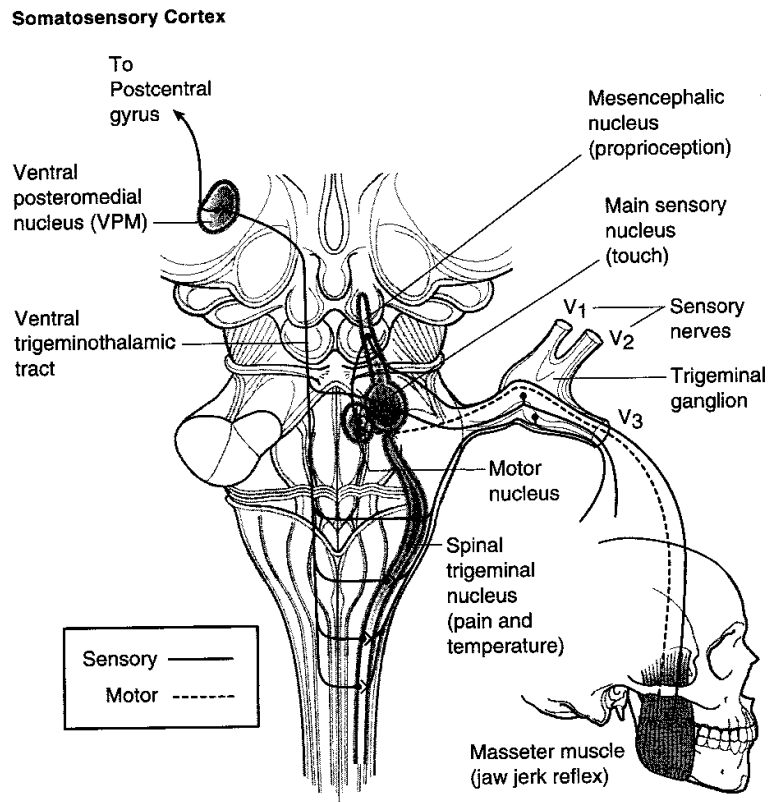


Figure IV-5-3. Trigeminal Pathways

Cranial Nerves V, VI, VII, and VIII

Four cranial nerves emerge from the pons. Cranial nerves VI, VII, and VIII emerge from the pontomedullary junction. The facial nerve is located medial to the vestibulocochlear nerve. The abducens nerve (CN VI) emerges near the midline lateral to the corticospinal tract. The trigeminal nerve (CN V) emerges from the middle of the pons.

MIDBRAIN

The midbrain (mesencephalon) is located between the pons and diencephalon. The cerebral aqueduct, a narrow channel that connects the third and fourth ventricles, passes through the midbrain. The inferior colliculi and superior colliculi are found on the dorsal aspect of the midbrain above the cerebral aqueduct. The inferior colliculus processes auditory information received bilaterally from the cochlear nuclei by axon fibers of the lateral lemniscus. The superior colliculi help direct movements of both eyes in gaze. The pretectal region is located just beneath the superior colliculi and in front of the oculomotor complex. This area contains interneurons involved in the pupillary light reflex. The massive cerebral peduncles extend ventrally from the

midbrain. The cerebral peduncles contain corticospinal and corticobulbar fibers. The interpeduncular fossa is the space between the cerebral peduncles.

The substantia nigra is the largest nucleus of the midbrain. It appears black to dark brown in the freshly cut brain because nigral cells contain melanin pigments. Neurons in the substantia nigra utilize Dopamine and GABA as neurotransmitters.

The medial lemniscus and spinothalamic tract and descending hypothalamic fibers course together ventrolateral to the periaqueductal gray.

The MLF continues to be located near the midline, just beneath the cerebral aqueduct.

The mesencephalic nuclei of the trigeminal nerve are located on either side of the central gray.

Cranial Nerve Nuclei

The trochlear nucleus is located just beneath the periaqueductal gray near the midline between the superior and inferior colliculi. The oculomotor nucleus and the nucleus of Edinger-Westphal are found just beneath the periaqueductal gray near the midline at the level of the superior colliculi.

Two cranial nerves emerge from the midbrain: the oculomotor (CN III) and the trochlear (CN IV) nerves.

The **oculomotor nerve** arises from the oculomotor nucleus and exits ventrally from the midbrain in the interpeduncular fossa. CN III also contains preganglionic parasympathetic axons that arise from the nucleus of Edinger-Westphal, which lies adjacent to the oculomotor nucleus.

Axons of the **trochlear nerve** decussate in the superior medullary velum and exit the brain stem near the posterior midline just inferior to the inferior colliculi.

Corticobulbar Innervation of Cranial Nerve Nuclei

Corticobulbar fibers serve as the source of upper motoneuron innervation of lower motoneurons in cranial nerve nuclei (Figure IV-5-4). Corticobulbar fibers arise in the motor cortex and influence lower motoneurons in all brain stem nuclei that innervate skeletal muscles. This includes:

- Muscles of mastication (CN V)
- Muscles of facial expression (CN VII)
- Palate, pharynx, and larynx (CN X)
- Tongue (CN XII)
- Sternocleidomastoid and trapezius muscles (CN XI)

The corticobulbar innervation of cranial nerve lower motoneurons is predominantly bilateral, in that each lower motoneuron in a cranial nerve nucleus receives input from corticobulbar axons arising from both the right and the left cerebral cortex.

Clinical Correlate

Facial Paralysis

The upper motoneuron innervation of lower motoneurons in the facial motor nucleus is different and clinically significant. Like most cranial nerve lower motoneurons, the corticobulbar innervation of facial motoneurons to muscles of the upper face (which wrinkle the forehead and shut the eyes) is bilateral. The corticobulbar innervation of facial motoneurons to muscles of the mouth, however, is contralateral only. Clinically, this means that one can differentiate between a lesion of the seventh nerve and a lesion of the corticobulbar fibers to the facial motor nucleus. A facial nerve lesion (as in **Bell Palsy**) will result in a complete ipsilateral paralysis of muscles of facial expression, including an inability to wrinkle the forehead or shut the eyes and a drooping of the corner of the mouth. A corticobulbar lesion will result in only a drooping of the corner of the mouth on the contralateral side of the face and no other facial motor deficits. Generally, no other cranial deficits will be seen with corticobulbar lesions because virtually every other cranial nerve nucleus is bilaterally innervated. In some individuals, the hypoglossal nucleus may receive mainly contralateral corticobulbar innervation. If these corticobulbar fibers are lesioned, the tongue muscles undergo transient weakness without atrophy or fasciculations and may deviate away from the injured corticobulbar fibers. If, for example, the lesion is in corticobulbar fibers on the left, there is transient weakness of the right tongue muscles, causing a deviation of the tongue toward the right side upon protrusion.

Abbreviations

LF = lower face innervation
 UF = upper face innervation
 UMN = upper motoneuron

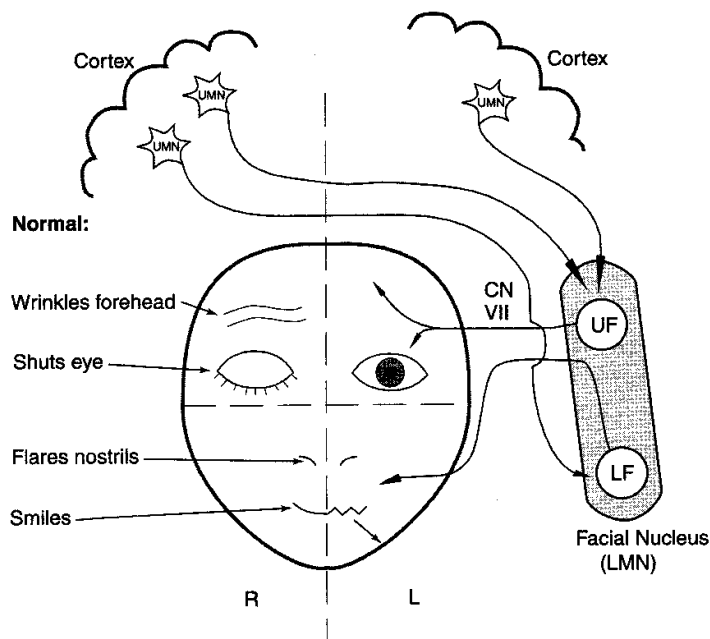


Figure IV-5-4. Corticobulbar Innervation of the Facial Motor Nucleus

COMPONENTS OF THE EAR, AUDITORY, AND VESTIBULAR SYSTEMS

Each ear consists of three components: two air-filled spaces, the external ear and the middle ear, and the fluid-filled spaces of the inner ear (Figure IV-5-5).

The external ear includes the pinna and the external auditory meatus, which extends to the tympanic membrane. Sound waves travel through the external auditory canal and cause the tympanic membrane (eardrum) to vibrate. Movement of the eardrum causes vibrations of the ossicles in the middle ear (i.e., the malleus, incus, and stapes). Vibrations of the ossicles are transferred through the oval window and into the inner ear.

The middle ear lies in the temporal bone, where the chain of three ossicles connect the tympanic membrane to the oval window. These auditory ossicles amplify the vibrations received by the tympanic membrane and transmit them to the fluid of the inner ear with minimal energy loss. The malleus is inserted in the tympanic membrane, and the stapes is inserted into the membrane of the oval window. Two small skeletal muscles, the tensor tympani and the stapedius, contract to prevent damage to the inner ear when the ear is exposed to loud sounds. The middle ear cavity communicates with the nasopharynx via the eustachian tube, which allows air pressure to be equalized on both sides of the tympanic membrane.

The inner ear consists of a labyrinth (osseous and membranous) of interconnected sacs (utricle and saccule) and channels (semicircular ducts and the cochlear duct) that contain patches of receptor or hair cells that respond to airborne vibrations or movements of the head. Both the cochlear duct and the sacs and channels of the vestibular labyrinth are filled with endolymph, which bathes the hairs of the hair cells. Endolymph is unique because it has the inorganic ionic composition of an intracellular fluid but it lies in an extracellular space. The intracellular ionic composition of endolymph is important for the function of hair cells. Perilymph, ionically like a typical extracellular fluid, lies outside the endolymph-filled labyrinth (Figure IV-5-6).

Clinical Correlate

Middle ear diseases (otitis media, otosclerosis) result in a conductive hearing loss because of a reduction in amplification provided by the ossicles.

Lesions of the facial nerve in the brain stem or temporal bone (Bell palsy) may result in hyperacusis, an increased sensitivity to loud sounds.

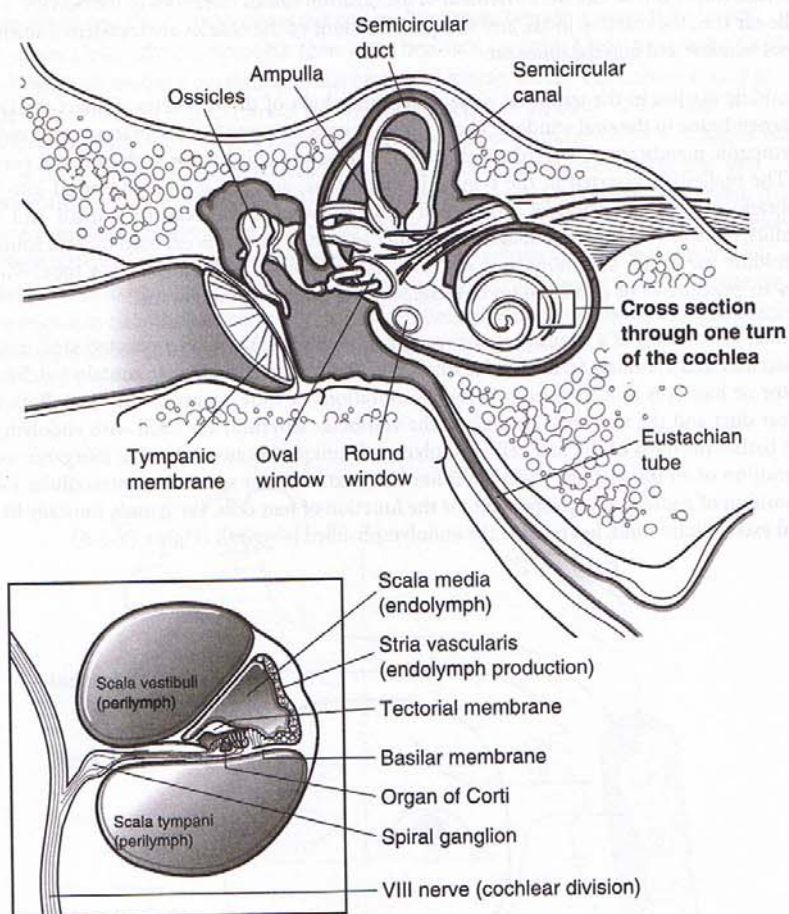


Figure IV-5-5. Structures of the Inner Ear

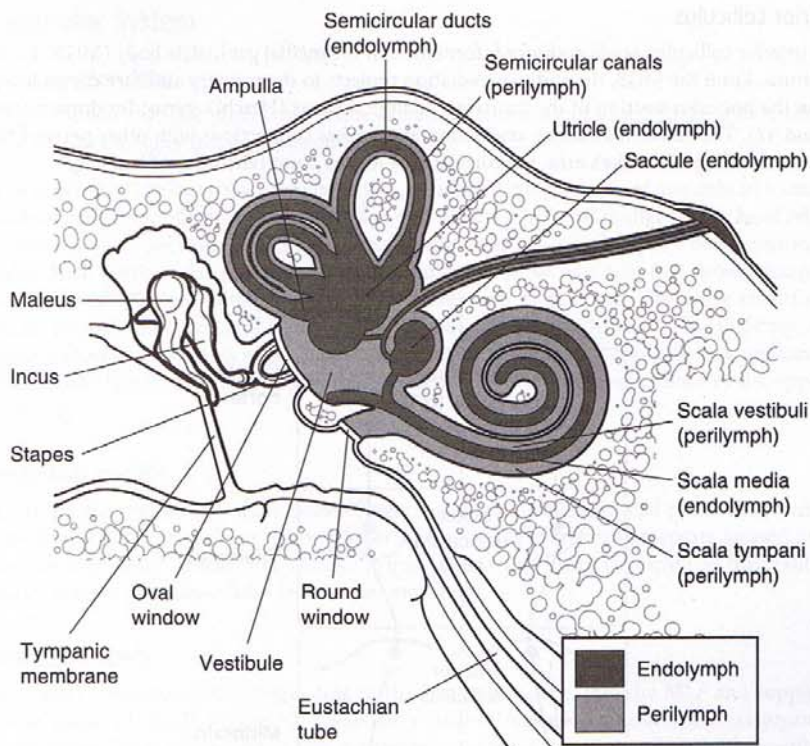


Figure IV-5-6. Distribution of Endolymph and Perilymph in Inner Ear

Clinical Correlate

Presbycusis results from a loss of hair cells at the base of the cochlea.

Auditory System

Cochlear duct

The cochlear duct is the auditory receptor of the inner ear. It contains hair cells, which respond to airborne vibrations transmitted by the ossicles to the oval window. The cochlear duct coils two and a quarter turns within the bony cochlea and contains hair cells situated on an elongated, highly flexible, basilar membrane. High-frequency sound waves cause maximum displacement of the basilar membrane and stimulation of hair cells at the base of the cochlea, whereas low-frequency sounds maximally stimulate hair cells at the apex of the cochlea.

Spiral ganglion

The spiral ganglion contains cell bodies whose peripheral axons innervate auditory hair cells of the organ of Corti. The central axons from these bipolar cells form the cochlear part of the eighth cranial nerve. All of the axons in the cochlear part of the eighth nerve enter the pontomedullary junction and synapse in the ventral and dorsal cochlear nuclei. Axons of cells in the ventral cochlear nuclei bilaterally innervate the superior olivary nuclei in the pons. The superior olivary nuclei are the first auditory nuclei to receive binaural input and use the binaural input to localize sound sources. The lateral lemniscus carries auditory input from the cochlear nuclei and the superior olivary nuclei to the inferior colliculus in the midbrain. Each lateral lemniscus carries information derived from both ears; however, input from the contralateral ear predominates (Figure IV-5-7).

Clinical Correlate**Lesions Causing Hearing Loss**

Lesions of the cochlear part of the eighth nerve or cochlear nuclei inside the brain stem at the pontomedullary junction result in a profound unilateral sensorineural hearing loss. All other lesions to auditory structures in the brain stem, thalamus, or cortex result in a bilateral suppression of hearing and a decreased ability to localize a sound source. If a patient presents with a significant hearing loss in one ear, the lesion is most likely in the middle ear, inner ear, eighth nerve, or cochlear nuclei, and not at higher levels of the auditory system.

Inferior colliculus

The inferior colliculus sends auditory information to the medial geniculate body (MGB) of the thalamus. From the MGB, the auditory radiation projects to the primary auditory cortex located on the posterior portion of the transverse temporal gyrus (Heschl's gyrus; Brodmann areas 41 and 42). The adjacent auditory association area makes connections with other parts of the cortex, including Wernicke's area, the cortical area for the comprehension of language.

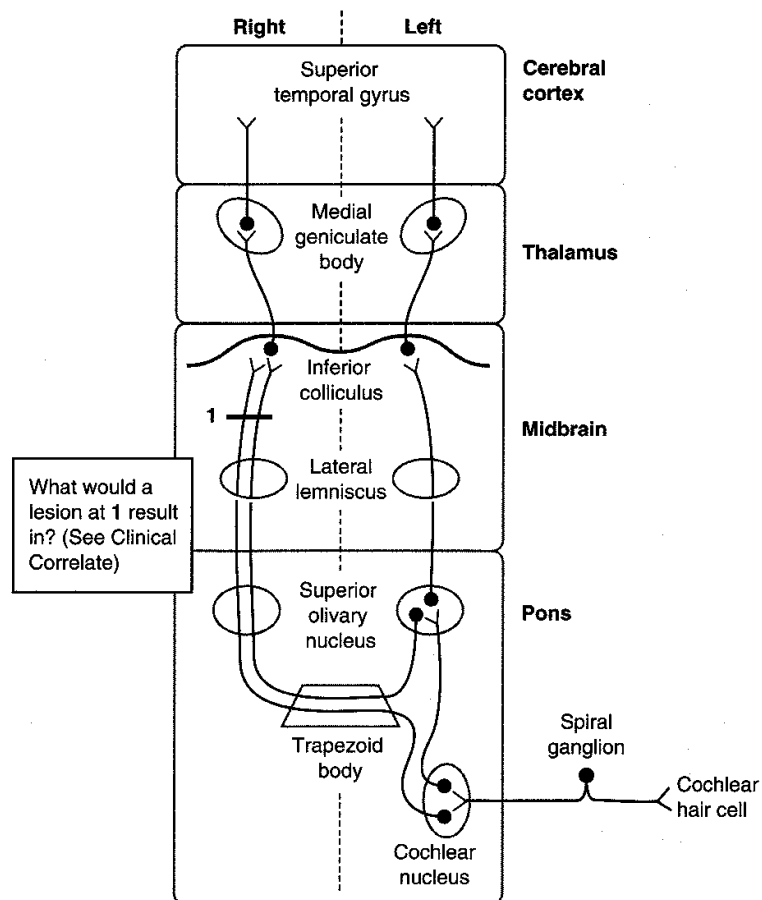


Figure IV-5-7. Auditory System

Vestibular System

Sensory receptors

The vestibular system contains two kinds of sensory receptors, one kind in the utricle and the saccule and the other in the semicircular ducts.

The utricle and the saccule are two large sacs, each containing a patch of hair cells in a macula. Each macula responds to linear acceleration and detects positional changes in the head relative to gravity. There are three semicircular ducts in the inner ear, each lying in a bony semicircular canal. Each semicircular duct contains an ampullary crest of hair cells that detect changes in angular acceleration resulting from circular movements of the head. The three semicircular ducts, anterior, posterior, and horizontal, are oriented such that they lie in the three planes of space. Circular movements of the head in any plane will depolarize hair cells in a semicircular duct in one labyrinth and hyperpolarize hair cells in the corresponding duct in the opposite labyrinth.

Vestibular nuclei

There are four vestibular nuclei located in the rostral medulla and caudal pons. The vestibular nuclei receive afferents from the vestibular nerve, which innervates receptors located in the semicircular ducts, utricle, and saccule. Primary vestibular fibers terminate in the vestibular nuclei and the flocculonodular lobe of the cerebellum.

Vestibular fibers

Secondary vestibular fibers, originating in the vestibular nuclei, join the MLF and supply the motor nuclei of CN III, IV, and VI. These fibers are involved in the production of conjugate eye movements. These compensatory eye movements represent the efferent limb of the vestibulo-ocular reflex, which enables the eye to remain focused on a stationary target during movement of the head or neck. Most of our understanding of the vestibulo-ocular reflex is based on horizontal head turning and a corresponding horizontal movement of the eyes in the direction opposite to that of head turning. For example, when the head turns horizontally to the right, both eyes will move to the left using the following vestibulo-ocular structures. Head turning to the right stimulates hair cells in the right semicircular ducts. The right eighth nerve increases its firing rate to the right vestibular nuclei. These nuclei then send axons by way of the MLF to the right oculomotor nucleus and to the left abducens nucleus. The right oculomotor nerve to the right medial rectus adducts the right eye, and the left abducens nerve to the left lateral rectus abducts the left eye. The net effect of stimulating these nuclei is that both eyes will look to the left (Figures IV-5-8 and IV-5-9).

Clinical Correlate

A lesion of the vestibular nuclei or nerve (in this example on the left) produces a vestibular nystagmus with a slow deviation of the eyes toward the lesion (A) and a fast correction back to the right (B).

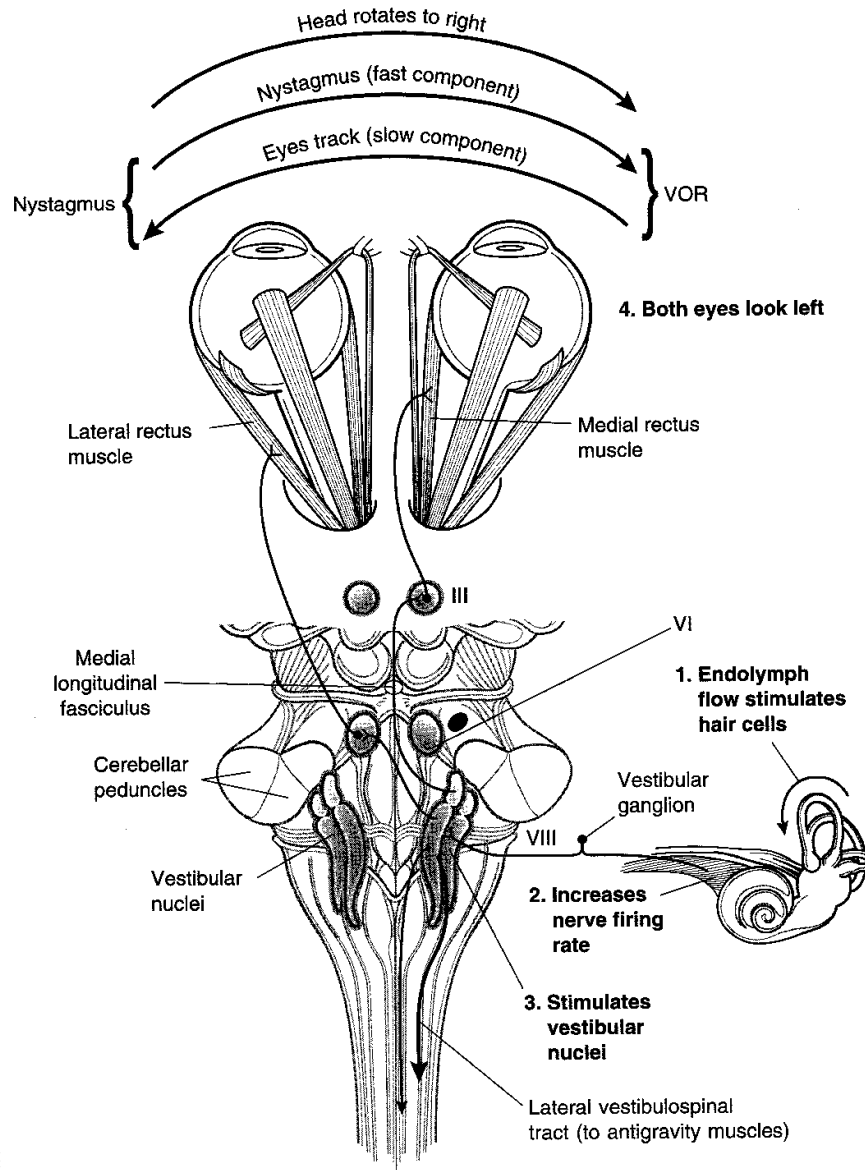


Figure IV-5-8. The Vestibulo-Ocular Reflex (VOR)

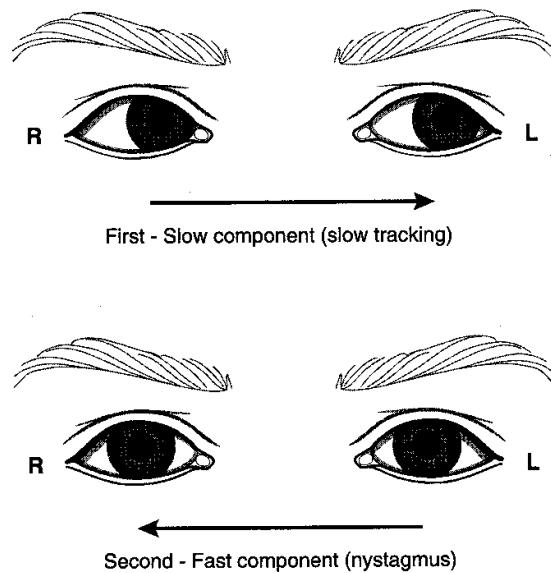


Figure IV-5-9. Vestibular System Part 2

Clinical Correlate

Vestibular dysfunction may result from either peripheral or central lesions.

Vertigo may result from a lesion of either the peripheral (end organ, nerve) or central (nuclear, brain stem pathways) vestibular structures. Vertigo refers to the perception of rotation, which may involve either the subject or the external space. The vertigo is usually severe in peripheral disease and mild in brain stem disease. Chronic vertigo (i.e., persisting longer than 2–3 weeks) strongly suggests a central lesion.

Vertigo may also be caused by a variety of drugs, including anticonvulsants, aspirin, alcohol, and certain sedatives and antibiotics. Ménière disease is characterized by abrupt, recurrent attacks of vertigo lasting minutes to hours accompanied by tinnitus or deafness and usually involving only one ear. Nausea and vomiting and a sensation of fullness or pressure in the ear also are common during the acute episode. The attacks often are severe, and the patient may be unable to stand. The disease usually occurs in middle age and results from distention of the fluid spaces in the cochlear and vestibular parts of the labyrinth.

Nystagmus

Nystagmus refers to rhythmic oscillations of the eyes slowly to one side followed by a rapid reflex movement in the opposite direction. Nystagmus is defined by the direction of the rapid reflex movement or the fast phase. It is usually horizontal, although rotatory or vertical nystagmus may also occur.

Unilateral vestibular nerve or vestibular nucleus lesions may result in a vestibular nystagmus. In a pathologic vestibular nystagmus, the initial slow phase is the response to the pathology, and the fast phase is the correction attempt made by the cortex in response to the pathology. Consider this example: if the left vestibular nerve or nuclei are lesioned, because of the loss of balance between the two sides, the right vestibular nuclei are unopposed and act as if they have been stimulated, causing both eyes to look slowly to the left. This is the slow phase of a pathologic vestibular nystagmus. Because the head did not move, the cortex responds by moving both eyes quickly back to the right, the direction of the fast phase of the nystagmus.

Tests for Nystagmus

The integrity of the vestibulo-ocular reflex can be an indicator of brain stem integrity in comatose patients. To test this reflex, a vestibular nystagmus is induced by performing a **caloric test** in which an examiner introduces warm or cool water into an external auditory meatus. Warm water introduced into the external ear stimulates the horizontal semicircular duct and causes the eyes to move slowly in the opposite direction. Because the head did not turn, the eyes are moved quickly back by the cortex (if intact) toward the same ear where the warm water was introduced, producing a fast phase of nystagmus to the same side. Introduction of cool water into the external ear mimics a lesion; the horizontal duct activity is inhibited on the cool water side, and the opposite vestibular complex moves the eyes slowly toward the cool water ear. The corrective or fast phase of the nystagmus moves the eyes quickly away from the ear where the cool water was introduced. A mnemonic which summarizes the direction of the fast phase of vestibular nystagmus in a caloric test toward the warm water side and away from the cool water side is COWS; cool, opposite, warm, same.

HORIZONTAL CONJUGATE GAZE

The eyeballs move together in conjugate gaze. The ocular muscles function to move and position both eyes as a unit so that an image falls on a corresponding spot on the retina of each eye. The slightest weakness in the movements of one eye causes diplopia, the presence of a double image, indicating that the image has been shifted to a different position on the retina of the affected side. Although gaze in all planes is possible, the muscles and cranial nerves involved in horizontal conjugate gaze, or abduction and adduction of both eyes together, are the most important eye movements (Figure IV-5-10).

Abduction of each eyeball is performed largely by the lateral rectus muscle, which is innervated by the abducens nerve (CN VI). Adduction of the eyeball is performed by the medial rectus muscle, which is innervated by the oculomotor nerve (CN III). Therefore, for both eyes to look to the right in horizontal gaze, the right abducens nerve and the right lateral rectus muscle must be active to abduct the right eye, and the left oculomotor nerve and the left medial rectus muscle must be active to adduct the left eye. The net effect is that both eyes will look to the right.

In the brain stem, the abducens nucleus (CN VI) and the oculomotor nucleus (CN III) are situated close to the midline just beneath the fourth ventricle or the cerebral aqueduct, in the pons and midbrain. These nuclei are interconnected by the fibers in the MLF. It is the fibers in the MLF that permit conjugate gaze, either when the target moves or when the head moves, through their interconnections to gaze centers and the vestibular system.

Control of Horizontal Gaze

Horizontal gaze is controlled by two interconnected gaze centers. One control center is in the frontal lobe, the frontal eye field (Brodmann area 8). This area acts as a center for **contralateral** horizontal gaze. In the pons is a second gaze center, known as the pontine gaze center or the PPRF, the paramedian pontine reticular formation. This is a center for **ipsilateral** horizontal gaze. When activated by neurons in the frontal eye field, the pontine gaze center neurons send axons to synapse with cell bodies in the abducens nucleus, which is actually contained within the pontine gaze center. The pontine gaze center also sends axons that cross immediately and course in the contralateral MLF to reach the contralateral oculomotor nucleus. The net effect of stimulation of the left frontal eye field, therefore, is activation of the pontine gaze center on the right and a saccadic horizontal eye movement of both eyes to the right. Horizontal gaze to the right results from activation of the right abducens nucleus and the left oculomotor nucleus by fibers in the MLF. Lesions in the MLF result in an internuclear ophthalmoplegia in which there is an inability to adduct one eye on attempted gaze to the opposite side. For example, a lesion in the right MLF results in an inability to adduct the right eye on an attempted gaze to the left. The left eye abducts normally but exhibits a nystagmus. If the MLF is lesioned bilaterally (as might be the case in multiple sclerosis), neither eye adducts on attempted gaze (Figures IV-5-11 and IV-5-12), and the abducting eye exhibits a nystagmus.

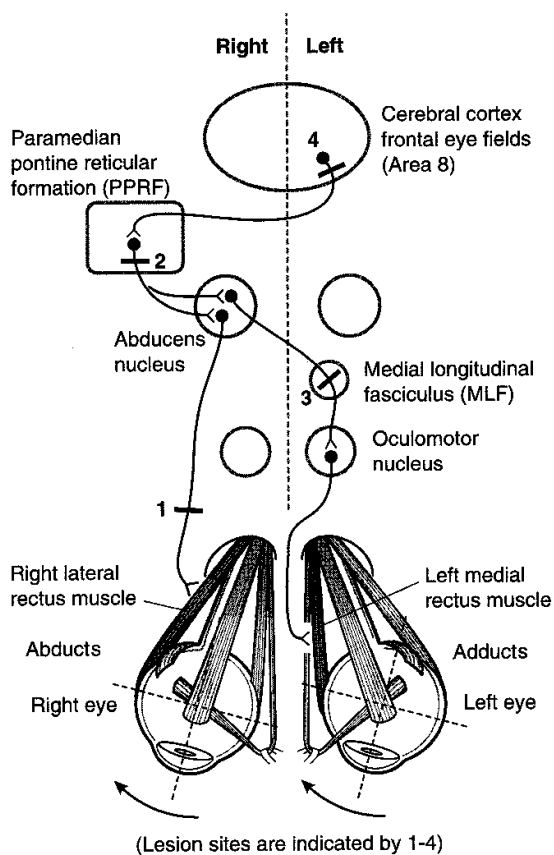


Figure IV-5-10. Voluntary Horizontal Conjugate Gaze

Ask patient to look to the right—response shown below

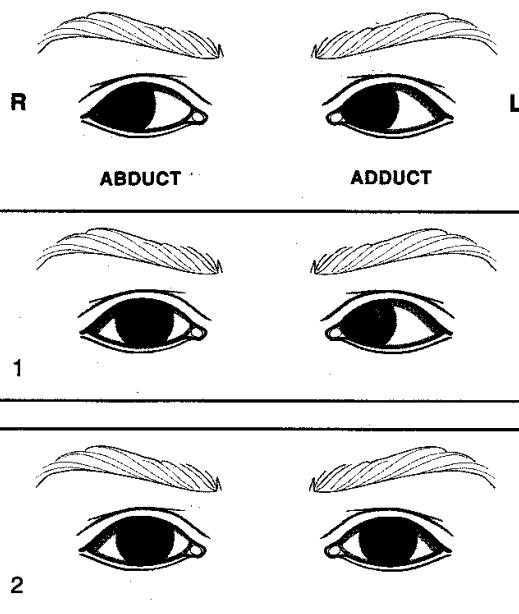


Figure IV-5-11. Normal and Abnormal Horizontal Gaze

Table IV-5-2. Normal and Abnormal Responses to the Horizontal Conjugate Gaze: Part 1

Lesion location	Symptoms (Results)
Right Abducens nerve, #1	Right eye cannot look right (abduct)
Right Abducens nucleus, #2	Neither eye can look right (lateral gaze paralysis)—may be slow drift left and right facial paralysis

Ask patient to look to the right—response shown below

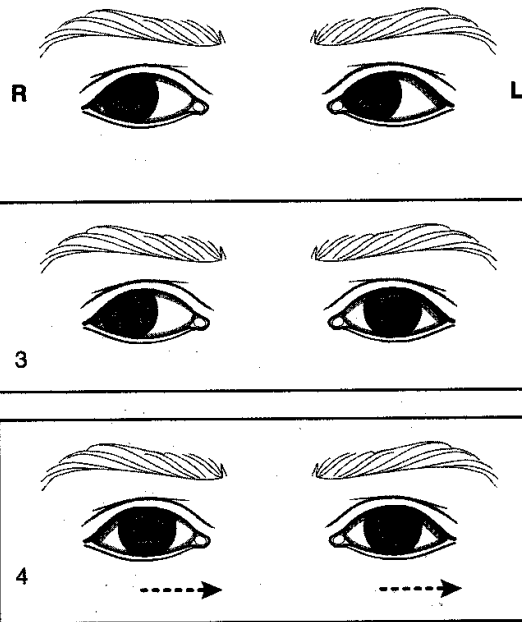


Figure IV-5-12. Normal and Abnormal Horizontal Gaze

Table IV-5-3. Normal and Abnormal Responses to the Horizontal Gaze: Part 2

Location	Symptoms (Results)
Left MLF, #3 Internuclear ophthalmoplegia	Left eye cannot look right; convergence intact; right eye exhibits nystagmus
Left cerebral cortex, #4	Neither eye can look right: but slow drift to left

BLOOD SUPPLY TO THE BRAIN STEM

Vertebral Artery

This artery is a branch of the subclavian that ascends through the foramina of the transverse processes of the upper six cervical vertebrae. It enters the posterior fossa by passing through the foramen magnum. The vertebral arteries continue up the ventral surface of the medulla and, at the caudal border of the pons, join to form the basilar artery (Figure IV-5-13).

Abbreviations

AICA = anterior inferior cerebellar artery

PICA = posterior inferior cerebellar artery

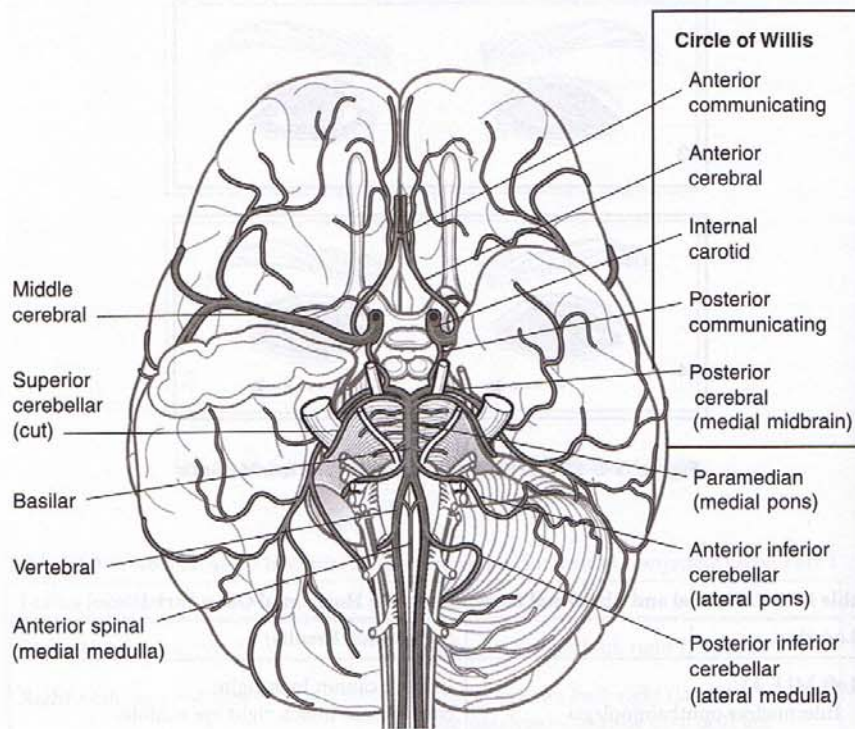


Figure IV-5-13. Arterial Supply of the Brain

Branches of the vertebral artery include: the anterior spinal artery, which supplies the ventrolateral two thirds of the cervical spinal cord and the ventrolateral part of the medulla; the posterior inferior cerebellar artery (PICA), which supplies the cerebellum and the dorsolateral part of the medulla.

Basilar Artery

The basilar artery is formed by the joining of the two vertebral arteries at the pontomedullary junction. It ascends along the ventral midline of the pons and terminates near the rostral border of the pons by dividing into the two posterior cerebral arteries. Branches include the anterior inferior cerebellar arteries (AICA) and the paramedian arteries.

Branches of the basilar artery include: the labyrinthine artery, which follows the course of the eighth cranial nerve and supplies the inner ear; the anterior inferior cerebellar artery, which supplies part of the pons and the anterior and inferior regions of the cerebellum; the superior cerebellar artery, which supplies part of the rostral pons and the superior region of the cerebellum; pontine branches, which supply much of the pons via paramedian and circumferential vessels.

At the rostral end of the midbrain, the basilar artery divides into a pair of posterior cerebral arteries. Paramedian and circumferential branches of the posterior cerebral artery supply the midbrain.

BRAIN STEM LESIONS

There are two keys to localizing brain stem lesions. First, it is uncommon to injure parts of the brain stem without involving one or more cranial nerves. The cranial nerve signs will localize the lesion to the midbrain (CN III or IV), upper pons (CN V), lower pons (CN VI, VII, or VIII), or upper medulla (CN IX, X, or XII). Second, if the lesion is in the brain stem, the cranial nerve deficits will be seen with a lesion to one or more of the descending or ascending long tracts (corticospinal, medial lemniscus, spinothalamic, descending hypothalamic fibers). Lesions in the brain stem to any of the long tracts except for the descending hypothalamic fibers will result in a contralateral deficit. A unilateral lesion to the descending hypothalamic fibers that results in Horner syndrome is always seen ipsilateral to the side of the lesion.

Medial Medullary Syndrome

Medial medullary syndrome is most frequently the result of occlusion of the vertebral artery or the anterior spinal artery (Figure IV-5-14). Medial medullary syndrome presents with a lesion of the hypoglossal nerve as the cranial nerve sign and lesions to both the medial lemniscus and the corticospinal tract. Corticospinal tract lesions produce contralateral spastic hemiparesis of both limbs.

Medial lemniscus lesions produce a contralateral deficit of proprioception and touch, pressure, and vibratory sensations in the limbs and body.

Lesions of the hypoglossal nerve in the medulla produce an ipsilateral paralysis of half the tongue with atrophy. The tongue deviates toward the side of the lesion upon protrusion.

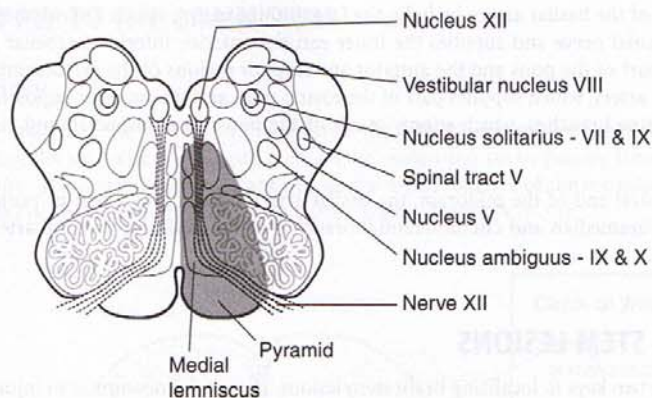


Figure IV-5-14. Medial Medullary Syndrome (ASA)

Table IV-5-4. Medial Medullary Syndrome

Structure	Sign
Pyramid	Contralateral spastic hemiparesis of body
Medial lemniscus	Contralateral loss of position and vibration sense on the body
Fibers of XII	Tongue deviates to lesion side

Lateral Medullary (Wallenberg) Syndrome

Lateral medullary syndrome results from occlusion of the PICA (Figure IV-5-15).

The cranial nerves or nuclei involved in the lesion are the vestibular or the cochlear parts of CN VIII, the glossopharyngeal and the vagus nerves, and the spinal nucleus or tract of V. The long tracts involved are the spinothalamic tract and the descending hypothalamic fibers.

Spinothalamic tract lesions produce a pain and temperature sensation deficit in the contralateral limbs and body.

Lesions of descending hypothalamic fibers produce an ipsilateral Horner syndrome (i.e., miosis, ptosis, and anhidrosis).

Lesions of the vestibular nuclei and pathways may produce nystagmus, vertigo, nausea, and vomiting. If there is a vestibular nystagmus, the fast component will be away from the side of the lesion.

Lesions of the cochlear nucleus or auditory nerve produce an ipsilateral sensorineural hearing loss.

Lesions of the vagus nerves exiting the medulla may produce dysphagia (difficulty in swallowing) or hoarseness. The palate will droop on the affected side, and the uvula will deviate away from the side of the lesion.

Lesions of the glossopharyngeal nerve result in a diminished or absent gag reflex.

Lesions of the spinal tract and nucleus of the trigeminal nerve produce a loss of just pain and temperature sensations on the ipsilateral side of half the face. Touch sensations from the face

and the corneal blink reflex will be intact. In lateral medullary syndrome, the pain and temperature losses are alternating; these sensations are lost from the face and scalp ipsilateral to the lesion but are lost from the contralateral limbs and trunk.

Taste sensations may be altered if the solitary nucleus is involved.

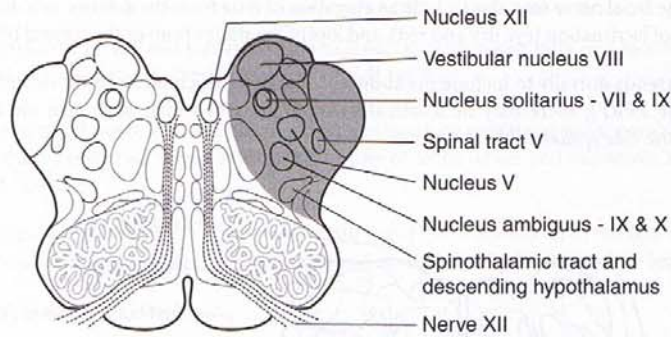


Figure IV-5-15. Lateral Medullary Syndrome (Wallenberg Syndrome; PICA)

Table IV-5-5. Lateral Medullary Syndrome (Wallenberg Syndrome)

Structure	Sign
Inferior cerebellar peduncle (ICP)	Ipsilateral limb ataxia
Spinal V	Ipsilateral pain and temperature loss—face
Spinothalamic tract	Contralateral pain and temperature loss—body
Vestibular nuclei	Vomiting, vertigo, nystagmus—away from lesion side
Descending hypothalamics	Horner syndrome (always ipsilateral)
Nucleus ambiguus (fibers of IX, X)	Ipsilateral paralysis of the vocal cord, dysphagia, palate droop

Medial Pontine Syndrome

Medial pontine syndrome results from occlusion of paramedian branches of the basilar artery (Figure IV-5-16).

At a minimum, this lesion affects the exiting fibers of the abducens nerve and the corticospinal tract. The medial lemniscus may be affected if the lesion is deeper into the pons, and the facial nerve may be affected if the lesion extends laterally.

The long tract signs will be the same as in medial medullary syndrome, involving the corticospinal and medial lemniscus, but the abducens nerve and the facial nerve lesions localize the lesion to the caudal pons.

Corticospinal tract lesions produce contralateral spastic hemiparesis of both limbs.

Medial lemniscus lesions produce a contralateral deficit of proprioception and touch, pressure, and vibratory sensations in the limbs and body.

Lesions of the abducens nerve exiting the caudal pons produce an internal strabismus of the ipsilateral eye (from paralysis of the lateral rectus). This results in diplopia on attempted lateral gaze to the affected side.

Lesions of the facial nerve exiting the caudal pons produce complete weakness of the muscles of facial expression on the side of the lesion.

Lesions of the facial nerve may also include an alteration of taste from the anterior two thirds of the tongue, loss of lacrimation (eye dry and red), and loss of the motor limb of the corneal blink reflex.

If a lesion extends dorsally to include the abducens nucleus (which includes the horizontal gaze center in the PPRF), there may be a lateral gaze paralysis in which both eyes are forcefully directed to the side ipsilateral to the lesion.

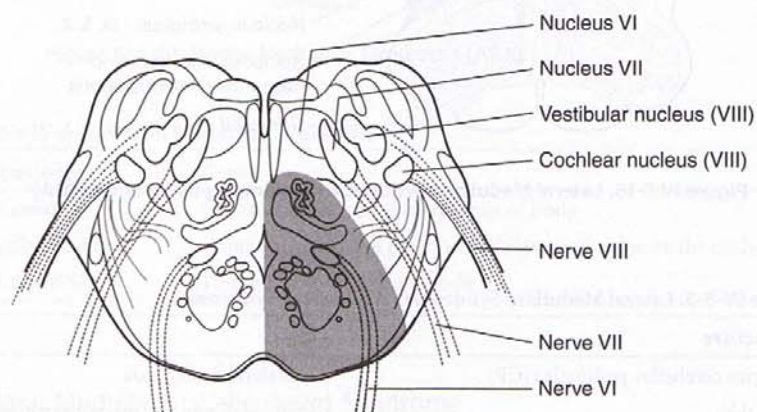


Figure IV-5-16. Medial Pontine Syndrome (Paramedian Branches of Basilar Artery)

Table IV-5-6. Medial Pontine Syndrome

Structure	Sign
CST	Contralateral spastic hemiparesis of the body
Medial lemniscus	Contralateral loss of position and vibration on the body
Fibers of VI	Medial strabismus

Lateral Pontine Syndrome

Lesions of the dorsolateral pons usually result from occlusion of the anterior inferior cerebellar artery (caudal pons) or superior cerebellar artery (rostral pons). The long tracts involved will be the same as in lateral medullary syndrome, the spinothalamic tract and the descending hypothalamic fibers. The cranial nerves involved will be the facial and vestibulocochlear in the caudal pons, the trigeminal nerve in the rostral pons, and the spinal nucleus and tract of V in both lesions (Figure IV-5-17).

Spinothalamic tract lesions produce a pain and temperature sensation deficit in the contralateral limbs and body.

Lesions of descending hypothalamic fibers produce an ipsilateral Horner syndrome (i.e., miosis, ptosis, and anhidrosis).

Lesions of the vestibular nuclei and pathways (caudal pons) produce nystagmus, vertigo, nausea, and vomiting. Again, the fast phase of the nystagmus will be away from the side of the lesion. Lesions of the cochlear nucleus or auditory nerve produce an ipsilateral sensorineural hearing loss.

Lesions of the spinal tract and nucleus of the trigeminal nerve result only in a loss of pain and temperature sensations on the ipsilateral side of half the face.

Lesions of the facial nerve and associated structures produce ipsilateral facial paralysis, loss of taste from the anterior two thirds of the tongue, loss of lacrimation and salivation, and loss of the corneal reflex.

Lesions of the trigeminal nerve (rostral pons) result in complete anesthesia of the face on the side of the lesion, weakness of muscles of mastication, and deviation of the jaw toward the lesioned side.

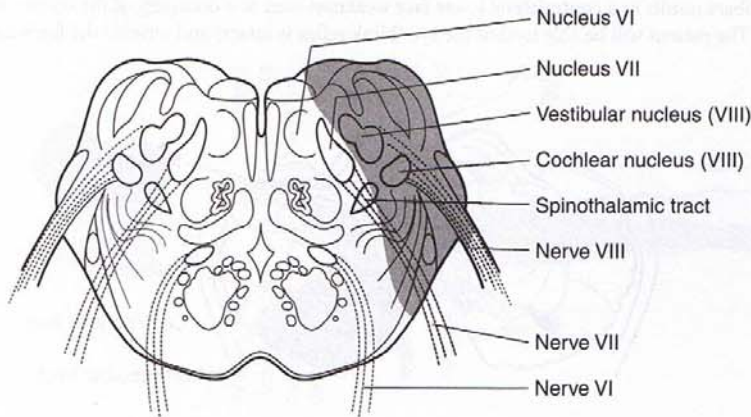


Figure IV-5-17. Lateral Pontine Syndrome (AICA)

Table IV-5-7. Lateral Pontine Syndrome

Structure	Sign
ICP	Ipsilateral limb ataxia
Spinal V	Ipsilateral pain and temperature loss—face
Spinothalamic	Contralateral pain and temperature loss—body
Vestibular nuclei	Vomiting, vertigo, nystagmus—away from lesion side
Descending hypothalamics	Horner syndrome (ipsilateral)
Fibers of VII	Ipsilateral facial paralysis
Fibers of VIII	Hearing loss

Pontocerebellar Angle Syndrome

Pontocerebellar angle syndrome is usually caused by an acoustic neuroma (schwannoma) of CN VIII. This is a slow-growing tumor, which originates from Schwann cells in the vestibular nerve (or less commonly the auditory nerve). As the tumor grows, it exerts pressure on the lateral part of the caudal pons where CN VII emerges and may expand anteriorly to compress the fifth nerve. The cranial nerve deficits seen together localize the lesion to the brain stem, but the absence of long tract signs indicates that the lesion must be outside of the brain stem.

Medial Midbrain (Weber) Syndrome

Medial midbrain (Weber) syndrome results from occlusion of branches of the posterior cerebral artery (Figures IV-5-18 and IV-5-19).

In medial midbrain syndrome, exiting fibers of CN III are affected, along with corticobulbar and corticospinal fibers in the medial aspect of the cerebral peduncle. Third nerve lesions result in a ptosis, mydriasis (dilated pupil), and an external strabismus. As with any brain stem lesion affecting the third cranial nerve, accommodation and convergence will also be affected. Corticospinal tract lesions produce contralateral spastic hemiparesis of both limbs. The involvement of the corticobulbar fibers results in a contralateral lower face weakness seen as a drooping of the corner of the mouth. The patient will be able to shut the eye (blink reflex is intact) and wrinkle the forehead.

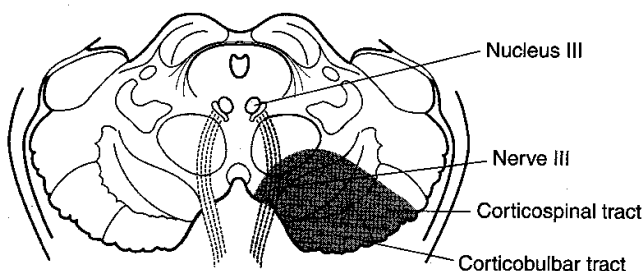


Figure IV-5-18. Ventral Midbrain Syndrome (Weber Syndrome; PCA)

Table IV-5-8. Ventral Midbrain Syndrome

Structure	Sign
CST	Contralateral spastic hemiparesis, mostly upper limb
Corticobulbar tract	Contralateral spastic hemiparesis of lower half of FACE
Fibers of III	Ipsilateral oculomotor palsy <ol style="list-style-type: none"> 1. Dilated pupil 2. Ptosis 3. Eye pointing down and out (lateral strabismus)

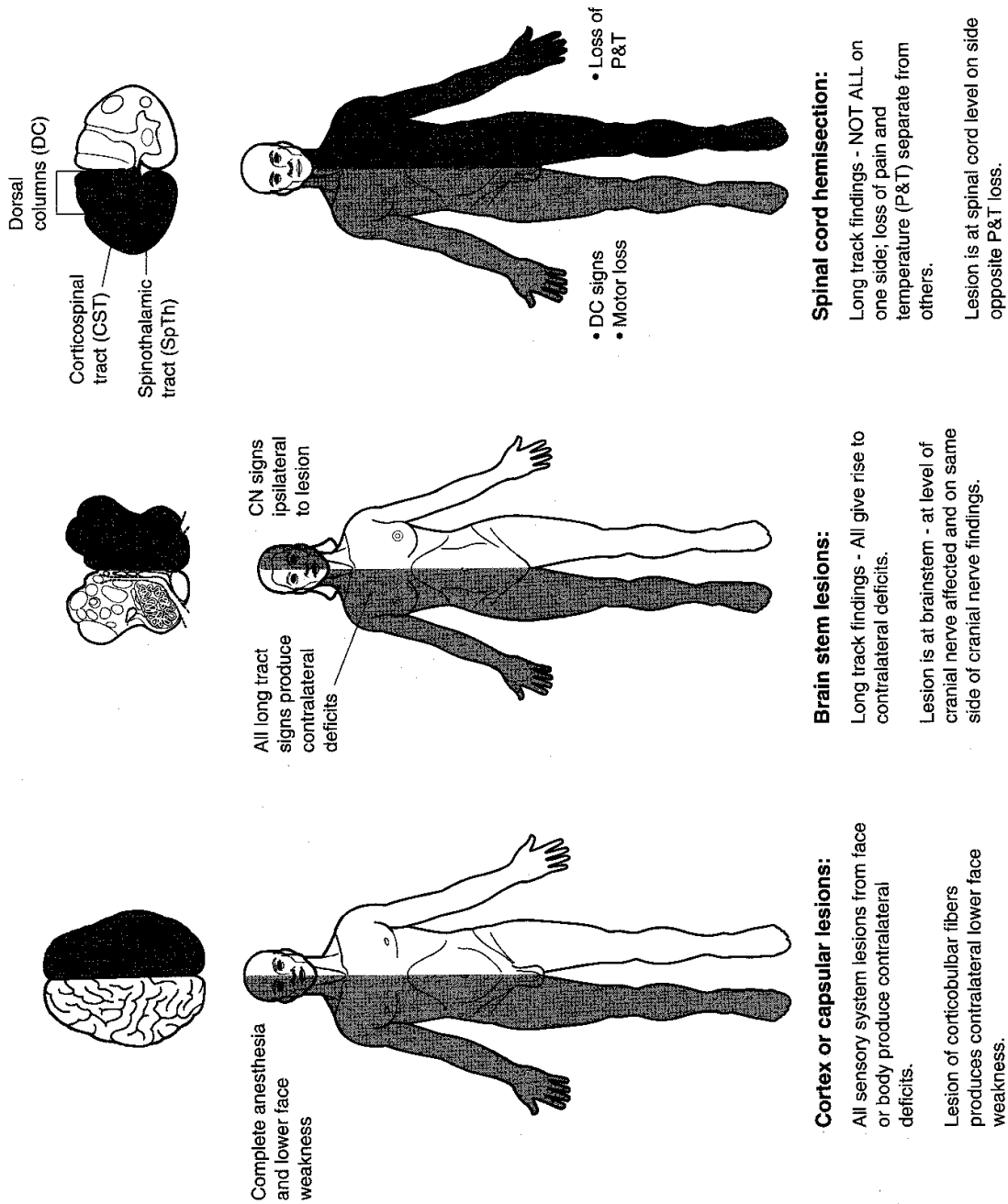


Figure IV-5-19. Strategy for the Study of Lesions

Clinical Correlate

Neurons in both the raphe and locus coeruleus degenerate in Alzheimer disease.

Parinaud Syndrome

Parinaud syndrome usually occurs as a result of a pineal tumor compressing the superior colliculi. The most common sign is paralysis of upward or vertical gaze, combined with bilateral pupillary abnormalities (e.g., slightly dilated pupils, which may show an impaired light or accommodation reaction) and signs of elevated intracranial pressure. Compression of the cerebral aqueduct can result in noncommunicating hydrocephalus.

RETICULAR FORMATION

The reticular formation is located in the brain stem and functions to coordinate and integrate the actions of different parts of the CNS. It plays an important role in the regulation of muscle and reflex activity and control of respiration, cardiovascular responses, behavioral arousal, and sleep.

Reticular Nuclei

Raphe nuclei

The raphe nuclei are a narrow column of cells in the midline of the brain stem, extending from the medulla to the midbrain. Cells in some of the raphe nuclei (e.g., the dorsal raphe nucleus) synthesize serotonin (5-hydroxytryptamine [5-HT]) from L-tryptophan and project to vast areas of the CNS. They play a role in mood, aggression, and the induction of non-rapid-eye-movement (REM) sleep.

Locus caeruleus

Cells in the locus caeruleus synthesize norepinephrine and send projections to most brain areas involved in the control of cortical activation (arousal). Decreased levels of norepinephrine are evident in REM (paradoxical) sleep.

Periaqueductal gray

The periaqueductal (central) gray is a collection of nuclei surrounding the cerebral aqueduct in the midbrain. Opioid receptors are present on many periaqueductal gray cells, the projections from which descend to modulate pain at the level of the dorsal horn of the spinal cord.

Chapter Summary

The brain stem is divided into three major subdivisions—the medulla oblongata, pons, and midbrain. The brain stem contains many descending and ascending tracts, the reticular formation, and the sensory and motor cranial nuclei of cranial nerves III–XII. Cranial nerve nuclei for CN III and IV are located in the midbrain; cranial nerve nuclei for CN V–VIII are located in the pons; and cranial nerve nuclei of IX–XII in the medulla. The motor and sensory nuclei of these cranial nerves form columns within the brain stem. Most of the motor nuclei are located medially and the sensory nuclei are located more laterally in the brain stem. Normal functions of the cranial nerves and the clinical deficits resulting from lesions of the brain stem are listed in Table IV-5-1. Lesions affecting the three long tracts to and from the spinal cord will produce contralateral deficits, but lesions of the motor or sensory cranial nuclei result in ipsilateral findings.

The motor nuclei of cranial nerves III–VII and IX–XII are lower motor neurons that innervate most of the skeletal muscles of the head. These lower motor neurons are innervated by upper motor neurons of cranial nerves (corticobulbar fibers). The cell bodies of the corticobulbar fibers are found primarily in the motor cortex of the frontal lobe. Corticobulbar innervation of lower motor neurons is primarily bilateral from both the right and left cerebral cortex, except for the innervation of the lower facial muscles around the mouth, which are derived only from the contralateral motor cortex. Generally, no cranial deficits will be seen with unilateral corticobulbar lesions, except for drooping of the corner of the mouth contralateral to the side of the lesion.

Cranial nerve VIII provides sensory pathways for auditory and vestibular systems. Auditory input depends on the stimulation of hair cells on the organ of Corti due to movement of endolymph within the membranous labyrinth of the inner ear. Axons from the organ of Corti enter the pons via CN VIII and synapse in the cochlear nuclei. From the cochlear nuclei, auditory projections bilaterally ascend the brain stem to the superior olivary nuclei via the lateral lemniscus to the inferior colliculus, and then to the medial geniculate body of the thalamus. Final auditory projections connect the thalamus with the primary auditory cortex of both temporal lobes. Thus, each auditory cortex receives input from both ears; however, input from the contralateral ear predominates. Lesions of the inner ear or of the cochlear nuclei in the pons will produce total deafness, whereas other lesions central to the cochlear nuclei will primarily affect the ability to localize sound direction.

Vestibular functions originate from endolymph movement that depolarizes hair cells in the macula of the utricle and saccule (linear acceleration and positional changes to gravity) and the ampulla of the semicircular ducts (angular acceleration). Input from these receptors project to the vestibular nuclei located in the rostral medulla and caudal pons. From these nuclei, neurons project (1) to the spinal cord via the lateral vestibulospinal tract to innervate the antigravity muscles, (2) to the flocculonodular lobe of the cerebellum, and (3) via the medial longitudinal fasciculus (MLF) to the ipsilateral oculomotor nucleus and the contralateral trochlear nucleus. This latter pathway to the ocular nuclei is the basis of the vestibuloocular reflex that allows horizontal movement of the head in one direction and the eyes moving in the direction opposite to that of head turning. Unilateral lesions of the vestibular nerve or vestibular nuclei may result in pathologic nystagmus. Nystagmus consists of two phases. First, a slow phase to the side of the lesion, and then a fast phase in the direction contralateral to the side of the lesion. The direction of the fast phase is used to classify the direction of nystagmus. The caloric test is used to test the integrity of the vestibuloocular reflex.

(Continued)

Chapter Summary (continued)

The eyes move together in horizontal conjugate gaze, which allows a focused image to fall on the same spot on the retina of each eye. Horizontal gaze requires the adduction (medial rectus muscle) and abduction (lateral rectus muscle) of both eyes together. There are two control centers for horizontal gaze. The frontal eye fields of the inferior frontal gyrus serves as a center for contralateral gaze, and the paramedian pontine reticular formation (PPRF) serves as a center for ipsilateral gaze. Neurons of the frontal eye fields cross the midline and synapse in the PPRF. The pontine center sends axons that synapse in the ipsilateral abducens nucleus. Other neurons cross the midline and course in the contralateral MLF to innervate the contralateral oculomotor nucleus. Thus, horizontal gaze to the right results from stimulation of the right abducens nucleus to abduct the right eye and the left oculomotor nucleus to adduct the left eye. Lesions affecting horizontal gaze are shown in Tables IV-5-2 and IV-5-3.

Blood supply to the brain stem is provided by the anterior spinal and posterior inferior cerebellar (PICA) branches of the vertebral artery to the medulla, the paramedian and anterior inferior cerebellar branches of the basilar artery to the pons, and branches of the posterior cerebral artery to the midbrain.

There are some key strategies for localizing brain stem lesions. Lesions of cranial nerve nuclei produce ipsilateral findings; thus, looking at the cranial nerve deficits first will often identify the side and level of the brain stem damage. Lesions of the long tracts from the spinal cord within the brain stem always produce contralateral findings. A unilateral lesion of the descending hypothalamic fibers results in ipsilateral Horner syndrome. Classic lesions of the brain stem include the medial medullary syndrome, lateral medullary (Wallenberg) syndrome, medial pontine syndrome, lateral pontine syndrome, and medial midbrain (Weber) syndrome.

Review Questions

1. A 55-year-old overweight man was brought to the emergency room unconscious after he had collapsed while loading a truck. After he regained consciousness, an exam revealed a paresis of both right limbs with a Babinski sign on the right. The patient's tongue deviated to the left upon protrusion, and he had no vibratory sense on the right side of the body. These findings suggest
 - (A) a lesion to the medial part of the medulla
 - (B) a lesion to the medial part of the pons
 - (C) an infarct of the basilar artery
 - (D) a lesion to the lateral part of the medulla
 - (E) a lesion to the medial part of the midbrain
2. A transverse section through the brainstem contains the nucleus of Edinger Westphal. Which other structure are you most likely to see in the same section?
 - (A) Central canal
 - (B) Fourth ventricle
 - (C) Olive
 - (D) Middle cerebellar peduncle
 - (E) Superior colliculus

3. A 55-year-old man came to the physician with the complaint that he felt weak and that every time he tried to smile "the left corner of his mouth drooped." He also complained of double vision. An examination revealed a paresis of the left upper and lower limbs, an external strabismus of right eye, and right ptosis. These findings suggest that the patient has
 - (A) an acoustic neuroma
 - (B) a pinealoma
 - (C) a lesion of the right side of the midbrain
 - (D) a lesion to the right side of the caudal pons
 - (E) a lesion to the right side of the lateral medulla
4. Over a period of years, a 55-year-old woman has bouts of tinnitus and nausea that have now progressed to a significant hearing loss in her left ear. She is referred to a neurologist when she becomes unable to shut both eyes with equal power and has no corneal reflex on the left. She complains of facial numbness on the left and of being unable to keep liquids in her mouth long enough to swallow. An MRI reveals a tumor compressing nerves in the cerebellopontine angle. What is the most likely embryologic origin of the tumor cells?
 - (A) Astrocytes
 - (B) Neural tube cells
 - (C) Mesoderm cells
 - (D) Ependymal cells
 - (E) Neural crest cells
5. Your patient is able to look straight ahead with both eyes, but when she looks to the left, the right eye cannot be adducted, and the left eye exhibits a horizontal nystagmus. Convergence is intact. The lesion is most likely in the
 - (A) medial longitudinal fasciculus
 - (B) oculomotor nerve
 - (C) paramedian pontine reticular formation
 - (D) trochlear nerve
 - (E) frontal eye field
6. A patient presents with an inability to move the right eye in any direction, ptosis of the right eyelid, a dilated right pupil, and altered sensation in skin over the maxilla and the frontal bones. Which of the following is the most likely cause?
 - (A) Cavernous sinus thrombosis
 - (B) Occlusion of the anterior spinal artery
 - (C) Lesion in the midbrain
 - (D) Occlusion of the anterior cerebral artery
 - (E) Craniopharyngioma

7. A patient suffers a stroke and presents with weak right limbs, a mandible that deviates to the left upon protrusion, and anesthesia of the face and scalp. Where is the lesion?
 - (A) Pons
 - (B) Trigeminal nerve
 - (C) Posterior limb of the internal capsule
 - (D) Medulla
 - (E) Paracentral lobule of cortex
8. Your patient suffers from a hearing problem as a result of a buildup of cerumen in the external auditory meatus. What would you expect to see when utilizing the following tests?
 - (A) A tuning fork placed upon the bridge of the nose will result in a lateralization toward the ear with the buildup.
 - (B) The patient will perceive vibrations of the tuning fork adjacent to the meatus after no longer perceiving vibrations when the tuning fork is placed against the mastoid process on the affected side.
 - (C) A tuning fork placed at the apex of the skull in the midline will lateralize toward the normal ear.
 - (D) The patient will perceive the vibrations longer when the tuning fork is placed against the mastoid process of the normal side compared with the side with the buildup.
 - (E) A tuning fork placed at the apex of the skull will result in vibrations being perceived equally in both ears.
9. Your patient presents with headaches, hydrocephalus, an inability to look upward with either eye, and pupils that accommodate but are unreactive to light. What is most likely to be the cause?
 - (A) A craniopharyngioma
 - (B) A pinealoma
 - (C) Schwannoma
 - (D) Medullary syrinx
 - (E) Pituitary tumor
10. Your patient has a lesion that has resulted in a loss of touch sensations in the face. The patient still feels pain and temperature sensations, and there is no jaw weakness. The neural structure most likely affected is the
 - (A) spinal nucleus of V
 - (B) trigeminal nerve
 - (C) trigeminal ganglion
 - (D) principal nucleus of V
 - (E) mesencephalic nucleus of V

11. Your patient complains of diplopia and tilts his head to counteract the diplopia. An examination indicates that the diplopia is worse when the patient looks down to read the morning paper. You suspect a lesion of the
 - (A) trochlear nerve
 - (B) oculomotor nerve
 - (C) medial longitudinal fasciculus
 - (D) abducens nerve
 - (E) paramedian pontine reticular formation

12. Your patient cannot keep liquids from dripping out of the corner of his mouth. His blink reflex is intact bilaterally, he can shut both eyes with equal power, and he can wrinkle his forehead bilaterally. You suspect that the patient has
 - (A) Bell palsy
 - (B) internuclear ophthalmoplegia
 - (C) hemiballismus
 - (D) pseudobulbar palsy
 - (E) Guillain Barré syndrome

13. A 53-year-old man was brought to the hospital complaining of dizziness and hearing loss in the left ear. Upon examination, the following symptoms were observed:
 1. He had deafness in the left ear.
 2. He had analgesia and thermal anesthesia of the right side of the body and the left side of the face.
 3. His palate drooped, and he had difficulty swallowing.
 4. The left side of his face was dry, and his left pupil was constricted compared with his right pupil.
 5. He had a tendency to fall to the left.
 6. He had a horizontal nystagmus.

Symptom #3 in this case indicates that the lesion affected the

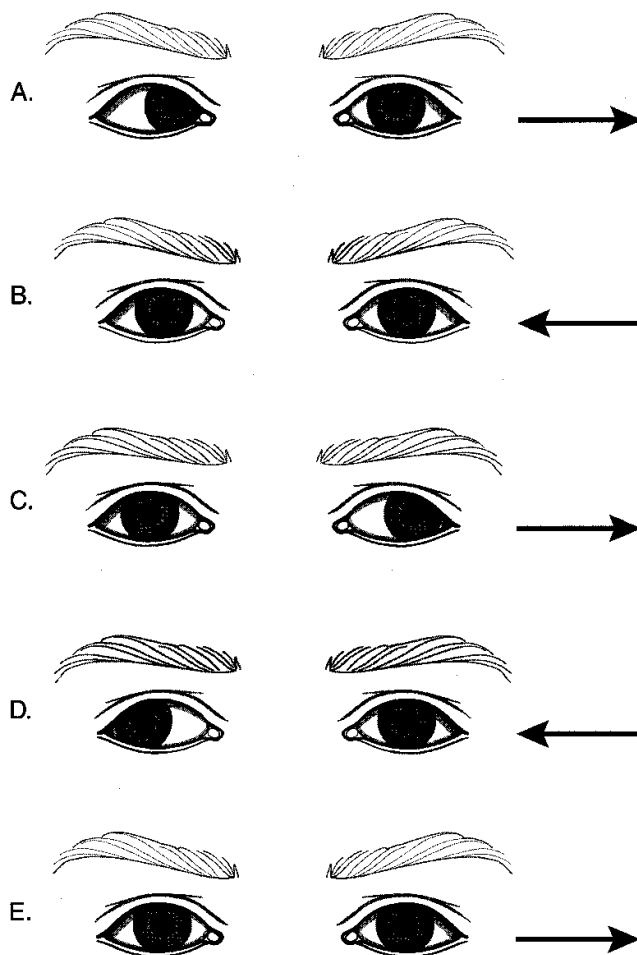
- (A) nucleus ambiguus
 - (B) solitary nucleus
 - (C) corticobulbar fibers to the nucleus ambiguus
 - (D) accessory nucleus
 - (E) dorsal motor nucleus of X
14. The nystagmus of symptom #6
 - (A) has a fast component to the right
 - (B) has a fast component to the left
 - (C) has a slow component to the right
 - (D) is due to inclusion of the right vestibular nuclei in the lesion

15. In this case, the patient's problems may have resulted from
 - (A) occlusion of the left posterior cerebral artery
 - (B) occlusion of the anterior spinal artery
 - (C) occlusion of the left middle cerebral artery
 - (D) occlusion of the left posterior inferior cerebellar artery
 - (E) occlusion of the left anterior inferior cerebellar artery
16. Your patient is having problems self-regulating their blood pressure. The cause of the problem seems to be in the carotid sinus and carotid body. Where in the brain do the nerve fibers that innervate these receptors synapse?
 - (A) Anterior hypothalamus
 - (B) Posterior pituitary
 - (C) Medulla
 - (D) Cortex
 - (E) Amygdala
17. By placing cool water in the patient's left external auditory meatus, under normal circumstances you would expect
 - (A) a nystagmus with a quick component to the right
 - (B) both eyes to drift slowly to the right
 - (C) the left eye to look to the right
 - (D) a nystagmus with a quick component to the left
 - (E) both eyes to look superiorly
18. An elderly patient comes to the physician complaining that he can no longer hear high-pitched sounds. The hearing problem is due to
 - (A) presbycusis
 - (B) a conductive hearing loss
 - (C) a loss of hair cells at the apex of the cochlea
 - (D) Meniere disease
 - (E) Otosclerosis
19. Your patient presents with drooping of the corner of the mouth on the left and weakness of the muscles of that part of the face. Saliva leaks from that side of the mouth. The patient has a blown right pupil and cannot adduct the right eye during gaze or convergence. There is a drooping of the right upper eyelid, and both left limbs are weak. The left foot exhibits a Babinski sign. Which of the following is the most likely cause of the patient's problems?
 - (A) A lesion in the posterior limb of the internal capsule on the right
 - (B) Bell palsy
 - (C) A lesion involving posterior cerebral artery branches, which supply the midbrain on the right
 - (D) A lesion involving branches of the basilar artery, which supply neural structures in the caudal pons on the right
 - (E) Subacute combined degeneration resulting from antibodies raised against intrinsic factor

20. Your patient has a profound sensorineural hearing loss in one ear; hearing in the other ear is normal. A possible site of the lesion is in the
 - (A) superior olive
 - (B) primary auditory cortex
 - (C) inferior colliculus
 - (D) lateral lemniscus
 - (E) cochlear nucleus
21. A transverse section through the brain stem contains the solitary nucleus. What other structure are you most likely to see in the same section?
 - (A) Main sensory nucleus of V
 - (B) Facial motor nucleus
 - (C) Spinal nucleus of V
 - (D) Superior cerebellar peduncle
 - (E) Trochlear nucleus
22. A 63-year-old man is suddenly unable to speak or swallow and is tetraplegic. He can only move his eyes vertically and is able to blink bilaterally. He is able to read and understand what is being said to him, and he seems aware of his surroundings and responds to yes or no questions by blinking once for yes and twice for no. Which blood vessel is most likely to have been occluded to produce these symptoms?
 - (A) Left middle cerebral artery
 - (B) Basilar artery
 - (C) Right vertebral artery
 - (D) Right posterior cerebral artery
 - (E) Right anterior cerebral artery
23. A tumor in the floor of the fourth ventricle has compressed the abducens nucleus in the dorsal part of the pons on the right. Your patient exhibits an internal strabismus. What else might you expect you to see in the patient?
 - (A) An ability to voluntarily look to the left with either eye
 - (B) An inability to wrinkle the forehead on the right
 - (C) A sensorineural hearing loss
 - (D) Alteration of taste on the anterior two-thirds of the tongue
 - (E) A right ptosis
24. Your patient has an aneurysm at the junction of the posterior communicating and posterior cerebral arteries that has compressed a nerve. On the affected side, the patient is most likely to exhibit
 - (A) anopsia
 - (B) a dilated pupil
 - (C) a medially deviated eye
 - (D) anterograde amnesia
 - (E) altered sensation in the skin of the forehead

25. Asking the patient to adduct the eye and then look down tests
- (A) the superior rectus muscle
 - (B) the inferior rectus muscle
 - (C) the superior oblique muscle
 - (D) the inferior oblique muscle
 - (E) the orbicularis oculi
26. Your patient has a tumor compressing structures traversing the jugular foramen. Your neurological evaluation might reveal
- (A) uvula deviated toward the side of the tumor
 - (B) alteration of taste on the anterior two-thirds of the tongue
 - (C) loss of the gag reflex
 - (D) hyperacusis
 - (E) atrophy of tongue muscles
27. Your patient has a loss of general sensation and ageusia on the posterior one third of the tongue, and touching the lateral wall of the throat fails to elicit a gag reflex. The neural structure that is the most likely to have been lesioned is the
- (A) glossopharyngeal nerve
 - (B) vagus nerve
 - (C) facial nerve
 - (D) nucleus ambiguus
 - (E) trigeminal nerve
28. During a neurological evaluation you note that when you stimulate the right cornea with a wisp of cotton, both eyes blink, but when you stimulate the left cornea, there is no response. You might also expect your patient to have
- (A) a dry eye
 - (B) altered sensation in skin of the cheek
 - (C) a dilated pupil on the left
 - (D) altered sensation in skin of the forehead
 - (E) an inability to wrinkle the skin of the forehead
29. Your patient cannot turn his head to the right and has difficulty raising his left arm above his head to comb his hair. You suspect a lesion of the
- (A) upper trunk of the brachial plexus on the left
 - (B) left accessory nerve
 - (C) left vagus nerve
 - (D) left long thoracic nerve
 - (E) lateral part of the medulla on the left

Questions 30 and 31 are based on the figure below.



30. The figure above represents the results of a patient's attempts to gaze horizontally in the direction of the arrow at the right. Which of the following choices most likely reflects attempts at horizontal gaze after a lesion of the frontal eye field in the right hemisphere?

- (A) A
- (B) B
- (C) C
- (D) D
- (E) E

31. The figure above represents the results of different patients' attempts to gaze horizontally in the direction of the arrow at the right. Which of the following choices most likely reflects attempts at horizontal gaze after a lesion of the medial longitudinal fasciculus on the left?
- (A) A
 - (B) B
 - (C) C
 - (D) D
 - (E) E

Answers and Explanations

1. **Answer: A.** A lesion to the medial medulla may affect the medial lemniscus and corticospinal tract. The key localizing sign is tongue deviation to the left upon protrusion, implicating the left hypoglossal nerve, which exits from the medial medulla.
2. **Answer: E.** The nucleus of Edinger Westphal is found in the rostral midbrain. The only other midbrain structure that would be found in the same section is the superior colliculus.
3. **Answer: C.** The lesion involves the corticospinal tract resulting in the hemiparesis. The key localizing sign is the third nerve lesion in the right midbrain resulting in the external strabismus and the ptosis. The corticobulbar fibers coursing through the cerebral peduncle have also been lesioned, resulting in the drooping of the corner of the mouth on the left but no other facial muscle weakness.
4. **Answer: E.** The patient most likely suffers from an acoustic neuroma, which forms initially in the Schwann cells of the eighth nerve first, then enlarges to compress the adjacent facial and trigeminal nerves. Schwann cells are derived from neural crest.
5. **Answer: A.** The patient has internuclear ophthalmoplegia caused by a lesion to the right MLF. Neither third nerve is affected because convergence is intact. MLF lesions present with weakness of adduction during gaze and nystagmus of the abducting or normal eye.
6. **Answer: A.** The only choice where a single lesion might affect all three CNs (III, IV, VI), which innervate muscles that move the eyeball, plus the ophthalmic and maxillary divisions of CN V would be a space-occupying lesion in the cavernous sinus.
7. **Answer: A.** The patient's weak limbs implicate the corticospinal tract in the lesion as well as the trigeminal nerve; the best answer for a single lesion is in the pons.
8. **Answer: A.** The patient has a conductive hearing loss. When the external and middle ear are bypassed by placing the tuning fork at the apex of the skull, the vibrations will be heard better on the affected side because air and bone conduction interfere with each other on the normal side, making that ear less sensitive.
9. **Answer: B.** The patient has Parinaud syndrome, which may be caused by a pineal tumor. The tumor compresses the dorsal aspect of the midbrain including the cerebral aqueduct, resulting in the hydrocephalus. The center for vertical gaze is affected, and the patient has Argyll Robertson pupils, which accommodate but are unreactive to light.

10. **Answer: D.** The principal nucleus of V is the site of termination of fibers conveying touch modalities from the face.
11. **Answer: A.** A weakness in the ability to intort the eye in a trochlear nerve lesion will result in an eyeball that is extorted; the patient tilts his head away from the lesioned side to counteract the diplopia.
12. **Answer: D.** The patient has a lesion to the corticobulbar fibers, which unilaterally innervate facial motor neurons to the lower face. The upper face has a bilateral corticobulbar innervation so that there is no loss in the ability to wrinkle the forehead or shut the eyes. A lesion site that affects corticobulbar fibers might be in the genu of the internal capsule.
13. **Answer: A.** Skeletal motor fibers of X, which innervate the muscles of the palate, pharynx, and larynx, arise from the nucleus ambiguus.
14. **Answer: A.** A left-side lesion to the vestibular nuclei in this case results in a vestibular nystagmus with a slow deviation of the eyes toward the lesion and a fast or corrective phase of the nystagmus away from the lesioned side.
15. **Answer: D.** The patient has lateral medullary syndrome affecting the spinothalamic tract and descending hypothalamic fibers providing long tract signs. The spinal nucleus of V has also been lesioned, giving rise to the pain and temperature loss in the face but no other trigeminal signs. The vagus nerve has been lesioned along with the cochlear and vestibular nuclei on the left. The posterior inferior cerebellar artery supplies the lateral medulla.
16. **Answer: C.** Most visceral sensations other than pain, including chemoreceptor and baroreceptor information from the carotid sinus and carotid body, enter the CNS in the glossopharyngeal and vagus nerves and synapse in the nucleus solitarius in the medulla.
17. **Answer: A.** In cool-water caloric testing, the cool water mimics a lesion and results in a fast or corrective phase away from the side of the cool-water stimulus.
18. **Answer: A.** Presbycusis is a decreased ability to perceive high-frequency sounds due to a loss of hair cells at the base of the cochlea.
19. **Answer: C.** The patient has a single long tract sign (corticospinal tract) and what appear to be two cranial nerve signs. Because the facial deficits are limited to the lower face, the lesion is not in the facial nerve but in the corticobulbar fibers above the facial motor nucleus. The true localizing cranial nerve in this case is CN III, which presents in this lesion with a dilated pupil and an inability to adduct the eyeball under any conditions. CN III involvement localizes the lesion to the medial midbrain, which is supplied by branches of the posterior cerebral artery.
20. **Answer: E.** The only lesion site that would result in a unilateral profound conductive hearing loss is the cochlear nucleus. A lesion at any other choice, which all represent higher levels of auditory processing, would result only in a slight bilateral hearing loss and a decreased ability to localize a sound source.
21. **Answer: C.** The solitarius nucleus is found throughout the length of the medulla; the only choice also found in the medulla is the spinal nucleus of V.

22. **Answer: B.** The patient has the "locked in" syndrome due to occlusion of the basilar artery in the caudal pons. Both corticospinal tracts are lesioned as are the corticobulbar fibers to the nucleus ambiguus and hypoglossal nuclei. At the level of the lesion, both abducens nerves are lesioned as are the associated horizontal gaze centers in the PPRF. Vertical gaze and blinking are possible bilaterally because their centers are located in the midbrain.
23. **Answer: B.** The skeletal motor fibers of the lower motor neurons in the facial nerve form an internal genu around the abducens and, if compressed, might affect the patient's ability to wrinkle the forehead on the side of the tumor.
24. **Answer: B.** Aneurysms at this location are second in frequency only to those at the anterior part of the circle of Willis and compress parasympathetic fibers of the oculomotor nerve resulting in a dilated pupil on the affected side.
25. **Answer: C.** The superior and inferior oblique muscles are tested by asking the patient to adduct the eye first, then look down (tests superior oblique) or up (tests inferior oblique). The superior and inferior rectus muscles are tested by asking the patient to abduct their eye first then look up or down.
26. **Answer: C.** Cranial nerves IX, X, and XI traverse the jugular foramen. Both IX and X contribute to the gag reflex. CN X also innervates muscles that elevate the palate; vagus nerve lesions result in deviation of the uvula but away from the side of the lesion or tumor.
27. **Answer: A.** The glossopharyngeal nerve carries both taste and general sensation from the posterior one third of the tongue and is the sensory limb of the gag reflex; both kinds of fibers might be affected if the nerve is lesioned.
28. **Answer: D.** The ophthalmic division of V carries sensory fibers from the cornea in the sensory limb of the light reflex and provides general sensation of the forehead, the scalp anterior to the mid-coronal plane, and the bridge of the nose.
29. **Answer: B.** The accessory nerve innervates the sternocleidomastoid, which contracts to allow the head to turn in the opposite direction, and the trapezius, which participates in abduction of the arm by rotating the scapula.
30. **Answer: E.** Right frontal eye field lesions would result in an inability to look to the left with either eye.
31. **Answer: D.** In a left MLF lesion, the patient would not be able to adduct the left eye on attempted gaze to the right.

The Cerebellum

6

GENERAL FEATURES

The cerebellum is derived from the metencephalon and is located dorsal to the pons and the medulla. The fourth ventricle is found between the cerebellum and the dorsal aspect of the pons. The cerebellum functions in the planning and fine-tuning of skeletal muscle contractions. It performs these tasks by comparing an intended with an actual performance.

The cerebellum consists of a midline vermis and two lateral cerebellar hemispheres. The cerebellar cortex consists of multiple parallel folds that are referred to as folia. The cerebellar cortex contains several maps of the skeletal muscles in the body (Figure IV-6-1).

The topographic arrangement of these maps indicates that the vermis controls the axial and proximal musculature of the limbs, the intermediate part of the hemisphere controls distal musculature, and the lateral part of the hemisphere is involved in motor planning.

The flocculonodular lobe is involved in control of balance and eye movements.

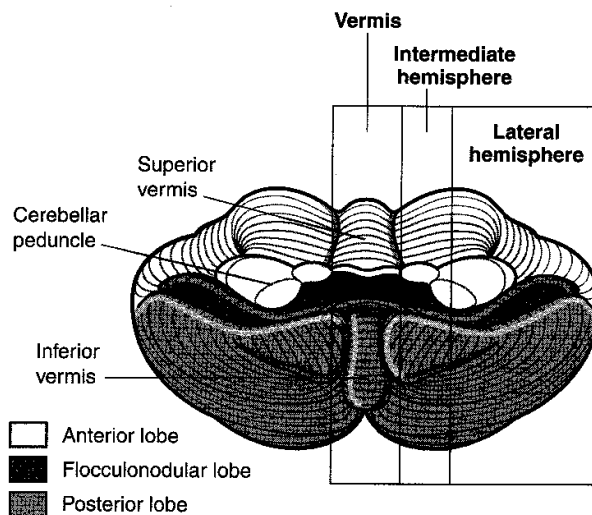


Figure IV-6-1. Cerebellum

Table IV-6-1. Cerebellum

Region	Function	Principle Input
Vermis and intermediate zones	Ongoing motor execution	Spinal cord
Hemisphere	Planning/coordination	Cerebral cortex and inferior olivary nucleus
Flocculonodular lobe	Balance and eye movements	Vestibular nuclei (VIII)

Major input to the cerebellum travels in the inferior cerebellar peduncle (ICP) (restiform body) and middle cerebellar peduncle (MCP). Major outflow from the cerebellum travels in the superior cerebellar peduncle (SCP) (Table IV-6-1).

Table IV-6-2. Major Afferents to the Cerebellum

Name	Tract	Enter Cerebellum Via	Target and Function
Mossy fibers	Vestibulocerebellar Spinocerebellar (Cortico) pontocerebellar	ICP ICP and SCP MCP (decussate)	Excitatory terminals on granule cells
Climbing fibers	Olivocerebellar	ICP (decussate)	Excitatory terminals on Purkinje cells

ICP = inferior cerebellar peduncle; MCP = middle cerebellar peduncle; SCP = superior cerebellar peduncle

CEREBELLAR CYTOARCHITECTURE

All afferent and efferent projections of the cerebellum traverse the ICP, MCP, or SCP. Most afferent input enters the cerebellum in the ICP and MCP; most efferent outflow leaves in the SCP (Figure IV-6-2 and Table IV-6-2).

Internally, the cerebellum consists of an outer cortex and an inner medulla.

The three cell layers of the cortex are the molecular layer, the Purkinje layer, and the granule cell layer.

The **molecular layer** is the outer layer and is made up of basket and stellate cells as well as parallel fibers, which are the axons of the granule cells. The extensive dendritic tree of the Purkinje cell extends into the molecular layer.

The **Purkinje layer** is the middle and most important layer of the cerebellar cortex. All of the inputs to the cerebellum are directed toward influencing the firing of Purkinje cells, and only axons of Purkinje cells leave the cerebellar cortex. A single axon exits from each Purkinje cell and projects to one of the deep cerebellar nuclei or to vestibular nuclei of the brain stem.

The **granule cell layer** is the innermost layer of cerebellar cortex and contains Golgi cells, granule cells, and glomeruli. Each glomerulus is surrounded by a glial capsule and contains a granule cell and axons of Golgi cells, which synapse with granule cells. The granule cell is the only excitatory neuron within the cerebellar cortex. All other neurons in the cerebellar cortex, including Purkinje, Golgi, basket, and stellate cells, are inhibitory.

Table IV-6-3. Cerebellum: Cell Types

Name	Target (Axon Termination)	Transmitter	Function
Purkinje cell	Deep cerebellar nuclei	GABA	Inhibitory*
Granule cell	Purkinje cell	Glutamate	Excitatory
Stellate cell	Purkinje cell	GABA	Inhibitory
Basket cell	Purkinje cell	GABA	Inhibitory
Golgi cell	Granule cell	GABA	Inhibitory

*Purkinje cells are the only outflow from the cerebellar cortex.

The **medulla** contains the deep cerebellar nuclei.

Cortical surface

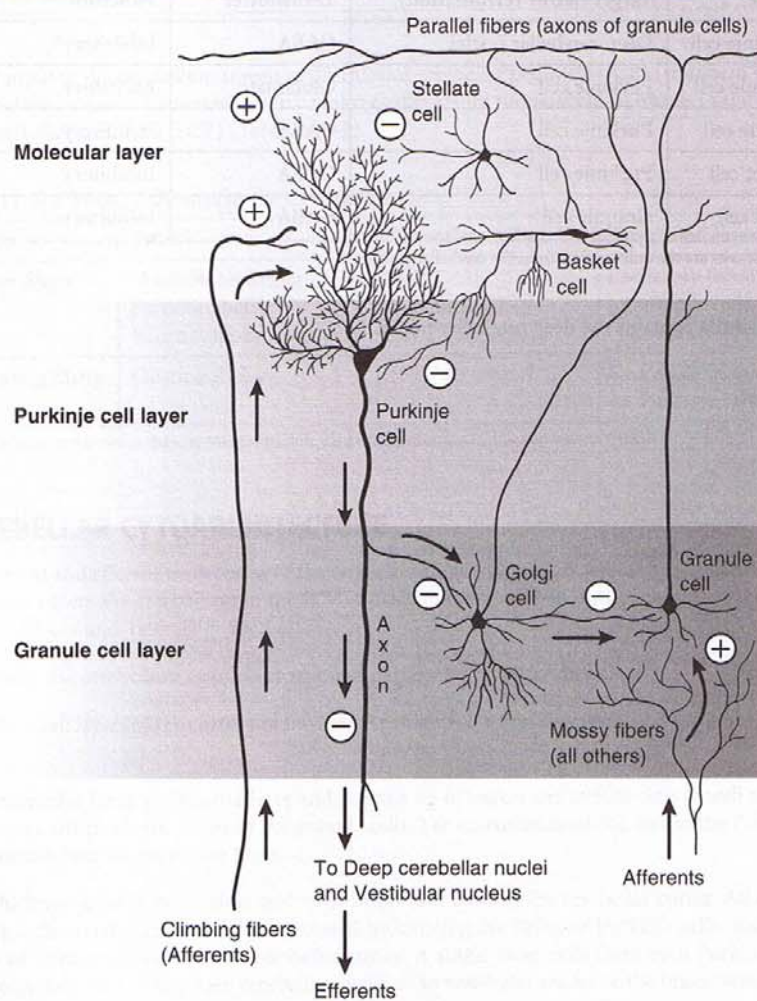


Figure IV-6-2. Cerebellar Cytoarchitecture

From medial to lateral, the deep cerebellar nuclei in the medulla are the fastigial nucleus, interposed nuclei, and the dentate nucleus.

Two kinds of excitatory input enter the cerebellum in the form of climbing fibers and mossy fibers. Both types influence the firing of deep cerebellar nuclei by axon collaterals.

Climbing fibers originate exclusively from the inferior olivary complex of nuclei on the contralateral side of the medulla. Climbing fibers provide a direct powerful monosynaptic excitatory input to Purkinje cells.

Mossy fibers represent the axons from all other sources of cerebellar input. Mossy fibers provide an indirect, more diffuse excitatory input to Purkinje cells.

All mossy fibers exert an excitatory effect on **granule cells**. Each granule cell sends its axon into the molecular layer, where it gives off collaterals at a 90-degree angle that run parallel to the cortical surface (i.e., parallel fibers). These granule cell axons stimulate the apical dendrites of the Purkinje cells. Golgi cells receive excitatory input from mossy fibers and from the parallel fibers of the granule cells. The Golgi cell in turn inhibits the granule cell, which activated it in the first place.

The **basket** and **stellate cells**, which also receive excitatory input from parallel fibers of granule cells, inhibit Purkinje cells.

CIRCUITRY

The basic cerebellar circuits begin with Purkinje cells that receive excitatory input directly from climbing fibers and from parallel fibers of granule cells.

Purkinje cell axons project to and inhibit the deep cerebellar nuclei or the vestibular nuclei in an orderly fashion (Figure IV-6-3).

- Purkinje cells in the flocculonodular lobe project to the lateral vestibular nucleus.
- Purkinje cells in the vermis project to the fastigial nuclei.
- Purkinje cells in the intermediate hemisphere primarily project to the interposed (globose and emboliform) nuclei.
- Purkinje cells in the lateral cerebellar hemisphere project to the dentate nucleus.

Clinical Correlate

Anterior vermis lesions are usually the result of degeneration from alcohol abuse and are present with gait ataxia. Posterior vermis lesions result from medulloblastomas or ependymomas and present with truncal ataxia.

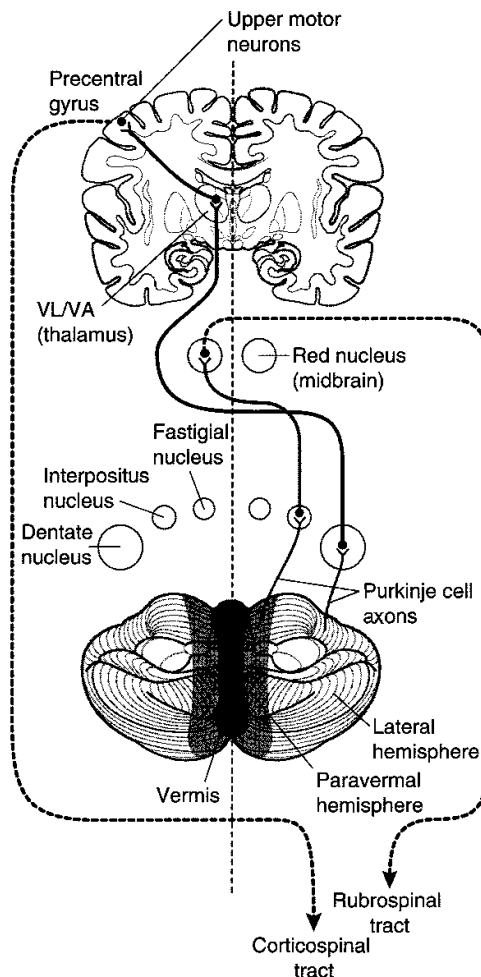


Figure IV-6-3. Cerebellar Efferents

Table IV-6-4. Major Efferents From the Cerebellum

Cerebellar Areas	Deep Cerebellar Nucleus	Efferents to:	Function
Vestibulocerebellum (flocculonodular lobe)	Fastigial nucleus	Vestibular nucleus	Elicit positional changes of eyes and trunk in response to movement of the head
Spinocerebellum (intermediate hemisphere)	Interpositus nucleus	Red nucleus Reticular formation	Influence LMNs via the reticulospinal and rubrospinal tracts to adjust posture and effect movement
Pontocerebellum (lateral hemispheres)	Dentate nucleus	Thalamus (VA, VL) then cortex	Influence on LMNs via the corticospinal tract, which effect voluntary movements, especially sequence and precision

Efferents from the deep cerebellar nuclei leave mainly through the SCP and influence all upper motoneurons. In particular, axons from the dentate and interposed nuclei leave through the SCP, cross the midline, and terminate in the ventrolateral (VL) nucleus of the thalamus.

The VL nucleus of the thalamus projects to primary motor cortex and influences the firing of corticospinal and corticobulbar neurons.

Axons from other deep cerebellar nuclei influence upper motoneurons in the red nucleus and in the reticular formation and vestibular nuclei.

Cerebellar Lesions

The hallmark of cerebellar dysfunction is a tremor with intended movement without paralysis or paresis. Symptoms associated with cerebellar lesions are expressed ipsilaterally because the major outflow of the cerebellum projects to the contralateral motor cortex, and then the corticospinal fibers cross on their way to the spinal cord. Thus, unilateral lesions of the cerebellum will result in a patient falling toward the side of the lesion.

Lesions to the vermal region

Vermal lesions result in difficulty maintaining posture, gait, or balance (an ataxic gait). Patients with vermal damage may be differentiated from those with a lesion of the dorsal columns by the Romberg sign. In cerebellar lesions, patients will sway or lose their balance with their eyes open; in dorsal column lesions, patients sway with their eyes closed.

Lesions that include the hemisphere

Lesions that include the hemisphere produce a number of dysfunctions, mostly involving distal musculature.

An intention tremor is seen when voluntary movements are performed. For example, if a patient with a cerebellar lesion is asked to pick up a penny, a slight tremor of the fingers is evident and increases as the penny is approached. The tremor is barely noticeable or is absent at rest.

Dysmetria (past pointing) is the inability to stop a movement at the proper place. The patient has difficulty performing the finger to nose test.

Dysdiadochokinesia (adiadochokinesia) is the reduced ability to perform alternating movements, such as pronation and supination of the forearm, at a moderately quick pace.

Scanning dysarthria is caused by asynergy of the muscles responsible for speech. In scanning dysarthria, patients divide words into syllables, thereby disrupting the melody of speech.

Gaze dysfunction occurs when the eyes try to fix on a point: They may pass it or stop too soon and then oscillate a few times before they settle on the target. A nystagmus may be present, particularly with acute cerebellar damage. The nystagmus is often coarse, with the fast component usually directed toward the involved cerebellar hemisphere.

Hypotonia usually occurs with an acute cerebellar insult that includes the deep cerebellar nuclei. The muscles feel flabby on palpation, and deep tendon reflexes are usually diminished.

Chapter Summary

The cerebellum controls posture, muscle tone, learning of repeated motor functions, and coordinates voluntary motor activity. Diseases of the cerebellum result in disturbances of gait, balance, and coordinated motor actions, but there is no paralysis or inability to start or stop movement.

The cerebellum is functionally divided into the (1) vermis and intermediate zone, (2) the hemisphere, and (3) the flocculonodular lobe. Each of these three areas receive afferent inputs mainly from the spinal cord, cortex and inferior olivary nucleus, and vestibular nuclei, respectively. These afferent fibers (mossy and climbing) reach the cerebellum via the inferior and middle cerebellar peduncles, which connect the cerebellum with the brain stem. The afferent fibers are excitatory and project directly or indirectly via granule cells to the Purkinje cells of the cerebellar cortex. The axons of the Purkinje cells are inhibitory and are the only outflow from the cerebellar cortex. They project to and inhibit the deep cerebellar nuclei (dentate, interposed, and fastigial nuclei) in the medulla. From the deep nuclei, efferents project mainly through the superior cerebellar peduncle and drive the upper motor neurons of the motor cortex. The efferents from the hemisphere project through the dentate nucleus, to the contralateral VL/VA nuclei of the thalamus, to reach the contralateral precentral gyrus. These influence contralateral lower motor neurons via the corticospinal tract.

Symptoms associated with cerebellar lesions are expressed ipsilaterally. Unilateral lesions of the cerebellum will result in a patient falling toward the side of the lesion. Hallmarks of cerebellar dysfunction include ataxia, intention tremor, dysmetria, and dysdiadochokinesia.

Review Questions

- Which of the following is true of Purkinje cells of the cerebellum?
 - They utilize glutamate as their neurotransmitter.
 - They receive excitatory input from Golgi and stellate cells.
 - They receive direct excitatory input from climbing fibers.
 - Their axons leave the cerebellum in the superior cerebellar peduncle.
 - They receive direct excitatory input from mossy fibers.
- Your patient has a problem stopping his finger in time to touch the tip of his nose after touching the finger of the examiner. You diagnose this as
 - dysmetria
 - athetosis
 - hemiballismus
 - chorea
 - dysdiadochokinesis
- A patient who suffers from chronic alcohol abuse, which affects neurons in the cerebellum, will most likely
 - sway back and forth with eyes closed
 - have a scanning dysarthria
 - have an ataxic gait
 - have a disdiadochokinesis
 - have a dysmetria

4. Which would you least likely expect to see in a patient who has experienced a lesion in the right hemisphere of the cerebellum?
 - (A) A tendency for the patient to fall to the right
 - (B) A right intention tremor
 - (C) A Romberg sign
 - (D) Swaying back and forth with eyes open
 - (E) An inability to perform rapidly alternating movements with the right hand
5. Neurons that send axons into the cerebellum in the middle cerebellar peduncle are controlled by which part of the brain?
 - (A) Spinal cord
 - (B) Vestibular system
 - (C) Cerebral cortex
 - (D) Olive
 - (E) Deep cerebellar nuclei

Answers and Explanations

1. **Answer: C.** Purkinje cells are inhibitory neurons of the cerebellar cortex that utilize GABA as their neurotransmitter. Their axons mostly do not leave the cerebellar cortex but synapse on cells of the deep cerebellar nuclei. They receive direct excitatory input from climbing fibers and indirect excitatory input from mossy fibers by way of axons of granule cells. Golgi and stellate cells are inhibitory interneurons in the cerebellar cortex.
2. **Answer: A.** Dysmetria is the inability to stop a movement at the proper place.
3. **Answer: C.** Chronic alcohol abuse preferentially affects anterior vermis Purkinje cells; the vermis controls proximal musculature so that lesions produce gait ataxias.
4. **Answer: C.** A Romberg sign is indicative of a dorsal column somatosensory lesion, not a cerebellar lesion.
5. **Answer: C.** Axons, which enter the cerebellum in the middle cerebellar peduncle, arise from neurons situated in pontine nuclei. Corticopontine axons, which arise from neurons located in the frontal lobe, are the primary source of input to these pontine neurons.

Visual Pathways

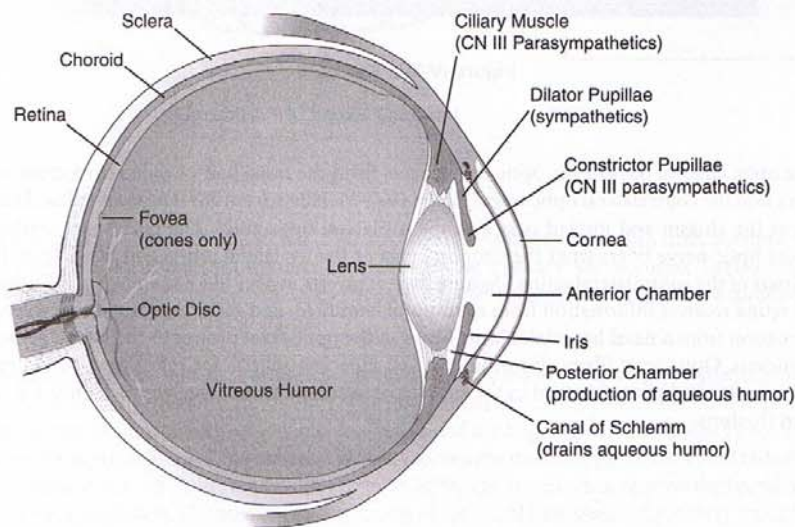
7

EYEBALL AND OPTIC NERVE

Light must pass through the cornea, aqueous humor, pupil, lens, and vitreous humor before reaching the retina (Figure IV-7-1). It must then pass through the layers of the retina to reach the photoreceptive layer of rods and cones. The outer segments of rods and cones transduce light energy from photons into membrane potentials. Photopigments in rods and cones absorb photons, and this causes a conformational change in the molecular structure of these pigments. This molecular alteration causes sodium channels to close, a hyperpolarization of the membranes of the rods and cones, and a reduction in the amount of neurotransmitter released. Thus, rods and cones release less neurotransmitter in the light and more neurotransmitter in the dark. Rods and cones have synaptic contacts on bipolar cells that project to ganglion cells (Figure IV-7-2). Axons from the ganglion cells converge at the optic disc to form the optic nerve, which enters the cranial cavity through the optic foramen. At the optic disc, these axons acquire a myelin sheath from the oligodendrocytes of the CNS.

Clinical Correlate

Vitamin A, necessary for retinal transduction, cannot be synthesized by humans. A dietary deficiency of vitamin A causes visual impairment resulting in night blindness.



Accommodation (Near) Reflex

- Contraction of the ciliary muscle, which results in thickening of the lens
- Contraction of the pupillae muscle
- Convergence

Figure IV-7-1. The Eyeball

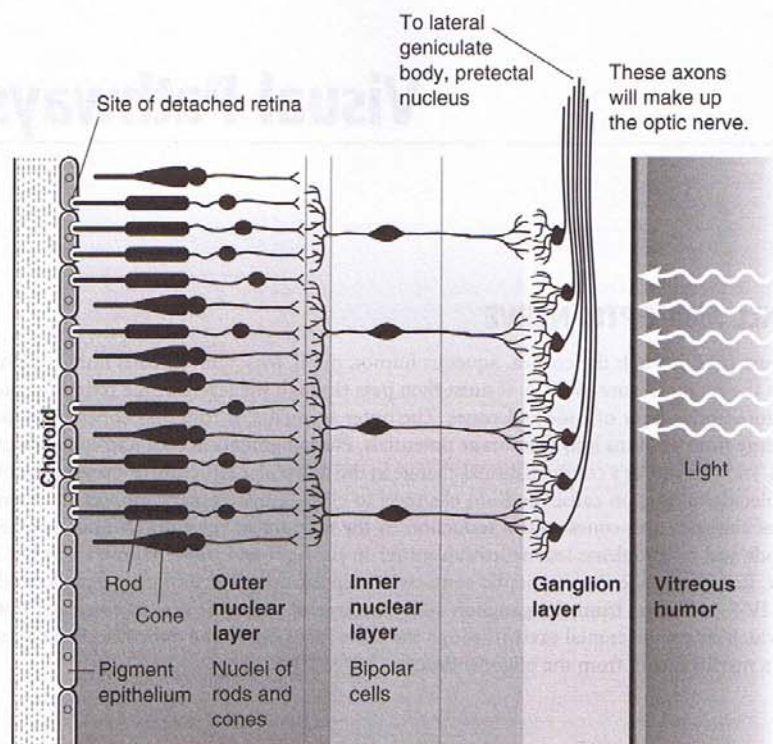


Figure IV-7-2. Retina

At the optic chiasm, 60% of the optic nerve fibers from the nasal half of each retina cross and project into the contralateral optic tract (Figure IV-7-3). Fibers from the temporal retina do not cross at the chiasm and instead pass into the ipsilateral optic tract. The optic tract contains remixed optic nerve fibers from the temporal part of the ipsilateral retina and fibers from the nasal part of the contralateral retina. Because the eye inverts images like a camera, in reality each nasal retina receives information from a temporal hemifield, and each temporal retina receives information from a nasal hemifield. Most fibers in the optic tract project to the lateral geniculate nucleus. Optic tract fibers also project to the superior colliculi for reflex gaze, to the pretectal area for the light reflex, and to the suprachiasmatic nucleus of the hypothalamus for circadian rhythms.

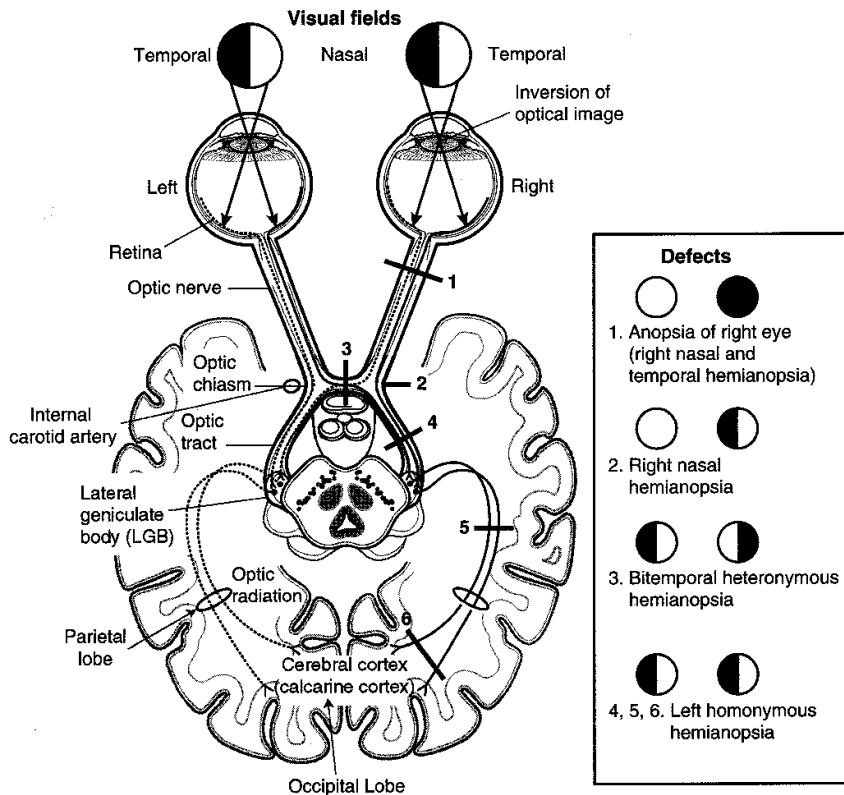


Figure IV-7-3. Visual System I

The lateral geniculate body (LGB) is a laminated structure that receives input from the optic tract and gives rise to axons that terminate on cells in the primary visual cortex (striate cortex, Brodmann area 17) of the occipital lobe. The LGB laminae maintain a segregation of inputs from the ipsilateral and contralateral retina.

The axons from the LGB that project to the striate cortex are known as optic radiations, visual radiations, or the geniculocalcarine tract. The calcarine sulcus divides the striate cortex (primary visual cortex or Brodmann area 17) into the cuneus and the lingual gyri. The cuneus gyrus, which lies on the superior bank of the calcarine cortex, receives the medial fibers of the visual radiations. The lingual gyrus, which lies on the inferior bank of the calcarine cortex, receives the lateral fibers of the visual radiation. The medial fibers coursing in the visual radiations, which carry input from the upper retina (i.e., the lower contralateral visual field), pass from the LGB directly through the parietal lobe to reach the cuneus gyrus. Significantly, the lateral fibers coursing in the visual radiations, which carry input from the lower retina (i.e., the upper contralateral visual field), take a circuitous route from the LGB through Meyer loop anteriorly into the temporal lobe. The fibers of Meyer loop then turn posteriorly and course through the parietal lobe to reach the lingual gyrus in the striate cortex.

Clinical Correlate

Some causes of lesions at #1-6:

1. Optic neuritis—in multiple sclerosis, occlusion of central artery of retina
2. Aneurysm of internal carotid artery
3. Craniopharyngioma, pituitary adenoma
4. Vascular; lesion is rarely complete
- 5, 6. Vascular due to occlusion of branch of posterior cerebral artery

Note

Visual information from **lower** retina courses in **lateral** fibers forming **Meyer loop**, which projects to the lingual gyrus.

Clinical Correlate

Some causes of lesions at #7-9:

7. Occlusion of branch of middle cerebral artery
- 8, 9. Occlusion of a branch of posterior cerebral artery. The macula is spared in #9 due to collateral blood supply from the middle cerebral artery.

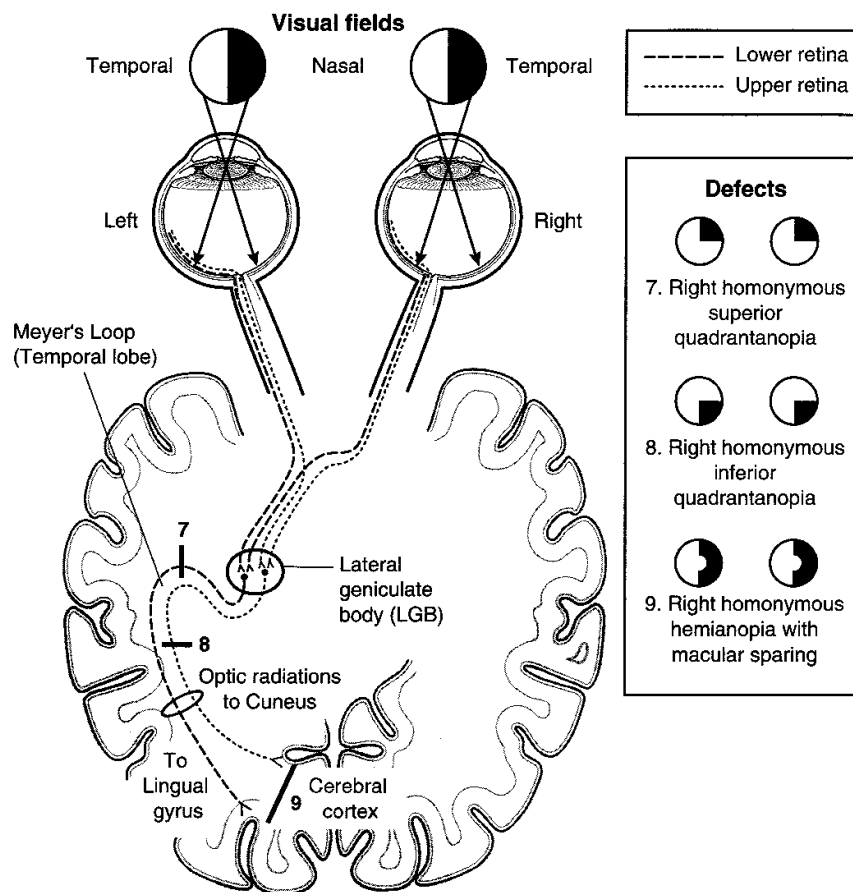


Figure IV-7-4. Visual System 2

Clinical Correlate

Unilateral optic nerve lesions are seen in multiple sclerosis where there is an immune-related inflammatory demyelination of the nerve. The lesion typically presents with a central scotoma due to involvement of the deep fibers in the nerve from the macula.

LESIONS OF THE VISUAL PATHWAYS

Lesions of the retina that include destruction of the macula produce a central scotoma. The macula is quite sensitive to intense light, trauma, aging, and neurotoxins.

Lesions of an optic nerve produce blindness (anopia) in that eye and a loss of the sensory limb of the light reflex. The pupil of the affected eye constricts when light is shined into the opposite eye (consensual light reflex) but not when light is shined into the blinded eye (absence of direct light reflex).

Compression of the optic chiasm, often the result of a pituitary tumor or meningioma, results in a loss of peripheral vision in both temporal fields because the crossing fibers from each nasal retina are damaged. The resulting visual field defect is called a bitemporal heteronymous hemianopia.

All lesions past the chiasm produce contralateral defects. Lesions of the optic tract result in a loss of visual input from the contralateral visual field. For example, a lesion of the right optic tract results in a loss of input from the left visual field. This is called a homonymous hemianopia; in this example, a left homonymous hemianopia.

Lesions of the visual radiations are more common than lesions to the optic tract or lateral geniculate body and produce visual field defects (a contralateral homonymous hemianopia) similar to those of the optic tract if all fibers are involved.

Lesions restricted to the lateral fibers in Meyer loop, usually in the temporal lobe, result in a loss of visual input from the contralateral upper quarter of the visual field. For example, a lesion of the temporal fibers in the **right** visual radiation results in loss of visual input from the upper left quarter of the field (a **left** superior quadrantanopia).

Lesions restricted to the medial fibers in the visual radiation in the parietal lobe result in a loss of visual input from the contralateral lower quarter of the field (an inferior quadrantanopia).

Lesions inside the primary visual cortex are equivalent to those of the visual radiations, resulting in a contralateral homonymous hemianopsia, except that macular (central) vision is spared.

Lesions of the cuneus gyrus are equivalent to lesions restricted to the parietal fibers of the visual radiation, with macular sparing.

Lesions of the lingula are similar to lesions of the Meyer's loop fibers except for the presence of macular sparing. The pupillary light reflex is spared in lesions of the radiations or inside visual cortex because fibers of the pupillary light reflex leave the optic tracts to terminate in the pretectal area. The combination of blindness with intact pupillary reflexes is termed cortical blindness.

VISUAL REFLEXES

Pupillary Light Reflex

When light is directed into an eye, it stimulates retinal photoreceptors and results in impulses carried in the optic nerve to the pretectal area. Cells in the pretectal area send axons to the Edinger-Westphal nuclei on both sides.

The Edinger-Westphal nucleus is the parasympathetic nucleus of the oculomotor nerve and gives rise to preganglionic parasympathetic fibers that pass in the third cranial nerve to the ciliary ganglion. Because cells in the pretectal area supply both Edinger-Westphal nuclei, shining light into one eye results in constriction of both the ipsilateral pupil (direct light reflex) and contralateral pupil (consensual light reflex).

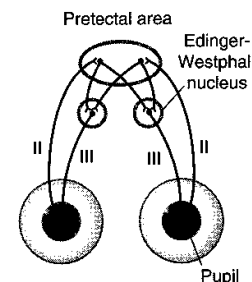
Accommodation-Convergence Reaction

This reaction occurs when an individual attempts to focus on a nearby object after looking at a distant object. The oculomotor nerve carries the efferent fibers from the accommodation-convergence reaction, which consists of three components, accommodation, convergence, and pupillary constriction.

Accommodation refers to the reflex that increases the curvature of the lens needed for near vision. Preganglionic parasympathetic fibers arise in the Edinger-Westphal nucleus and pass via the oculomotor nerve to the ciliary ganglion. Postganglionic parasympathetic fibers from the ciliary ganglion supply the ciliary muscle. Contraction of this muscle relaxes the suspensory ligaments and

Note

Lesions to the visual radiations are more common than lesions to the optic tract.



allows the lens to increase its convexity (become more round). This increases the refractive index of the lens, permitting the image of a nearby object to focus on the retina.

Convergence results from contraction of both medial rectus muscles, which pull the eyes to look toward the nose. This allows the image of the near object to focus on the same part of the retina in each eye.

Pupillary constriction (miosis) results from contraction of the constrictor muscle of the iris. A smaller aperture gives the optic apparatus a greater depth of field. With Argyll Robertson pupils, both direct and consensual light reflexes are lost, but the accommodation-convergence reaction remains intact. This type of pupil is often seen in cases of neurosyphilis; however, it is sometimes seen in patients with multiple sclerosis, pineal tumors, or tabes dorsalis. The lesion site is believed to occur near the pretectal nuclei just rostral to the superior colliculi.

Chapter Summary

The eyeball is formed by three layers: the sclera, choroid, and retina. The shape of the lens is modified for near and far vision by the ciliary muscle during the accommodation reflex. The sclera is the external layer and continues anteriorly as the cornea, which is transparent and allows light to enter the eye. The intermediate choroid layer is highly vascularized and pigmented. Anteriorly, the choroid layer forms the ciliary body and iris. The retina contains the photoreceptive layer of rods (for night vision and dim light) and cones (for color vision and high visual acuity).

The axons of the ganglionic cells of the retina form the optic nerve at the optic disc.

The visual pathway is a three-neuron pathway with the first neuron (bipolar neurons) and the second neuron (ganglionic neurons) located in the retina. The ganglionic axons project from the retina through the optic nerve, optic chiasm, and optic tract to synapse with the third neuron located in the lateral geniculate body of the thalamus. These thalamic axons then project via the optic radiations (geniculocalcarine tract) in the parietal lobe to reach the primary visual (striate) cortex at the posterior pole of the occipital lobe. Because the lens inverts images like a camera, each nasal retina receives information from the temporal visual fields, and each temporal retina receives information from the nasal visual field. At the optic chiasm, the fibers from the nasal half of each retina decussate while the optic fibers from the temporal half of each retina pass through the chiasm without decussating. Thus, central to the chiasm ipsilateral visual fields project through the contralateral visual pathways. Lesions at the lateral aspect of the optic chiasm produce ipsilateral nasal hemianopsia, whereas midline lesions at the chiasm produce bitemporal heteronymous hemianopsia. Any lesion central to the chiasm results in contralateral homonymous hemianopsia.

In addition, visual pathways carry optic fibers from the superior and inferior quadrants of the visual fields through the retina to the lateral geniculate body. The projections of the superior quadrants to the lower retina reach the lateral geniculate body laterally, synapse, and leave through the lateral course of Meyer loop in the temporal lobe before rejoining the optic radiation to reach the lower (lingual) gyrus of the striate cortex. Thus, lesions of the temporal lobe affecting Meyer loop result in contralateral homonymous superior quadrantanopia. Inferior quadrants of the visual fields project to the upper retina and then to the medial aspect of the lateral geniculate body. After synapsing in the geniculate body, the axons project completely through the optic radiations to reach the upper (cuneus) gyrus of the striate cortex. Lesions of these more medial fibers produce contralateral homonymous inferior quadrantanopia. Vascular lesions of the striate cortex due to occlusion of the posterior cerebral artery result in contralateral homonymous hemianopia with macular sparing.

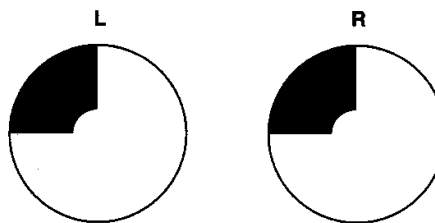
Review Questions

1. An aneurysm that has been detected at the juncture of the anterior cerebral artery and the anterior communicating artery on the right has caused a visual field defect. What might visual field testing reveal?
 - (A) Macular sparing
 - (B) A right nasal hemianopsia
 - (C) A left homonymous hemianopsia with macular sparing
 - (D) A bitemporal inferior quadrantanopsia
 - (E) A left homonymous inferior quadrantanopsia
2. A 63-year-old laborer was brought to the company doctor by a co-worker who found him wandering aimlessly around the parking lot. The driver had no recollection of how he came to be there. The last thing he remembered was that he was riding to work when he smelled something burning; then he remembered seeing large trucks running up and down the road. The driver was immediately admitted to a hospital where he began suffering from epileptic seizures and olfactory hallucinations. A neurological examination also revealed a visual field deficit. The deficit most likely was
 - (A) a homonymous hemianopsia
 - (B) an inferior quadrantanopsia with macular sparing
 - (C) psychic blindness
 - (D) anopsia
 - (E) a superior quadrantanopsia
3. Your patient comes to your office complaining of fuzzy vision and pain in the left eye. When light is presented to the right eye, both pupils constrict; when light is immediately presented to the left eye, the left pupil paradoxically dilates. You suspect that the patient has
 - (A) Argyll Robertson pupils
 - (B) left optic neuritis
 - (C) internuclear ophthalmoplegia
 - (D) Horner syndrome
 - (E) a lesion in the ciliary ganglion
4. Your patient has polyuria and develops secondarily amenorrhea at age 25. She tells you that she frequently has headaches that do not respond to over-the-counter analgesics. An MRI reveals that the patient has a partially calcified supratentorial tumor, and her neurological exam reveals a visual field deficit. Their visual problem most likely is
 - (A) an anopsia
 - (B) an inferior quadrantanopsia
 - (C) a homonymous hemianopsia with macular sparing
 - (D) a bitemporal heteronymous hemianopsia
 - (E) a superior quadrantanopia

5. The probable embryonic origin of the tumor in this case is from a remnant of
 - (A) endoderm cells
 - (B) ectoderm cells
 - (C) neural crest cells
 - (D) neural tube cells
 - (E) mesoderm cells

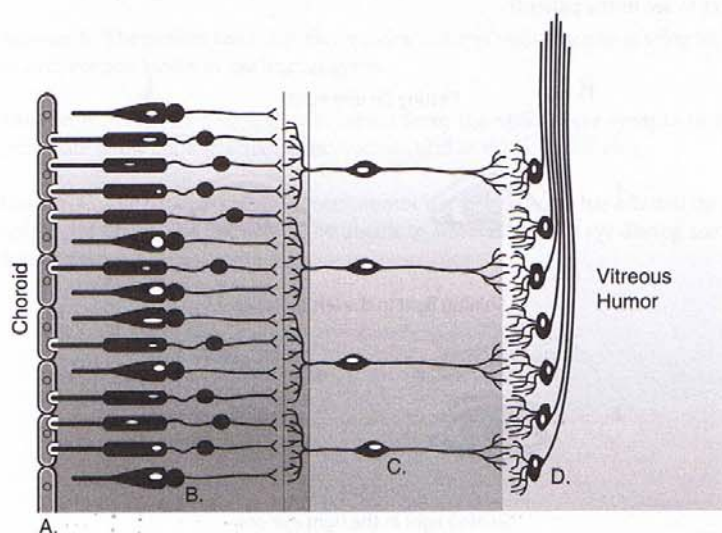
6. An older man wakes up with a headache and can no longer see things off to his left with either eye. Pupillary light reflexes are intact bilaterally, and visual field testing reveals a hemianopsia with no macular sparing. You suspect a lesion of the
 - (A) optic tract
 - (B) visual radiations
 - (C) Meyer's loop
 - (D) optic nerve
 - (E) lingual gyrus

7. Your patient has been diagnosed with the visual field deficit indicated below. Where is the lesion?



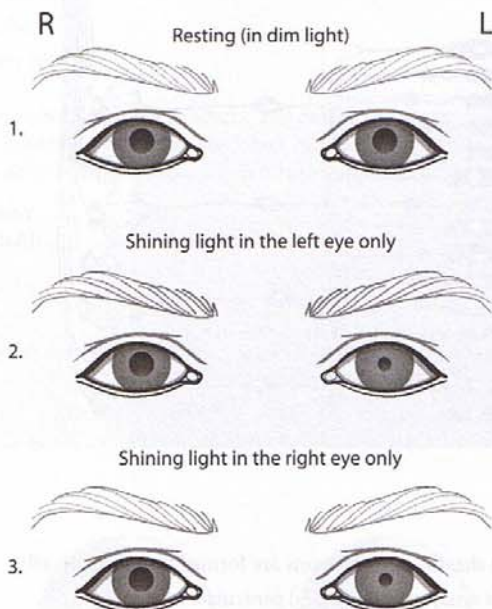
- (A) Meyer loop
- (B) Lingual gyrus
- (C) Cuneus gyrus
- (D) Lateral geniculate body
- (E) Optic tract

8. In the figure below, what is a feature of the cells at "D"?



- (A) The myelin sheaths of their axons are formed by Schwann cells.
- (B) Their axons synapse in the lateral geniculate body.
- (C) They are found in the outer nuclear layer of the retina.
- (D) They are derived from neural crest cells.
- (E) They take up vitamin A from the blood.

9. As part of a neurological exam on your patient, pupillary light reflex testing reveals the findings shown in the figure below. On the basis of these results, what else might you expect to see in the patient?



- (A) Anhydrosis on the left side of the face
- (B) Ptosis of the left upper eyelid
- (C) Inability to adduct the right eye during convergence
- (D) Inability to look down and out with the right eye
- (E) Loss of sensation in skin of the forehead

Answers and Explanations

1. **Answer: D.** Aneurysms in this location compress fibers in the superior aspect of the optic chiasm that carry information from the lower temporal quadrants, resulting in a bitemporal inferior quadrantanopsia.
2. **Answer: E.** Temporal lobe problems may combine seizures with olfactory hallucinations and affect fibers in Meyer's loop, resulting in a contralateral superior quadrantanopsia.
3. **Answer: B.** Optic nerve lesions result in a relative afferent pupillary defect, which is demonstrated using the swinging flashlight test.
4. **Answer: D.** The patient has a craniopharyngioma, which compresses the optic chiasm and results in a bitemporal heteronymous hemianopsia.
5. **Answer: B.** Craniopharyngiomas arise from remnants of the oral ectoderm of Rathke's pouch.

6. **Answer: B.** Lesions in the optic radiations result in homonymous hemianopsias with no macular sparing and light reflexes that are intact.
7. **Answer: B.** The patient has a superior quadrantanopia with macular sparing indicative of an intracortical lesion in the lingual gyrus.
8. **Answer: B.** Axons of ganglion cells, which form the optic nerve synapse in the lateral geniculate body, the suprachiasmatic nucleus, and in the pretectal area.
9. **Answer: C.** The patient has a right oculomotor nerve lesion that has affected the pupillary constrictor fibers. The patient will be unable to adduct the right eye during accommodation or gaze.

Diencephalon

8

The diencephalon can be divided into four parts: the thalamus, the hypothalamus, the epithalamus, and the subthalamus.

THALAMUS

The thalamus serves as the major sensory relay for the ascending tactile, visual, auditory, and gustatory information that ultimately reaches the neocortex. Motor control areas such as the basal ganglia and cerebellum also synapse in thalamic nuclei before they reach their cortical destinations. Other nuclei participate in the regulation of states of consciousness.

Major Thalamic Nuclei and Their Inputs and Outputs

Anterior nuclear group (part of the Papez circuit of limbic system)

Input is from the mammillary bodies via the mammillothalamic tract and from the cingulate gyrus; output is to the cingulate gyrus via the anterior limb of the internal capsule.

Medial nuclear group (part of limbic system)

Input is from the amygdala, prefrontal cortex, and temporal lobe; output is to the prefrontal cortex and cingulate gyrus. The most important nucleus is the dorsomedial nucleus.

Ventral nuclear group

Motor Nuclei

Ventral anterior nucleus (VA): Input to VA is from the globus pallidus, substantia nigra. Output is to the premotor and primary motor cortex.

Ventral lateral nucleus (VL): Input to VL is mainly from the globus pallidus and the dentate nucleus of the cerebellum. Output is to the primary motor cortex (Brodmann area 4).

Sensory Nuclei

Ventral posterolateral (VPL) nucleus: Input to VPL conveying somatosensory and nociceptive information ascends in the medial lemniscus and spinothalamic tract. Output is to primary somatosensory cortex (Brodmann areas 3, 1, and 2) of the parietal lobe.

Ventral posteromedial (VPM) nucleus: Input to VPM is from the ascending trigeminal pathways. Output is to primary somatosensory cortex (Brodmann areas 3, 1, and 2) of the parietal lobe.

Medial geniculate body (nucleus): Input is from auditory information that ascends from the inferior colliculus. Output is to primary auditory cortex.

Clinical Correlate

Thiamine deficiency in alcoholics results in degeneration of the dorsomedial nucleus of thalamus and the mammillary bodies, hippocampus, and vermis of the cerebellum (see Chapter 10).

Clinical Correlate

Thalamic pain syndrome affects the ventral nuclear group. Patients present with burning, aching pain in contralateral limbs or body. Involvement of the DC/ML part of VPL increases the sensitivity to pain and presents as contralateral loss of vibratory sense and gait ataxia. Thalamic pain syndrome is resistant to analgesic medications.

Lateral geniculate body (nucleus): Input is from the optic tract. Output is in the form of the geniculocalcarine or visual radiations that project to the primary visual (striate) cortex in the occipital lobe.

Midline and Intralaminar Nuclei

Midline and intralaminar nuclei receive input from the brain stem reticular formation, and from the spinothalamic tract. Intralaminar nuclei send pain information to the cingulate gyrus.

These nuclei appear to be important in mediating desynchronization of the electroencephalogram (EEG) during behavioral arousal.

HYPOTHALAMUS

The hypothalamus is composed of numerous nuclei that have afferent and efferent connections with widespread regions of the nervous system, including the pituitary gland, the autonomic system, and the limbic system (Figure IV-8-1).

Major Hypothalamic Regions or Zones, and Their Nuclei

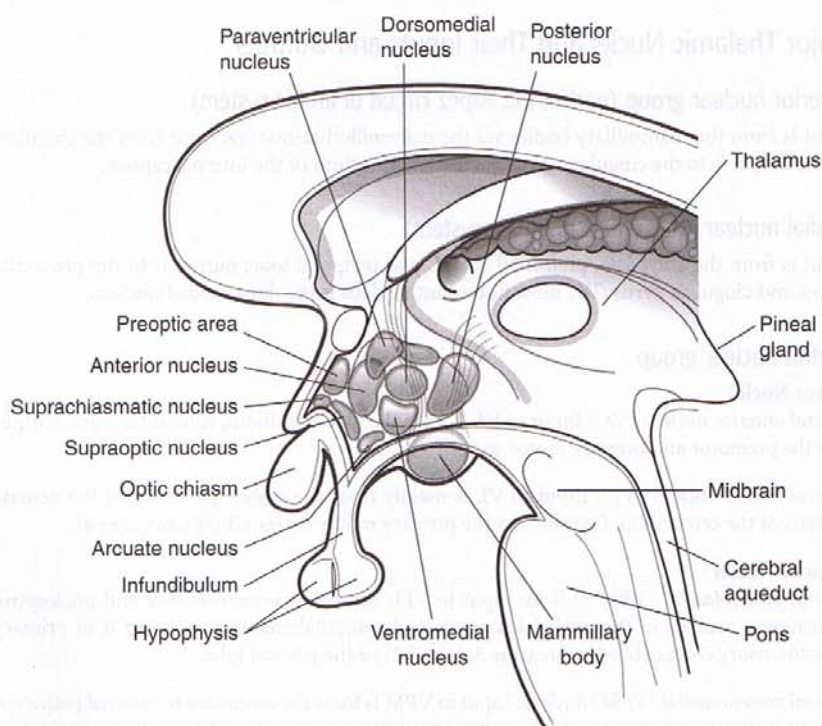


Figure IV-8-1. The Hypothalamic Nuclei

Anterior region

Paraventricular and Supraoptic Nuclei

These nuclei synthesize the neuropeptides antidiuretic hormone (ADH) and oxytocin. Axons arising from these nuclei leave the hypothalamus and course in the supraopticohypophysial tract, which carries neurosecretory granules to the posterior pituitary gland, where they are released into capillaries. Lesions of the supraoptic nuclei lead to diabetes insipidus, which is characterized by polydipsia (excess water consumption) and polyuria (excess urination).

Suprachiasmatic Nucleus

Visual input from the retina by way of the optic tract terminates in the suprachiasmatic nucleus. This information helps set certain body rhythms to the 24-hour light-dark cycle (circadian rhythms).

Tuberal region

Arcuate Nucleus

Cells in the arcuate nucleus produce releasing hormones and inhibitory factors, which enter capillaries in the tuberoinfundibular tract and pass through the hypophyseal-portal veins to reach the secondary capillary plexus in the anterior pituitary gland. Releasing hormones and inhibitory factors influence the secretory activity of the acidophils and basophils in the anterior pituitary. (See Histology section.)

Ventromedial Nucleus

The ventromedial hypothalamus is a satiety center and regulates food intake. Lesions of the ventromedial hypothalamus result in obesity.

Posterior region

Mammillary Bodies

The mammillary nuclei are located in the mammillary bodies and are part of the limbic system. The mammillothalamic tract originates in the mammillary nuclei and terminates in the anterior nuclear group of the thalamus.

Anterior hypothalamic zone

The anterior hypothalamic zone senses an elevation of body temperature and mediates the response to dissipate heat. Lesions of the anterior hypothalamus lead to hyperthermia.

Posterior hypothalamic zone

The posterior hypothalamic zone senses a decrease of body temperature and mediates the conservation of heat. Lesions of the posterior hypothalamus lead to poikilothermy (i.e., cold-blooded organisms). An individual with a lesion of the posterior hypothalamus has a body temperature that varies with the environmental temperature.

Lateral hypothalamic zone

The lateral hypothalamic zone is a feeding center; lesions of the lateral hypothalamus produce severe aphagia.

Clinical Correlate

Dopaminergic projections from the arcuate nuclei inhibit prolactin secretion from the anterior pituitary. Lesions result in galactorrhea (milk discharge) and amenorrhea.

Clinical Correlate

Korsakoff Syndrome

Lesions of the mammillary bodies occur in Korsakoff syndrome and are usually associated with thiamine deficiency associated with chronic alcoholism. Korsakoff syndrome results in both anterograde and retrograde amnesia with confabulations.

Clinical Correlate

Precocious Puberty

In young males, pineal lesions may cause precocious puberty.

Pineal Tumors

Pineal tumors may cause obstruction of CSF flow and increased intracranial pressure. Compression of the upper midbrain and pretectal area by a pineal tumor results in Parinaud syndrome, in which there is impairment of conjugate vertical gaze and pupillary reflex abnormalities.

Preoptic area

The preoptic area is sensitive to androgens and estrogens, whereas other areas influence the production of sex hormones through their regulation of the anterior pituitary. Before puberty, hypothalamic lesions here may arrest sexual development.

After puberty, hypothalamic lesions in this area may result in amenorrhea or impotence.

EPITHALAMUS

The epithalamus is the part of the diencephalon located in the region of the posterior commissure that consists of the pineal body and the habenular nuclei.

The pineal body is a small, highly vascularized structure situated above the posterior commissure and attached by a stalk to the roof of the third ventricle.

The pineal body contains pinealocytes and glial cells but no neurons. Pinealocytes synthesize melatonin, serotonin, and cholecystokinin.

The pineal gland plays a role in growth, development, and the regulation of circadian rhythms.

Environmental light regulates the activity of the pineal gland through a retinal–suprachiasmatic–pineal pathway.

The subthalamus is reviewed with the basal ganglia.

Chapter Summary

The diencephalon is divided into four parts: thalamus, hypothalamus, epithalamus, and the subthalamus.

The thalamus is the major sensory relay for many sensory systems. The long tracts of spinal cord and the trigeminal system synapse in the ventral posterolateral (VPL) and ventral posteromedial (VPM) nuclei, respectively. Auditory input is to the medial geniculate body, and the visual input is to the lateral geniculate body. Motor projections from the basal ganglia and cerebellum synapse in the ventral anterior and ventral lateral nuclei.

The hypothalamus contains nuclei that have fiber connections with many areas of the nervous system, including the pituitary gland in the anterior and tuberal regions of the hypothalamus. Other areas control eating, drinking, body temperature, and provide connections with the limbic system.

The epithalamus consists mainly of the pineal gland, which plays a major role in the regulation of circadian rhythms.

The subthalamic projections are important circuits related to the basal ganglia.

Review Questions

1. A patient has trouble sleeping due to a decreased production of melatonin. What neural structure influences melatonin synthesis at night?
 - (A) Preoptic nuclei
 - (B) Lateral geniculate body
 - (C) Suprachiasmatic nucleus
 - (D) Supraoptic nucleus
 - (E) Neurohypophysis
2. Which of the following thalamic nuclei is correctly matched with its function?
 - (A) Ventral posterior lateral/motor planning
 - (B) Ventral lateral/somatosensory
 - (C) Medial geniculate/auditory processing
 - (D) Anterior/language processing
 - (E) Ventral posterior medial/fine tuning of skeletal muscles
3. An MRI reveals the presence of a tumor in the third ventricle compressing the arcuate nuclei of the hypothalamus. Which of the following is the patient most likely to present with?
 - (A) Altered circadian rhythms
 - (B) Aphagia
 - (C) Galactorrhea and amenorrhea
 - (D) Diabetes insipidus
 - (E) Amnesia with confabulations
4. Your patient has a sense of fullness after a meal. What part of the hypothalamus is responding normally?
 - (A) Preoptic area of hypothalamus
 - (B) Lateral zone of hypothalamus
 - (C) Periventricular nuclei of hypothalamus
 - (D) Ventromedial nuclei of hypothalamus
 - (E) Mammillary body

Answers and Explanations

1. **Answer: C.** The suprachiasmatic nucleus utilizes retinal input to control circadian rhythms in part by influencing the pineal to cyclically produce serotonin and melatonin.
2. **Answer: D.** The medial geniculate nucleus is involved in auditory processing.
3. **Answer: C.** Lesions of the arcuate nuclei may result in increased prolactin output from the adenohypophysis due to a loss of an inhibitory influence from dopaminergic cells in the arcuate nuclei.
4. **Answer: D.** The fullness or satiety center of the diencephalon is the ventromedial nucleus of the hypothalamus.

Basal Ganglia

9

GENERAL FEATURES

The basal ganglia initiate and provide gross control over skeletal muscle movements. The major components of the basal ganglia include:

- Striatum, which consists of the caudate nucleus and the putamen
- External and internal segments of the globus pallidus
- Substantia nigra (in midbrain)
- Subthalamic nucleus (in diencephalon)

Together with the cerebral cortex and the VL nucleus of the thalamus, these structures are interconnected to form two parallel but antagonistic circuits known as the direct and indirect basal ganglia pathways (Figures IV-9-1 and IV-9-2). Both pathways are driven by extensive inputs from large areas of cerebral cortex, and both project back to the motor cortex after a relay in the VL nucleus of the thalamus. Both pathways use a process known as “disinhibition” to mediate their effects, whereby one population of inhibitory neurons inhibits a second population of inhibitory neurons.

Direct Basal Ganglia Pathway

In the direct pathway, excitatory input from the cerebral cortex projects to striatal neurons in the caudate nucleus and putamen. Through disinhibition, activated inhibitory neurons in the striatum, which use γ -aminobutyric acid (GABA) as their neurotransmitter, project to and inhibit additional GABA neurons in the internal segment of the globus pallidus.

The GABA axons of the internal segment of the globus pallidus project to the thalamus (VL). Because their input to the thalamus is disinhibited, the thalamic input excites the motor cortex. The net effect of the disinhibition in the direct pathway results in an **increased** level of cortical excitation and the promotion of movement.

Indirect Basal Ganglia Pathway

In the indirect pathway, excitatory input from the cerebral cortex also projects to striatal neurons in the caudate nucleus and putamen. These inhibitory neurons in the striatum, which also use GABA as their neurotransmitter, project to and inhibit additional GABA neurons in the external segment of the globus pallidus.

The GABA axons of the external segment of the globus pallidus project to the subthalamic nucleus. Through disinhibition, the subthalamic nucleus excites inhibitory GABA neurons in the internal segment of the globus pallidus, which inhibits the thalamus. This decreases the level of cortical excitation, inhibiting movement. The net effect of the disinhibition in the indirect pathway results in a **decreased** level of cortical excitation.

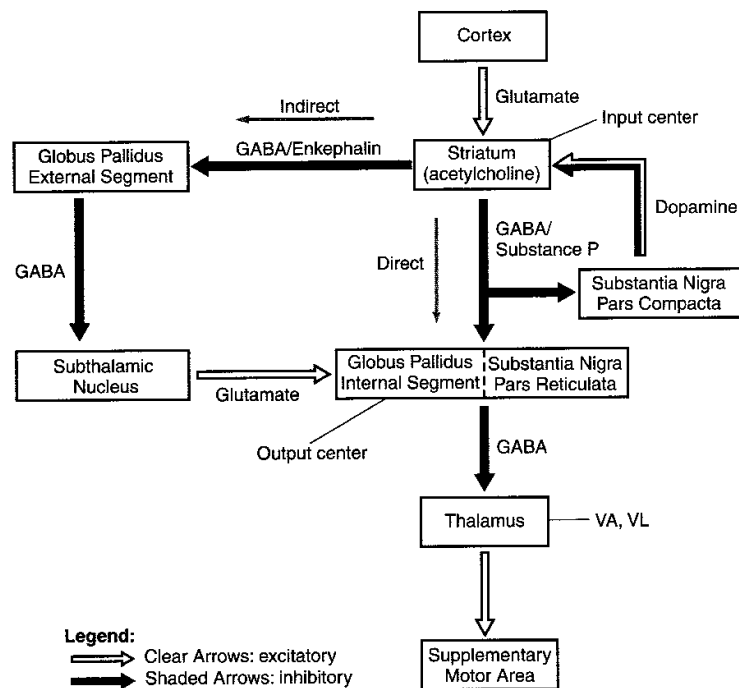


Figure IV-9-1. Direct and Indirect Basal Ganglia Pathways

Dopamine and cholinergic effects

In addition to the GABA neurons, two other sources of chemically significant neurons enhance the effects of the direct or indirect pathways.

Dopaminergic neurons in the substantia nigra in the midbrain project to the striatum. The effect of dopamine excites or drives the direct pathway, increasing cortical excitation. Dopamine excites the direct pathway through D_1 receptors and inhibits the indirect pathway through D_2 receptors.

Cholinergic neurons found within the striatum have the opposite effect. Acetylcholine drives the indirect pathway, decreasing cortical excitation.

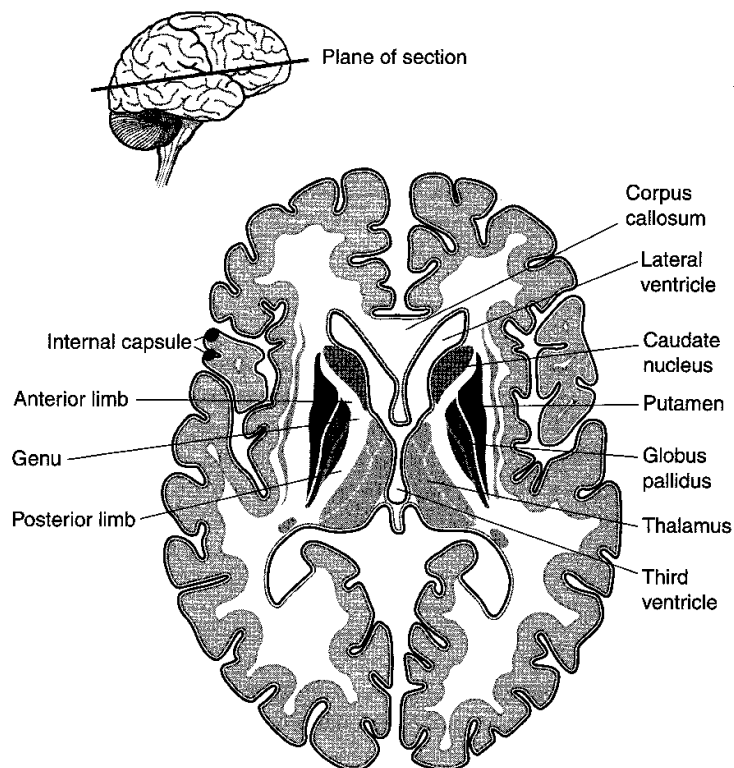


Figure IV-9-2. The Basal Ganglia

Table IV-9-1. Basal Ganglia—Clinicopathologic Correlations

Movement Disorder	Lesion
Chorea: multiple quick, random movements, usually most prominent in the appendicular muscles	Atrophy of the striatum . Huntington chorea.
Athetosis: slow, writhing movements, which are usually more severe in the appendicular muscles	Diffuse hypermyelination of the corpus striatum and thalamus cerebral palsy.
Hemiballismus: wild flinging movements of half of the body	Hemorrhagic destruction of the contralateral subthalamic nucleus . Hypertensive patients.
Parkinsonism: pill-rolling tremor of the fingers at rest, lead-pipe rigidity, and akinesia	Degeneration of the substantia nigra

Clinical Correlate

Lesions or Diseases of the Basal Ganglia

Lesions or diseases of the basal ganglia generally present with movement disorders, known as dyskinesias, and an involuntary tremor, or tremor at rest.

Most basal ganglia disorders seem to preferentially affect either the direct or the indirect pathways, altering the balance between the two.

Lesions of the direct pathway

Lesions of the direct pathway result in an underactive cortex and hypokinetic disturbances in which there is a slowing or absence of spontaneous movements. The best known disorder of the direct pathway is caused by the degeneration of dopaminergic neurons of the substantia nigra in Parkinson disease. Because the cortex is underactive, Parkinson patients have problems initiating movements, combined with a reduction in the velocity and amplitude of the movements. The tremor at rest is the classic pill rolling tremor seen in the fingers. Skeletal muscles in the upper limbs exhibit a cog wheel rigidity because of increased muscle tone. Patients also present with a stooped posture, an expressionless face, and a festinating or accelerating gait during which individuals seem to chase their center of gravity. One strategy for Parkinson patients is to give them L-dopa, a dopamine precursor that crosses the blood-brain barrier. Another strategy is to give anticholinergic drugs to inhibit the effects of acetylcholine on the indirect pathway.

Lesions of the indirect pathway

Other common disorders of the basal ganglia (chorea, athetosis, dystonia, tics) result from lesions to parts of the indirect pathway, which result in an overactive motor cortex. An overactive cortex produces hyperkinetic disturbances, expressed in numerous spontaneous movements. The involuntary tremors seen in these diseases range from being dancelike in chorea to ballistic with lesions to the subthalamic nucleus.

Chorea produces involuntary movements that are purposeless, quick jerks that may be superimposed on voluntary movements. Huntington chorea exhibits autosomal dominant inheritance (chromosome 4) and is characterized by severe degeneration of GABA neurons in the striatum. In addition to chorea, these patients frequently suffer from athetoid movements, progressive dementia, and behavioral disorders. Sydenham chorea is a transient complication in some children with rheumatic fever.

Athetosis refers to slow, wormlike, involuntary movements that are most noticeable in the fingers and hands but may involve any muscle group. It is present in Huntington disease and may be observed in many diseases that involve the basal ganglia.

Dystonia refers to a slow, prolonged movement involving predominantly the truncal musculature. Dystonia often occurs with athetosis. Blepharospasm (contraction of the orbicularis oculi causing the eyelids to close), spasmodic torticollis (in which the head is pulled toward the shoulder), and writer's cramp (contraction of arm and hand muscles on attempting to write) are all examples of dystonic movements.

Hemiballismus results from a lesion of the subthalamic nucleus usually seen in hypertensive patients. Hemiballismus refers to a violent projectile movement of a limb and is typically observed in the upper limb contralateral to the involved subthalamic nucleus.

(Continued)

Clinical Correlate (continued)

Tourette syndrome involves facial and vocal tics that progress to jerking movements of the limbs. It is frequently associated with explosive, vulgar speech.

Wilson disease results from an abnormality of copper metabolism, causing the accumulation of copper in the liver and basal ganglia. Personality changes, tremor, dystonia, and athetoid movements develop. Untreated patients usually succumb because of hepatic cirrhosis. A thin brown ring around the outer cornea, the Kayser-Fleischer ring, may be present and aid in the diagnosis.

Chapter Summary

The basal ganglia play important motor functions in starting and stopping voluntary motor functions and inhibiting unwanted movements. The basal ganglia consists of three nuclei masses deep in the cerebrum (caudate nucleus, putamen, and globus pallidus), one nucleus in the midbrain (substantia nigra), and the subthalamic nucleus of the diencephalon. The striatum combines the caudate nucleus and the putamen while the corpus striatum consists of these two nuclei plus the globus pallidus.

There are two parallel circuits (direct and indirect) through the basal ganglia. These circuits receive extensive input from the cerebral cortex that project back to the motor cortex after a relay in the VL nucleus of the thalamus. Both of these pathways demonstrate disinhibition. The direct pathway increases the level of cortical excitation and promotes movement. The indirect pathway decreases the level of cortical excitation and stops movement.

The striatum is the major input center and the globus pallidus is the major output center for the pathways through the basal ganglia. Critical to proper function of the striatum is dopamine production by the substantia nigra. Dopamine excites the direct pathway and inhibits the indirect pathway.

Lesions of the direct pathway result in an underactive cortex, which produces hypokinetic motor disturbances. The classic disorder caused by degeneration of dopaminergic neurons of the substantia nigra is Parkinson disease. These patients are characterized by tremor at rest (pill-rolling), increased muscle tone, mask face, and hypokinetic movement.

Hyperkinetic disorders result from lesions of the indirect pathway and cause an overactive motor cortex. These movements occur spontaneously at rest and cannot be controlled by the patient. Examples of these disorders include chorea (multiple quick movements), athetosis (slow serpentine movements), and hemiballismus (violent flinging movements). Hemiballismus results from hemorrhagic destruction of the contralateral subthalamic nucleus.

Review Questions

1. Your patient has a stooped posture, shuffling gait, and a tremor in the fingers at rest. Which part of the brain will show neuronal degeneration?
 - (A) Metencephalon
 - (B) Diencephalon
 - (C) Mesencephalon
 - (D) Myelencephalon
 - (E) Telencephalon
2. Which neurotransmitter may be inhibited pharmacologically to reduce the effects seen in the patient in the previous case?
 - (A) GABA
 - (B) Dopamine
 - (C) Glutamate
 - (D) Glycine
 - (E) Acetylcholine
3. A hypertensive patient suddenly develops violent flinging involuntary movements in an upper limb. The patient is able to suppress the movements for brief periods. The patient has suffered a vascular insult affecting the
 - (A) globus pallidus
 - (B) caudate nucleus
 - (C) internal capsule
 - (D) subthalamic nucleus
 - (E) substantia nigra
4. A 47-year-old banker exhibits a personality change over a period of weeks. He becomes irritable and no longer seems to be getting along at work. He exhibits jerky movements when trying to pick up a cup of coffee or hold a pen to write. The patient's wife recalls that the patient's mother died in her 60s of a progressive illness that started like her husband's. CT imaging reveals apparent degeneration of a neural structure situated medial to the anterior limb of the internal capsule, which normally protrudes into the lateral ventricle. The affected structure in this patient is the
 - (A) caudate nucleus
 - (B) globus pallidus
 - (C) corpus callosum
 - (D) thalamus
 - (E) putamen

Answers and Explanations

1. **Answer: C.** The mesencephalon (midbrain) contains the substantia nigra, which is the location of the degenerating dopaminergic neurons in Parkinson disease.
2. **Answer: E.** In Parkinson disease, loss of dopamine enhances the effects of the indirect basal ganglia pathway, which is also driven by cholinergic neurons intrinsic to the striatum. A muscarinic blocker will reduce the stimulatory effects of ACh on the indirect pathway.
3. **Answer: D.** The patient suffers from hemiballismus, which affects the neurons in the subthalamic nucleus.
4. **Answer: A.** The caudate nucleus is a major site of degeneration in Huntington disease.

Cerebral Cortex

10

The surface of the cerebral cortex is highly convoluted with the bulges or eminences referred to as gyri and the spaces separating the gyri called sulci (Figures IV-10-1 and IV-10-2). Lobes of the cerebrum are divided according to prominent gyri and sulci that are fairly constant in humans. Two prominent sulci on the lateral surface are key to understanding the divisions of the hemispheres. The lateral fissure (of Sylvius) separates the frontal and temporal lobes rostrally; further posteriorly, it partially separates the parietal and the temporal lobes. The central sulcus (of Rolando) is situated roughly perpendicular to the lateral fissure. The central sulcus separates the frontal and the parietal lobes. The occipital lobe extends posteriorly from the temporal and parietal lobes, but its boundaries on the lateral aspect of the hemisphere are indistinct. On the medial aspect of the hemisphere, the frontal and parietal lobes are separated by a cingulate sulcus from the cingulate gyrus. The cingulate is part of an artificial limbic lobe. Posteriorly, the parieto-occipital sulcus separates the parietal lobe from the occipital lobe. The calcarine sulcus divides the occipital lobe horizontally into a superior cuneus and an inferior lingual gyrus.

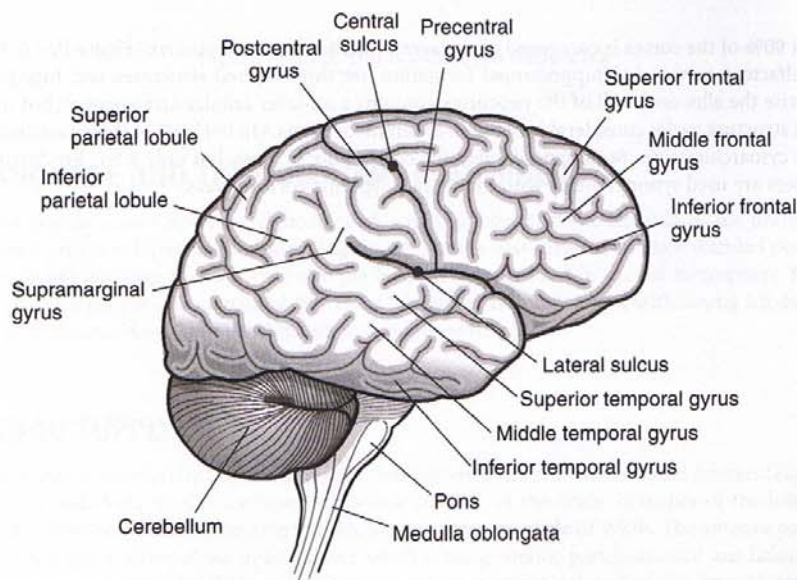


Figure IV-10-1. Lateral View of the Right Cerebral Hemisphere

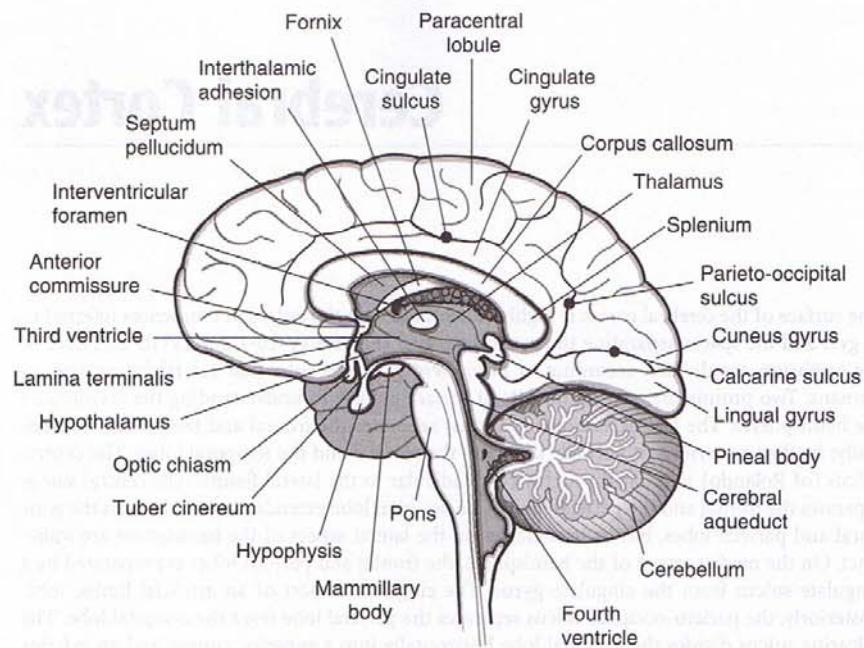


Figure IV-10-2. Medial View of the Right Cerebral Hemisphere

About 90% of the cortex is composed of six layers, which form the neocortex (Figure IV-10-3). The olfactory cortex and hippocampal formation are three-layered structures and together comprise the allocortex. All of the neocortex contains a six-layer cellular arrangement, but the actual structure varies considerably between different locations. On the basis of these variations in the cytoarchitecture, Brodmann divided the cortex into 47 areas, but only a few Brodmann numbers are used synonymously with functionally specific cortical areas.

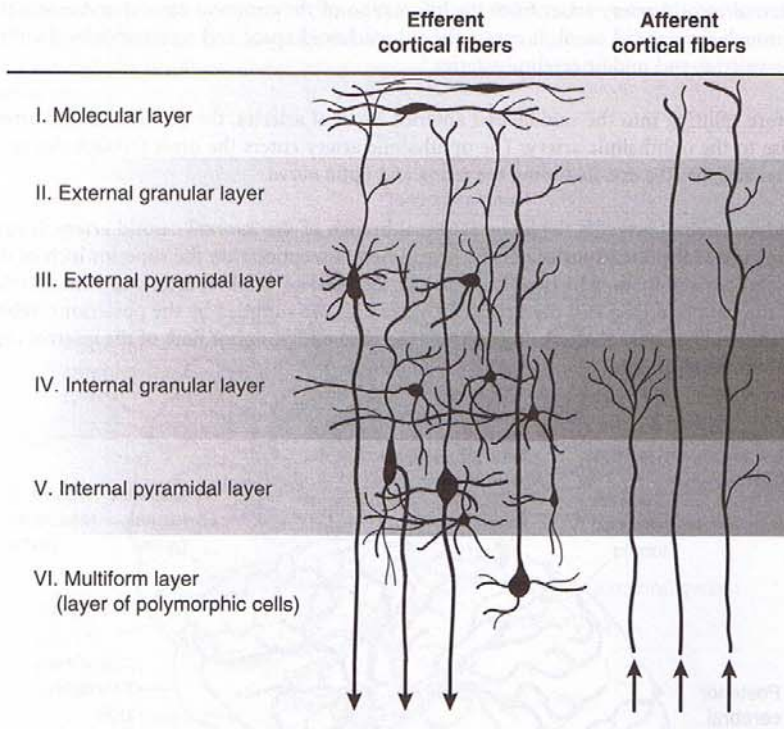


Figure IV-10-3. The Six-Layered Neocortex

LANGUAGE AND THE DOMINANT HEMISPHERE

Most people (about 80%) are right-handed, which implies that the left side of the brain has more highly developed hand-controlling circuits. In the vast majority of right-handed people, speech and language functions are also predominantly organized in the left hemisphere. Most left-handed people show language functions bilaterally, although a few, with strong left-handed preferences, show right-sided speech and language functions.

BLOOD SUPPLY

The cortex is supplied by the two internal carotid arteries and the two vertebral arteries (Figures IV-10-4 and IV-10-5). On the base (or inferior surface) of the brain, branches of the internal carotid arteries and the basilar artery anastomose to form the circle of Willis. The anterior part of the circle lies in front of the optic chiasm, whereas the posterior part is situated just below the mammillary bodies. The circle of Willis is formed by the terminal part of the internal carotid arteries; the proximal parts of the anterior and posterior cerebral arteries and the anterior and posterior communicating arteries. The middle, anterior, and posterior cerebral arteries, which arise from the circle of Willis, supply all of the cerebral cortex, basal ganglia, and diencephalon.

Note

The internal granular layer is the site of termination of the thalamocortical projections. In primary visual cortex, these fibers form a distinct Line of Gennari. The internal pyramidal layer gives rise to axons that form the corticospinal and corticobulbar tracts.

Clinical Correlate

Occlusion of the middle cerebral artery results in spastic paresis of the contralateral lower face and upper limb and anesthesia of the contralateral face and upper limb.

An aphasia (e.g., Broca, Wernicke, or conduction) may result when branches of the left middle cerebral artery are affected, and left-sided neglect may be seen with a blockage of branches of the right middle cerebral artery to the right parietal lobe.

The middle cerebral artery also supplies the proximal parts of the visual radiations as they emerge from the lateral geniculate nucleus of the thalamus and course in Meyer's loop. These fibers course into the temporal lobe before looping posteriorly to rejoin the rest of the visual radiation fibers.

Occlusion of the branches that supply Meyer's loop fibers in the temporal lobe results in a contralateral superior quadrantanopsia.

Note

The MCA supplies:

- the lateral surface of the frontal, parietal, and upper temporal lobes
- the posterior limb and genu of the internal capsule
- most of the basal ganglia

The internal carotid artery arises from the bifurcation of the common carotid and enters the skull through the carotid canal. It enters the subarachnoid space and terminates by dividing into the anterior and middle cerebral arteries.

Just before splitting into the middle and anterior cerebral arteries, the internal carotid artery gives rise to the ophthalmic artery. The ophthalmic artery enters the orbit through the optic canal and supplies the eye, including the retina and optic nerve.

The middle cerebral artery is the larger terminal branch of the internal carotid artery. It supplies the bulk of the lateral surface of the hemisphere. Exceptions are the superior inch of the frontal and parietal lobes, which are supplied by the anterior cerebral artery, and the inferior part of the temporal lobe and the occipital pole, which are supplied by the posterior cerebral artery. The middle cerebral artery also supplies the genu and posterior limb of the internal capsule and the basal ganglia.

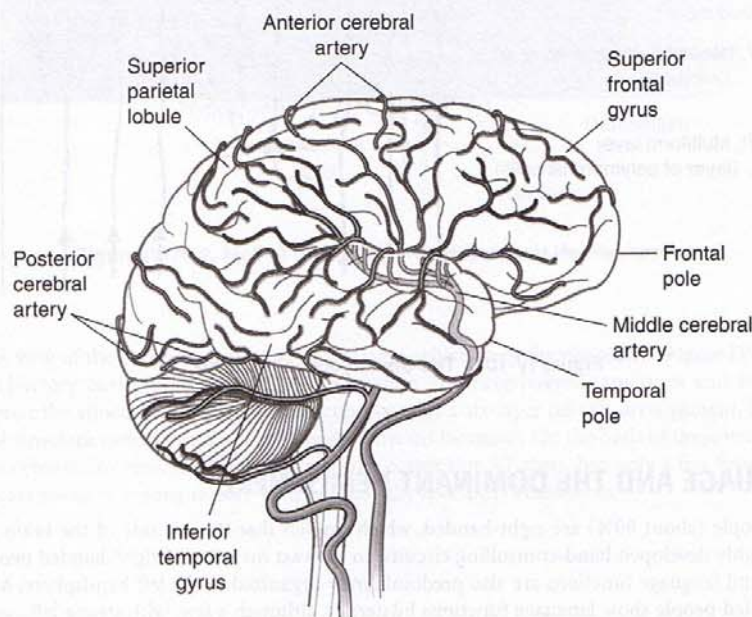


Figure IV-10-4. The Distributions of the Cerebral Arteries: I

The anterior cerebral artery is the smaller terminal branch of the internal carotid artery. It is connected to the opposite anterior cerebral artery by the anterior communicating artery, completing the anterior part of the circle of Willis. The anterior cerebral artery supplies the medial surface of the frontal and parietal lobes, which include motor and sensory cortical areas for the pelvis and lower limbs. The anterior cerebral artery also supplies the anterior four fifths of the corpus callosum and approximately 1 inch of the frontal and parietal cortex on the superior aspect of the lateral aspect of the hemisphere.

Occlusion of the anterior cerebral artery results in spastic paresis of the contralateral lower limb and anesthesia of the contralateral lower limb. Urinary incontinence may be present, but this usually occurs only with bilateral damage. A transcortical apraxia of the left limbs may result

from involvement of the anterior portion of the corpus callosum. A transcortical apraxia occurs because the left hemisphere (language dominant) has been disconnected from the motor cortex of the right hemisphere. The anterior cerebral artery also supplies the anterior limb of the internal capsule.

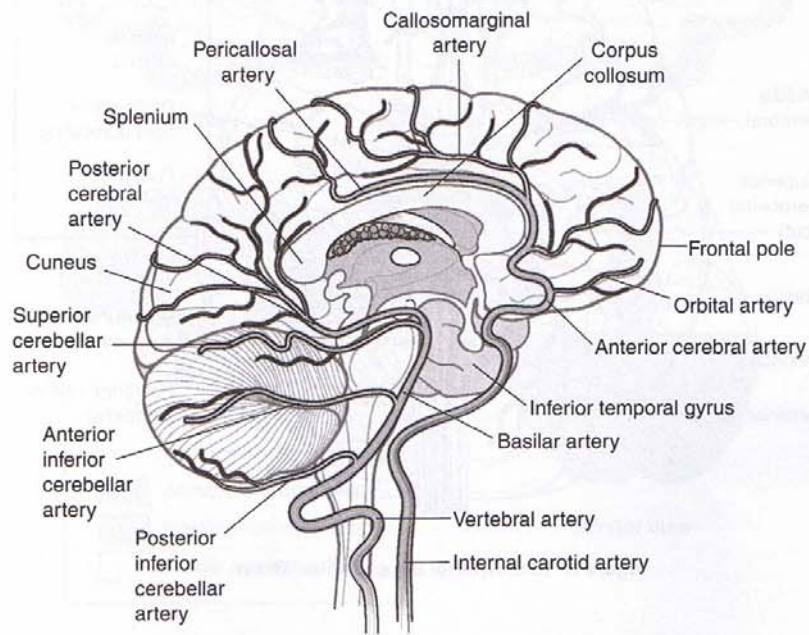


Figure IV-10-5. The Distributions of the Cerebral Arteries: II

Note

ICA Supplies:

1. Medial surface of frontal and parietal lobes
2. Anterior 4/5 of corpus callosum
3. Anterior limb of internal capsule

PCA Supplies:

1. Occipital lobe
2. Lower temporal lobe
3. Splenium
4. Midbrain

Clinical Correlate

The most common aneurysm site in the circle of Willis is where the anterior communicating artery joins an anterior cerebral artery.

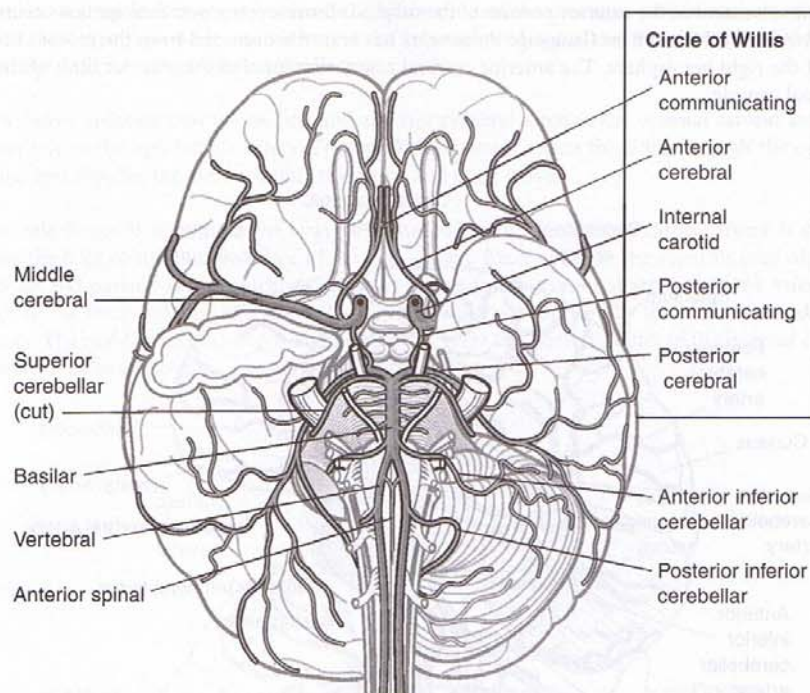


Figure IV-10-6. Arterial Supply of the Brain

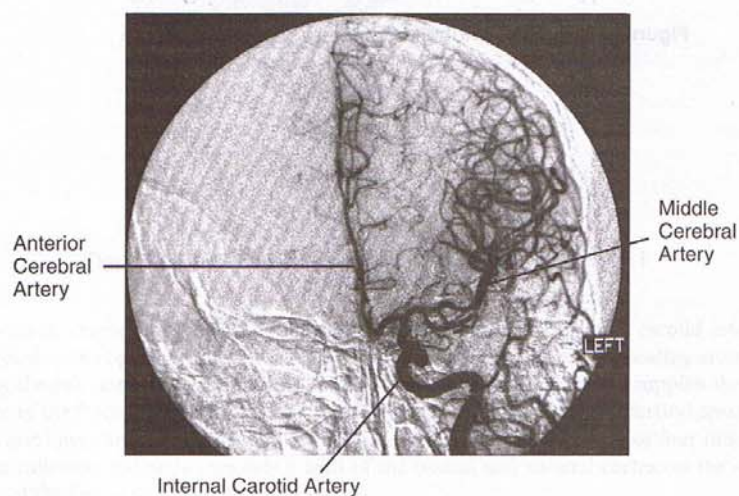


Figure IV-10-7. Anteroposterior View of Left Internal Carotid

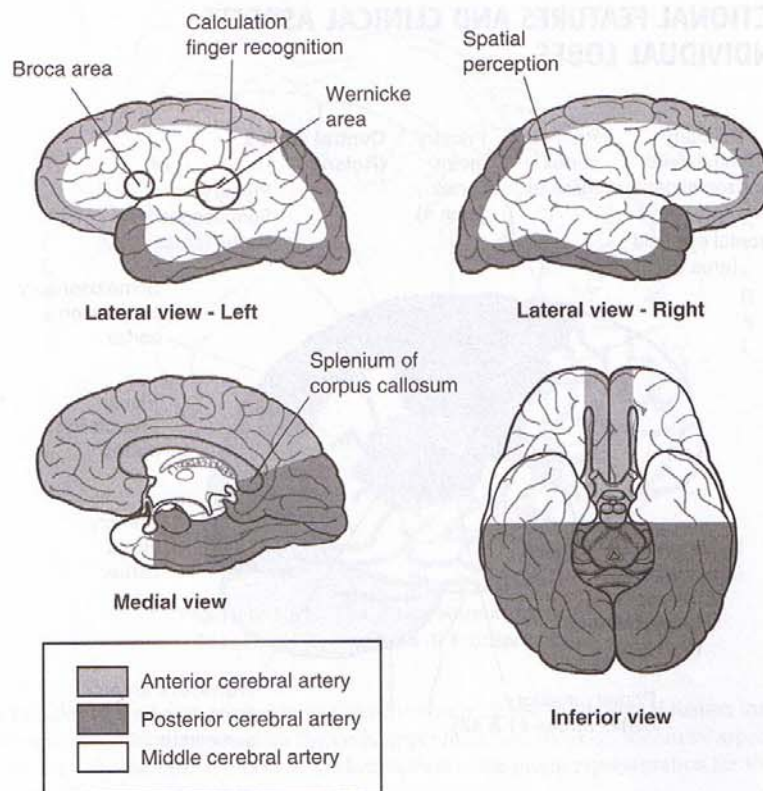


Figure IV-10-8. Territories Supplied by the Cerebral Arteries

The posterior cerebral artery is formed by the terminal bifurcation of the basilar artery. The posterior communicating artery arises near the termination of the internal carotid artery and passes posteriorly to join the posterior cerebral artery. The posterior communicating arteries complete the circle of Willis by joining the vertebrobasilar and carotid circulations. The posterior cerebral artery supplies the occipital and temporal cortex on the inferior and lateral surfaces of the hemisphere, the occipital lobe and posterior two thirds of the temporal lobe on the medial surface of the hemisphere, and the thalamus and subthalamic nucleus.

Occlusion of the posterior cerebral artery results in a homonymous hemianopia of the contralateral visual field with macular sparing.

FUNCTIONAL FEATURES AND CLINICAL ASPECTS OF INDIVIDUAL LOBES

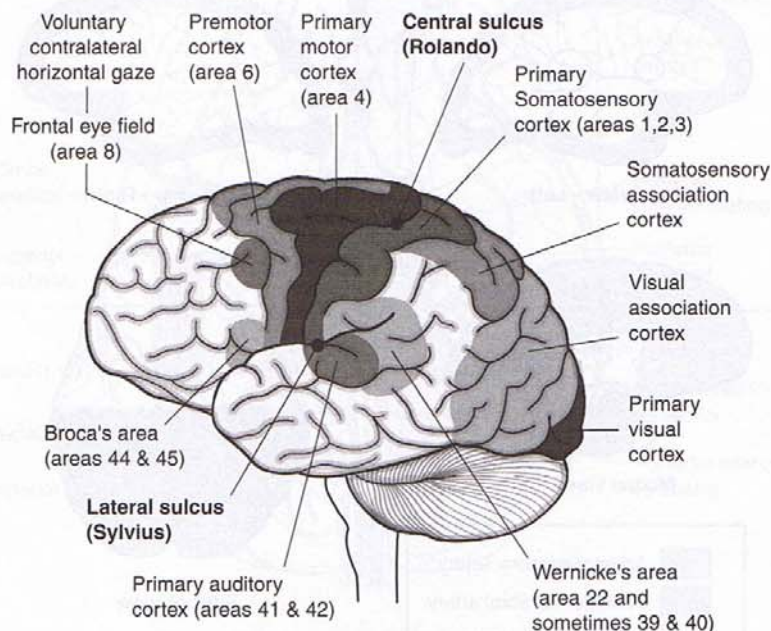


Figure IV-10-9. Cerebral Cortex: Functional Areas

Frontal Lobe

A large part of the frontal cortex rostral to the central sulcus is related to the control of movements, primarily on the opposite side of the body. These areas include primary motor cortex (Brodmann area 4), premotor cortex (area 6), the frontal eye field (area 8), and the motor speech areas of Broca (area 44 and 45). Traditionally, area 4 is considered the primary motor cortex. It is in the precentral gyrus, immediately anterior to the central sulcus, and contains an orderly skeletal motor map of the contralateral side of the body (Figure IV-10-10).

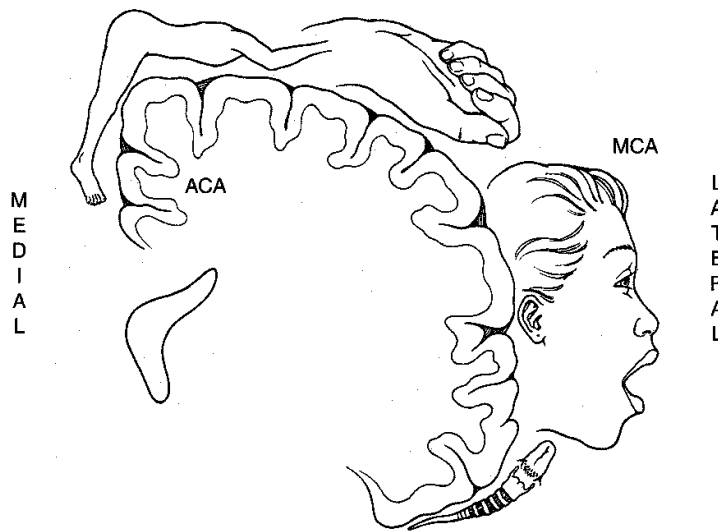


Figure IV-10-10. The Motor Homunculus in Precentral Gyrus (Area 4) Frontal Lobe

The muscles of the head are represented most ventrally closest to the lateral fissure, then, proceeding dorsally, are the regions for the neck, upper limb, and trunk on the lateral aspect of the hemisphere. On the medial aspect of the hemisphere is the motor representation for the pelvis and lower limb.

Premotor cortex

Just anterior to area 4 is the premotor cortex (area 6). Neurons here are particularly active prior to the activation of area 4 neurons, so it is thought that the premotor cortex is involved in the planning of motor activities. Damage here results in an apraxia, a disruption of the patterning and execution of learned motor movements. Individual movements are intact, and there is no weakness, but the patient is unable to perform movements in the correct sequence.

Prefrontal cortex

The prefrontal cortex is located in front of the premotor area and represents about a quarter of the entire cerebral cortex in the human brain. This area is involved in organizing and planning the intellectual and emotional aspects of behavior, much as the adjacent premotor cortex is involved in planning its motor aspects.

Clinical Correlate

Lesion of the Frontal Eye Field

The frontal eye field lies in front of the motor cortex in Brodmann area 8. This cortical area is the center for contralateral horizontal gaze. A lesion here results in an inability to make voluntary eye movements toward the contralateral side. Because the activity of the intact frontal eye field in the opposite cortex would also be unopposed after such a lesion, the result is conjugate slow deviation of the eyes toward the side of the lesion.

If motor cortex is involved in the lesion, the patient may have a contralateral spastic paresis. The intact frontal eye field in the opposite hemisphere deviates the eyes away from the paralyzed limbs.

Clinical Correlate

Lesions in the Prefrontal Area

Lesions in the prefrontal area produce what is called the frontal lobe syndrome. The patient cannot concentrate and is easily distracted; there is a general lack of initiative, foresight, and perspective. Another common aspect is apathy (i.e., severe emotional indifference). Apathy is usually associated with abulia, a slowing of intellectual faculties, slow speech, and decreased participation in social interactions. Prefrontal lesions also result in the emergence of infantile suckling or grasp reflexes that are suppressed in adults. In the suckling reflex, touching the cheek causes the head to turn toward the side of the stimulus as the mouth searches for a nipple to suckle. In the grasp reflex, touching the palm of the hand results in a reflex closing of the fingers, which allows an infant to grasp anything that touches the hand.

Clinical Correlate

Expressive Aphasia

Broca area is just anterior to the motor cortex region that provides upper motoneuron innervation of cranial nerve motor nuclei. This area in the left or dominant hemisphere is the center for motor speech and corresponds to Brodmann areas 44 and 45. Damage to Broca area produces a motor, nonfluent, or expressive aphasia that reflects a difficulty in piecing together words to produce expressive speech. Patients with this lesion can understand written and spoken language but normally say almost nothing. When pressed on a question such as "what did you do today?" they might reply "went town." The ability to write is usually also affected in a similar way (agraphia) in all aphasias, although the hand used for writing can be used normally in all other tasks. Patients are keenly aware and frustrated by an expressive aphasia, because of their lack of the ability to verbalize their thoughts orally or in writing.

Broca area damage often extends posteriorly into the primary motor cortex and might be combined with a contralateral paralysis of the muscles of the lower face, resulting in a drooping of the corner of the mouth. If the lesion is larger, the patient might have a spastic hemiparesis of the contralateral upper limb.

Parietal Lobe

Primary somatosensory cortex

The parietal lobe begins just posterior to the central sulcus with the postcentral gyrus. The postcentral gyrus corresponds to Brodmann areas 3, 1, and 2 and contains primary somatosensory cortex. Like primary motor cortex, there is a similar somatotopic representation of the body here, with head, neck, upper limb, and trunk represented on the lateral aspect of the hemisphere, and pelvis and lower limb represented medially (Figure IV-10-11). These areas are concerned with discriminative touch, vibration, position sense, pain, and temperature. Lesions in somatosensory cortex result in impairment of all somatic sensations on the opposite side of the body, including the face and scalp.

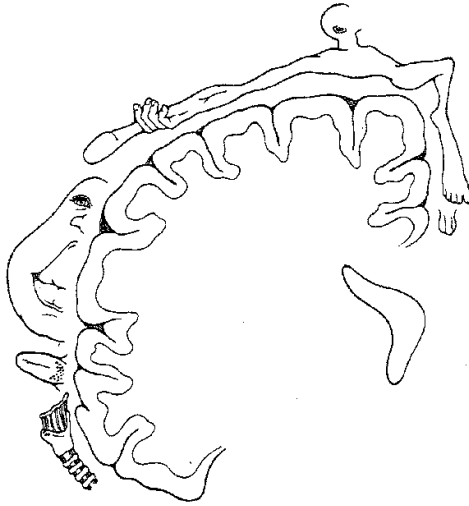


Figure IV-10-11. The Sensory Homunculus in Postcentral Gyrus (Areas 3, 1, 2) Parietal Lobe

Posterior parietal association cortex

Just posterior and ventral to the somatosensory areas is the posterior parietal association cortex, including Brodmann areas 5 and 7.

Clinical Correlate

Lesions, usually in the dominant hemisphere and which include areas 5 and 7 of the posterior parietal association areas, often result in apraxia (also seen with lesions to the premotor cortex). Apraxia is a disruption of the patterning and execution of learned motor movements. This deficit seems to reflect a lack of understanding how to organize the performance of a pattern of movements (i.e., what should be done first, then next, etc.). The patient may be unable, for example, to draw a simple diagram (constructional apraxia) or describe how to get from his home to work.

Another deficit, with lesions of areas 5 and 7 is astereognosia (inability to recognize objects by touch). There is no loss of tactile or proprioceptive sensation; rather, it is the integration of visual and somatosensory information that is impaired. Both apraxia and astereognosia are more common after left hemisphere damage than in right hemisphere damage. The astereognosia is usually confined to the contralateral side of the body; in contrast, apraxia is usually bilateral. Apraxia is probably a result of the loss of input to the premotor cortex (area 6), which is involved in the actual organization of motor movements into a goal-directed pattern.

Note

Any blockage of the left middle cerebral artery that results in an aphasia (Broca Wernicke, conduction) or Gerstmann syndrome will also result in **agraphia**.

Wernicke area

The inferior part of the parietal lobe and adjacent part of the temporal lobe in the dominant (left) hemisphere, known as Wernicke's area, are cortical regions that function in language comprehension. At a minimum, Wernicke's area consists of area 22 in the temporal lobe but may also include areas 39 and 40 in the parietal lobe. Areas 39 (the angular gyrus) and 40 (the supra-marginal gyrus) are regions of convergence of visual, auditory, and somatosensory information.

Clinical Correlate**Receptive Aphasia**

Lesions in area 22 in the temporal lobe and 39 or 40 in the parietal lobe produce a fluent, receptive, or Wernicke's aphasia. The patient with Wernicke aphasia cannot comprehend spoken language and may or may not be able to read (alexia) depending on the extent of the lesion. The deficit is characterized by fluent verbalization but lacks meaning. Patients are paraphasic, often misusing words as if speaking using a "word salad."

Patients with Wernicke aphasia are generally unaware of their deficit and show no distress as a result of their condition.

Gerstmann Syndrome

If the lesion is confined to just the angular gyrus (area 39), the result is a loss of ability to comprehend just written language (alexia) and to write it (agraphia), but spoken language may be understood. Alexia with agraphia in pure angular gyrus lesions is often seen with three other unique symptoms: acalculia (loss of the ability to perform simple arithmetic problems), finger agnosia (inability to recognize one's fingers), and right-left disorientation. This constellation of deficits constitutes Gerstmann syndrome and underscores the role of this cortical area in the integration of how children begin to count, add, and subtract using their fingers.

Conduction Aphasia

There is a large fiber bundle connecting areas 22, 39, and 40 with Broca area in the frontal lobe, known as the superior longitudinal fasciculus (or the arcuate fasciculus). A lesion affecting this fiber bundle results in a conduction aphasia. In this patient, verbal output is fluent, but there are many paraphrases and word-finding pauses. Both verbal and visual language comprehension are also normal, but if asked to, the patient cannot repeat words or execute verbal commands by an examiner (such as count backwards beginning at 100) and also demonstrates poor object naming. This is an example of a disconnect syndrome in which the deficit represents an inability to send information from one cortical area to another. Like an expressive aphasia, the patient is aware of the deficit and is frustrated by their inability to execute a verbal command that they fully understand.

Transcortical Apraxia

Lesions to the corpus callosum caused by an infarct of the anterior cerebral artery may result in another type of disconnect syndrome known as a transcortical apraxia. As in other cases of apraxia, there is no motor weakness, but the patient cannot execute a command to move their left arm. They understand the command, which is perceived in Wernicke area of the left hemisphere, but the callosal lesion disconnects Wernicke area from the right primary motor cortex so that the command cannot be executed. The patient is still able to execute a command to move the right arm because Wernicke area in the left hemisphere is able to communicate with the left primary motor cortex without using the corpus callosum.

(Continued)

Clinical Correlate (continued)**Asomatognosia**

The integration of visual and somatosensory information is important for the formation of the "body image" and awareness of the body and its position in space. Widespread lesions in areas 7, 39, and 40 in the nondominant right parietal lobe may result in unawareness or neglect of the contralateral half of the body known as asomatognosia. Although somatic sensation is intact, the patients ignore half of their body and may fail to dress, undress, or wash the affected (left) side. Patients will have no visual field deficits, so they can see, but deny the existence of things in the left visual field. Asking them to bisect a horizontal line produces a point well to the right of true center. If asked to draw a clock face from memory, they will draw only numbers on the right side, ignoring those on the left. The patients may deny that the left arm or leg belongs to them when the affected limb is passively brought into their field of vision. Patients may also deny their deficit, an anosognosia.

Occipital Lobe

The occipital lobe is essential for the reception and recognition of visual stimuli and contains primary visual and visual association cortex.

Visual cortex

The visual cortex is divided into striate (area 17) and extrastriate (areas 18 and 19). Area 17, also referred to as the primary visual cortex, lies on the medial portion of the occipital lobe on either side of the calcarine sulcus. Its major thalamic input is from the lateral geniculate nucleus. Some input fibers are gathered in a thick bundle that can be visible on the cut surface of the gross brain, called the line of Gennari. The retinal surface (and therefore the visual field) is represented in an orderly manner on the surface of area 17, such that damage to a discrete part of area 17 will produce a scotoma (i.e., a blind spot) in the corresponding portion of the visual field. A unilateral lesion inside area 17 results in a contralateral homonymous hemianopsia with macular sparing, usually caused by an infarct of a branch of the posterior cerebral artery. The area of the macula of the retina containing the fovea is spared because of a dual blood supply from both the posterior and middle cerebral arteries. The actual cortical area serving the macula is represented in the most posterior part of the occipital lobe. Blows to the back of the head or a blockage in occipital branches of the middle cerebral artery that supply this area may produce loss of macular representation of the visual fields. Bilateral visual cortex lesions result in cortical blindness; the patient cannot see, but pupillary reflexes are intact.

Visual association cortex

Anterior to the primary visual or striate cortex are extensive areas of visual association cortex. Visual association cortex is distributed throughout the entire occipital lobe and in the posterior parts of the parietal and temporal lobes. These regions receive fibers from the striate cortex and integrate complex visual input from both hemispheres. From the retina to the visual association cortex, information about form and color, versus motion, depth and spatial information are processed separately. Form and color information is processed by the parvocellular-blob system. This "cone stream" originates mainly in the central part of the retina, relays through separate layers of the lateral geniculate, and projects to blob zones of primary visual cortex. Blob zones project to the inferior part of the temporal lobe in areas 20 and 21. Unilateral lesions here result in achromatopsia, a complete loss of color vision in the contralateral hemifields. Patients see everything in shades of gray. Additionally, these patients may also present with prosopagnosia, an inability to recognize faces.

Motion and depth are processed by the magnocellular system. This “rod stream” originates in the peripheral part of the retina, relays through separate layers of the lateral geniculate, and projects to thick stripe zones of primary visual cortex. Striped areas project through the middle temporal lobe to the parietal lobe in areas 18 and 19. Lesions here result in a deficit in perceiving visual motion; visual fields, color vision, and reading are unaffected.

Clinical Correlate

Visual Agnosia

Damage to parts of the temporal lobes involving the cone stream produces a visual agnosia. Visual agnosia is the inability to recognize visual patterns (including objects) in the absence of a visual field deficit. For example, you might show a patient with an object agnosia a pair of glasses, and the patient would describe them as two circles and a bar. Lesions in areas 20 and 21 of the temporal lobe that also include some destruction of adjacent occipital lobe in either hemisphere result in prosopagnosia, a specific inability to recognize faces. The patient can usually read and name objects. The deficiency is an inability to form associations between faces and identities. On hearing the voice of the same person, the patient can immediately identify the person.

Alexia Without Agraphia

A principal “higher-order” deficit associated with occipital lobe damage is alexia without agraphia (or pure word blindness). The patients are unable to read at all and, curiously, often have a color anomia (inability to name colors). However, they are able to write. This is another example of a disconnect syndrome in which information from the occipital lobe is not available to the parietal or frontal lobes to either understand or express what has been seen.

(Recall that alexia with agraphia—inability to read or write—occurs with lesions encompassing the angular gyrus in the dominant parietal lobe.) The cause of the syndrome is usually an infarction of the left posterior cerebral artery that affects not only the anterior part of the occipital lobe but the splenium of the corpus callosum. Involvement of the left occipital cortex results in a right homonymous hemianopsia with macular sparing. Involvement of the splenium of the corpus callosum prevents visual information from the intact right occipital cortex from reaching language comprehension centers in the left hemisphere. Patients can see words in the left visual field but do not understand what the words mean.

Temporal Lobe

Primary auditory cortex

On its superior and lateral aspect, the temporal lobe contains the primary auditory cortex. Auditory cortex (areas 41 and 42) is located on the two transverse gyri of Heschl, which cross the superior temporal lobe deep within the lateral sulcus. Much of the remaining superior temporal gyrus is occupied by area 22 (auditory association cortex), which receives a considerable projection from both areas 41 and 42 and projects widely to both parietal and occipital cortices.

Patients with unilateral damage to the primary auditory cortex show little loss of auditory sensitivity but have some difficulty in localizing sounds in the contralateral sound field. Area 22 is a component of Wernicke area in the dominant hemisphere, and lesions here produce a Wernicke aphasia.

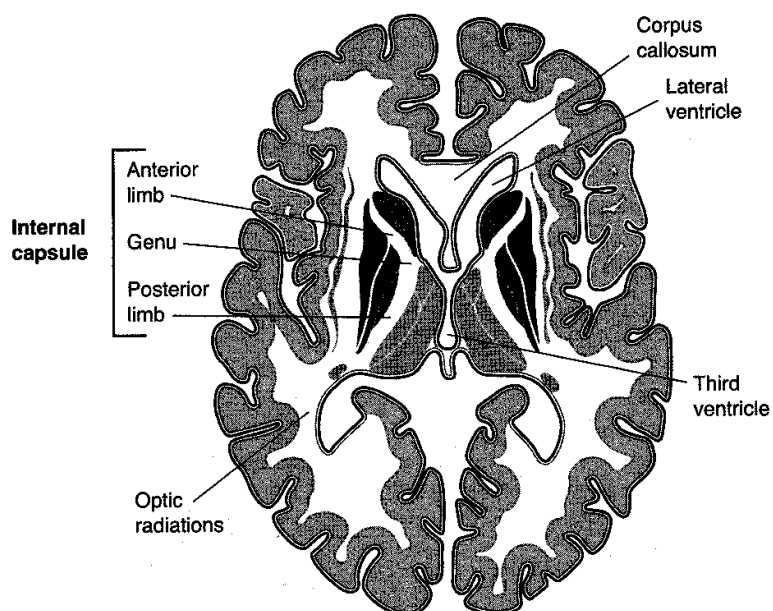


Figure IV-10-12. Internal Capsule: Arterial Supply

Table IV-10-1. Internal Capsule: Arterial Supply

Internal Capsule	Arterial Supply	Tracts
Anterior limb	Anterior cerebral artery	Thalamocortical
Genu	Middle cerebral artery	Corticobulbar
Posterior limb	Middle cerebral artery	Corticospinal, all somatosensory thalamocortical projections

Note: The posterior cerebral artery also supplies the optic radiations.

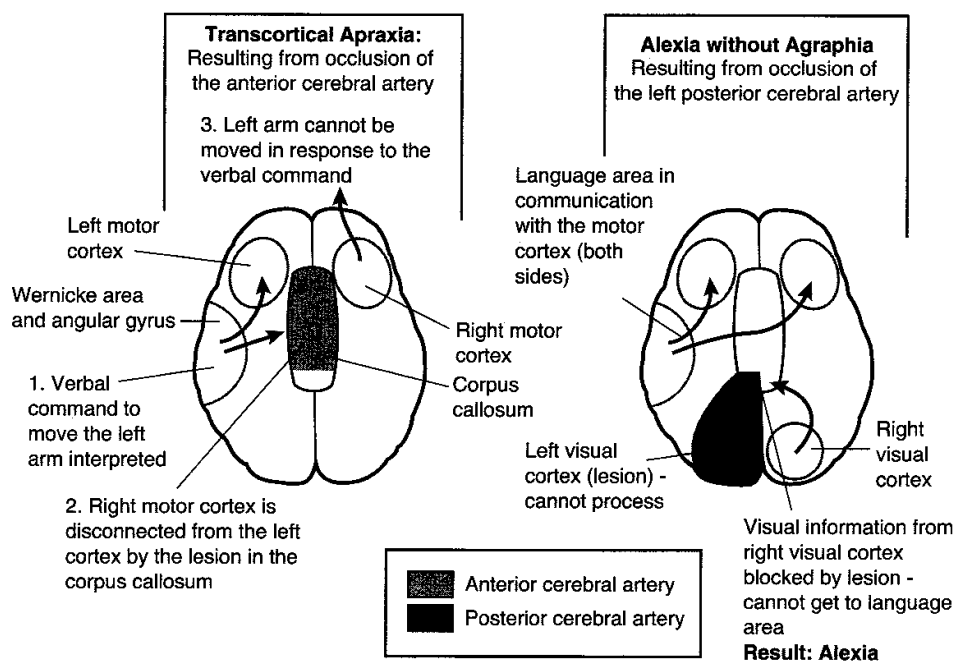


Figure IV-10-13. Symptoms Following Occlusion of the Cerebral Arteries

Table IV-10-2. Symptoms Following Occlusion of the Cerebral Arteries

Anterior Cerebral	Middle Cerebral		Posterior Cerebral
Contralateral spastic paralysis and anesthesia of the lower limb	Contralateral spastic paralysis and anesthesia of the arm and face		Contralateral homonymous hemianopsia (usually with macular sparing)
Urinary incontinence	LEFT SIDE	RIGHT SIDE	LEFT SIDE: Alexia without agraphia (see above)—cannot read, but can write
Transcortical apraxia—cannot move left arm in response to a command	Aphasias*: Broca, Wernicke, global, or conduction	Parietal lobe: 1. Inattention and neglect of the contralateral side of the body 2. Spatial perception defects	
	Gerstmann Syndrome (parietal lobe-angular gyrus): 1. R-L disorientation 2. Finger agnosia 3. Acalcula 4. Alexia with agraphia		

*Examples of disconnect syndromes

Chapter Summary

The external layer of the gray matter covering the surface of the cortex is characterized by numerous convolutions called gyri, separated by grooves called sulci. The cortex is divided into the frontal, parietal, occipital, and temporal lobes by several prominent sulci. Different areas of the cortex are concerned with sensory and motor functions. The frontal lobe contains the primary motor and premotor cortex, frontal eye field, and Broca speech area. The primary somatosensory and association cortex is found in the parietal lobe. The temporal lobe contains the primary auditory cortex and Wernicke area. The primary visual cortex is at the posterior pole of the occipital lobe.

The blood supply of the cortex is supplied by branches of the two internal carotid arteries and two vertebral arteries. On the ventral surface of the brain, the anterior cerebral and middle cerebral branches of the internal carotid arteries connect with the posterior cerebral artery, derived from the basilar artery form the circle of Willis. This circle of vessels is completed by the anterior and posterior communicating arteries. The middle carotid artery mainly supplies the lateral surface of the frontal, parietal, and upper aspect of the temporal lobe. Deep branches also supply part of the basal ganglia and internal capsule. The anterior cerebral artery supplies the medial aspect of the frontal and parietal lobes. The entire occipital lobe, lower aspect of temporal lobe, and the midbrain are supplied by the posterior cerebral artery.

The homunculus of the motor and sensory cortex indicates that the upper limb and head are demonstrated on the lateral surface of the cortex. The pelvis and the lower limb are represented on the medial surface of the hemispheres. Therefore, the motor and sensory functions of the lower limb are supplied by the anterior cerebral artery while the motor and sensory functions of the upper limb and head is supplied by the middle cerebral artery.

The primary language centers (Broca and Wernicke areas) are functionally located only in the dominant hemisphere, usually the left hemisphere. Both of these are supplied by the middle cerebral artery. Lesions of the Broca area result in motor or expressive aphasia (intact comprehension). Lesions of the Wernicke area produce receptive aphasia (lack of comprehension). Conduction aphasia results from a lesion of the arcuate fasciculus that connects the Broca and Wernicke areas.

The internal capsule is a large mass of white matter that conducts almost all tracts to and from the cerebral cortex. It is divided into an anterior limb, genu, and posterior limb. The anterior limb is supplied by the anterior cerebral artery, and the genu and posterior limb are supplied by the middle cerebral artery. The primary motor and sensory systems course through the posterior limb and genu.

Review Questions

1. Your patient has an apparent language problem in which his speech lacks rhythm and is reduced to the use of nouns and verbs in the wrong tense. He seems to hear and understand things that are said to him and can repeat single words but not a full sentence. The patient has right lower face weakness, and his right upper limb is weak. There are no sensory deficits. The language problem is most likely due to a
 - (A) Broca aphasia
 - (B) Wernicke aphasia
 - (C) Gerstmann aphasia
 - (D) fluent aphasia
 - (E) sensory aphasia

2. A dazed homeless man is brought to the emergency room. He seems confused and lethargic. He has difficulty following objects in all directions and walks with a broad-based gait, but his muscle strength is normal and he exhibits no tremor either at rest or during movements. On the basis of the assumption that this patient is an alcoholic, thiamine is administered, which relieves the ocular paresis and the confusion. Despite the thiamine treatments, the patient seems to be unable to remember past events well and tends to make up stories to cover this deficit. Which part of the brain may show thiamine-resistant pathological changes in this patient?
 - (A) Hippocampus
 - (B) Amygdala
 - (C) Hypothalamus
 - (D) Cerebellar hemisphere
 - (E) Frontal lobe

3. A patient has suffered a stroke caused by occlusion of the right anterior cerebral artery. This patient is most likely to present with
 - (A) a loss of pain and temperature sensations in the left leg
 - (B) weakness of the right leg
 - (C) drooping of the corner of the mouth on the left
 - (D) a nonfluent aphasia
 - (E) a loss of discriminative touch from the right side of the face

4. Your patient has a language problem involving an impaired ability to repeat an examiner's commands. Their speech is fluent, and comprehension seems intact. You suspect a
 - (A) Broca aphasia
 - (B) Wernicke aphasia
 - (C) conductive aphasia
 - (D) nonfluent aphasia
 - (E) sensory aphasia

5. Your female patient has suffered a stroke. She has difficulty copying simple diagrams, even though she hears and understands your requests to do so. You notice that she only has make-up on the right side of her face and does not seem to know where her left hand is in space. Which blood vessel might have been occluded to cause these symptoms?
- (A) Left vertebral artery
 - (B) Right middle cerebral artery
 - (C) Left anterior cerebral artery
 - (D) Right posterior cerebral artery
 - (E) Right anterior cerebral artery
6. A lesion of the posterior limb of the internal capsule on the right may result in
- (A) transcortical apraxia
 - (B) a drooping of the corner of the mouth on the right
 - (C) retrograde amnesia
 - (D) altered sensations from the left side of the face
 - (E) a left homonymous hemianopsia with macular sparing
7. Your patient has suffered a stroke involving the posterior cerebral artery. You might expect the patient to exhibit
- (A) a homonymous hemianopsia with macular sparing
 - (B) bladder incontinence
 - (C) alexia with agraphia
 - (D) acalculia
 - (E) transcortical apraxia
8. A 50-year-old man thinks that he is getting old because he seems hard of hearing. He looks at you as if he doesn't understand what you are saying; his speech is intact but often doesn't make much sense because of the misuse of words. He seems totally unaware of his speech or comprehension problems. You suspect that the patient has
- (A) Gerstmann syndrome
 - (B) alexia without agraphia
 - (C) an expressive aphasia
 - (D) a sensory aphasia
 - (E) prosopagnosia
9. A lawyer suffers a bad fall that results in head trauma. His motor, sensory, and language skills are intact after the incident, and he has no visual problems. In the following weeks, he begins to lose interest in his work and doesn't seem to care much about his family. The trauma most likely affected the
- (A) temporal lobe
 - (B) parietal lobe
 - (C) occipital lobe
 - (D) frontal lobe
 - (E) limbic system

10. A 16-year-old female patient with a long history of epileptic seizures that could not be controlled pharmacologically had part of her brain ablated bilaterally. Afterward she is unable to identify friends and family members. She goes on eating binges, exhibits a tendency for heightened sexual activity, and seems unable to respond with appropriate emotions to external stimuli. What neural structure may have been removed bilaterally?
 - (A) Fornix
 - (B) Mamillary body
 - (C) Splenium of corpus callosum
 - (D) Amygdala
 - (E) Cingulate cortex
11. A patient suddenly can no longer read or write. He seems to speak normally, although he misuses words, and he understands and executes simple motor commands. Later testing reveals that he cannot add and subtract, and he cannot identify which fingers are which. You suspect that his lesion has affected the
 - (A) splenium of the corpus callosum
 - (B) angular gyrus
 - (C) cuneus gyrus
 - (D) arcuate fasciculus
 - (E) paracentral lobule

Answers and Explanations

1. **Answer: A.** Broca, motor, or nonfluent aphasia is localized to the frontal lobe adjacent to primary motor cortex.
2. **Answer: C.** The mammillary bodies in the hypothalamus seem to be particularly sensitive to chronic alcohol abuse and the related thiamine deficiency. Mammillary degeneration is irreversible and results in retrograde amnesia with confabulations.
3. **Answer: A.** The anterior cerebral artery supplies cortical areas associated with somatosensory input from and upper motor neuron control of the contralateral lower limb.
4. **Answer: C.** All patients with aphasia have an impaired ability to repeat. If this is the only language deficit, then the lesion is most likely in the arcuate fasciculus, which connects the Wernicke and Broca areas. Because speech is fluent and comprehension seems intact, the conclusion is that the patient has suffered from a conductive aphasia.
5. **Answer: B.** The patient suffers from unilateral neglect, where she ignores the entire left side of her visual and somatosensory world, and presents with constructional apraxia. Neglect is seen in lesions of the nondominant or right parietal lobe supplied by branches of the right middle cerebral artery.
6. **Answer: D.** All thalamocortical somatosensory information comes from the entire contralateral body and face, and axons of upper motor neurons course through the posterior limb of the internal capsule, so that the patient may present with an anaesthesia of the contralateral face. Transcortical apraxia is seen in lesion of the corpus callosum, lower face weakness would be seen if the lesion included the genu of the internal capsule, amnesia is not seen in a capsular lesion, and macular sparing deficits are seen only in visual cortex lesions.

7. **Answer: A.** The posterior cerebral artery supplies primary visual cortex and, if occluded, results in a homonymous hemianopsia with macular sparing. All other choices are seen in occlusion of either the anterior (bladder incontinence, transcortical apraxia) or middle cerebral artery (alexia with agraphia, acalculia).
8. **Answer: D.** The patient has a Wernicke aphasia, a fluent or a sensory aphasia in which he cannot comprehend the spoken word, his speech is normal but frequently doesn't make sense, and he is unaware of his deficit.
9. **Answer: D.** The patient suffers from trauma to the frontal lobe in the area of the pre-frontal cortex, which is a center for personality traits.
10. **Answer: D.** The patient had bilateral removal of the anterior parts of the temporal lobes including the amygdala and has the signs associated with Kluver-Bucy syndrome.
11. **Answer: B.** The patient has the signs of Gerstmann syndrome, which affects the angular gyrus of the dominant parietal lobe.

The Limbic System

11

GENERAL FEATURES

The limbic system is involved in emotion, memory, attention, feeding, and mating behaviors. It consists of a core of cortical and diencephalic structures found on the medial aspect of the hemisphere. A prominent structure in the limbic system is the hippocampal formation on the medial aspect of the temporal lobe. The hippocampal formation extends along the floor of the inferior horn of the lateral ventricle in the temporal lobe and includes the hippocampus, the dentate gyrus, the subiculum, and adjacent entorhinal cortex. The hippocampus is characterized by a three-layered cerebral cortex. Other limbic-related structures include the amygdala, which is located deep in the medial part of the anterior temporal lobe rostral to the hippocampus, and the septal nuclei, located medially between the anterior horns of the lateral ventricle. The limbic system is interconnected with thalamic and hypothalamic structures, including the anterior and dorsomedial nuclei of the thalamus and the mammillary bodies of the hypothalamus. The cingulate gyrus is the main limbic cortical area. The cingulate gyrus is located on the medial surface of each hemisphere above the corpus callosum. Limbic-related structures also project to wide areas of the prefrontal cortex.

OLFACTORY SYSTEM

Central projections of olfactory structures reach parts of the temporal lobe and the amygdala. The olfactory nerve consists of numerous fascicles of the central processes of bipolar neurons, which reach the anterior cranial fossa from the nasal cavity through openings in the cribriform plate of the ethmoid bone. These primary olfactory neurons differ from other primary sensory neurons in two ways. First, the cell bodies of these neurons, which lie scattered in the olfactory mucosa, are not collected together in a sensory ganglion, and second, primary olfactory neurons are continuously replaced. The life span of these cells ranges from 30 to 120 days in mammals.

Within the mucosa of the nasal cavity, the peripheral process of the primary olfactory neuron ramifies to reach the surface of the mucous membrane. The central processes of primary olfactory neurons terminate by synapsing with neurons found in the olfactory bulb. The bulb is a six-layered outgrowth of the brain that rests on the cribriform plate. Olfactory information entering the olfactory bulb undergoes a great deal of convergence before the olfactory tract carries axons from the bulb to parts of the temporal lobe and amygdala.

In A Nutshell

Functions of the Limbic System

- Visceral—smell
- Sex drive
- Memory/Learning
- Behavior and emotions

Clinical Correlate

Alzheimer disease results from neurons, beginning in the hippocampus, that exhibit neurofibrillary tangles and amyloid plaques. Other nuclei affected are the cholinergic neurons in the nucleus basalis of Meynert, noradrenergic neurons in the locus coeruleus, and serotonergic neurons in the raphe nuclei. Patients with Down syndrome commonly present with Alzheimer's in middle age because chromosome 21 is one site of a defective gene.

Clinical Correlate

Olfactory deficits may be incomplete (hyposmia), distorted (dysosmia), or complete (anosmia). Olfactory deficits are caused by transport problems or by damage to the primary olfactory neurons or to neurons in the olfactory pathway to the CNS. Head injuries that fracture the cribriform plate can tear the central processes of olfactory nerve fibers as they pass through the plate to terminate in the olfactory bulb, or they may injure the bulb itself. Because the olfactory bulb is an outgrowth of the CNS covered by meninges, separation of the bulb from the plate may tear the meninges, resulting in CSF leaking through the cribriform plate into the nasal cavity.

THE PAPEZ CIRCUIT

A summary of the simplified connections of the limbic system is expressed by the Papez circuit (Figure IV-11-1). The Papez circuit oversimplifies the role of the limbic system in modulating feelings, such as fear, anxiety, sadness, happiness, sexual pleasure, and familiarity; yet, it provides a useful starting point for understanding the system. Arbitrarily, the Papez circuit begins and ends in the hippocampus. Axons of hippocampal pyramidal cells converge to form the fimbria and, finally, the fornix. The fornix projects mainly to the mammillary bodies in the hypothalamus. The mammillary bodies, in turn, project to the anterior nucleus of the thalamus by way of the mammillothalamic tract. The anterior nuclei project to the cingulate gyrus through the anterior limb of the internal capsule, and the cingulate gyrus communicates with the hippocampus through the cingulum and entorhinal cortex.

The amygdala functions to attach an emotional significance to a stimulus and helps imprint the emotional response in memory.

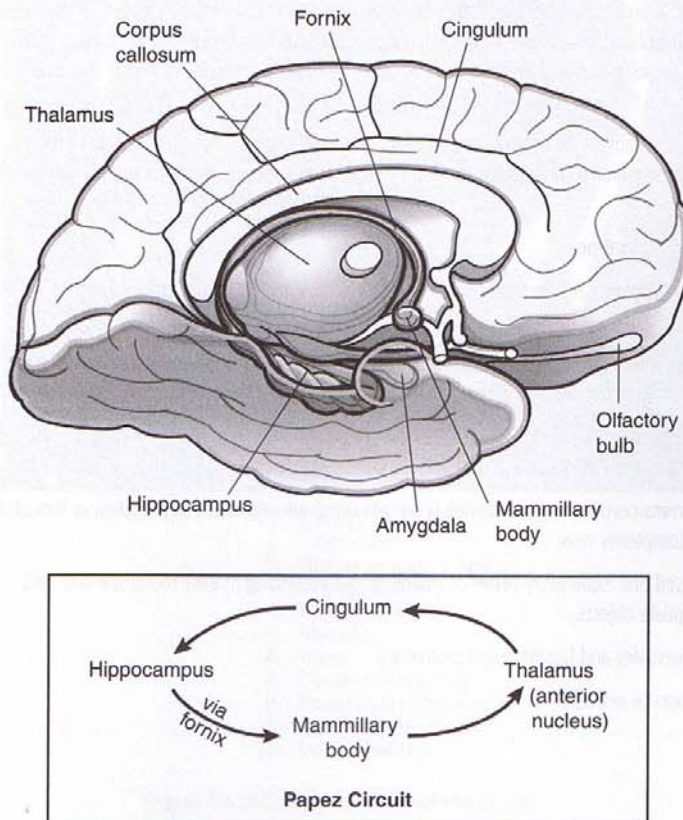


Figure IV-11-1. The Limbic System

Clinical Correlate

Alzheimer Disease and Anterograde Amnesia

Alzheimer patients lose episodic memory (events in time) earliest and most severely. Also impaired may be working memory (short-term retention) and semantic memory (objects or facts). Procedural memory (how to use tools) is affected late.

Korsakoff patients have both anterograde and retrograde amnesia but it is limited to episodic memory.

Clinical Correlate

Thiamine treatment improves signs of Wernicke encephalopathy, but it does not reverse amnesia in Korsakoff syndrome.

Clinical Correlate

Anterograde Amnesia

Bilateral damage to the medial temporal lobes including the hippocampus results in a profound loss of the ability to acquire new information, known as anterograde amnesia.

Korsakoff Syndrome

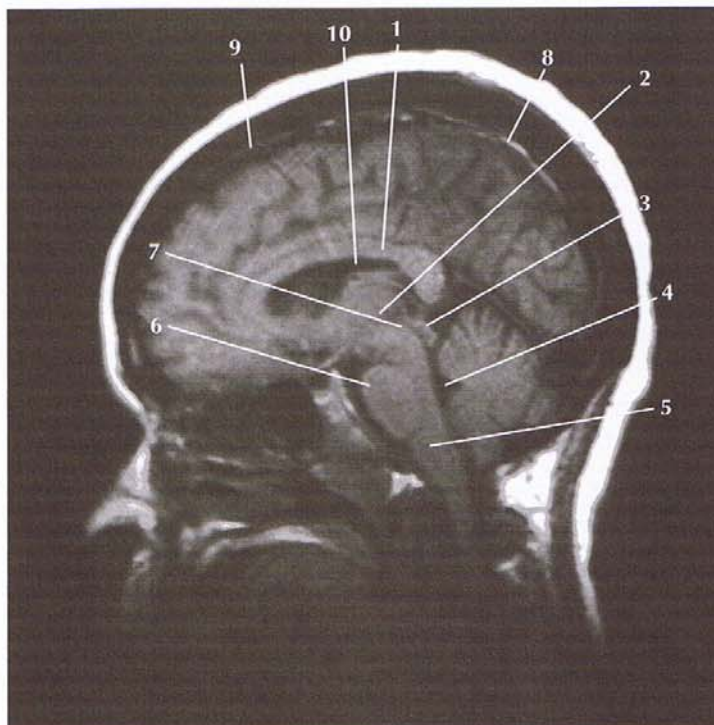
Anterograde amnesia is also observed in patients with Korsakoff syndrome. Korsakoff syndrome is seen mainly in alcoholics who have a thiamine deficiency and often follows an acute presentation of Wernicke encephalopathy. Wernicke encephalopathy presents with ocular palsies, confusion, and gait ataxia and is also related to a thiamine deficiency. In Wernicke-Korsakoff syndrome, lesions are always found in the mammillary bodies and the dorsomedial nuclei of the thalamus.

In addition to exhibiting an anterograde amnesia, Korsakoff patients also present with retrograde amnesia. These patients confabulate, making up stories to replace past memories they can no longer retrieve.

Klüver-Bucy Syndrome

Klüver-Bucy syndrome results from bilateral lesions of the amygdala and hippocampus. These lesions result in:

- Placidity—there is marked decrease in aggressive behavior; the subjects become passive, exhibiting little emotional reaction to external stimuli.
- Psychic blindness—objects in the visual field are treated inappropriately. For example, monkeys may approach a snake or a human with inappropriate docility.
- Hypermetamorphosis—visual stimuli (even old ones) are repeatedly approached as though they were completely new.
- Increased oral exploratory behavior—monkeys put everything in their mouths, eating only appropriate objects.
- Hypersexuality and loss of sexual preference
- Anterograde amnesia



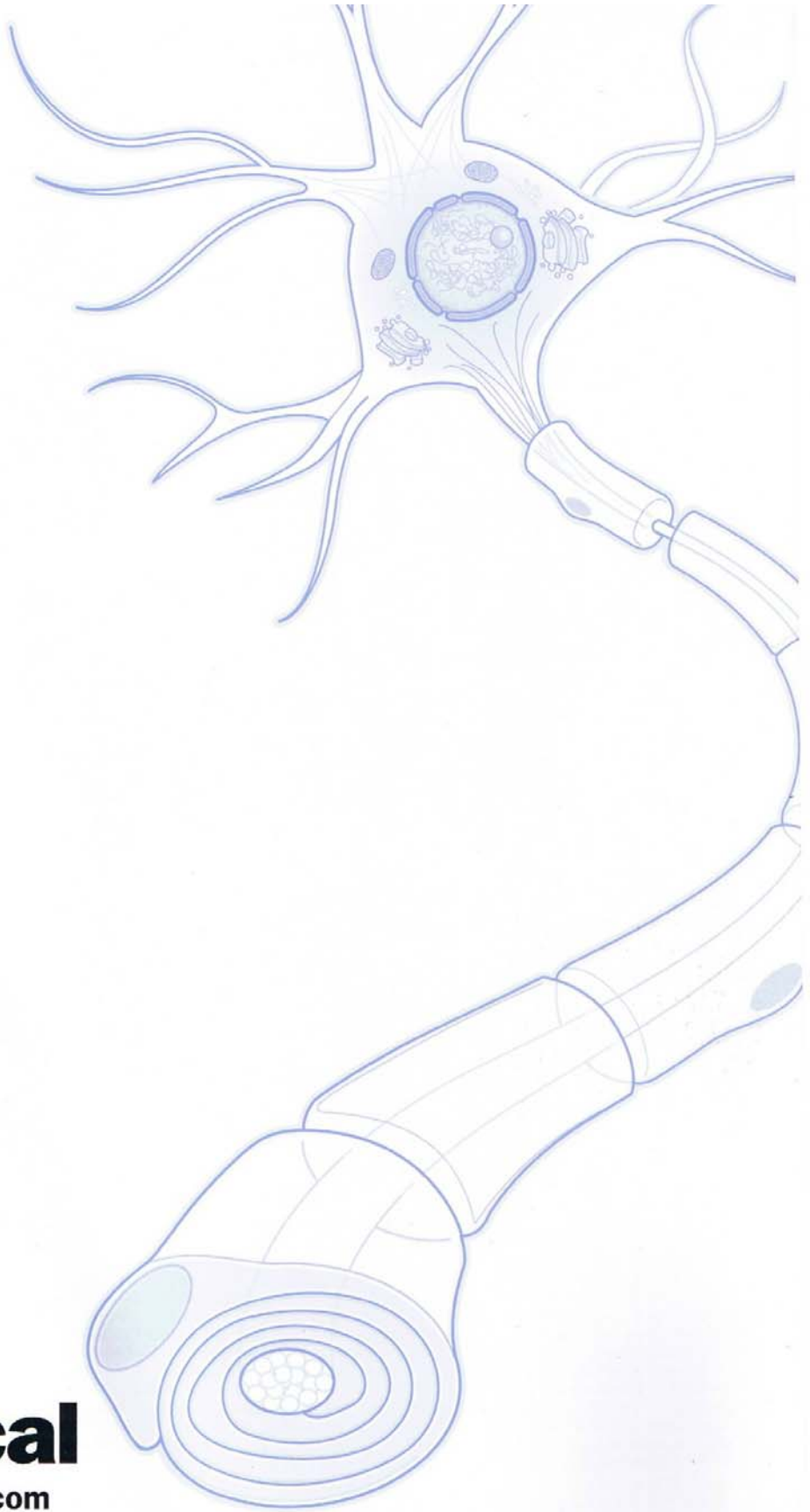
1. Corpus Callosum
2. Thalamus
3. Tectum (superior and inferior colliculi)
4. Fourth Ventricle
5. Medulla
6. Pons
7. Cerebral Aqueduct
8. Superior Sagittal Sinus
9. Subarachnoid Space
10. Lateral Ventricle

Figure IV-11-2. Sagittal View of the Brain

Chapter Summary

The limbic system is involved in emotion, attention, feeding, and mating behaviors. The major limbic system structures include the hippocampus, amygdala, mammillary body, cingulate gyrus, and the anterior nucleus of the thalamus. The Papez circuit represents possible connections of the limbic system between the diencephalon, temporal lobe, thalamus, and cortical areas.

Clinical presentations of lesions related to the limbic system are Alzheimer disease, anterograde and retrograde amnesia, Korsakoff syndrome, and Klüver-Bucy syndrome.



BK4028B Printed in USA ©2004 Kaplan, Inc.

**KAPLAN[®]
medical**
kaplanmedical.com