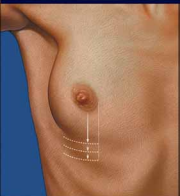


Werner L. Mang

# MANUAL OF AESTHETIC SURGERY ■ 2



- Breast Augmentation
- Brachioplasty
- Abdominoplasty
- Thigh and Buttock Lift
- Liposuction
- Hair Transplantation
- Adjuvant Therapies  
Including Spacelift







Professor Dr. med. Dr. habil. Werner L. Mang was born in Ulm, Germany, on 9 April 1949. Following his basic surgical training in the 1970s, he became a specialist in ENT (1980) and plastic operations (1984). He is the Medical Director of the Bodenseeklinik, Europe's largest clinic for aesthetic surgery. Professor Mang is Chairman of the Board of Directors of Mang-Medical AG, founding President of the German Society for Aesthetic Surgery, President of the International Society of Aesthetic Surgery, and an honorary member of numerous specialist societies.

He is also the author of the successful *Manual of Aesthetic Surgery*, Volume 1 (Mang School), which has been translated into English, Portuguese, Russian, and Chinese.

He is the author of more than 200 specialist publications; he has been a pioneer in his field in Germany and has personally carried out more than 30,000 cosmetic operations over the last 20 years. Thus, Professor Mang has significantly influenced the evolution of aesthetic surgery, as did Professor Pitanguy before him.

---

Werner L. Mang

# MANUAL OF AESTHETIC SURGERY 2

- **Breast Augmentation**
- **Brachioplasty**
- **Abdominoplasty**
- **Thigh and Buttock Lift**
- **Liposuction**
- **Hair Transplantation**
- **Adjuvant Therapies  
Including Spacelift**

Coauthors

Klaus Lang · Frank Neidel · Marian Stefan Mackowski  
Nico Roßmann · Manuel Stock

120 Medical Illustrations by Hans Jörg Schütze

20 Plates of Surgical Instruments and 66 Photographs

 Springer



---

ISBN 3-540-66553-6 Springer Berlin Heidelberg New York

Library of Congress Control Number: 00061916

This work is subject to copyright. All rights are reserved, whether the whole or part of the material is concerned, specifically the rights of translation, reprinting, reuse of illustrations, recitation, broadcasting, reproduction on microfilm or in any other way, and storage in data banks. Duplication of this publication or parts thereof is permitted only under the provisions of the German Copyright Law of September 9, 1965, in its current version, and permission for use must always be obtained from Springer-Verlag. Violations are liable for prosecution under the German Copyright Law.

Springer is a part of Springer Science + Business Media

[springeronline.com](http://springeronline.com)

© Springer-Verlag Berlin Heidelberg 2005

Printed in Germany

The use of general descriptive names, registered names, trademarks, etc. in this publication does not imply, even in the absence of a specific statement, that such names are exempt from the relevant protective laws and regulations and therefore free for general use. Product liability: The publishers cannot guarantee the accuracy of any information about dosage and application contained in this book. In every individual case the user must check such information by consulting the relevant literature.

Editor: Gabriele M. Schröder, Heidelberg

Desk editor: Irmela Bohn, Heidelberg

Production editor: Ute Pfaff, Heidelberg

Medical Illustrations: Hans Jörg Schütze, Köln

Cover-Design: Erich Kirchner, Heidelberg

Typesetting and Reproduction of Plates and Photos:

AM-productions GmbH, Wiesloch

Printing and bookbinding: Stürtz AG, Würzburg

DVD-Video: Video Transfer, Groß-Umstadt

Printed on acid-free paper

24/3150 - 5 4 3 2 1 0

---

## Addresses

### **Professor Dr. med. Dr. habil. Werner L. Mang**

Ärztlicher Direktor der Bodenseeklinik Lindau  
Klinik für Plastische und Ästhetische Chirurgie  
Graf-Lennart-Bernadotte-Straße 1  
88131 Lindau / Germany  
Tel. +49 (0) 83 82 – 26 01 80;  
Fax +49 (0) 83 82 – 26 01 87 0  
email: info@Bodenseeklinik.de  
Internet: www.Bodenseeklinik.de

APL-Professor, Klinikum rechts der Isar  
Technische Universität München  
Ismaninger Straße 22  
81675 München / Germany

### **Dr. med. Klaus Lang**

Bodenseeklinik Lindau  
Graf-Lennart-Bernadotte-Straße 1  
88131 Lindau / Germany

### **Dr. med. Marian Stefan Mackowski**

Bodenseeklinik Lindau  
Graf-Lennart-Bernadotte-Straße 1  
88131 Lindau / Germany

### **Dr. med. Frank Neidel**

Bodenseeklinik Lindau  
Graf-Lennart-Bernadotte-Straße 1  
88131 Lindau / Germany

### **Dr. med. Nico Roßmann**

Bodenseeklinik Lindau  
Graf-Lennart-Bernadotte-Straße 1  
88131 Lindau / Germany

### **Dr. med. Manuel Stock**

Bodenseeklinik Lindau  
Graf-Lennart-Bernadotte-Straße 1  
88131 Lindau / Germany

---

In memory of  
Dr. Karl Mang  
Dominic Blake

---

*Manual of Aesthetic Surgery* is dedicated to my wife, Sybille, and my children, Gloria-Victoria and Thomas-Werner. Without my wife Sybille I would have been unable to find the energy to build the new clinic at Lake Constance or to write this manual. Over the last few years, there has been no time for holidays or free weekends with my family, and it thus pleases me even more that, despite this stress, both my children are interested in the field of medicine. Naturally, it would be wonderful if my children could one day continue my life's work and become capable surgeons.

---

## Introduction

My idea of writing an audiovisual work about aesthetic surgery has been crowned by success, for which I am extremely grateful. In Volume 1 of the Manual of Aesthetic Surgery, for the first time treatments were described simply, clearly, and concisely using text, pictures, and videos, so that young doctors who want to learn about this area, either as interested students and doctors or as young specialists in aesthetic/plastic surgery, could acquire the basic knowledge and surgical expertise they need without making treatment mistakes.

The manual is intended to be a basic tool and is not for professionals and doctors who have been practicing in this specialty for a long time. It is intended to be a textbook for doctors who are starting out in this field and want to learn about it.

Naturally, it was not possible to mention all the tricks, subtleties, and latest operation methods, suture materials, implants, etc. in these volumes. Every aesthetic surgeon must learn these through further training and conferences. However, for every surgical technique in trauma or abdominal surgery, the basics of the operation must be standardized. This was achieved well with Volume I of the manual. It has been the most successful book of its kind for Springer-Verlag, Heidelberg, and has been published in Spanish, Russian, and Chinese because of the enormous interest in it.

I had never thought that this book would be so well accepted. It has become an interdisciplinary textbook for surgeons, ENT and dental surgeons, plastic surgeons, dermatologists, gynecologists, orthopedists, and urologists and has a place in many hospital libraries throughout the world.

After the first volume was published, I received invitations to give lectures and surgical courses and take up chairmanships from almost everywhere in the world. I have been accredited as an honorary professor at foreign universities and see my life's task in plastic/aesthetic surgery as being to bring together all specialties that teach and research the field of aesthetic surgery in order to ensure excellent quality assurance in relation to patient care.

---

As a result of my lectures to the most varied specialist societies on every continent, I have discovered again and again that there is competition between ENT surgeons, dental surgeons, and plastic surgeons in almost every country, even though all three specialties perform extremely valuable work in the field of aesthetic surgery.

The leading plastic surgeons of the past, Diefenbach, von Gräfe, Joseph, and Lexer, were either ENT surgeons or general surgeons. We must never forget our history and the disciplines from which the specialty of aesthetic/plastic surgery has developed.

Anyone who has had sound surgical training and has an interest in the field of aesthetic surgery will value this book as a benchmark. It can help in allowing the specialty of aesthetic surgery to be taught in an interdisciplinary way, so that the specialties concerned can mutually exchange knowledge and thus contribute to further progress in this field.

Aesthetic surgery can only achieve a serious basis in the long-term through constant training, the exchange of ideas, attendance at conferences, and the opening up of all specialties that perform valuable work in this field. Neither plastic surgery nor ENT and dental surgery can claim this specialty for themselves alone, as there is too much overlap both historically and in the specialist further-training guidelines. For this reason, work is carried out in an interdisciplinary way at the clinic at Lake Constance with the departments ENT and plastic surgery, plastic and reconstructive surgery, maxillofacial surgery, aesthetic dental surgery, dermatology, and venous, hair and laser surgery. This is the only way a large clinic can cover the entire spectrum. The same applies to a well-trained aesthetic surgeon. He will always have main areas within his field of work and will be unable to cover all operations professionally alone. This is why the model of the clinic at Lake Constance will be successful in the long term, as in this clinic different groups of specialists are unified and offer interdisciplinary aesthetic surgery. This is the clinic of the future.

Every year approximately 3,000 operations are carried out at the clinic at Lake Constance, which has five operating theaters and 50 beds. The *Manual of Aesthetic Surgery* should be seen as the symbiosis of my lifetime work with the Bodenseeklinik. It has been published to coincide with the building of the new clinic (completion 2003). In view of the great success and enormous demand for Volume 1, Volume 2 has now been published. The building of the new clinic has resulted in a delay but Volume 2 uses the same principles as Volume 1 and describes

---

the most important aesthetic operations in the torso area in a simple, clear, and concise way, providing a standard basis for novices, not for professionals. All physicians with an interest in aesthetic surgery can build on this and refine their surgical techniques during the course of their life. The basic principles must be standardized, so that dangers and risks can be reduced. Rhinoplasty should not be performed differently in London and Rome, and liposuction techniques should be the same in New York and Tokyo.

Just as in abdominal surgery, there are basic principles that must be observed so that the operations and results can be reproduced and serious treatment errors can be avoided.

Naturally, there are variations in the operations, whether the procedure is rhinoplasty, otoplasty, breast implants, or liposuction. The same applies to operations on the appendix or tonsils. The basic surgical technique used, however, is always the same. The anatomy never lies. It is therefore essential that the basic operations are standardized, particularly in aesthetic surgery, which I consider to be the most difficult type of surgery, as the surgeon must not only be well trained, but must also be a psychologist and artist. Volume 2 of the manual attempts to do this.

Substantial reconstructive procedures, such as breast reconstruction (reduction, tightening) and body lifting have been intentionally avoided. If necessary, this field will be looked at in another volume, as there is enormous potential for error and only experienced doctors working in a clinic environment are capable of learning this.

---

## A General Remark

If I may be permitted another remark here:

The author's philosophy and the philosophy of the Bodenseeklinik is interdisciplinary cooperation, instruction and further training of young doctors, cooperation with all professional societies for the promotion of good patient care, and further development in the field of aesthetic surgery.

The Manual of Aesthetic Surgery has thus come about through tireless work. My clinic at Lake Constance is the largest clinic of its kind in Europe, a training clinic with interdisciplinary cooperation between all specialties that provide a stimulus for aesthetic surgery. Doctors from the disciplines of plastic surgery, ENT and dental surgery, dermatology, aesthetic dentistry, and anti-aging medicine all work in the clinic at Lake Constance. There are also dietary assistants, specialist beauticians, hair-stylists, color consultants, and psychologists.

Long-term success can only be achieved when aesthetic surgery is seen to be holistic medicine and the correct indications are available. Many patients have serious psychological problems that cannot be solved even by the best cosmetic surgery. These patients are then dissatisfied with the surgeon and try to find a cure from other surgeons. If these surgeons do not then cooperate with the surgeon who carried out the previous operation, the patient will complain. Medicolegal problems have an important role in aesthetic surgery throughout the world.

The specialty can only have a long-term future if doctors are well-trained, act as good colleagues towards one another, and do not want to make their name at the cost of others. I would therefore like to pass on this message to all the surgeons in the world: be considerate and fair to colleagues, regardless of their specialty. The Hippocratic oath should apply to cosmetic surgeons, too.

The philosophy of the Mang school is naturalness. Less is more. Health before beauty. Cosmetic surgery is not "alteration surgery" but rather "well-being surgery."

The aim of every operation, whether it is a facelift, rhinoplasty or a breast implant, should be a natural result. The patient should feel good and the surgery should not be conspicuous. Faces that are perfectly smooth, unnaturally augmented lips, and huge breasts are no longer the



---

trend of the twenty-first century. The two volumes of the manual therefore present surgical techniques that provide natural and normal results.

Aesthetic surgery is not beauty surgery. It is instead high-tech surgery with the highest surgical standards. As with every other surgical procedure, the risks mean that specialist surgical personnel, anesthesia, recovery rooms, and inpatient monitoring are essential. Surgery on a day-case basis is only advisable for minor procedures carried out under local anesthesia, such as eyelid corrections, facelifts, hair transplantations, and laser operations. Otherwise, an inpatient stay is necessary, as most complications, e.g., severe bleeding, occur within the first 24 h after the operation.

The current worldwide problem of medicolegal issues in cosmetic surgery procedures should be combated with extensive expert activity. In addition to providing accurate oral and written information in the presence of witnesses and photographic documentation, use of the correct surgical techniques and postoperative monitoring are extremely important in avoiding the possibility of becoming liable for compensation. More and more patients are happy to take legal action and this means that good training, quality assurance, good relationships between colleagues, and professional interaction with patients are even more essential.

---

## The Standard Procedures

The other standard procedures are clear and can be easily and safely learned following good basic surgical training. Similar basic surgical rules apply to brachioplasty, abdominoplasty, and thigh lift and buttock lifts. In principle, these procedures entail cleanly lifting a cutaneous/fatty flap from the fascia and tightening the skin appropriately, using a large cutaneous resection and positioning the incisions in such a way that they are preferably not visible. The surgeon's talent is estimating the correct cutaneous resection, so that not too much and not too little is removed, and accurate surgical planning of the incisions so that they will preferably be in a non-visible area. The intracutaneous suturing technique with Monocryl, a suture which is not removed, is now standard and provides the best results. In certain cases, the skin may also be adapted with overcast cutaneous suturing with thin nylon, following subcutaneous, tension-free skin closure. When these continuous sutures are removed in time, the cosmetic results of the suturing are no different than for intracutaneous suturing.

For all operations associated with large scars, follow-up treatment is very important. A compression dressing should be worn for approximately 4 weeks and follow-up treatment for the scar should be carried out with a silicone plaster. Scars resulting from brachioplasty, abdominoplasty, and thigh and buttock lifts in particular are often unpredictable and must be discussed in detail with the patient when the procedure is explained so that there is no disagreement later.

---

*Volume II of the Manual of Aesthetic Surgery will appeal to doctors in the field of aesthetic/plastic surgery and provide them with a basic knowledge of the most important and most frequently requested operations in the torso area:*

### **Breast Augmentation**

This procedure is requested very frequently. The incision line and access are decisive factors in the success of the operation. In the manual and video, we present the simplest and safest type of access. This involves making a small incision in the inframammary fold and, with supramuscular insertion, clean dissection between the fascia and the gland. With submuscular access, the implant is inserted below the pectoral muscle, after this has been carefully detached at the medial and caudal attachment.

The video shows supramuscular access, as this is the easiest surgical technique for novices and provides an aesthetically pleasing result if the skin condition is good.

In a clinical study on our patients, we were able to establish that there is no significant difference in the rate of fibrosis in submuscular and in supramuscular access. The rate of fibrosis among our patients was less than 4% for both these methods.

The choice of implant is also important. Only licensed implants should be used. We would advise against using cheap implants and implants that have not undergone long-term testing.

The concept of breast augmentation described in the manual can be used as a basis. Experience is very important, particularly in breast surgery, as regards the shape of the implant (round, low profile, high profile, anatomical, etc.) and the best position.

In addition to an access incision in the inframammary fold, naturally the incision can also be made above the nipple or via the axilla. This requires additional experience and practice. The wound is sutured intracutaneously with 4.0 Monocryl. The sutures are not tightened and the incision can be treated with a silicone plaster 4 weeks after the operation for 2 months. Usually, there is no residual visible scar.

The procedure is performed under conventional anesthesia and with antibiotic cover. The patient should wear a specially fitted sports bra for 4 weeks after the operation.

---

## **Brachioplasty**

An important factor in brachioplasty, as with all major tightening operations on the torso, is that there may be residual scars if the suturing technique and wound healing are poor. This must be made clear to the patient before the operation.

An important preoperative stage in the operation is to mark the surplus skin to be resected precisely on the patient, who should be standing. The size of the resection is also a decisive factor in the successful outcome. If too little is resected, this will result in folds in the medial area of the upper arm. If too much is resected, hypertrophic scars may form.

The surgical technique is simple. It basically consists of dissection of a cutaneous/fatty flap from the fascia of the upper arm, step-by-step resection and wound closure in three layers. As the patient is often worried about a large caudal scar extending to the epicondyle of the upper arm, we have developed a modified technique: the “fish mouth” technique. With this technique, the tightening is not performed vertically and primarily on the upper arm, but horizontally and on the skin of the axilla. With this type of incision, the incision on the inside of the upper arm does not extend beyond the cranial third. Postoperative scar care is also important with this type of incision. The patient must be monitored for 24 h after the operation, and the special compression dressing can be removed after 8 days.

## **Abdominoplasty**

The art of a good aesthetic surgeon is in choosing the right indication. He needs many years of experience to do this. It is possible to achieve good results without making large incisions with the new method of tumescence liposuction, particularly with collections of fat in the abdomen/hip area. If, however, there is a lot of surplus skin and the patient has lost more than 30 kg in weight, or pregnancies have severely stretched the upper abdomen and periumbilical region, abdominoplasty is indicated. If it is necessary to tighten only the lower abdomen, it may be possible to avoid moving the navel. However, it is usually necessary to make an incision around the navel and reimplant this in the correct position.

In the video, the basic abdominoplasty technique is described clearly, concisely, and simply so that every experienced surgeon will be able to perform this procedure. As with all tightening operations on the body, the procedure consists of an operation on the thick cutaneous/fatty flap

---

along the abdominal fascia. It is essential that the surgeon makes precise markings on the torso while the patient is standing and carefully plans the surgery prior to the operation. The level of the incision must be defined precisely so that it will always be possible to avoid a vertical incision. The more surplus skin there is, the more caudally the incision may be placed. During abdominoplasty it must also be taken into account that the mons pubis is usually included in the tightening.

Dissection is carried out along the abdominal fascia as far as the costal arch. The entire cutaneous/fatty flap is then pulled downward and resected in stages, with the upper body slightly flexed, so that later neither too little skin (bulging) nor too much skin (risk of necrosis) is resected.

A preoperative autologous blood donation is advisable for very obese patients. Ultrasound investigation for umbilical and abdominal wall hernias is also recommended. Intraoperative and postoperative thrombosis and infection prophylaxis is given for 10 days after the operation. The 4.0 Monocryl sutures must not be tight. A silicone plaster is applied after 4 weeks for 2 months. Care of the scar is essential. This is the mark of a good abdominoplasty. Similarly, the reconstruction of the navel must appear natural and there should be no “dog ears” at the sides in the caudal area of the incision.

The procedure is performed under general anesthesia during an inpatient stay. A special girdle should be worn for 4 weeks after the operation.

### **Thigh and Buttock Lift**

The technique for a thigh lift is similar to that for brachioplasty. Deep, subcutaneous dissection of the fascia and step-by-step resection of the skin, previously marked precisely, are performed.

An operation on the medial side of the thigh is one of the most unsatisfactory operations an aesthetic/plastic surgeon can perform.

The patient's expectations of the procedure are usually too great and he/she is then disappointed by the result. The patient should therefore be given an extremely detailed explanation prior to the thigh and buttock lift. The indication should be considered carefully and if the patient expects too much, they should preferably be turned away.

The extent of the resection should be defined carefully the day before the operation. If the skin on the inner side of the thigh is loose, the buttock region is usually also loose, so these operations can be combined well.

---

The incision line in the buttock area should not extend beyond the lateral buttock fold, as otherwise there may be residual aesthetically displeasing scars, which often disturb patients more than hanging skin.

With extremely slack skin in the area of the medial thigh, vertical tightening extending to the medial side of the knee can be performed in addition to horizontal tightening in the groin and buttock region. This allows extremely intense tightening of the entire medial thigh, but the residual scar should be drawn to the patient's attention and explained.

The video shows the most frequently requested operation for horizontal thigh and buttock lifting. In contrast to brachioplasty, it is important that the thick cutaneous/fatty flap be secured at two points to achieve a longer-lasting result and better scar formation, owing to gravity in the thigh area. The points for fixation are the periosteum of the pubic bone and the inguinal ligament. The extent of the resection is defined with key sutures, and the area is resected in stages so that not too much and not too little skin is removed. The operation is performed under general anesthesia on an inpatient basis. Thrombosis and infection prophylaxis is started. A special girdle must be worn for 3 weeks after the operation, followed by care of the scar with a silicone plaster.

Because of the many requests, hair transplantation, Prof. Mang's spacelift, and a few brief descriptions of adjuvant therapies are included in Volume 2.

Adjuvant therapies are being continually developed and newly published, mainly within the field of dermatology. For this reason, only the essential features of the adjuvant therapies are described very briefly in this manual, with no claim to completeness.

The essential texts on biological implants (collagen), lipotransfer, botulinum toxin, dermabrasion, ultrapulse CO<sub>2</sub> laser, erbium-YAG laser, coblation, and chemical peeling can be found in Volume 1. As only ultrapulse CO<sub>2</sub> laser treatment was shown in Volume 1, we have filmed short videos for Volume 2 on biological implants (collagen, hyaluronic acid), botulinum toxin, dermabrasion, erbium-YAG laser, and chemical peeling. For space reasons, these films have been kept very short and should show that adjuvant therapies should also be included in the repertoire of an experienced aesthetic surgeon.

Two of these treatments have been described in detail in the video and the text.

---

## **Liposuction – Removal of Fat with the Tumescence Technique (Mang’s Solution)**

Liposuction is one of the most frequently performed operations in aesthetic/plastic surgery. In men, liposuction is primarily requested for the abdominal/hip area; in women, it is for the lateral and medial thigh, buttocks and hips (“saddle area”).

Dry suction under general anesthesia does not merely put a strain on the cardiovascular system with an increased risk of thrombosis and embolism, but also causes blood loss, including a drop in hemoglobin to under 8 g %, as well as destroying the infrastructural supporting tissue (IST).

This infrastructural supporting tissue is maintained when the tumescence technique is used, so that there is no “chewing gum effect” following liposuction, i.e., the skin does not have depressions in it but instead is tightened.

The tumescence technique was first published at the beginning of the 1990s by Jeff Klein. Lidocaine was used as local anesthesia. In view of the toxicity, we carried out a large study that showed that the aesthetic/plastic surgical tumescence technique with lower doses of prilocaine solution (Mang’s solution) produces the same results with a lower incidence of complications:

- Mang’s solution=0.9 % saline solution (NaCl) 3000 ml
- 1 % prilocaine 1500 mg (=150 ml)
- Epinephrine 3 mg
- 8.4 % NaHCO<sub>3</sub> 30 mEq
- Triamcinolone acetonide 30 mg

As high doses of prilocaine may cause methemoglobinemia, no more than 6000 ml of this tumescence solution should be injected per session either manually or with a pump. The results are very good if the correct indications are given. There is no blood loss, the risk of thrombosis and embolism is significantly reduced, and there is protection from infection. The patient is mobile on the first day after the operation.

The patient should be monitored for 24 h after the operation. He/she may leave the hospital with a special girdle, which must be worn for 3 weeks. The injection sites may be treated with scar ointment for 3 weeks after the operation. Then the region treated by liposuction should be exercised in a gym under supervision.

---

In the video, the manual tumescence liposuction technique with Mang's solution is presented as a basic technique. Auxiliary devices of whatever type (MicroAire, ultrasound, reciprocator, etc.) may be useful and reduce the liposuction time, although the same results can be achieved perfectly with the manual technique. This technique is simple, can be performed without any large instruments, and there are no significant risks if it is carried out by a specialist.

Similarly, the tumescence injection can be given manually or mechanically with a pump. The manual technique, however, is very time-consuming and it is necessary for the surgeon to have a lot of stamina, so at our clinic we apply the tumescence solution quickly (without too much pressure and over at least 45 min) and homogeneously with a six-cannula pump system. Following local tumescence anesthesia, you should wait 30 min and then begin liposuction.

If performed by an experienced surgeon, manual liposuction may take up to 90 min and up to 45 min with the MicroAire system. The patient must be prepared for the total liposuction procedure with tumescence to last approximately 2.5 h.

### **Hair Transplantation**

Hair transplantation is a procedure frequently performed in men. We have an experienced transplantation team, managed by Dr. Frank Neidel. Depending on the indication, we work with both slit and micro-punch techniques, manually or with laser assistance. Precise surgical planning, the correct technique and the schedule of the hair transplantation team, which is made up of the surgeon and three assistants who prepare the hair roots, are all important factors.

Approximately 3,000 hair roots are transplanted per session. The procedure is performed on an outpatient basis under local anesthesia. The patient is then given antibiotic cover and hair hygiene is strict. The hair should be washed on the fourth day after the operation with a mild chamomile shampoo.

### **Spacelift**

The name spacelift was chosen by Prof. Mang and protected by patent (German Patent Office, Patent and Logogram No: 303 23891), as three-dimensional fat droplets of 0.1–0.3 mm are injected via the purified autologous fat cells into the space between the cutaneous and adipose



---

tissue of the face, virtually as if in a honeycomb. As these fat droplets are not injected in a bolus dose but by using microinjections, they do not die but retain a vascular association and are transformed into fibroblasts, or rather connective tissue cells, and thus stabilize the aging process. Fat cells are thus injected into the space between the cutaneous and adipose tissue, particularly at those sites where the collagen and elastin fibers break down with age, i.e., in the nasolabial, mouth, forehead, lateral eye, and cheek regions.

The spacelift should be seen as a prophylaxis against aging after the 35th year of life. If there is surplus skin in the area of the neck/cheeks or eyelids, conventional tightening or lifting must be performed. A spacelift cannot replace a facelift.

The procedure is carried out on an outpatient basis under local anesthesia. Cooling and lymph drainage are then necessary for 3 days, along with antibiotic cover.

---

## Acknowledgements

It fills me with pleasure when I receive letters from young colleagues asking when the second volume of the *Manual of Aesthetic Surgery* will finally appear as they have learned so much from the first volume. Naturally, there has also been constructive criticism, but the overwhelming majority of interested aesthetic/plastic surgeons see the manual as a standard work for gaining basic knowledge in the field of aesthetic surgery. If I have achieved this aim, the effort has been worthwhile.

Naturally, there will always be new methods, implants, and surgical materials. Aesthetic surgery, however, is no different from general surgery; there are clear guidelines that must be built upon to prevent errors and complications.

As aesthetic surgeons, we are often unable to define beauty, and we should not be swayed by fashion. What is said to be beautiful in the media today may be different again in a few years' time. The aesthetic surgeon must therefore impart timeless beauty through his creative work. The patient must feel good. Less is often more and overly aggressive aesthetic surgery is not my style.

During the 1980s and 1990s, I spent a lot of time at conferences in the USA and Brazil, but in the last few years I have been more active in Russia and China. I often receive invitations from these countries because of my *Manual of Aesthetic Surgery, Volume 1*, as aesthetic surgery is only just being developed there, and any knowledge in this field is extremely welcome. I have become acquainted with many competent plastic surgeons who are very interested in the field of aesthetics, particularly in Russia. The demand is also increasing in these countries.

I have a close relationship with the University of St. Petersburg through Prof. Malakhov, whose human qualities I admire just as much as his surgical skills.

Within Europe, our task is also to share our knowledge in aesthetic surgery. In doing this, doctors will make a substantial contribution to international understanding. The same applies to China where there is a great demand for knowledge in aesthetic surgery. Young doctors from this country have demonstrated their technical skill in my clinic.

---

I have already mentioned all of my medical colleagues in Volume 1 with whom I have been working since 1975 and have had the privilege to learn from, as well as everyone who has helped me on the way. In addition to these, I would also like to mention my long friendship with Prof. Ivo Pitanguy. I first visited Prof. Pitanguy at his clinic in Rio de Janeiro in 1972. Since then, Prof. Ivo Pitanguy has often taken part in conferences in Lindau and is always a very welcome guest in our home. His professional competence, his charm, his gentlemanly nature, his warm-heartedness and his ability to get things done, as well as his pioneering spirit and his love for aesthetic/plastic surgery have perhaps encouraged me to continue resolutely in this specialty and to pass on my knowledge to young colleagues. This young team of enthusiastic aesthetic/plastic surgeons at my clinic has also helped me to complete Volume 2 of the manual. For this, I would like to give particular thanks to Dr. med. Klaus Lang, Dr. med. Marian Stefan Mackowski and Dr. Manuel Stock for their assistance with the chapters on surgery of the abdominal wall and extremities, Dr. med. Frank Neidel for compiling the hair transplantation chapter, and Dr. Nico Roßmann for the photographic documentation and his marvelous care of patients on the ward. Dr. med. Kathrin Ledermann is responsible for adjuvant therapies at my clinic and helped me to compile the videos and texts about this area. My sincere thanks for this. I would like to thank Ms Annemarie Anzenbacher and Ms Karina Engelhardt for the clerical work and organization and my entire surgical and inpatient team who likewise gave up much time to compile the films and photographs.

My particular thanks naturally go to the Springer-Verlag and, in particular, Ms Gabriele Schröder, who has always been very patient with me and has not pressed me too much, despite my delays. I would like to thank Ms Ute Pfaff for the wonderful production of the volume and, last but not least, Mr Klaus Peter Prieur, who recorded the films in the operating room and edited and set them in the studio with much patience, skill, and originality.

The *Manual of Aesthetic Surgery* is brought to life by the excellent illustrations. Mr Hans Jörg Schütze created these in an ingenious way. He was present at the operations and drew every important stage. The first volume of this manual was only so successful because of his professional competence and perseverance. I offer him my warmest thanks for this.

Werner L. Mang

---

## Foreword by M. P. Ceravolo

All plastic surgeons have been waiting for this book. Those who have read Prof. Mang's first volume will be surprised to see how the clarity of the text, the detailed drawings, and the wisdom in the technical advice now proposed by the author are even more impressive than in the first volume. Breast surgery, abdominoplasty, and the technical difficulties of other major operations can easily be tamed through an extremely didactic method and outstanding iconography.

The author, like Virgilius in the *Divine Comedy*, accompany the reader through the different circles of Hell, explaining how to do things and how "avia" become "pervia" if well handled. Professor Mang's eclectic personality, his rousing enthusiasm, and his vast experience merge in this book, making it a "must" for the surgeon training in aesthetic surgery and a pleasure for the experienced plastic surgeon.

Mario Pelle Ceravolo  
Professor of Plastic Surgery  
University of Rio de Janeiro, Brazil  
Medical College, New York, USA  
and Rome, Italy

---

## Foreword by D. L. Feinendegen

Aesthetic surgery has experienced exceptionally rapid growth over the last few years. There has been a continual increase in the number of people requesting such operations and, alongside specialists in plastic surgery, more and more doctors from other specialist surgical fields are now working in this area. Until now, however, it has been possible to acquire sound training in aesthetic surgery within Europe in only a few large hospitals. Doctors interested in this field therefore often have to move abroad to obtain experience in aesthetic surgery.

Professor Mang has been working to establish training in aesthetic surgery for many years. His greatest contribution has been to ensure interdisciplinary cooperation between plastic surgeons, ENT specialists, oral surgeons, and other surgeons active in the field of aesthetic surgery. Professor Mang has already made these ideas a reality in his new clinic.

With his two manuals on aesthetic surgery, Professor Mang has created a foundation for training in aesthetic surgery. The first volume has already made a strong impression, with its clear structure and excellent, step-by-step diagrams that make even difficult surgical techniques easy to understand. The manuals appeal particularly to young doctors who are having their first experience with aesthetic surgery. The additional option of audiovisual learning, provided by the integrated DVDs, underlines Professor Mang's modern teaching concept.

The two manuals reflect Professor Mang's tireless dedication to the task of continuing to establish the field of aesthetic surgery. I myself have come to value Professor Mang as a teacher and wish him continued success in making his ideas a reality. I hope that as many doctors as possible will be able to profit from these ideas, ultimately contributing to the welfare of patients.

Dr. med. Dominik L. Feinendegen  
Spezialarzt FMH für Plastisch-Rekonstruktive  
und Ästhetische Chirurgie  
Zollikon, Switzerland

---

## Foreword by P. F. Fournier

It is a great pleasure and a great honor for me to write a foreword in the second book of Professor Werner L. Mang.

Professor Mang and I have been acquainted for many years and have attended many meetings together. He must be congratulated on having presented his great experience in aesthetic surgery in his books in a dynamic way with a video included in a DVD. All aesthetic surgeons with experience or surgeons learning aesthetic surgery who have not the privilege to observe Professor Mang in his clinic at Lake Constance can be informed about the latest and best procedures used by Professor Mang. The text and illustrations are of exceptional quality and reading the different chapters is a real pleasure.

All chapters have been written with great care and with the desire to be of the highest interest for the readers. There is no doubt that this second book will have the same deserved success as the chapters of the first book.

We are greatly indebted to Professor Mang for all the time he spent in offering both seasoned and beginning aesthetic surgeons eager to learn or refine a surgical procedure a true mine of precious and safe techniques. He is extending the horizons of our specialty by providing the readers with his contributions or the improvements that he brought to conventional techniques. He emphasizes details that continue to make our specialty creative and very practical at the same time. All such precise information is an incentive to read and learn more to achieve excellence in our daily work, in patient selection, in planning, and performing.

Again, we should be very grateful to Professor Mang for sharing his great knowledge, experience, creative mind, and insight.

I have known Prof. Mang for more than 20 years. Following his surgical training, he gained an international reputation as a specialist in ENT and plastic surgery and, through his *Manual of Aesthetic Surgery*, Volume 1, he became beyond the boundaries of Europe. In 1987, Prof. Mang founded the German Society for Aesthetic Medicine and was a pioneer in this field in Germany. I have frequently attended his wonderful conferences in Lindau on Lake Constance, listened to his excellent lectures, and become acquainted with interesting aesthetic surgeons from all over the world. My wife and I have been pleased to accept private invitations

---

from the Mang family and these have given us the pleasure of meeting Professor Mang's enchanting wife, Sibylle, and his children, Gloria and Thomas.

Prof. Mang's clinical activity and his services to society are remarkable. He is a workaholic and pursues his goals in aesthetic surgery determinedly, properly, and with a lot of self-sacrifice. In many discussions with him, we wanted to find out what beauty really is. Cosmetic surgeons have heavy responsibilities and must be creative.

For Volume 2 of the *Manual of Aesthetic Surgery*, therefore, I have attempted to define the term beauty:

Initially we are expected to believe that beauty has something to do with proportion, balance, and symmetry. I would like to attempt, therefore, to explain beauty objectively by looking back to the starting point of the ancient Egyptians, Greeks, and Romans

### **What is Beauty?**

Beauty is a combination of form and proportion that brings us pleasure and that we can admire. The perception of beauty, however, varies between different cultures. Beauty is a balance between form and volume. Beauty produces in us an aesthetic feeling, an admiration, by pleasing the eye. Some people even claim that beauty is a visual phenomenon.

Beauty is a combination of qualities, such as form, proportion, the color of the human face (or other objects) that charm the gaze.

Over 200 years ago, David Hume (1711–1776), a Scottish philosopher, remarked, "Beauty is essentially a private and personal experience. Beauty is in the eye and mind of the beholder." He also said, "Beauty is not a quality of the thing itself but that which exists in the mind of those who contemplate it." Beauty is an individual emotion.

A few philosophers have concluded, "Beauty is good, and what is good, is beautiful."

A long time ago, the philosopher Sapphie said, "That which is beautiful is good and he who is good will soon become beautiful."

Our early experiences influence how we judge now. Particularly because beauty does not captivate through detail but through the whole, which is greater than the sum of the individual parts, our parents, partners, ex-

---

partners, wives and friends remind us of experiences. In the same way, our current experiences will affect our feelings of tomorrow. The happy and unhappy phases of our lives leave behind traces that shape our inclinations. Faces that we loved during our youth, which gave us warmth and security, live on in our thoughts.

Beauty does not only have to do with the face, the voice, the body or a charming appearance. A person is beautiful because of their character, their personality, their ability to feel joy and give pleasure to others, and their capacity for love.

If we like a face, we like the mood which that person conveys. A person can be attractive in many ways.

Beauty and charm are often confused. Cleopatra, George Sand, Louisa de la Valliere and Theodora were famous for their beauty. In truth, they were very beautiful but also had a lot of charm. Beauty is more an illusion than a reality.

Beauty exists not only for the eye but also for the mind.

A beautiful personality emphasizes the beauty of the face. There are numerous ways of defining beauty and it is often associated with charm. Charm, however, differs from beauty because it is permanent, whereas beauty fades. The English say, "Charm lasts! Beauty passes!" Ultimately, we can see that it is not only the eyes which judge whether someone is beautiful or not but the mind which plays a much greater role and judges the heart and inner beauty.

According to the American Sociologist Frumkin, a woman is judged in relation to her sexual charisma. Whether she is judged beautiful or not beautiful depends not only on the symmetry of her proportions but also on whether these attributes suggest potential sexual possibilities. The sensual emotion is then transformed into an aesthetic feeling.

Following these classic explanations, we can conclude that the perception of beauty differs among cultures and individuals and that it is not only a question of form and symmetry. A person's personality, charm and inner beauty play an important part in giving a person a pleasing image. The eyes alone do not make a judgment, but the head and the heart as well. The mind is influenced by our past experiences, which affect our judgment, just as our current experiences influence the future. One of Buddha's teachings tells us, "Today is the son of yesterday and the father of tomorrow." Beauty is like an iceberg; only one small part is visible.



---

Konrad Lorenz, Nobel Prize winner for Medicine and Physiology, has made a special contribution to our understanding of the biology of behavior. This has helped us to understand human beauty.

When someone feels drawn to a face, this is because the face has childlike features. Everyone instinctively feels attracted to a childlike face. The sight of a childlike face evokes an emotion that is automatically linked with a desire to protect. It is the same in both humans and animals. Konrad Lorenz explained this in the following terms: the desire to protect one's offspring is prompted by something which the offspring sends out, a physical peculiarity, a sound, a smell. It is the same in man. There are signals which provoke protective instincts, sympathy and tenderness. What are they, asks Konrad Lorenz? In infants, the signals come from the head. The roundness and fullness, the prominent forehead, the full cheeks, a small snub nose; all these infantile characteristics provoke a protective instinct. A child's face is associated with purity, friendliness, honesty, and vulnerability.

We know that women keep their curves, whereas men lose them. A good plastic surgeon should therefore ensure that during surgery he optimizes the characteristics which, as in a baby, provoke affection, tenderness, and a desire to protect.

Softness and roundness = tenderness.

Once again, to give the impression of beauty, it is of fundamental importance to be able to recognize childlike features in an adult's face. Features, however, are not the sole cause of the protective reflex; expressions are also important. These at least have the advantage that they are within the reach of everyone. A few people know how helpful expressions can be in getting someone to do something or in pleasing someone. The emotions which were elicited by Brigitte Bardot's childlike features were helped particularly by her famous "spoilt child"-like pouting. Just as well known are the childlike expressions used, or abused, by Marilyn Monroe and Audrey Hepburn. It has even been rumored that Marilyn Monroe deliberately made herself up badly to give the impression that she was a small girl who still did not know how to get ready properly and, even after long sessions at the hairdressers, immediately rumbled her hair to restore the disheveled appearance of a small girl who had just come in from playing. Men have no desire to protect women who do not have a childlike appearance and want to dominate men, and feel reminded more of their mother than their wife.

---

Women are more concerned with beauty than men and consciously or subconsciously display this childlike behavior. They are consciously or subconsciously shy, fragile, weak, innocent, naïve, ignorant, temperamental, admiring, inquisitive, etc. A few women even emphasize weaknesses to trigger the protective instinct. Have I already mentioned that apparent weaknesses in women are also their strengths? All this to strike a man directly in his heart. Napoleon said, “Women’s two weapons are make-up (the significance of this will be discussed later) and the tears of a small, helpless child.”

It is easy to understand why childlike features in an adult can move someone, in the same way as freckles, full red cheeks, long eyelashes, blond curls, well-defined and full lips. Among men, as we can see in a few of the great sex symbols, the side parting (Clark Gable, Gary Cooper), an untidy mane of hair (Leonardo de Caprio) and daily shaving can only be explained as the desire for a childlike appearance. It is not necessary, however, to have all these attributes; one is usually sufficient.

Every individual can display childlike features at any time. As regards particular features, if someone does not have these, he or she can usually acquire them with the help of cosmetic surgery. Beauty is not merely a completely natural phenomenon; instead, it has been a cultural phenomenon for a long time and this is the case particularly in the present day. People try to improve themselves and women, to whom beauty is more important than it is to men (men tend to try to obtain power), try to improve their beauty and charm with make-up and accessories like spectacles, false eyelashes, earrings, hair styles, permanent make-up around the lips, eyelids and eyebrows, hats, necklaces and the invisible accessory, perfume. A few modern accessories have been developed by beauty professionals to disguise beauty defects, e.g., wide spectacle side pieces hide crow’s feet, a high frame emphasizes the length of a nose that is too short and, conversely, a lower frame disguises a nose that is too long. All these strategies are discussed discreetly and in detail in women’s magazines. An old proverb describes this perfectly: “Thirty percent of beauty is natural, seventy percent is created by vanity.” The disadvantage of this resource is that it is not possible to look young and beautiful without it.

Make-up has always been around and if a face is to be beautified, it should be made to look natural and the face should resemble a young face. Lipstick, for example, creates the intense color of young red lips, which is a sign of a more rapid metabolism. Blusher is a reminder of

---

childlike red cheeks and powder gives the face the pale, velvety skin of youth. Desmond Morris called this over-stimulation. Long false eyelashes remind us of the long eyelashes of children. If applied badly, however, make-up can also ruin the beauty of a face. It can be both friend and foe. In ethnological books, we can read that in former times, witches improved the appearance of sick people so that the relatives were not shocked when they saw them.

Childlike features and expressions are therefore important in provoking the protective instinct, but the voice should also be soft and pleasant, like a child's. A hard, metallic voice, such as smokers have, is not reminiscent of that of a child.

Clothing should be pleasing to the eye and mind and it should have a good cut. The mini skirt makes us think of the long legs of an adolescent. Colors remind us of childhood; light colors, like blue or pink, are always chosen by old women. Naturally, black should be avoided.

In conclusion, all human senses should be stimulated: sight, hearing, smell (children do not have a smell – thus we use deodorant) and touch. The firmness of the skin is also important.

Beauty institutes have understood this for a long time and enthusiastically apply it. Do we not read in women's magazines: ladies have beautiful breasts, a flat stomach and good legs, but are they also firm? The firmness and elasticity of tissue are fundamental qualities of a child's skin and a part of their beauty. Beauty is costly. It is easy for wealthy people to get jewelry and beauty accessories, but these are more difficult to acquire without money. This is one explanation of the popularity of aesthetic medicine and surgery among the less well-off and among those who cannot please merely with their natural gifts or with the artificial resources of the wealthy. As they are only able to please with their body, the less wealthy will more readily pay for an operation to remove acquired or existing supposed defects so that they can continue to be admired.

The idea of using the child formula is well known. The heart should be receptive to generosity, and this is used for reasons other than just noble ones. Thus, for example, a child's face next to the product in an advertisement increases sales and turnover. Whether these are medications or other products, if the consumers are sensitive, sales will increase.

Naturally, a way to the heart is sought but also, and predominantly, a way to the wallet. The child formula strategy is likewise used to direct public

---

attention to countries in need, to collect donations, and to fight poverty and suffering. A begging child will always get more money than an adult. The Disney films, of which audiences are so fond, use ever smaller and ever more vulnerable animals; we always see the young mouse, the puppy or the fawn, never the fully grown animal. This also applies to toys. Usually, small animals and babies are used as dolls. As Saint Exupery said, "One can only see well with the heart."

It is also important to know that a physical defect also provokes a protective reflex. A few celebrated personalities and women involved in politics keep a slight squint, which could be easily corrected, to provoke this famous protective mechanism and thus strengthen their influence and power of persuasion. They do not want an operation. It is just as well known that if one part of the face is not perfect and other facial features are consciously highlighted, then the defect is less striking, as the eye is drawn to the emphasized features. If, for example, the eyes are beautiful and the nose is not, the eyes should be emphasized even more to disguise the unattractive nose. Make-up artists advise this even though they are not familiar with Konrad Lorenz's theories and nevertheless know how to beautify a face. A scar can deflect attention from the beauty of a face. To conceal public embarrassment, Passot says, "Give him a medal and he will be taken for a hero."

Similarly, make-up artists do not know about the Muller-Lyer illusion of two lines of equal length with arrows pointing in different directions at either end. Nevertheless, they know how to give eyes the appearance of being closer together, by applying make-up to the inner corner or, conversely, increasing the distance between the eyes by applying make-up to the outer corner.

The same applies to cheek bones in a face that is either too long or too short. Blusher is applied either further apart or closer together as appropriate.

Why be beautiful? The reasons suggested are pride, a desire to be admired and to be seen positively by others.

The cult of beauty is actually cultural. Humans are the only life form who do not accept their fate but try to improve it. Preserving beauty means improving the quality of life to beautify life. The progress of civilization in all areas has led to increased life expectancy. This does not seem to be sufficient; the quality of life must also be maintained and a

---

life must be “beautiful” for longer. Some people say that medicine has given a few more years to life; aesthetic medicine and surgery have given life to these years.

Beauty and fashion are external signs of our inner need to express and redefine ourselves. Fashion is only a stylistic device in the work of art which is life.

Beauty does not last forever but everyone knows that, at the same time, beauty does not have an age. It is possible to look good at 20 but it is also possible to remain irresistible for an entire lifetime, as Coco Chanel has remarked.

Madame de Pompadour said, “The first requirement of a woman is to please.” It is more and more difficult to fulfill this requirement with increasing age. This reminds me of an old woman who came to me and asked for a facelift. When I showed that I had little interest in performing this procedure because of her age, she said, in a quiet voice, “When one has ceased to please, one doesn’t have to displease for long.”

Ultimately, the desire to be beautiful is not a desire to be admired but a desire to be loved. In addition, this desire for love is ultimately the only thing that the followers of the cult of beauty want to communicate. Konrad Lorenz acknowledges this, “Everyone loves children and wants to protect them, this is hereditary.” Can you resent someone for wanting to be like them in order to be loved more? There is no doubting this theory. We should remember that the plastic surgeon should reconstruct child-like features in his work, if this is possible and wanted, to provoke positive feelings and admiration. We recognize the link between beauty and admiration and the intense fluctuations of the spirit and the mind. Theodore Gautier summarized this well, “To admire is to love with the mind, to love is to admire with the heart.”

Konrad Lorenz’s theory is strengthened with details. To provoke a protective instinct, an adult’s face must resemble that of a child; this is considered to be beautiful. The perception of beauty is subjective; the personality and qualities of the individual play a part. In those who experience this, this perception is influenced by earlier experiences.

Pierre F. Fournier, M.D.  
Honorary President of the French Society  
of the Aesthetic Surgery (National Society)  
Paris, France

---

## Foreword by M. S. Mackowski

After training in the field of plastic surgery for more than 20 years and holding the position of Consultant at the Department of Plastic and Reconstructive Surgery at the Ruhr University, Bochum, I have been the Leading Consultant and Deputy Clinical Director at the Bodenseeklinik in Lindau since 2004.

It was at this hospital, where aesthetic surgery is carried out and taught to the highest standards, that I first became familiar with Professor Mang's philosophy. He believes that aesthetic surgery is an interdisciplinary specialty in which mutual cooperation makes it possible to learn a huge amount.

During my numerous visits to plastic and aesthetic surgeons abroad, I have not found a hospital specializing in the field of aesthetic surgery anywhere which is as large, modern and well-organized as the Bodenseeklinik. It is not only aesthetic operations that are performed to the highest standards at the Bodenseeklinik; all types of plastic and reconstructive surgery are also carried out here, with a particular focus on breast reconstruction.

As Professor Mang's deputy, I have also got to know his human side and soon realized that in addition to having many years of surgical experience, he has a huge sense of responsibility towards his patients, an impeccable understanding of indications and an impressive desire to achieve. If Professor Mang can sometimes be impatient and demands too much from his colleagues, he is most importantly direct, kind and sincere.

I am extremely pleased that I will be able to assist Professor Mang in shaping the hospital over the coming years and foresee that a third volume dealing with breast reductions, breast lifts, body lifts, hints and tips for aesthetic operations and advanced surgical techniques for the facial, breast and abdominal areas will follow the successful Volume 1 (head and neck) and Volume 2 (torso).

Dr. med. M. S. Mackowski  
Specialist in Plastic Surgery  
Leading Consultant at the Bodenseeklinik  
Lindau, Germany

---

## Foreword by S. Malakhov

I first became acquainted with Prof. Mang in 2002 when he performed surgery at the St. Petersburg Medical Academy at the invitation of Prof. Zapessotsky. Many plastic surgeons watched him doing this and were fascinated by his atraumatic operation technique. One of my assistants went to Prof. Mang's clinic at Lake Constance for further study and reported back on the friendly and excellent training received in Prof. Mang's clinic.

On the occasion of his visit to St. Petersburg, Prof. Mang presented me with the first volume of the *Manual of Aesthetic Surgery*. I was impressed by the clear and concise way in which cosmetic operations were explained. This concept of audiovisual teaching was unknown at that time in Russia. All of my colleagues who have an interest in the subject of aesthetic and plastic surgery were also impressed with this manual.

The first volume dealt with cosmetic operations in the head/neck area, and the second volume describes cosmetic operations in the trunk area in a way that is just as clear and comprehensible. It is an ideal textbook for learning about aesthetic surgery; this type of operation has not previously been taught in this form, particularly in Russia.

I witnessed Prof. Mang's hospitality on the occasion of the International Conference for Aesthetic Surgery in Lindau in July 2003. I was impressed not only with the scientific part of the conference in which 600 people participated, but also with the social event on the occasion of the opening of Prof. Mang's new clinic.

There are plans to strengthen further and intensify this relationship between the clinic at Lake Constance and the Medical Academy in St. Petersburg. I wish Prof. Mang much success for Volume 2 of the *Manual of Aesthetic Surgery*.

Finally, I would like to complete my foreword by giving you a little information on the history of plastic surgery in Russia:

### **Plastic/Aesthetic Surgery in Russia – the Past and the Future**

Development of plastic surgery in Russia is closely associated with the name of the great Russian surgeon, N.I. Pirogov. It was he who first paid attention to the aesthetic results of surgery on open areas of the human body. In his famous book, *Basis of General War Field Surgery*, he touched

---

on the topics repeatedly. One of his followers wrote the thesis on rhynoplasty. In 1865 another brilliant follower Y.K. Shimanovskii published the first manual in the world for practical surgeons, *Human Body Surface Surgery*, for which he was awarded the I. Bush prize. This unique book contains more than 150 drafts and schemes of plastic surgery procedures made with the author's own hand, many of them still significant.

A little bit later in 1869, the young Russian surgeons (S.M. Yanovich-Chainski, A.S. Yatsenko, P.Ya. Pyasetskii) took up the idea of J. Reverdin concerning free transplantation of autodermal microflaps for closing wound defects and implemented the experience in Russia. In 1898, K.P. Suslov worked out the original method of the elimination of nose defects by transplantation of free skin-cartilage transplants from the ear.

Unfortunately, during the first decades of the twentieth century, there were three revolutions and the First World War, which did not favor the development of plastic surgery in Russia. Nevertheless, in 1916 the world-wide recognized work by V.P. Filatov was published. The work was dedicated to the results of using of round fat-dermal flaps developed by V.P. Filatov. This method was the only opportunity of tissue complex transplantation right up to the second half of the twentieth century when flaps with axial blood supply came into use. Other famous Russian surgeons who played an important role in plastic surgery development are: P.I. Diakonov, N.A. Bogoraz, A.A. Limberg, A.E. Rauer, B.I. Vozchek, B.S. Preobrazhenskii, I.M. Mikhelson, and many others.

After World War II, a special system was organized for the treatment of burn patients; this played a particular role in the formation and development of plastic surgery in Russia. During this research and organization work several generations of plastic surgeons grew up, who have a good knowledge of the most up-to-date methods of free and local skin plastic surgery procedures, including those using microsurgery. The methods of skin reconstruction by means of different variants of combined autoallodermoplastics were developed and implemented. The most significant names in this field were Y.Y. Dzhanelidze, T.Y. Arieiev, M.I. Shraiber, N.I. Atiasov, B.S. Vihriev, and others.

In 1930, in Moscow increasing interest in plastic surgery led to the creation of the Institute of Beauty, which is now called the Institute for Plastic Surgery and Cosmetology. In 1961 a similar clinic was opened in Leningrad. In the following decades this tendency developed rapidly, and now in Russia there are hundreds of centers working in the field of beauty surgery.



---

At the end of the last century, many specialists understood that plastic surgery is an independent and complex specialty that requires the long-term education of individual surgeons. That is why at the end of the 1980s and the beginning of the 1990s in Moscow the first structure for the training and retraining of plastic surgeons was included in the system of continuous medical education. In 1997 at the Saint Petersburg Medical Academy of Postgraduate Studies, the first special department and clinic for plastic and aesthetic surgery was created. Specialists in this department have experience in all methods of plastic surgery and educational work. The department provides long-term programs for the basic training of young specialists (3–5 years) and short-term programs for continuing medical education. The intensive research work of the departmental staff allows training programs to be refreshed and ongoing improvement of the surgery procedures.

All of the above means that the education of plastic surgeons is continuous and that their professional level is constantly renewed. The following events have favored the development of plastic surgery in Russia: creation of the All-Russian Society of Plastic, Reconstructive and Aesthetic surgeons; publishing of several periodicals; organization and holding of scientific conferences, seminars and master-classes in different regions of Russia; constant contact with international societies of plastic surgeons.

My colleagues and I believe that aesthetic surgery in Russia has a great future.

Professor S. Malakhov  
Head of the Clinic for Plastic  
and Aesthetic Surgery  
Saint Petersburg Medical Academy  
of Postgraduate Studies, Russia

---

## Foreword by D. Millesi

Aesthetic surgery has developed with enormous velocity over the past decade. Owing to the growing number of patients undergoing aesthetic surgery, it is not only more and more accepted in a wider range of our population, but also has to fulfill the growing expectations of very critical patients.

Many new techniques are at our disposition and the number is constantly growing. Apart from basic techniques, detailed technical points become more and more important for the successful outcome. It is nearly impossible to provide a complete survey of all techniques available today in a single textbook, not to mention the variety of technical details that are frequently not described. It is to W. L. Mang's credit that he elected the forum of a manual instead of a large textbook to present his great personal experience. In the first volume of his manual, W. L. Mang described his personal experience with rhinoplasty, rhytidectomy, eyelid surgery, and otoplasty. His techniques and his tricks are presented in the form of very instructive sketches, and any surgeon who wants to enter the field of aesthetic surgery can do this easily following the impressive illustrations. Now the second part of the *Manual of Aesthetic Surgery* is available. It covers liposuction, breast implants, hair transplantation, aesthetic surgery of the extremities, and abdominal plastic surgery. These regional chapters are complemented by a chapter of adjuvant therapies, including lipotransfer. The new volume is designed according to the same principles as the first volume. Again, the main focus is on the illustrations, which are easy to follow and help the reader to understand the individual surgical steps. In addition to the excellent optical presentations, a DVD is included, providing audiovisual presentations. I personally have had enormous profit from the brilliant images, and I am sure that the second volume will help beginners in this field in the same way. It would be advantageous if all prominent surgeons in aesthetic surgery would present their professional experience in way similar to W.L. Mang.

Prim. Dr. med. Dagmar Millesi  
Fachärztin für plastische und ästhetische Chirurgie  
Vienna, Austria

---

## Foreword by I. Pitanguy

In his first volume of *Manual of Aesthetic Surgery*, Professor Mang provided a clearly written and comprehensible book that can be read by all physicians who may have an interest in the field of aesthetic plastic surgery. Prof. Mang shared with us his vast experience in aesthetic surgery and presented the techniques that have proven useful in his hands.

Together with his team of collaborators at the clinic at Lake Constance, in Volume 2 Prof. Mang describes operations clearly and explicitly. Especially for the younger surgeon, this part of the book offers the opportunity to become acquainted with aspects of surgery of the abdominal and breast regions, as well as the upper and lower limbs.

When Prof. Mang first visited me in Brazil in 1971, he impressed me as a particularly hard-working colleague, eager for knowledge. Through his numerous visits to my clinic in Rio, and during my own visits to Germany, I have grown to know Prof. Mang and his delightful family well and to value the friendship that we have developed, with that special charm all the Germans are capable of giving.

With the completion of his new clinic at Lake Constance, Prof. Mang has fulfilled his life's dream. I wish both his clinic and this book much success.

Prof. Ivo Pitanguy, FACS, FICS  
Head Professor of the Post-Graduate Courses  
in Plastic Surgery of the Pontifical  
Catholic University of Rio de Janeiro  
and the Carlos Chagas Post-Graduate Medical Institute.  
Member of the Brazilian Society of Plastic Surgery,  
the Brazilian National Academy of Medicine,  
and the Brazilian Academy of Letters

---

## Foreword by H. U. Steinau

The second volume of Werner L. Mang's *Manual of Aesthetic Surgery* brings together his group of experienced plastic surgeons and specialized ENT and maxillofacial colleagues to share their profound personal knowledge in treating the most common aesthetic problem areas.

The new chapters "Implantation and Adjuvant Treatment of Wrinkles", "Hair Transplantation", "Liposuction" and "Body Contouring, Including Aesthetic Breast Surgery and Abdominoplasty" provide basic guidelines for safe and proper procedures and step-by-step operative details for different body regions.

Anatomical landmarks and potential pitfalls are clearly depicted and discussed. The publisher has provided coloured pictures of excellent quality with concomitant schematic drawings.

The chapters explain the selection of optimal operative strategies and details are given on their basic instrumental supplementation, surgical principles and potential problems. Advanced planning and selection of safe solutions are followed by various anesthetic regimens including tumescence techniques, which are now used routinely in ambulatory surgery.

Taken as a whole, the second volume represents a valuable contribution that will provide novices during residency with a broad-based training program. Its interesting case collections and methodologies afford experienced aesthetic surgeons with the opportunity to critically compare their preferred treatment options with convincing "second opinions".

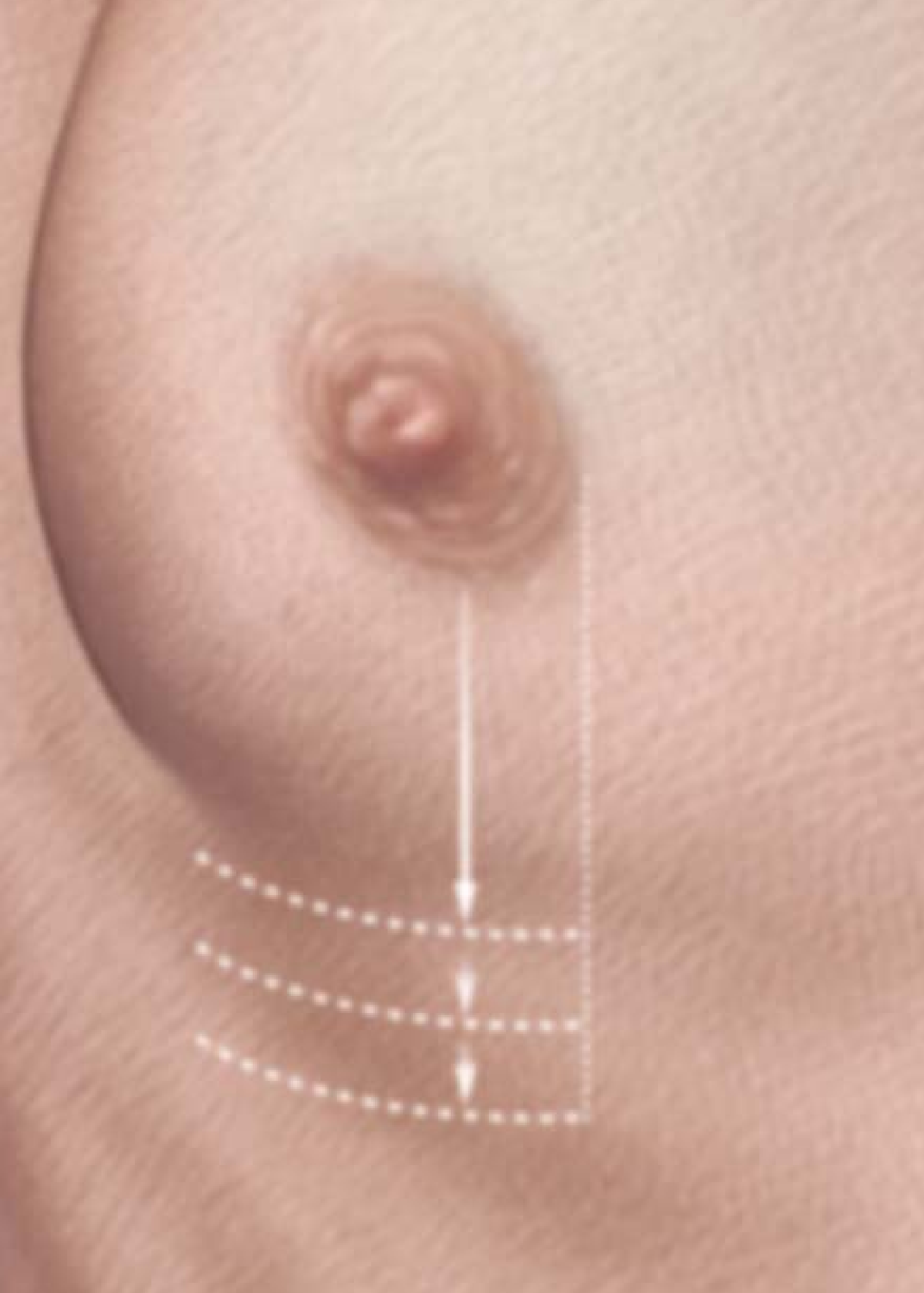Professor Mang and his multidisciplinary team are to be commended for their continuous educational efforts and outstanding didactic accomplishments.

Professor Dr. med. Hans U. Steinau  
Department of Plastic Surgery and Burns  
BG-University Hospital "Bergmannsheil"  
RU-Bochum, Germany

---

## Contents

- Breast Augmentation 1
- Brachioplasty 49
- Abdominoplasty 79
- Thigh and Buttock Lift 121
- Liposuction 157
- Hair Transplantation 203
- Adjuvant Therapies  
Including Spacelift 225



---

## Breast Augmentation

- Introduction 3
- Breast Implants 5
- Anatomical Overview 7
- Instruments 8
- Duplicate Patient Information 13
- Preliminary Examinations 13
- Photographic Documentation 13
- Surgical Planning 14
- ■ Incision Line in the Case of Submammary Access 16
  - Definition of the Subsequent Breast or Implant Size by Establishing the Distance Between the Lower Margin of the Nipple and the Subsequent Inframammary Fold 17
  - Positioning of the Patient, Disinfection of the Operating Area 18
- ■ Tumescence 18
- ■ Submammary Incision 20
- ■ Preparation, Step 1 20
  - Preparation, Step 2: Precise Demonstration of the Caudal, Medial and Lateral Borders of Pectoralis Major 22
  - Deep, Blunt Dissection 23
  - Wound Revision and Hemostasis Using the Illuminated Retractor and Bipolar Tweezers 24
- ■ Determining the Size and Shape of the Implant 24
  - Fitting the Final Implant 26
  - Exact Positioning of the Implant 28

The symbol ○ indicates parts of the procedures shown in the video.

- 
- Insertion of the Redon Drain (size 10) 28
  - ■ Deep Wound Closure 30
    - Two-Layer, Atraumatic Wound Closure Using 4.0 Monocryl 30
  - ■ Dressing 32
    - Aftercare 32
    - Appendix:  
Breast Augmentation – Submuscular Access 34
  - Results 38
  - Literature 45



---

## Introduction

Since the beginning of humanity the female breast has been synonymous with the idea of femininity. The “ideal” size, however, always depended on whatever was in vogue at the time, and any appropriate changes were made on illustrations. The first references to surgical interventions to increase the size of the female breast date back to the end of the nineteenth century. There are reports of treatments ranging from fat transplants to paraffin injections, from creams and various synthetic materials to silicone injections, and, as one can imagine, these had disastrous consequences. It was not until the 1960s that it became possible to develop usable silicone gel implants. The further development of these has continued until the present day and has given rise to a safe method of breast augmentation. This is due above all to the viscosity of silicone gel, which enables the implant to be as natural as possible. There are also saline-filled implants on the market, but these have inherent disadvantages. The saline can diffuse more easily through the outer silicone layer, which firstly may produce a loss and unevenness in size, and secondly may give rise to noises.

The advantages of titanium-coated hydrogel breast implants and others need to be demonstrated in long-term studies. For decades we have been using roughened implants with silicone gel (INAMED Aesthetics, Santa Barbara, CA; Düsseldorf, Germany [formerly McGhan Medical]) without complications and with a low capsular fibrosis rate.

Breast enlargement is a very frequently desired operation. This book presents the most simple, clear technique in order to ensure that the novice has a basic idea of how to introduce breast implants and to avoid risks. The simplest, safest access is by means of a 3- to 4-cm-long incision in the inframammary fold which, if it is made precisely, if an atraumatic suture technique is used and if there is good postoperative treatment, is hardly visible after 3 months.

The access described in the manual is very clear and easily understandable and also produces good aesthetic results. Of course, a breast implant may also be introduced via the nipple and via the axilla. This requires the person carrying out the operation to have appropriate experience. In some cases it will be indicated. Any breast implant, however, may be introduced without any problems by means of the access described in the manual. It is then up to the young aesthetic surgeon to build on this knowledge.

---

Once the question of access has been resolved, the second-most-important decision is whether the implant is going to be placed above the pectoralis major or underneath it. Here, too, the manual gives clear and easily understood instructions, namely, that generally, if there is good skin and gland coverage, the implant is positioned above the muscle, between muscle and gland. The operation is carried out macroscopically and the dissected pocket is monitored by means of an endoscope so that any bleeding is seen, all strands of connective tissue are cleanly cut through, and the implant pocket is prepared in an anatomically clean manner.

In a clinical study of 500 patients followed up at the Bodenseeklinik, the fibrosis rate was not significantly lower with submuscular access than with supramuscular access (<4%).

Submuscular access is and must be carried out if, following pregnancy or dramatic weight loss, only a very thin flap of ptotic skin is present, meaning that the covering is very weak. Otherwise an impression of the implant and a rippling phenomenon is unavoidable. In this case the implant must be placed under the muscle. This intervention is more laborious and causes more bleeding. The pectoralis major must be separated while in view, including by endoscope, at its lower margin up to the midline using an electric scalpel, cutting through its points of attachment on the relevant costal arches, directly from the rib. Subsequently, the muscular pocket can generally be dissected bluntly. A disadvantage of this method may be that the implant slips and that the muscle contracts and changes, which means that when the implant is in the submuscular position, there may be later cosmetic problems and changes if the submuscular pocket is not dissected completely cleanly.

Consequently, a novice in the area of aesthetic breast surgery should send patients who have difficult skin and ptotic breasts to an experienced breast surgeon. As a novice, one does not do oneself any favors by carrying out complicated breast operations. In this book, therefore, we have only selected subglandular breast implants with access via the inframammary fold since this intervention can be easily learned, is standardized, and is associated with low risk.

When implants are used, these should only be implants that have been licensed by the health authorities. Similarly, to start with one should not use implants that are too large (not over 350 g) since these are associated with significantly more postoperative complications and a significantly greater desire for subsequent operations than is the case of smaller implants.

---

## Breast Implants

Every day, women in Germany fulfill their dreams of having well-formed breasts. While the round shapes – which are obviously implants – are still preferred in the USA, German women want their surgically enlarged breasts to have a natural appearance: the ‘tear shape’. Yet, it is not only important to have a natural appearance; the implanted material should also feel as natural as possible. Tear-shaped implants are made entirely of silicone – with good reason. Other materials used for breast implants have proved to be extremely disadvantageous for patients. Sodium chloride is certainly safe as regards patients’ health but it has drawbacks: the implants gurgle and the material has nothing in common with the surrounding breast tissue. For this reason, only McGhan silicone gel breast implants from Inamed Aesthetics\* are used at Professor Mang’s Bodenseeklinik. As the sole manufacturer, Inamed Aesthetics has experience with these implants stretching back more than 25 years. This is an important point as the quality and safety of the implant play an important role in the result of the breast operation. Publications throughout the world confirm the fact that these implants have the lowest complication rate, which is in line with the high quality and safety requirements at the Bodenseeklinik.

A standardized quality mark for breast implants has been in existence throughout the entire European Union for three years. This guarantees that the implants will not harm patients’ health. The silicone implants used today are filled with cross-linked (cohesive) silicone and therefore cannot leak. If such an implant is cut open, the contents appear as firm as a wine gum. The surface has also been made rough which ensures that the implant meets completely naturally with the tissue. Inamed Aesthetics guarantees the safety of the implants with the INAMEDPlus guarantee program.

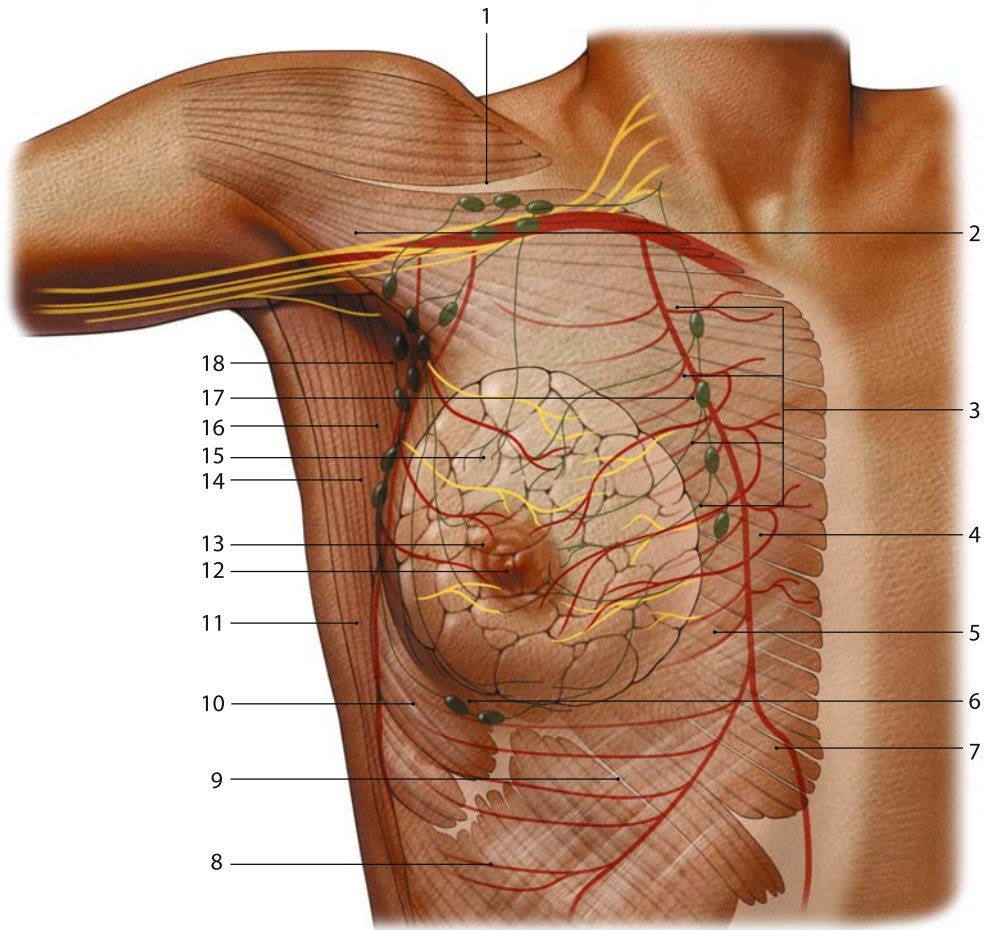
This program covers every McGhan silicone gel breast implant which has been explanted due to unexplained damage to the implant shell and the resultant rupture of the shell. The decisive factor is that it was implanted after March 31 2004.\*\* Even in such highly unusual cases,

---

\* Inamed Aesthetics GmbH, Hansa-Allee 201, 40549 Düsseldorf, Germany.

\*\* Breast implants which were used before 31 March 2004 come under the Inamed Aesthetics Standard Product Exchange Program. Inamed Plus is offered in addition to the Inamed Aesthetics Standard Product Exchange Program. This represents a new era in breast surgery and will make many patients feel safer. From June 2004 the company Inamed issues a life-long guarantee for breast implants.

only a cosmetic correction is required – the patient’s health has not been put at risk because of this at any time. If the explanted product is no longer being produced, it will be replaced by a current and equivalent breast implant. And what is more, patients affected by this will receive a financial contribution of up to 1,000 Euro for explantation required as a result of damage to the implant shell, as long as this is carried out within 10 years after implantation. More detailed information on this exclusive guarantee program can be obtained directly from the Bodenseeklinik on request.

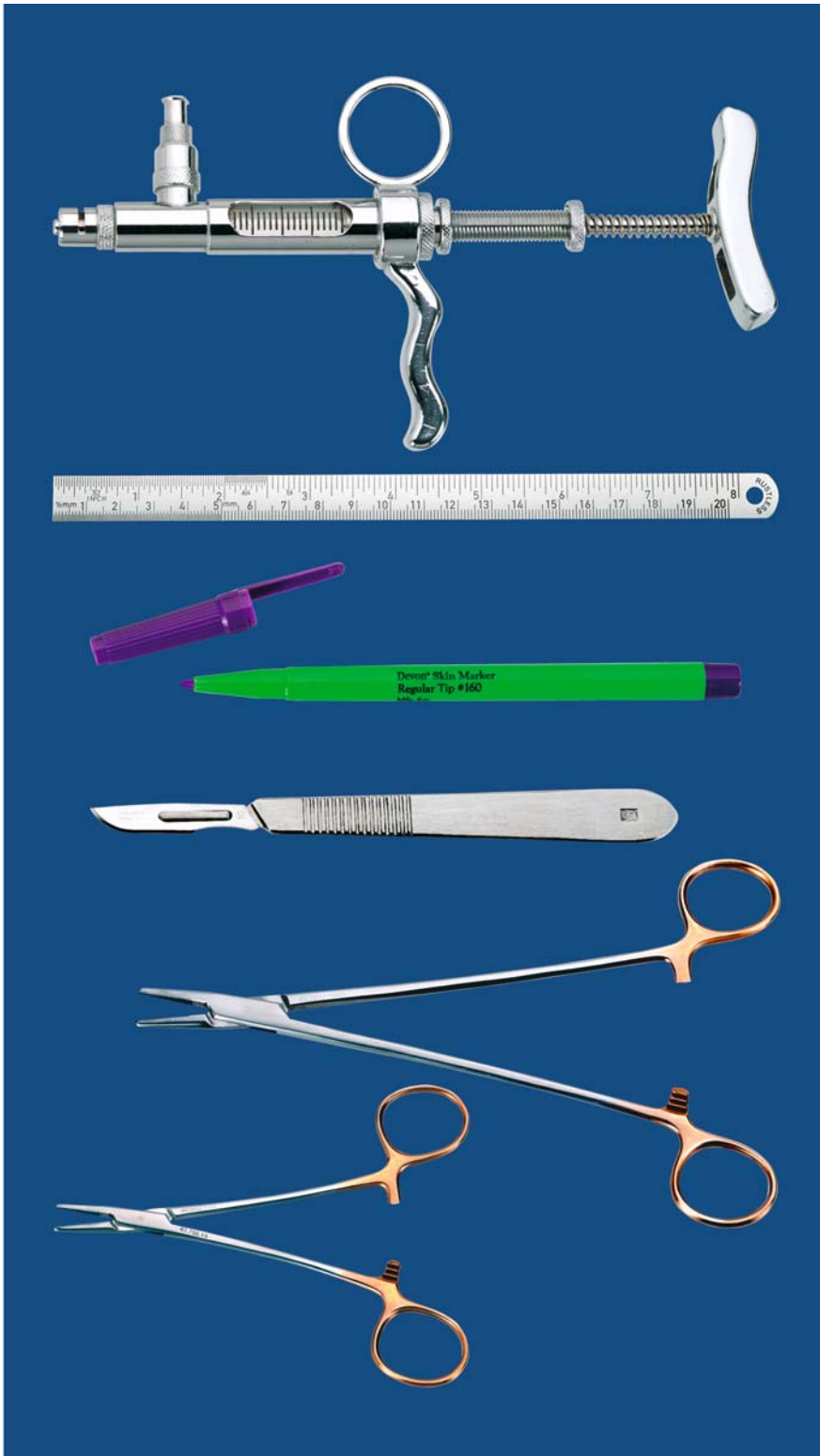


### Anatomical Overview

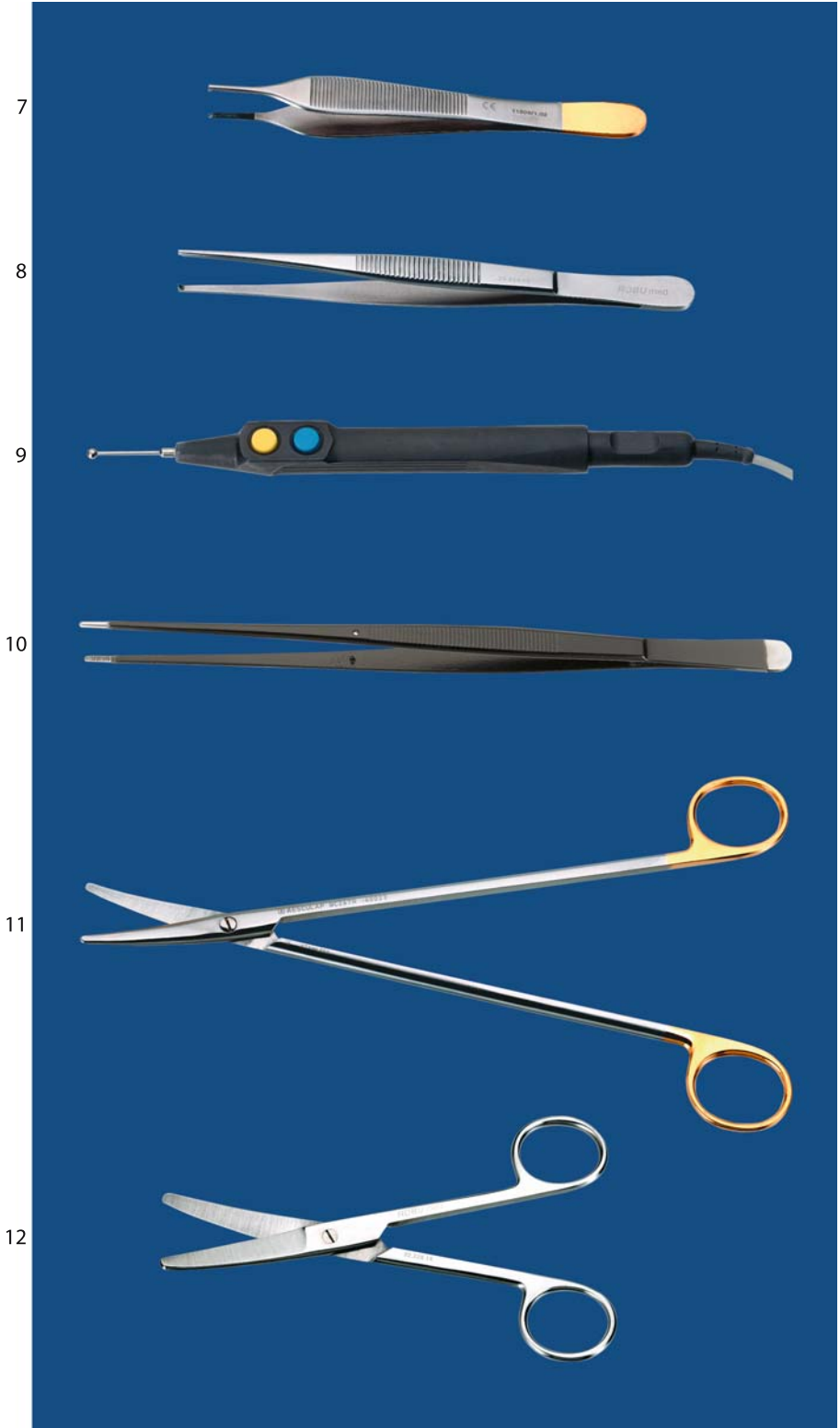
- |                                |                             |
|--------------------------------|-----------------------------|
| 1. Infraclavicular lymph nodes | 10. M. serr. ant.           |
| 2. Cervical plexus             | 11. Thoracodorsal artery    |
| 3. Parasternal lymph nodes     | 12. Areola                  |
| 4. M. pect. major              | 13. Nipple                  |
| 5. Pectoral fascia             | 14. Paramammary lymph nodes |
| 6. Submammary lymph nodes      | 15. Breast                  |
| 7. Superior epigastric artery  | 16. Lateral thoracic artery |
| 8. M. ext. obl.                | 17. Internal mammary artery |
| 9. Intercostal arteries        | 18. Axillary lymph nodes    |

### **Instruments**

- Pump-syringe [1]
- Centimeter rule [2]
- Sterile marking pen [3]
- Scalpel [4]
- Large needle holder [5]
- Small needle holder [6]
- Adson tweezers with plate [7]
- Coarse surgical tweezers [8]
- Monopolar electrocoagulation [9]
- Insulated anatomical tweezers for hemostasis [10]
- Large Metzenbaum dissecting scissors [11]
- Cooper scissors [12]
- Illuminated retractor [13]
- Langenbeck retractor [14]
- Sharp 4-pronged retractor [15]
- Redon introducer [16]
- Curved forceps [17]
- Roux retractor [18]

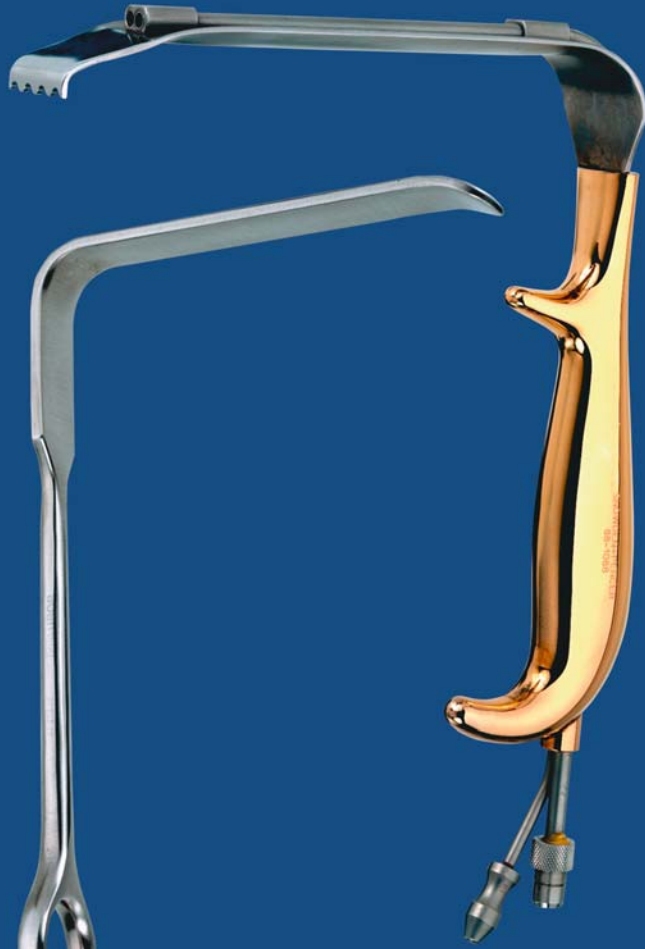

**Breast Augmentation**





13



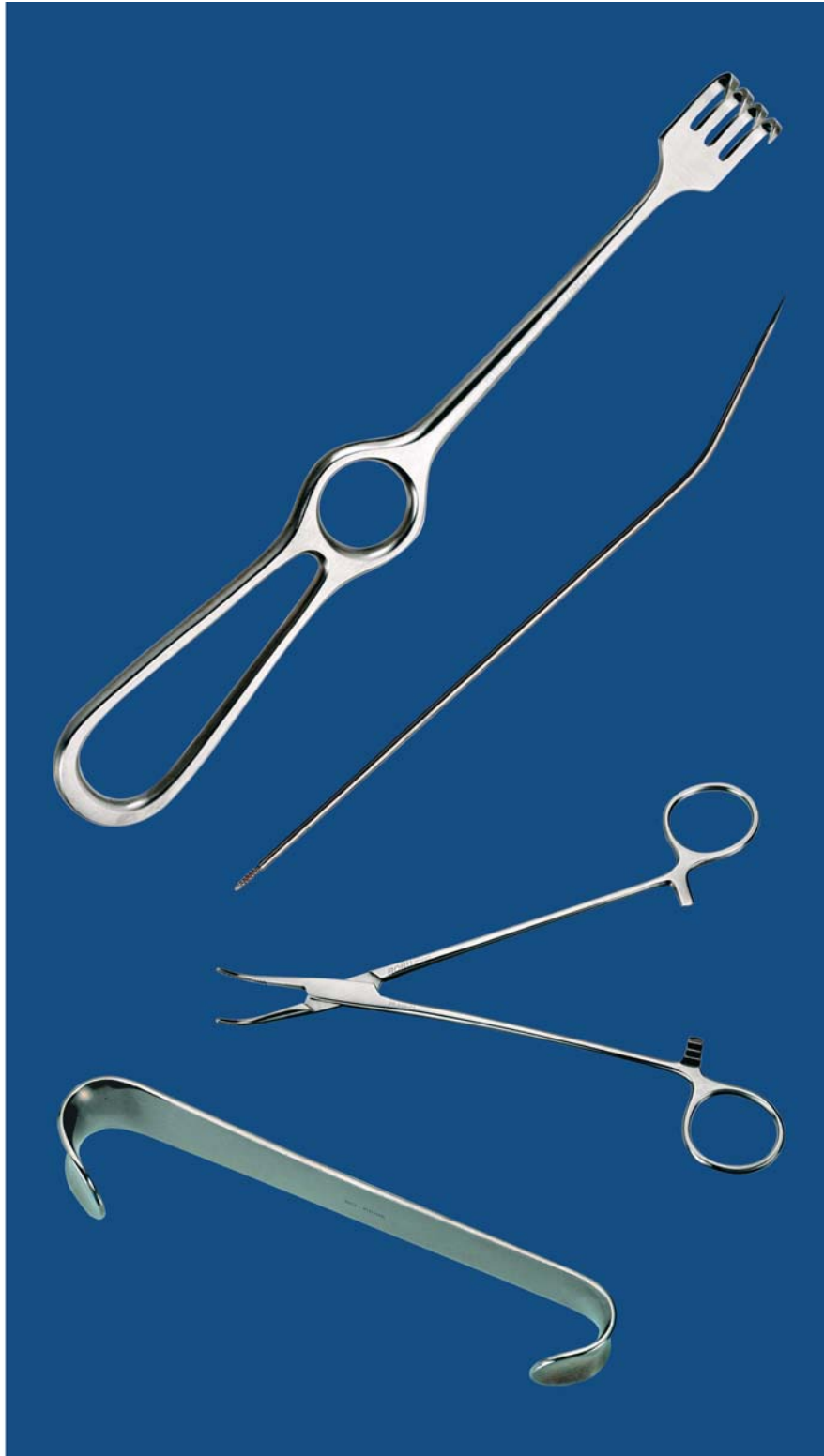
14



15

16

17



---

### **Duplicate Patient Information**

The patient is first given comprehensive information about the objectives and risks of the procedure on the day of the first consultation. A written record is kept of this.

One day before the surgical procedure, the patient is again given comprehensive information on two separate occasions: once by the surgeon and once by the surgical resident. All the risks are set down in writing at this time.

In addition to general operative risks such as wound infection, impairment to wound healing, injuries to blood vessels and nerves, scar formation, subsequent bleeding, thrombosis and embolism, in the case of breast enlargement it is also necessary to give information to the patient about circulatory disturbances and sensitivity disturbances relating to the nipple, impairment of ability to breast-feed, necrosis of the skin, glands, and adipose tissue, asymmetry (especially if this exists already before the operation) and specifically about capsular fibrosis, prosthetic defects, and possible displacement of the prosthesis.

### **Preliminary Examinations**

- Current results of preoperative routine laboratory tests
- Up-to-date mammogram with findings
- Clinical examination, particularly of the nipple and axilla

### **Photographic Documentation**

Upper body, standing:

- Frontal
- Half turned to the right and left
- Side view right and left

---

## Surgical Planning

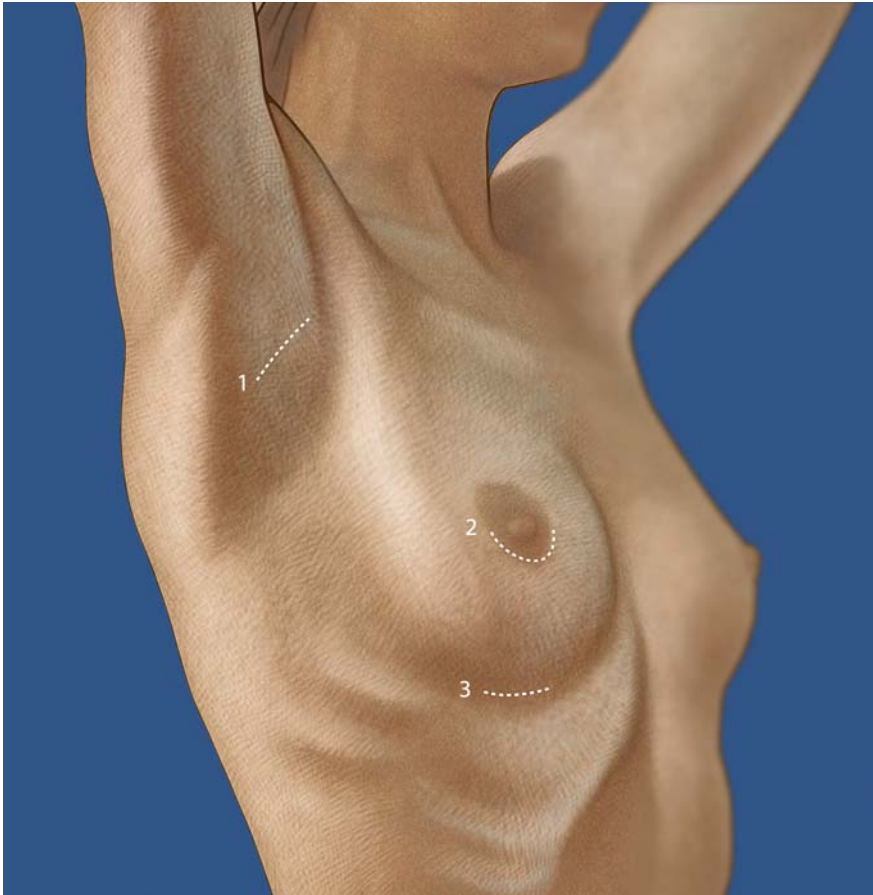The operation is performed under general anesthesia achieved with endotracheal intubation or laryngeal mask ventilation. The day before the operation the doctor carrying out the operation discusses with the patient in detail what changes the latter desires and how these can be achieved by the surgeon. The patient must be warned about having unrealistic expectations, and the patient must be informed in detail about postoperative behavior. There should be intra-operative single-shot infection prophylaxis with 2 g cefaclor.

The surgical planning must incorporate information about the skin condition, muscle thickness, a mammogram, or ultrasound of the breast. It must also cover the shape of the chest, the current size of the breast, circumference of the thorax, and the weight and stature of the patient.

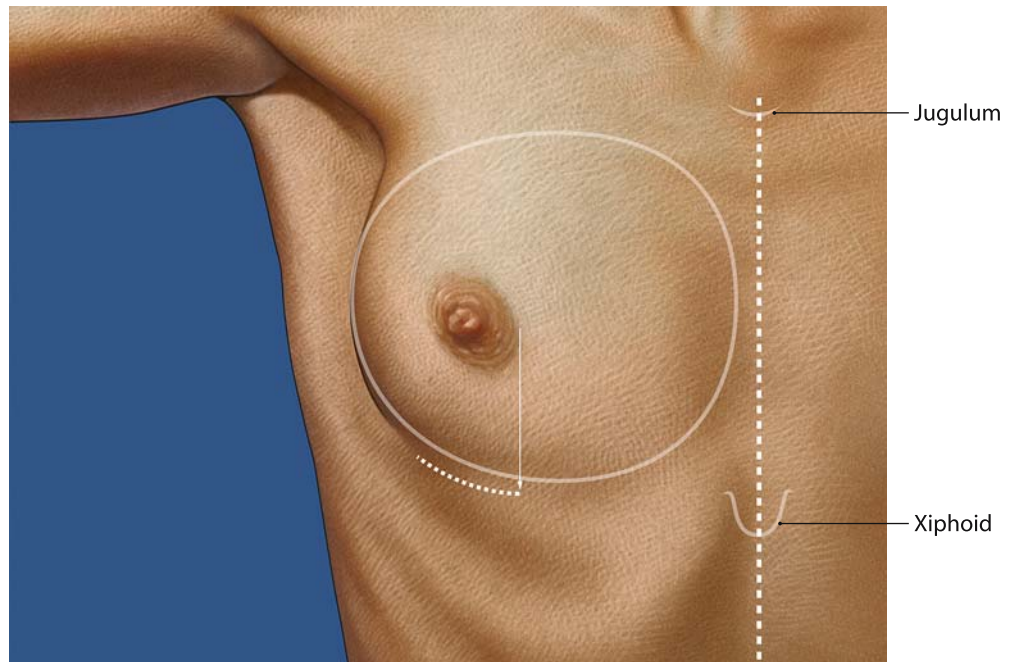
A novice in breast augmentation surgery should start with implants that are not too large (no larger than 320 g) and begin by using the safest access. This is access in the inframammary fold (3). This access (approximately 3–4 cm) is free from problems, can be clearly seen, and is easy to learn. It ensures safe dissection in view and low-risk introduction of the implants.

Wound closure without tension using a 4.0 poliglecaprone 25 (Monocryl) intracutaneous suture ensures that the scar is as good as invisible if there is normal wound healing and good care is taken of the scar. Often this scar is less unsightly than the scar that is produced with axillary axis (1). With regard to the latter, patients often complain that they have an unsightly scar when naked. Periareolar access (2) is very rarely indicated. This may lead, in addition to visible scar formation, to sensitivity disturbances in the nipple area. Both forms of access (1 and 2) should be in the repertoire of a well-trained aesthetic breast surgeon. Since this manual is primarily intended to convey basic knowledge, the video and text will give detailed information about submammary, i. e., supramuscular, access. As an appendix to this chapter, reference is made to submuscular access, which is indicated if the skin is poor, in order to ensure better coverage of the implant and to avoid the phenomenon of rippling.

Submuscular access is more invasive since the pectoralis major has to be completely separated at its caudal and medial point of attachment. Detachment of the muscle makes the breast more susceptible to subsequent deformation. The nipple is not lifted upwards to such a large extent, and on the basis of our studies (comparison of 100 patients)

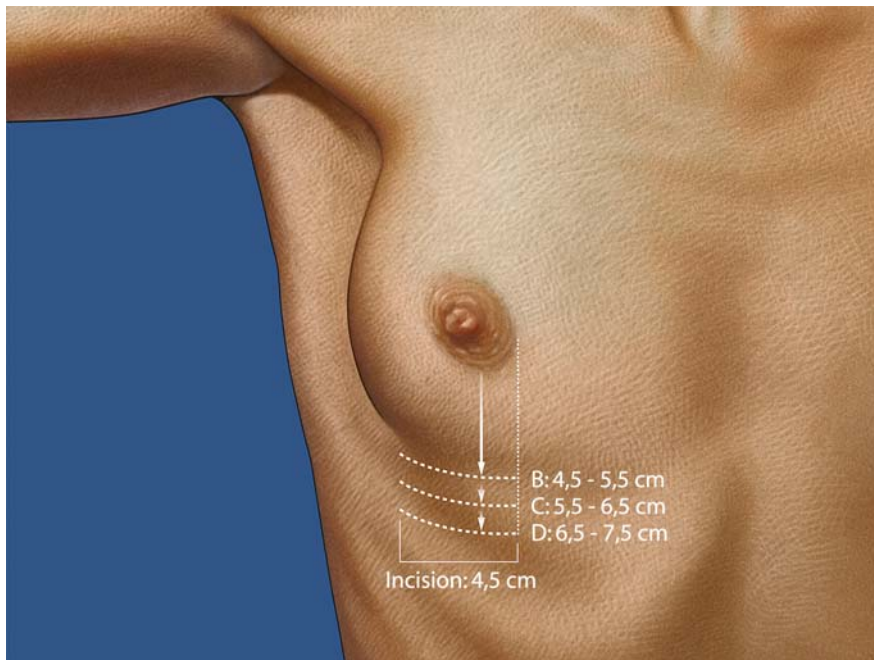


the fibrosis rate does not differ significantly between the submuscular and supramuscular position (<4%). In most cases the implant may be placed above the muscle (in over two-thirds of our patient group).



#### ● Incision Line in the Case of Submammary Access

- The incision lines are marked on the evening before surgery or on the morning of the operation with the patient standing upright. First the jugulum is marked, then the midline down to the xiphoid and the navel. Next the cranial boundaries of the mammary glands are marked by pushing the breast upwards with the palm of the hand. Depending on the intended degree of augmentation, the incision line is made either at the level of the inframammary fold or a corresponding 1–3 cm lower. The medial incision boundary should not extend beyond the medial boundary of the nipple. The incision line is normally 3–4 cm and runs, swinging slightly, precisely in the line that will subsequently be the inframammary fold. It may be positioned slightly higher, but should never be too low, i.e., underneath the inframammary fold, since the incision could be seen when wearing a bikini.
- From the medial margin of the nipple, a line is drawn in a caudal direction. This vertical marking line may not be exceeded by the incision in a medial direction, since this scar region may be visible.



**Definition of the Subsequent Breast or Implant Size  
by Establishing the Distance Between the Lower Margin  
of the Nipple and the Subsequent Inframammary Fold**

- The distance from the nipple to the inframammary fold is measured. By pushing the breast upwards with the palm of the hand in a medial, cranial, and lateral direction, the existing boundaries of the mammary glands are marked. Depending on the findings and on the patient's wishes, the surgeon carrying out the operation draws the extension of the breast boundary in a medial direction (shrinking the intermammary distance), or in a lateral and caudal direction, according to the desired enlargement and change in the form of the breast.
- It is particularly important to be aware of the inframammary fold, which with appropriate enlargement of the breast must be moved in a caudal direction so that it does not, after the operation, come to rest on the lower breast pole but in the new inframammary fold that is in a lower position.
- The submammary incision is drawn in the submammary fold, or parallel to this but lower, beginning medially from the vertical extension of the medial areolar boundary to the intended submammary fold. The length



in the lateral direction is usually approximately 4 cm and therefore enables the usual types of implants to be introduced easily. The distance from the lower pole of the nipple to the incision in the subsequent fold enveloping the breast is dependent on the desired breast size (B, C, D) and therefore on the size of the implant. The larger the implant, the greater the distance. A rule of thumb is that:

- Size B: approximately 4.5–5.5 cm
- Size C: approximately 5.5–6.5 cm
- Size D: approximately 6.5–7.5 cm

#### **Positioning of the Patient, Disinfection of the Operating Area**

[0.9% NaCl 500 ml, 1% prilocaine 250 mg (equivalent to 25 ml), epinephrine 0.5 mg, 8.4% NaHCO<sub>3</sub> 5 mEq]

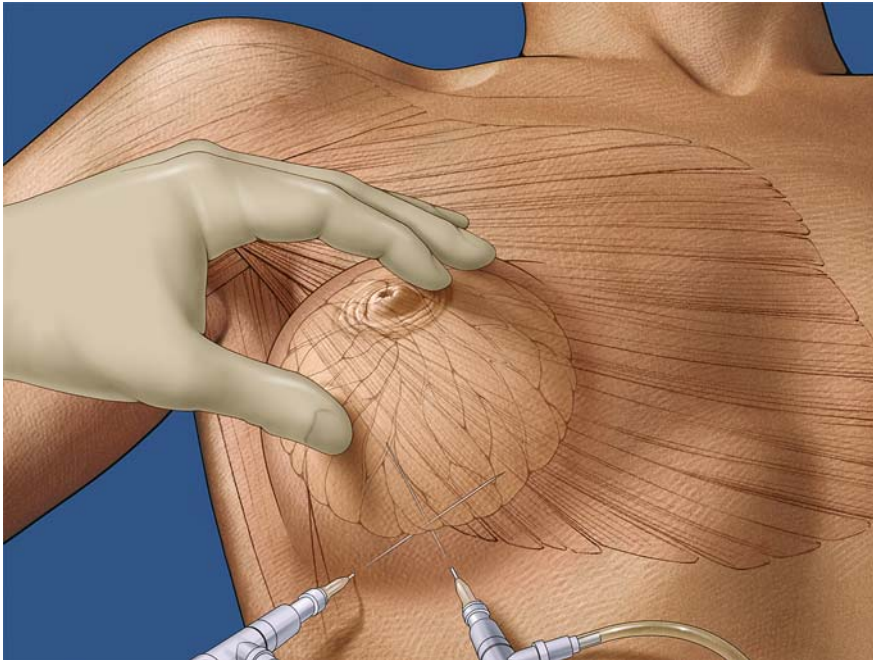
- Following intubation (if the patient wishes, the operation may also be carried out under general anesthesia with laryngeal mask ventilation or by means of tumescent local anesthesia), the patient should be positioned on her back with a slightly raised upper body (30%–40%). The arms are approximately 75% abducted. Attention must be paid here to any tension or pressure. We recommend using soft silicone cushions under the entire arm so that there is no nerve damage to the brachial plexus. Similarly, when operating it must be ensured that neither the operating surgeon nor the assistant leans on the arms.
- Disinfection is carried out carefully using the colored disinfectant solution Cutasept. The sterile draping is applied in such a way that the operating area is protected from the head/neck or anesthesia area.

#### **○ Tumescent**

The advantages of prior tumescence (manually or mechanically using a pump) are impressive. There is less bleeding. The gland is lifted from the fascia of pectoralis major. As a result, dissection is simple because the correct layer is easily located and time is saved. Wound healing is faster.

Initially, the incision area is infiltrated to deep into the muscle fascia. Then by pulling up the mammary gland with the left hand, tumescence is continued in the prefascial, parasternal, and lateral regions in the whole of the dissection area. As an operating surgeon, one detects how the gland becomes detached from the muscle fascia and can predissect the subsequent dissection boundaries and layers with the tumescence needle. As a result, much time is saved in the dissection process since this





dissection can generally be carried out using the finger as a blunt instrument, in the correct layer and completely without bleeding. For this reason it is important that the surgeon performing the operation carries out the tumescence him/herself and does not leave it to his assistant.

- Approximately 100 ml of tumescence solution is infiltrated on each side, depending on the size of the breast. In the process, the complete mammary gland is lifted up from the pectoral muscle.

On the basis of a clinical trial, which involved the introduction of breast implants with and without tumescence ( $n = 100$ ), we have shown that postoperative swelling and pain are reduced and that the healing process is accelerated.

**Note:**

Liberal preoperative tumescence of the operation site may be confusing for inexperienced surgeons since it results in an increase in the breast volume.

---

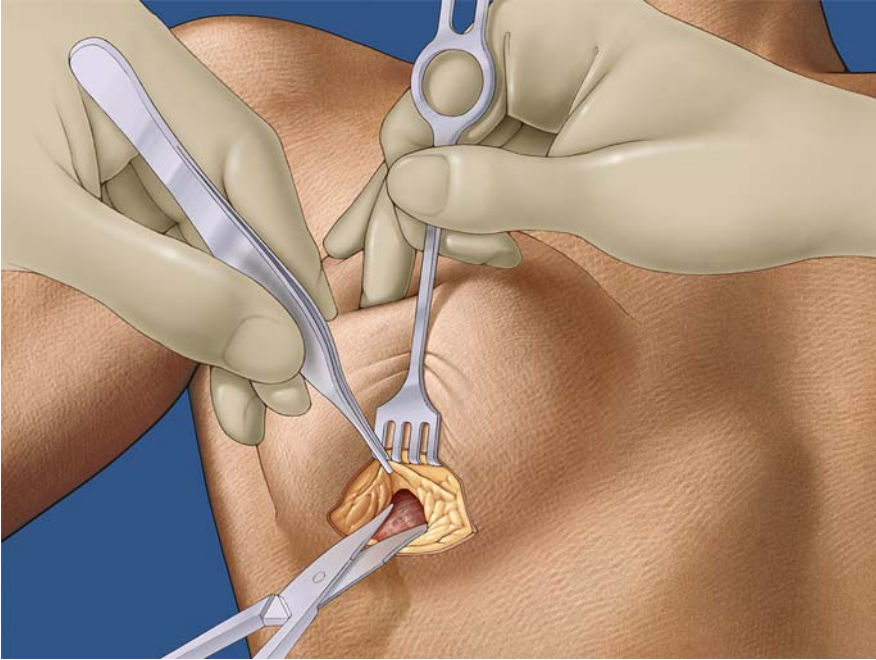
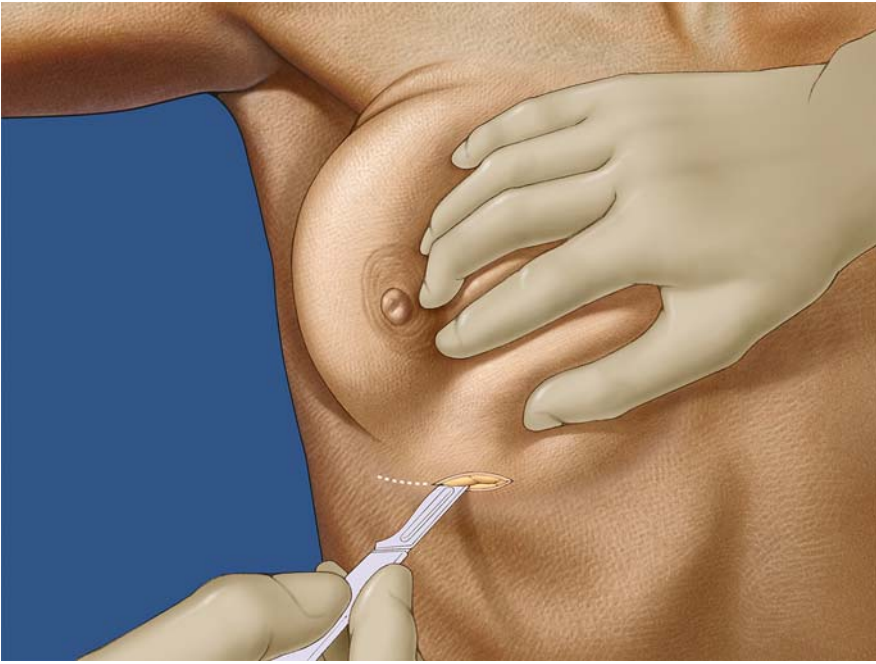### ◉ Submammary Incision

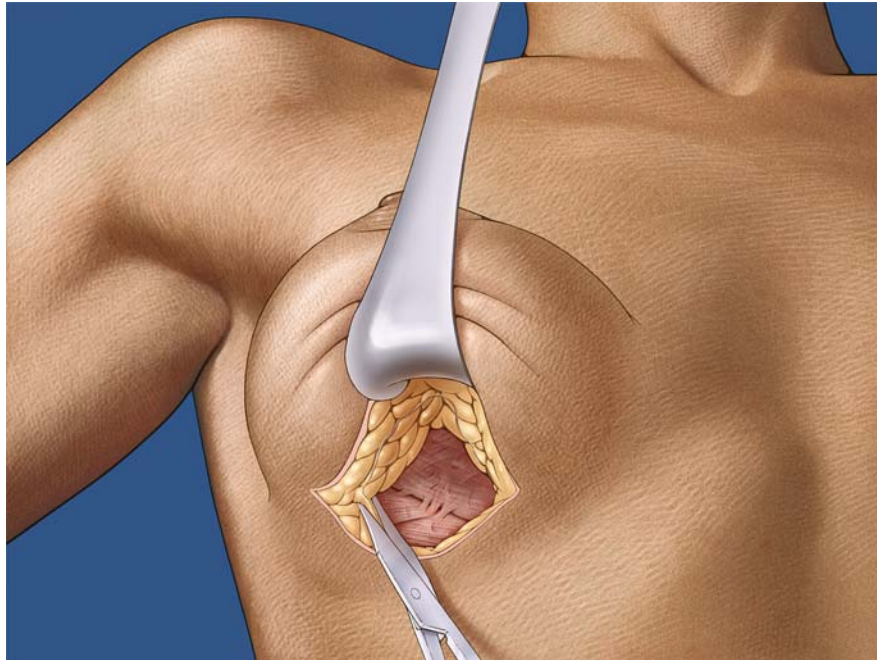
- The breast is lifted up by the assistant using his/her right hand, and the operating surgeon makes an incision precisely at the position previously marked. It should be ensured here that the incision from the medial to the lateral level is performed in a slight arch shape that matches the intended inframammary fold, since this makes the subsequent scar as inconspicuous as possible. The incision is made fully into the subcutaneous adipose tissue.

---

### ◉ Preparation, Step 1

- Using his/her right hand, the assistant holds the sharp four-pronged retractor under traction on the upper incision margin in such a way that the operating surgeon can carry out the dissection along the mammary gland in the direction of the pectoralis major fascia cleanly and without bleeding using surgical tweezers and Metzenbaum dissecting scissors. Owing to the tumescence this is largely free from bleeding. The excess tumescence solution flows back out again. If there are small amounts of bleeding, the sites can be coagulated using bipolar tweezers.

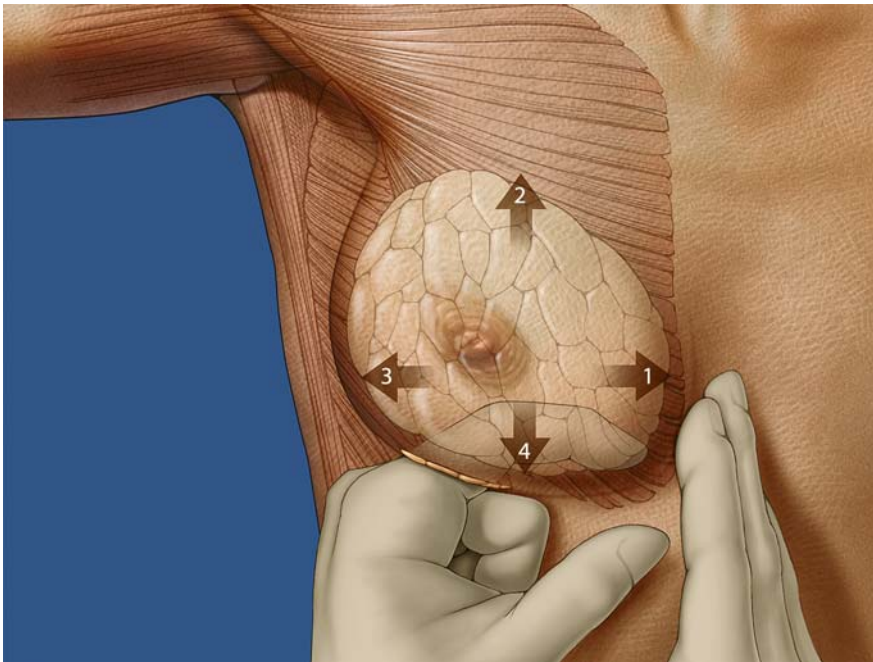




### **Preparation, Step 2: Precise Demonstration of the Caudal, Medial and Lateral Borders of Pectoralis Major**

The use of an illuminated retractor or a forehead lamp enables one to get an overview of the operation site. Strong strands of connective tissue are dealt with by sharp dissection in the lateral and medial directions. In view, the entire lower part of the breast muscle can be demonstrated very well. Tearing of the fascia or muscle should be avoided. Strong strands of connective tissue generally lie medially in the direction of the sternum. These must be dissected cleanly and sharply, in view. Bleeding from the vessels that perforate the fascia should be stopped carefully using bipolar tweezers since this is often the cause of postoperative bleeding.

- In this dissection step, the sharp four-pronged retractor is exchanged for a Roux retractor. The assistant holds this up under traction so that despite the small cut, there is a good clear view of the operation site. One must leave oneself time for this dissection step. When the correct layer has been found, i. e., when one is exactly on the fascia, further dissection of the whole implant pocket can generally be carried out using just the right middle or index finger as a blunt instrument.



### Deep, Blunt Dissection

- When forming the pocket for the subsequent implant, it is important to dissect sufficiently in the cranial and medial directions, in order to obtain a soft, inconspicuous transition of the implant margin. In the medial direction, one should ensure that there is no connection between the sites of the left and right implants. There should be a safety margin of at least 3 cm, since otherwise there will not be a good aesthetic result.
- In addition, when carrying out blunt dissection, one should ensure that the pocket is not taken too far in the lateral direction, since this could cause the bed of the implant to be too big laterally, producing separation of the breasts, i. e., they slide to the side and the result is not good. It is important that the breast “stands” and that in the lower neckline, the medial, cranial margin is well positioned, without the implant or the margin of the implant being discernible. The art of implant surgery is to create an implant site that constitutes an optimum precondition for the implant.

As a result of the prior tumescence, detachment of the gland from the fascia is trouble-free. The boundaries must be smooth in all directions and they must be sufficiently extensive so as not to cause later creasing



---

of the implant. If the dissection using the middle or index finger as a blunt instrument in the medial and cranial part is not completely successful, this dissection may be completed using Metzenbaum dissecting scissors with the illuminated retractor. Pushing to the side can easily be performed bluntly.

- The implant compartments must be identical to the marking lines that were drawn before the operation. It should be ensured that the two implant pockets are symmetrical and the same size. Consequently, before incorporating implants, both the implant sites should be examined very precisely and hemostasis should be carried out twice using the bipolar tweezers.

### **Wound Revision and Hemostasis Using the Illuminated Retractor and Bipolar Tweezers**

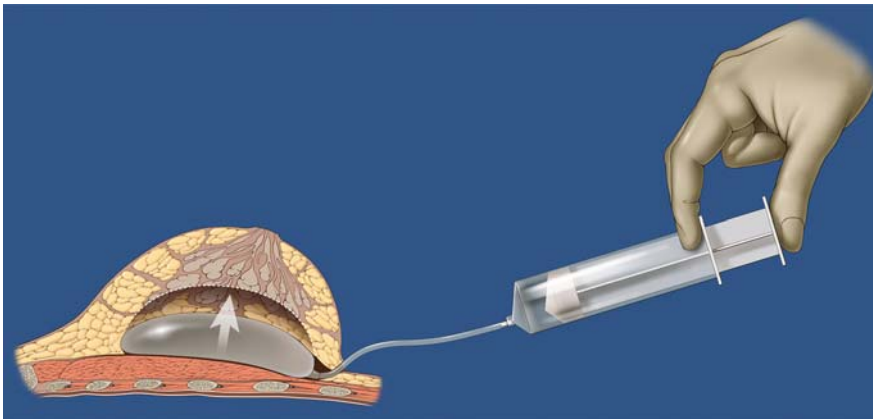
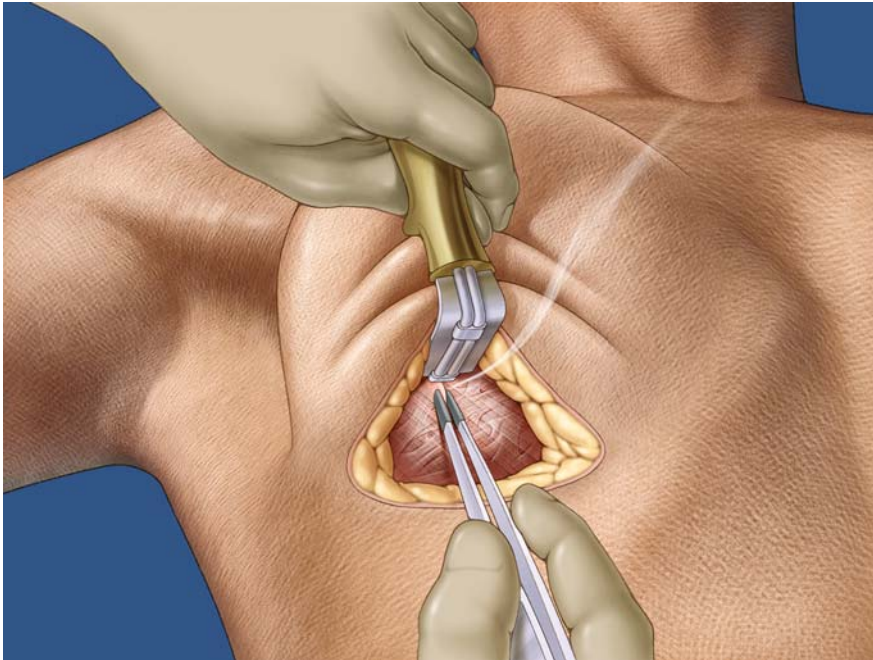
- Hemostasis is carried out by means of electrocoagulation and with the assistance of an endoscope or an illuminated retractor. This hemostasis is carried out twice. One always begins with the right breast. After dissection and hemostasis have been completed, a damp compress is applied. When the left side has been dissected, a second hemostasis is carried out before incorporation of the implant. Until now, we have not seen any postoperative bleeding in patients where this second hemostasis has been carried out. The patient, however, must not get up for 24 h after the operation, during which time her blood pressure is monitored, and the patient is supine with the upper body raised and with a light compression bandage.

### **◉ Determining the Size and Shape of the Implant**

The shape and size of the implant depend on the individual. The operating surgeon must have a stock of implants that comprises all common sizes and shapes (anatomical, round, etc.). The size is dictated by the skin and muscle conditions. If, as an operating surgeon, one is faced with the decision of using a larger or smaller implant, then as a novice one should choose the smaller implant. At the beginning the selection of the shape of the implant is not so crucial. This is also something one can talk about with the patient before the operation using implant samples. It is definitely not wrong to begin with round low-profile implants\*. Later one can then incorporate other shapes into one's repertoire.

---

\*Inamed Aesthetics GmbH, Hansa-Allee 201, 40549 Düsseldorf, Germany



The sizers produced by implant manufacturers are helpful when it comes to determining the implant to be used. Implants of any size can be simulated. The incorporation of the sizer is trouble-free and involves the assistant holding open the operative access using a Langenbeck retractor. The sizer is filled up until the agreed breast size is obtained. The same procedure is repeated on the opposite side. The sizer also enables one to balance out differences in the size of the breasts very well.

---

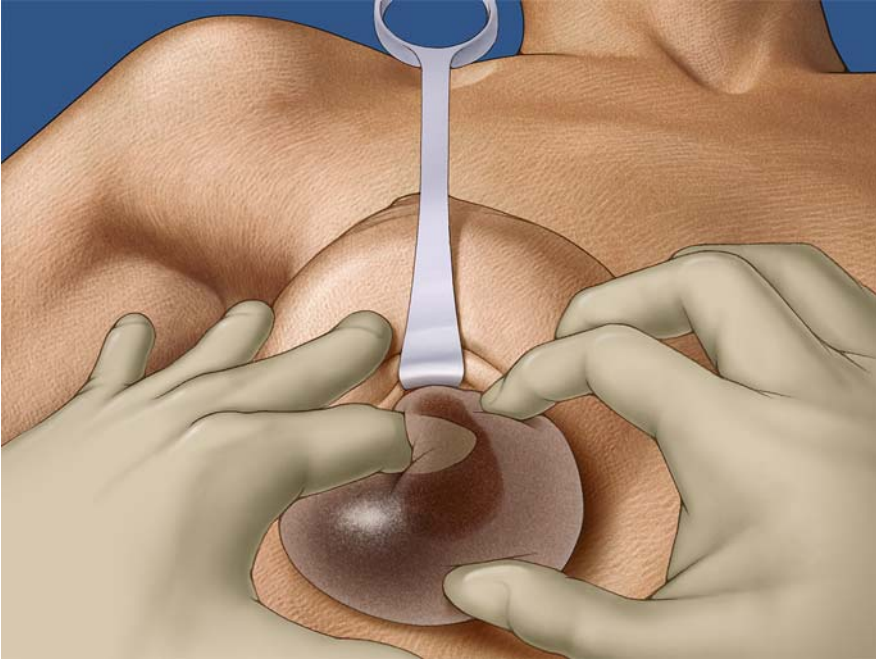Together with INAMED we are also developing sizers of different shapes, which means that it is possible, intraoperatively, not only to determine the size, but also the selection of the shape. As a result one can determine more easily what shape of implant is best for each type of breast.

### **Fitting the Final Implant**

- After removal of the sizer and after hemostasis has been carried out again, the implant, which has been immersed in betadine (Betasisadona), can be fitted. To do this the assistant holds the skin and gland tissue using a medium-sized Langenbeck retractor demonstrating the apex with strong traction in a cranial direction. The operating surgeon fixes the implant at the opening with his or her index finger and uses the other hand to prevent the implant from sliding out. Through alternating movements of both index fingers, the implant is introduced through the small opening. In doing this the correct position of the prosthesis must be checked, and it must not be allowed to unfold. The incorporated prosthesis is then smoothed out both above and below the implant using the finger.
- In the center of the base, i.e., on the underside of the implant, there is a small nipple. After incorporation of the implant, this should be positioned approximately at the height of the actual nipple. The implant must be free over its whole base and without folds and ideally fill out the entire dissection boundaries, without causing impressions, particularly in the cranial and medial part (bulging); if this is the case, the dissection of the implant site has not been sufficient. In these circumstances a smaller implant must be used or the implant pocket must be enlarged.

This cannot happen if the shape and size of the implant have previously been correctly determined using the sizer.





**Breast Augmentation**

---

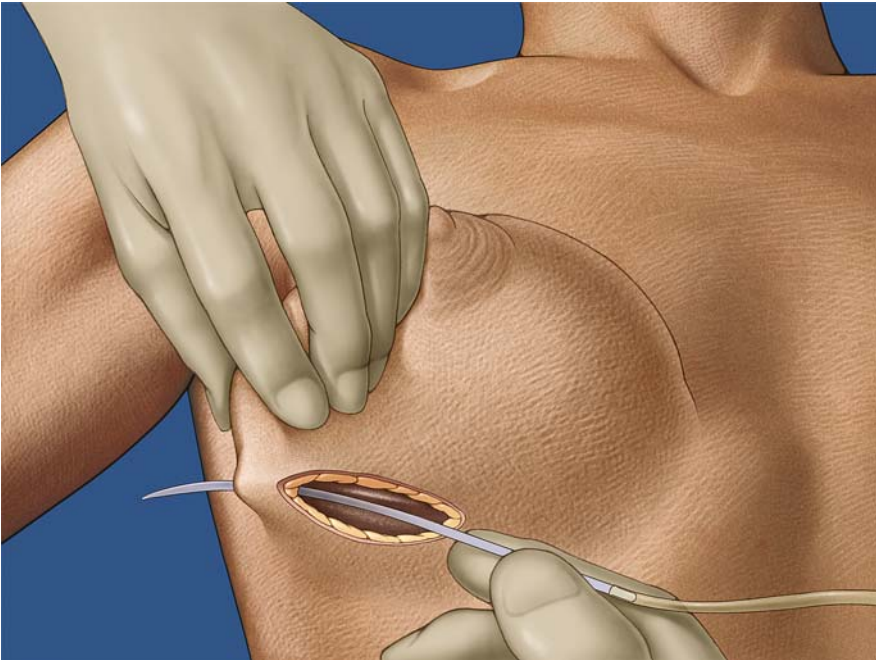
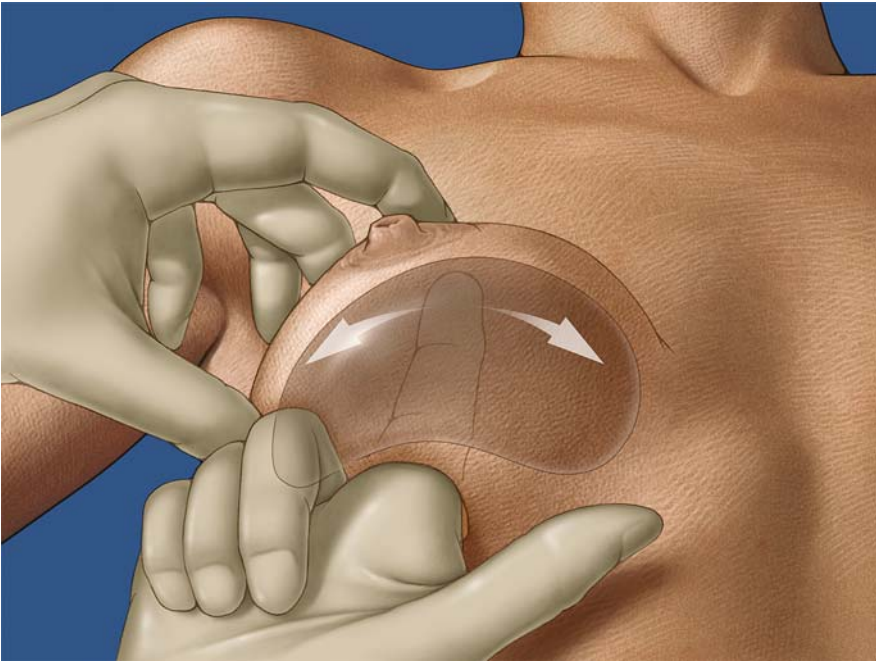
### **Exact Positioning of the Implant**

- If the desired implant is in the correct position and has an optimum fit, it is immersed once more in betadine solution and is implanted in the way described. In the process it must be possible to feel the small marking in the central region of the base of the implant using one's middle finger to ensure that the positioning of the latter is correct. The implant is smoothed above and below using the middle and index finger. A check is carried out to ensure the implant fits the implant pocket exactly.

---

### **Insertion of the Redon Drain (size 10)**

- A size 10 Redon drain is used for wound drainage. It empties laterally and is fixed using one suture. One should ensure that the implant is not damaged and that the drain is positioned in such a way that between the implant and muscle fascia it extends from the edge of the incision to the medial dissection margin.



---

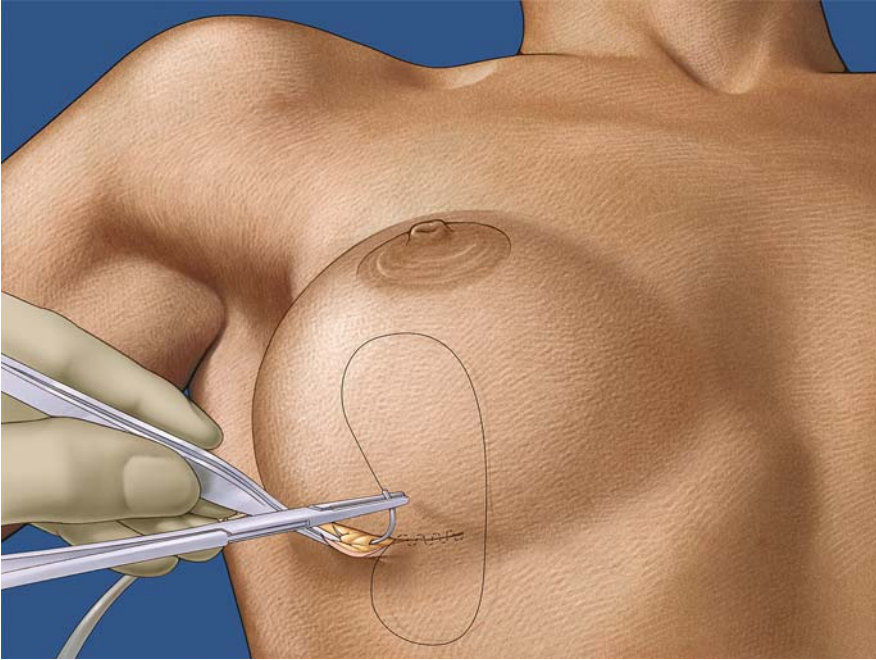
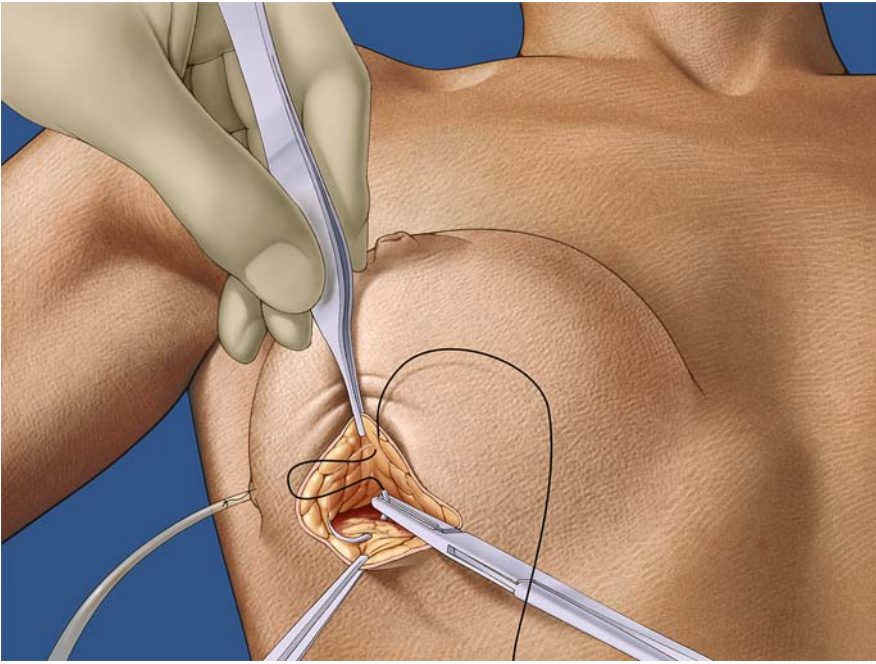
### ● Deep Wound Closure

- Three concealed 2.0 Monocryl interrupted sutures are used as deep fixation sutures, which connect the lower dermis with the fascia. This suturing is important to achieve a stable, lower boundary to the inframammary fold and to avoid a later sinking or slipping of the implant in a caudal direction. Consequently, the sutures must be deep and complete, protecting the implant, so that no dehiscence can occur. The Redon drain should not lie under the suturing but rather should, prior to this, be pushed under the implant in the direction of the sternum. For suturing the assistant should hold the implant away in the cranial direction using a Langenbeck retractor to ensure that there is no accidental puncturing of the prosthesis by the sutures.

---

### **Two-Layer, Atraumatic Wound Closure Using 4.0 Monocryl**

- Following subcutaneous closure with 2.0 Monocryl interrupted sutures there is already good, tension-free wound closure of the skin. Subsequently, the skin is closed continuously, intracutaneously using 4.0 Monocryl. One concealed knot is made at the beginning and the end of the suture so that this thread does not have to be pulled out later. Since we have been using only Monocryl sutures in breast surgery, we have not observed any problems with healing, thread granulomas or poor scar healing. If good care is taken of the scar, the incision generally heals without any problems and is virtually invisible.



---

### ◉ Dressing

- After wound closure, the incisions are closed using Steri-Strips that the patient may remove herself after 8 days. In addition to the dressing, small pieces of gauze and 10×15 cm Cutiplast plasters are applied to the nipples, and a 10×10 cm folded pressure dressing and 10×15 cm Cutiplast plaster are applied to the submammary incision. Subsequently, a bandage is used for postoperative compression. After 2 days this is changed to a sports bra of the appropriate size.

### Aftercare

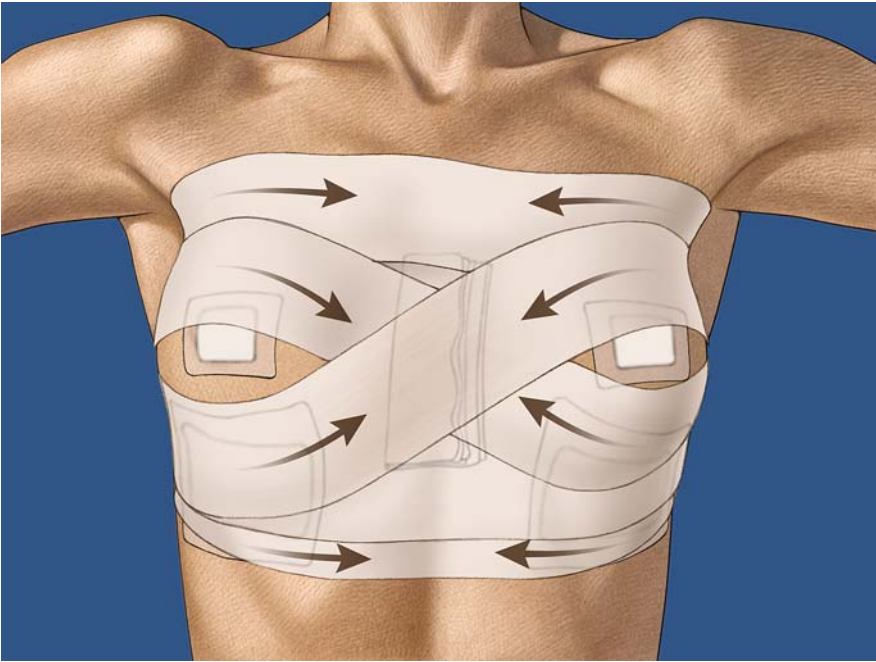
- After the operation the patient is monitored for 24 h. The blood pressure is monitored and it ought not to be above 120 mg systolic. During this time the patient must stay in bed on her back with the upper body raised by 30°. The first day after the operation the Redon drain is removed and the bandage is changed. If the course of the recovery is without problems, the patient is given a well-fitting sports bra. This is adjusted in the clinic and the patient must wear it at home for 4 weeks.

Where the implant is beneath the muscle, we recommend that the patients wear a 'Stuttgart belt'. This reduces muscle swelling, produces a supple connective tissue site (long-term study from the USA) and accelerates the contouring process.

For the first 8 days after the operation, the patient receives an antibiotic (cefaclor) and triamcinolone acetonide tablets, 8 mg per day. After 8 days, the patient can remove the Steri-Strips herself. The incisions must be taken care of for 2 weeks using dexpanthenol ointment, and after 4 weeks silicone gel must be used or a plaster applied for 2 months. Four weeks after the operation it is possible to do heavy physical work and sport. Social activities and work do not pose a problem after 8 days.

Patients are requested to go to the breast clinic immediately if there are any problems. After 12 months there will be a final check with precise photo documentation.





**Breast Augmentation**

---

## Appendix: Breast Augmentation

### Submuscular Access

Submuscular access is more difficult, involves more bleeding and is more time-consuming. This operation technique is indicated when the skin and glandular tissue are unfavorable and too thin: if the implants were incorporated above the muscle, the skin covering would be too thin and rippling and the impression of an implant would be inevitable. In this case the implant must go underneath the muscle. It cannot be said that one method is better than the other; the operating surgeon should, based on his or her experience, decide in each individual case whether the implant should be placed above or below the muscle.

A submuscular implant is appropriate if the following conditions exist:

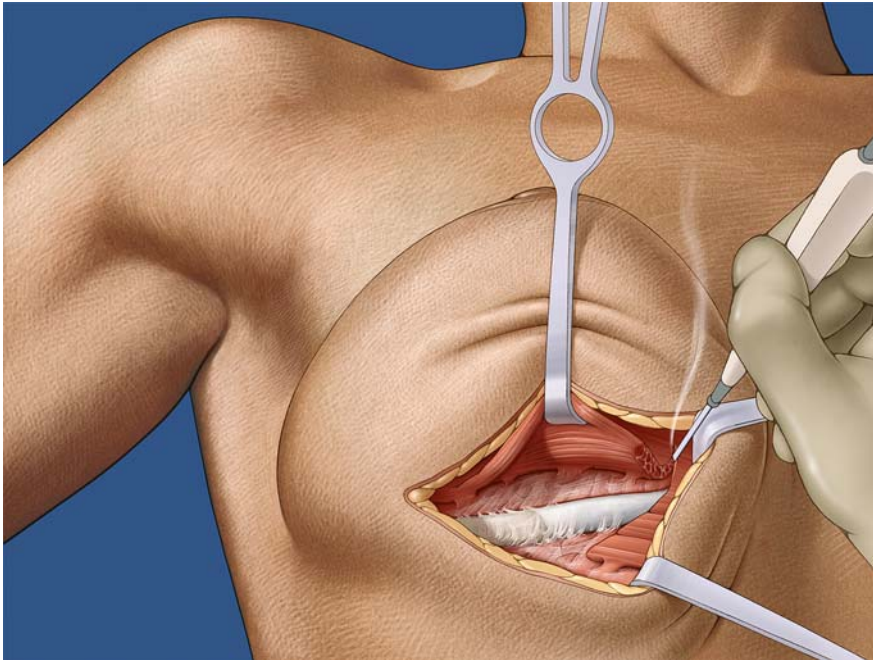
- Glandular hypoplasia, with thin covering of soft tissue
- Postpartum involution atrophy with moderate surplus of thin soft tissue
- Glandular aplasia
- Previous subcutaneous mastectomy
- Recurrent capsular fibrosis
- Pressure atrophy of the breast where an implant is already in place

In over two-thirds of the cases it will be fine to position the implant above the muscle. This is why there is more detail about this method in the manual.

- If the implant is positioned underneath the muscle, then the points of attachment of pectoralis major are detached along the rib from the intermediate area medially in the direction of the sternum, where one should always ensure that there is a distance of 3 cm or two fingers from the right to the left breast between the two implant pockets. The implant pockets must not communicate.
- The dissection may be carried out using a scalpel or Metzenbaum scissors. It is recommended, however, that the electric scalpel be used since this produces less bleeding. One should always use the rib for orientation. When carrying out the dissection, one should ensure that no perforations are produced in the intercostal spaces.

A good light source is required for submuscular dissection, so that one can also stop bleeding in the deeper regions without difficulty.





- Like the supramuscular access, the beginning of the dissection is very important, as this is when the correct layer is demonstrated. Then, even when carrying out dissection under the muscle, much of the detachment can be carried out using the middle or index finger as a blunt instrument. In the medial and caudal part it may be necessary to cut through the connective tissue and strong muscle fibers using a sharp instrument, either with Metzenbaum scissors or the electric scalpel. If the electric scalpel is used, care must be taken to avoid perforations.

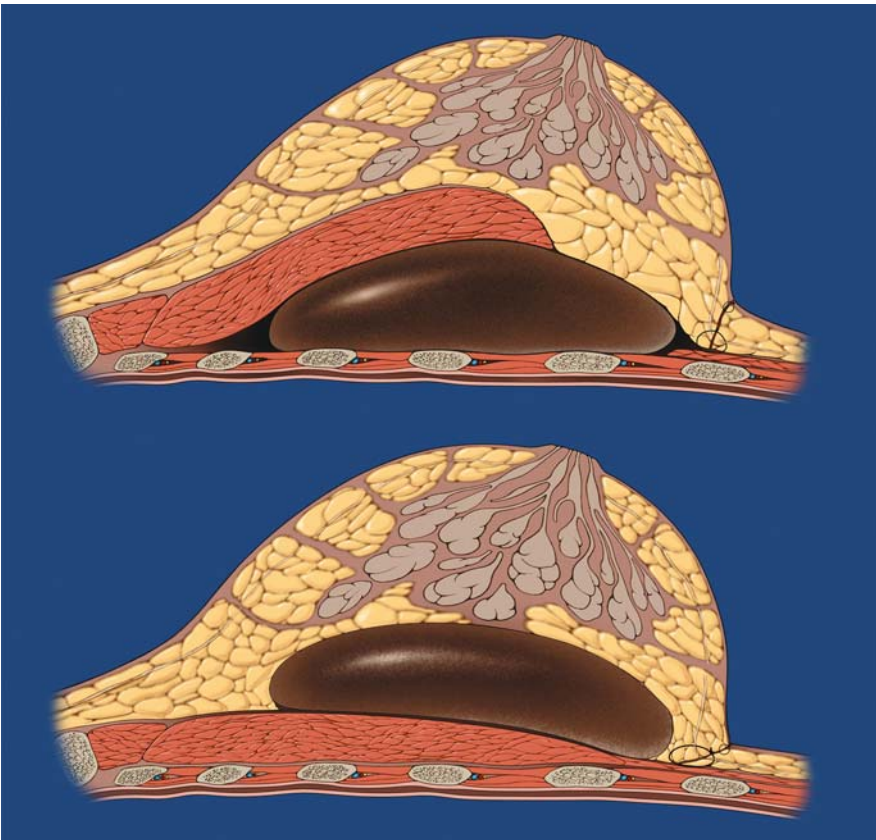
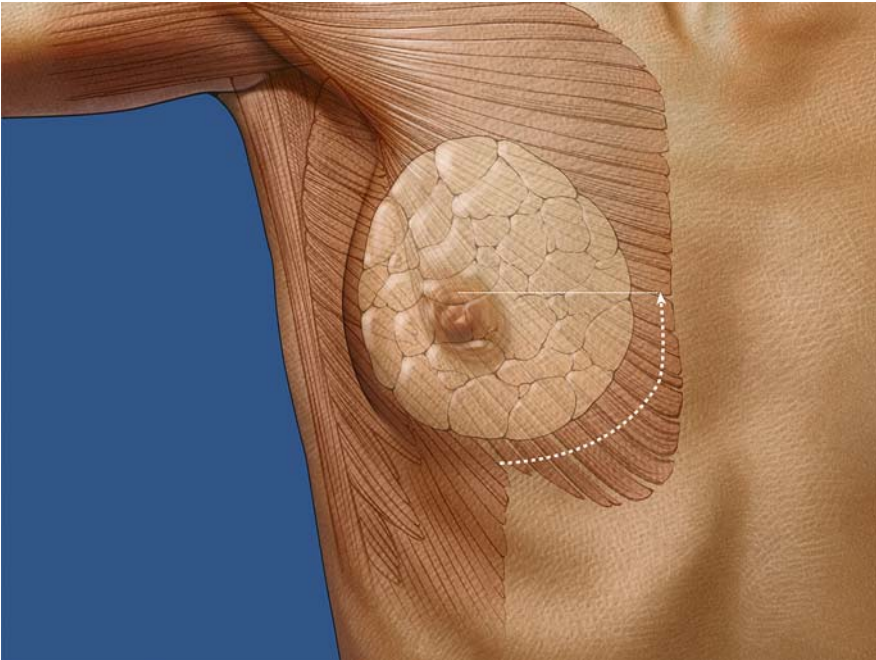
---

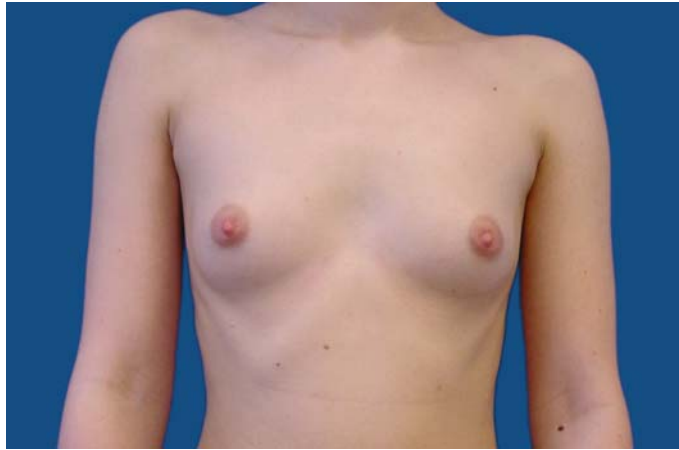
This diagram illustrates how the pectoralis major is inserted on the sternum caudally. This part of the insertion, depicted with the dotted line, is detached up to the height of the nipple using scissors or the electric scalpel. The process of completely cutting through it can be monitored using the adipose tissue behind as a guide, as this will become visible because the muscle retracts. Meticulous hemostasis must be carried out twice in order to avoid postoperative bleeding, which always occurs during the first 24 h.

---

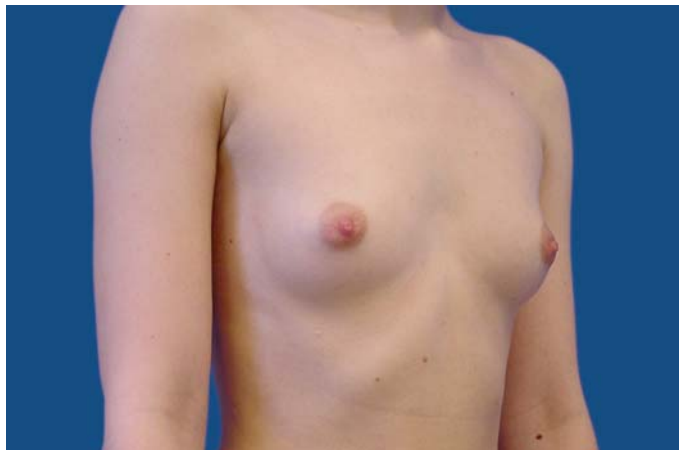These two figures show the position of the implant underneath the muscle and above the muscle, respectively. One can see that as a result of the traction and fitting of the implant, the muscle retracts after being detached and this ensures good coverage over two-thirds of the implant.

The three-layer wound closure is the same for both access methods. The concealed fixation suture of the muscle fascia with 2.0 Monocryl is important since this ensures that the inframammary fold is defined and a stable counter-position to the implant is created.





Before the operation – frontal view

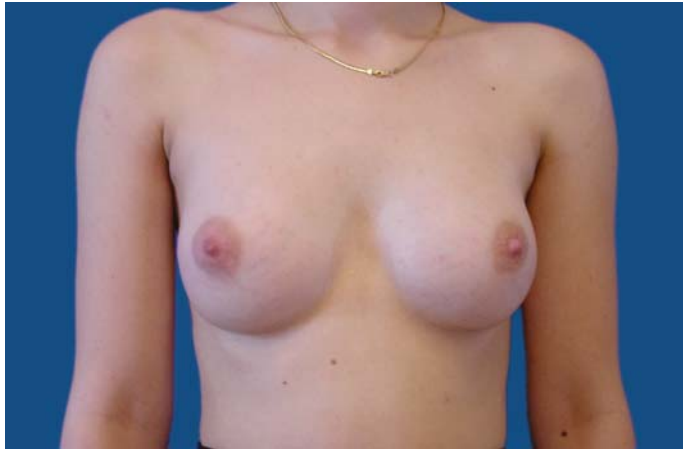

Before the operation – semioblique view, right

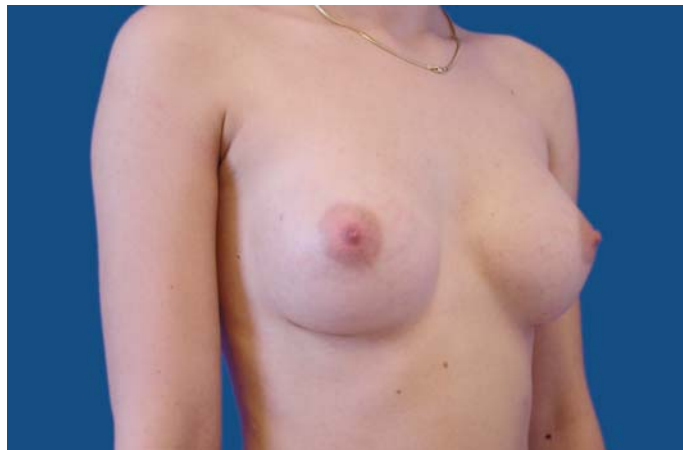### Results

Patient I: This is a 24-year-old patient whose breasts did not make her feel like a woman. She wanted her breasts enlarged to a size 75 B.

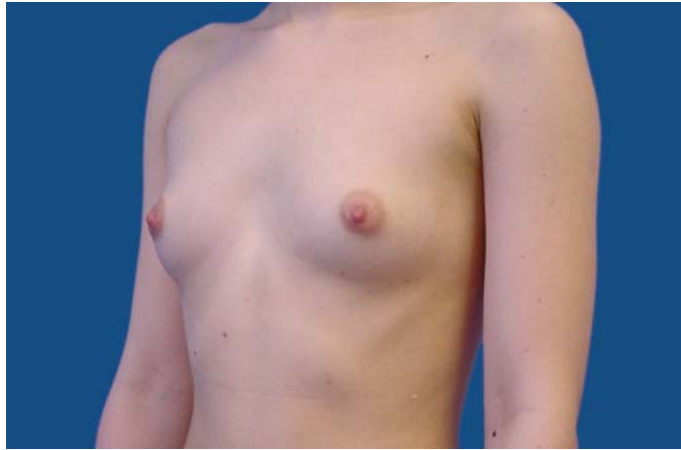
For this patient, access via the inframammary fold was used to insert a 230-g round, low-profile implant produced by Inamed. The implant was placed above the muscle.



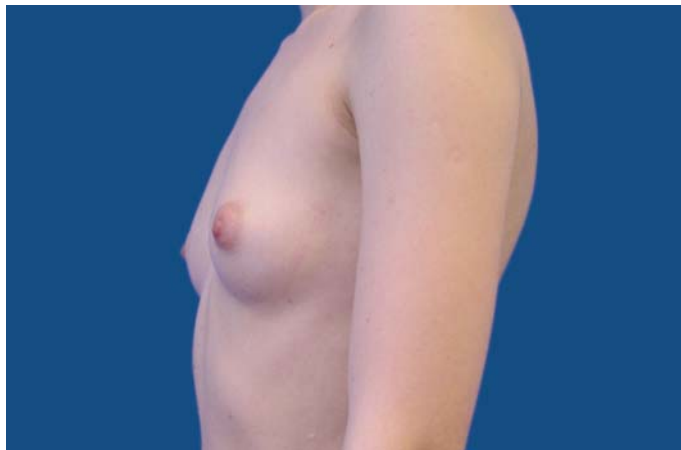After the operation – frontal view



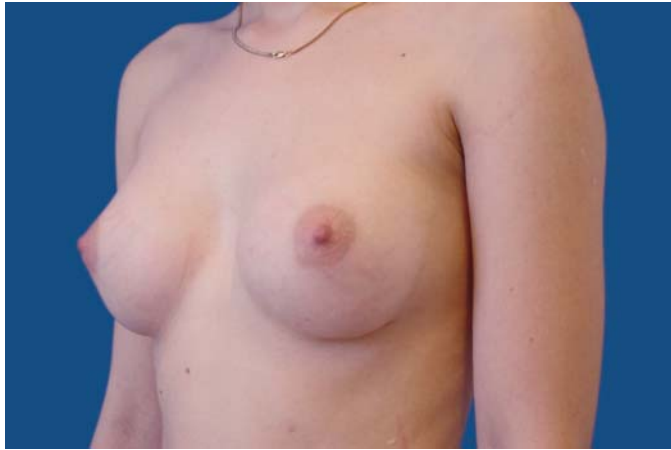After the operation – semioblique view, right



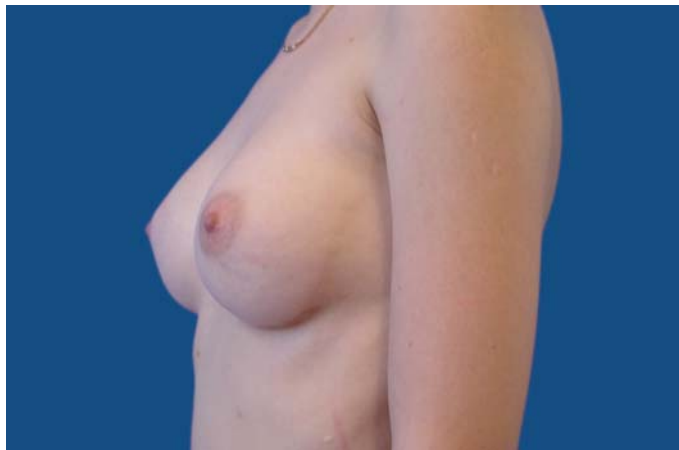Before the operation – semioblique view, left



Before the operation – view from left

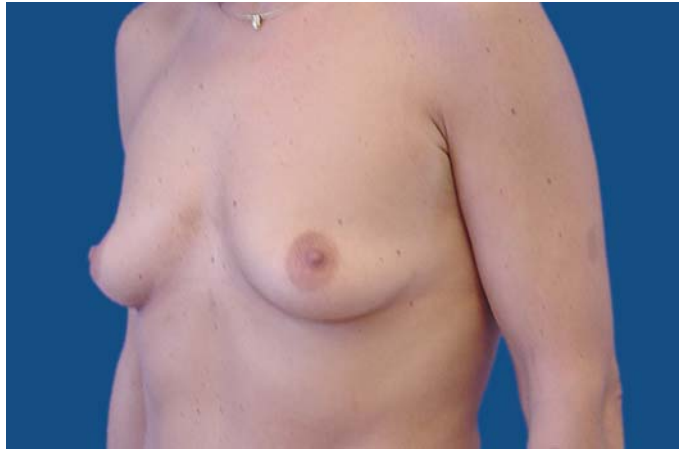

After the operation – semioblique view, left

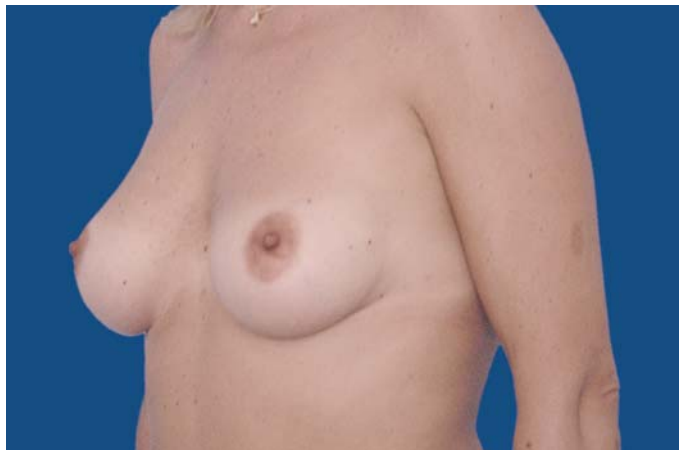

After the operation – side view, left

Patient I: Twelve Months After the Implant  
Normal wound healing, no scar formation, no fibrosis.  
The breast has an anatomical shape with a round implant.



Before the operation – oblique view, left

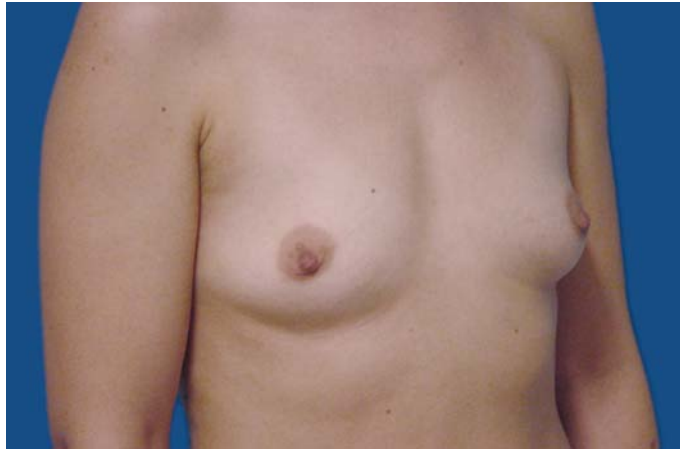


Twelve months after the operation. Oblique view, left

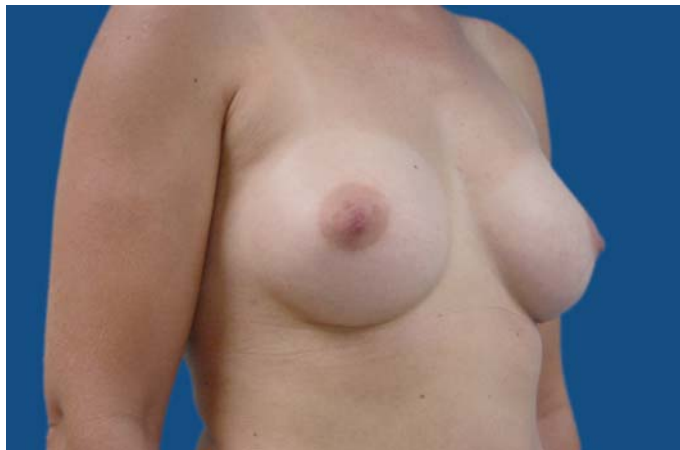Patient II: This is a 45-year-old patient who had given birth twice. She expressed a desire to have breasts like she had before the births, now that she had finished having children. A supramuscular implantation with a 260-g round, low-profile implant was carried out using the supramuscular access on this patient.

Twelve months after the operation: The breast shows no scar formation and has a natural shape. An outsider would not notice that breast augmentation had taken place.





Before the operation



Twelve months after the operation

Patient III: 32-year old patient with breast hypoplasia and thin skin covering with prominent sternum. Implant 290, submuscular. It is up to the experienced surgeon to decide whether a submuscular implant is appropriate. If there is any doubt, then the submuscular implant is the safe option. There has been no definitive scientific clarification relating to the incidence of capsular fibrosis.

## Literature

- Bosch G, Jacobo O (2001) Aesthetic breast augmentation: the double implant. *Aesthetic Plast Surg* 25:353–356
- Bosch G, Jacobo O (2002) The double pocket technique: aesthetic breast augmentation. *Aesthetic Plast Surg* 26:461–464
- Burden WR (2001) Skin-sparing mastectomy with staged tissue expander reconstruction using a silicone gel prosthesis and contralateral endoscopic breast augmentation. *Ann Plast Surg* 46:234–236; discussion 236–237
- Caleel RT (2000) Transumbilical endoscopic breast augmentation: submammary and subpectoral. *Plast Reconstr Surg* 106:1177–1182; discussion 1183–1174
- Camirand A, Doucet J, Harris J (1999) Breast augmentation: compression – a very important factor in preventing capsular contracture. *Plast Reconstr Surg* 104:529–538; discussion 539–541
- Candiani P, Campiglio GL (1997) Augmentation mammoplasty: personal evolution of the concepts looking for an ideal technique. *Aesthetic Plast Surg* 21:417–423
- Castello JR, Barros J, Vazquez R (1999) Giant liponecrotic pseudocyst after breast augmentation by fat injection. *Plast Reconstr Surg* 103:291–293
- Cheung YC, Su MY, Ng SH, et al (2002) Lumpy silicone-injected breasts. Enhanced MRI and microscopic correlation. *Clin Imaging* 26:397–404
- Cho BC, Lee JH, Ramasastry SS, et al (1997) Free latissimus dorsi muscle transfer using an endoscopic technique. *Ann Plast Surg* 38:586–593
- Collis N, Platt AJ, Batchelor AG (2001) Pectoralis major “trapdoor” flap for silicone breast implant medial knuckle deformities. *Plast Reconstr Surg* 108:2133–2135; discussion 2136
- Coln D, Gunning T, Ramsay M, et al (2002) Early experience with the Nuss minimally invasive correction of pectus excavatum in adults. *World J Surg* 26:1217–1221@ref.reference:
- Cothier-Savey I, Tamtawi B, Dohnt F, et al (2001) Immediate breast reconstruction using a laparoscopically harvested omental flap. *Plast Reconstr Surg* 107:1156–1163; discussion 1164–1155
- Diekmann S, Diekmann F, Hauschild M, et al (2002) Digital full field mammography after breast augmentation (in German). *Radiologe* 42:275–279
- Dowden RV (2000) Dispelling the myths and misconceptions about transumbilical breast augmentation. *Plast Reconstr Surg* 106:190–194; discussion 195–196
- Elliott LF (2001) Breast augmentation with round smooth saline or gel implants: the pros and cons. *Clin Plast Surg* 28:523–529
- Elliott LF (2002) Circumareolar mastopexy with augmentation. *Clin Plast Surg* 29:337–347
- Fernandez CP, Lopez FM, Burrieza PI (1999) Our experience with the triple-V transareolar incision for augmentation mammoplasty. *Aesthetic Plast Surg* 23:428–432
- Frey M (1999) A new technique of reduction mammoplasty: dermis suspension and elimination of medial scars. *Br J Plast Surg* 52:45–51
- Giacalone PL, Bricout N, Dantas MJ, et al (2002) Achieving symmetry in unilateral breast reconstruction: 17 years experience with 683 patients. *Aesthetic Plast Surg* 26:299–302
- Gordon JB, Barot LR, Fahey AL, et al (2001) The Internet as a source of information on breast augmentation. *Plast Reconstr Surg* 107:171–176
- Graf RM, Bernardes A, Rippel R, et al (2003) Subfascial breast implant: a new procedure. *Plast Reconstr Surg* 111:904–908
- Gutierrez L, Montes A (2002) Siliconomas: a case report. *Rev Med Child* 130:793–797
- Hakelius L, Ohlsen L (1997) Tendency to capsular contracture around smooth and textured gel-filled silicone mammary implants: a five-year follow-up. *Plast Reconstr Surg* 100:1566–1569

- Hall-Findlay EJ (2002) Pedicles in vertical breast reduction and mastopexy. *Clin Plast Surg* 29:379–391
- Hedén P (2003) *Plastic Surgery and You*. Silander & Fromholtz Förlags AB
- Hedén P, Jernbeck J, Hober M (2001) Breast augmentation with anatomical cohesive gel implants: the world's largest current experience. *Clin Plast Surg* 28:531–552
- Herborn CU, Marincek B, Erfmann D, et al (2002) Breast augmentation and reconstructive surgery: MR imaging of implant rupture and malignancy. *Eur Radiol* 12:2198–2206
- Hidalgo DA (2000) Breast augmentation: choosing the optimal incision implant and pocket plane. *Plast Reconstr Surg* 105:2202–2216; discussion 2217–2208
- Hinderer UT (2001) Circumareolar dermo-glandular plication: a new concept for correction of breast ptosis. *Aesthetic Plast Surg* 25:404–420
- Ho WS, Ying SY, Chan AC (2002) Endoscopic-assisted subcutaneous mastectomy and axillary dissection with immediate mammary prosthesis reconstruction for early breast cancer. *Surg Endosc* 16:302–306
- Klein SM, Bergh A, Steele SM, et al (2000) Thoracic paravertebral block for breast surgery. *Anesth Analg* 90:1402–1405
- Lai YL, Weng CJ, Chen YR, et al (2001) Circumnipple-incision longitudinal-breast dissection augmentation mammoplasty. *Aesthetic Plast Surg* 25:194–197
- Mang, WL (1996) *Ästhetische Chirurgie Bd. I*. Einhorn Presse Verlag
- Marck KW, van der Biezen JJ, Dol JA (1996) Internal mammary artery and vein supercharge in TRAM flap breast reconstruction. *Microsurgery* 17:371–374. Massiha H (2000) Augmentation in ptotic and densely glandular breasts: prevention treatment and classification of double-bubble deformity. *Ann Plast Surg* 44:143–146
- Massiha H (2002) Scar tissue flaps for the correction of postimplant breast rippling. *Ann Plast Surg* 48:505–507
- Niechajev I (2001) Mammary augmentation by cohesive silicone gel implants with anatomic shape: technical considerations. *Aesthetic Plast Surg* 25:397–403
- Pardo Mateu L, Chamorro Hernandez JJ (1998) Partial myotomy of the pectoralis major in sub-muscular breast implants. *Aesthetic Plast Surg* 22:228–230
- Pechter EA (1998) A new method for determining bra size and predicting postaugmentation breast size. *Plast Reconstr Surg* 102:1259–1265
- Pereira JJ (1997) Aesthetic breast surgery with inverted-T scar placed above the inframammary sulcus. *Aesthetic Plast Surg* 21:16–22
- Pitanguy, J (1981) *Aesthetic Plastic Surgery of Head and Body*. Springer New York Berlin
- Planas J, Migliano E, Wagenfuhr J Jr, et al (1997) External ultrasonic treatment of capsular contractures in breast implants. *Aesthetic Plast Surg* 21:395–397
- Pound EC 3rd, Pound EC Jr (2001) Transumbilical breast augmentation (TUBA): patient selection technique and clinical experience. *Clin Plast Surg* 28:597–605
- Serletti JM, Moran SL (1998) The combined use of the TRAM and expanders/implants in breast reconstruction. *Ann Plast Surg* 40:510–514
- Songcharoen S (2002) Endoscopic transumbilical subglandular augmentation mamma-plasty. *Clin Plast Surg* 29:1–13
- Sudarsky L (2001) Experience with transumbilical breast augmentation. *Ann Plast Surg* 46:467–472; discussion 472–463
- Tebbetts JB (2001) A surgical perspective from two decades of breast augmentation: toward state of the art in 2001. *Clin Plast Surg* 28:425–434
- Tebbetts JB (2002) Achieving a predictable 24-hour return to normal activities after breast augmentation. 2. Patient preparation refined surgical techniques and instrumentation. *Plast Reconstr Surg* 109:293–305; discussion 306–297

- 
- Unterweger M, Meuli-Simmen C, Caduff R, et al (2000) Breast imaging after augmentation with homologous adipose tissue implant (in German). *Schweiz Rundsch Med Prax* 89:894–896
- Vila-Rovira R (1999) Breast augmentation by an umbilical approach. *Aesthetic Plast Surg* 23:323–330
- Villafane O, Garcia-Tutor E, Taggart I (2000) Endoscopic transaxillary subglandular breast augmentation using silicone gel textured implants. *Aesthetic Plast Surg* 24:212–215
- Werner A (1998) B-technique after augmentation mammoplasty to correct dislocation of nipple and areola (in German). *Zentralbl Gynekol* 120:559–561
- Yanaga H, Tai Y, Kiyokawa K, et al (1999) An ipsilateral superdrainaged transverse rectus abdominis myocutaneous flap for breast reconstruction. *Plast Reconstr Surg* 103:465–472
- Yang D, Wang X, Xia S (1997) Augmentation mammoplasty through the external oblique muscle route (in Chinese). *Zhonghua Zheng Xing Shao Shang Wai Ke Za Zhi* 13:188–190



- 
- ## Brachioplasty
- Introduction 51
  - Upper-Arm Tightening 51
  - Anatomical Overview 53
  - Instruments 54
  - Duplicate Patient Information 58
  - Preliminary Examinations 58
  - Photographic Documentation 58
  - Surgical Planning 58
  - ■ Preliminary Marking of Incision Lines 58
    - Mang's Fish-Mouth Technique 60
    - Positioning, Disinfection 60
  - ■ Tumescence 60
  - ■ Incision 62
  - ■ Superficial Preparation 62
    - Deep Preparation, Hemostasis 64
  - ■ Incision of the Dissected Dermofat Flap in Stages 64
    - Fixing of the Skin Flap with 3.0 Monocryl Key Sutures 66
  - ■ Resection in Stages 66
  - ■ Two-Layer Skin Closure 68
    - Cutaneous Sutures: Running or Intracutaneous 4.0 Monocryl 68
  - ■ Dressing 70
    - Aftercare 70
    - Results 72
    - Literature 77

---

## Introduction

Many patients who wish to improve the shape of their upper arms have a considerable surplus of skin. The cause can be, for example, massive weight loss, but the process of skin aging can also leave such signs. In this case only excision can produce the desired improvement in the contour. Even the most careful upper-arm tightening, however, will result in a scar on the medial side of the arm, starting in the armpit and stretching as far as the elbow. The patient must therefore be informed accordingly because most patients want this procedure in order to be able to show their arms in public again.

## Upper-Arm Tightening

Upper-arm tightening is requested increasingly by women over the age of 60. It is often surprising that women of this age do not have a facelift; instead they are more bothered by their flabby upper arms when they want to wear a bathing suit or sleeveless clothes. The only way of eliminating the surplus skin and the wrinkles in the long term is cutaneous excision. The art of the surgeon in doing this is to position the incision in such a way that it is on the medial side of the upper arm and to ensure that the resection of the skin is carried out so generously that the entire upper-arm region is tightened.

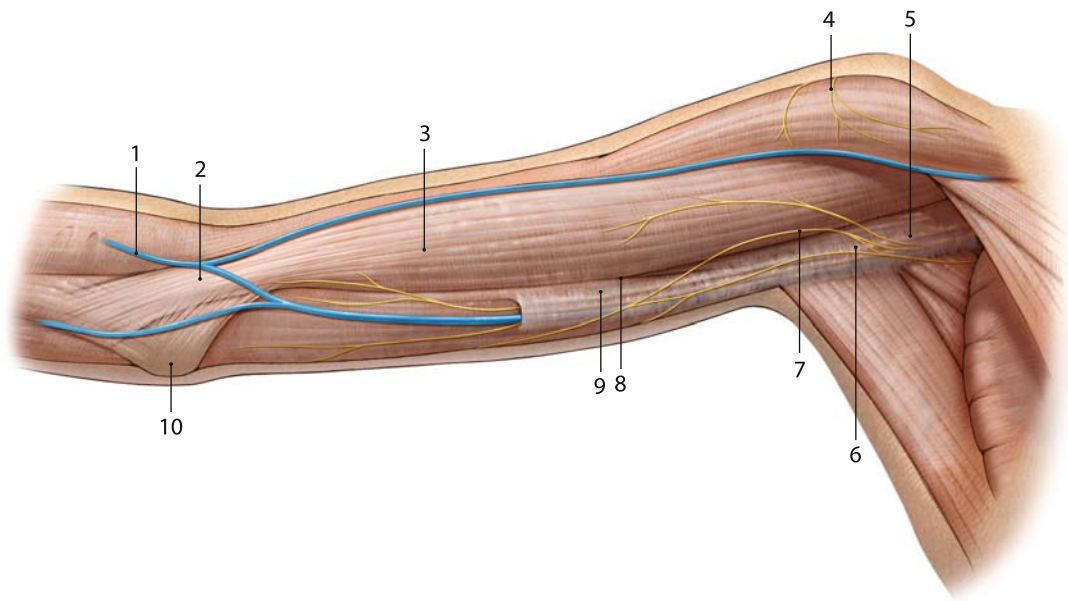
Upper-arm tightening is not technically difficult. The thick skin/fat flaps are dissected off the fascia, protecting the nerves and vessels, following exact marking of the incision line. The same basic principle applies to all operations to tighten the skin, namely, that the flap is mobilized and, following appropriate measurement, is then fixed in place in stages with key sutures so that neither too much nor too little skin is removed. Mang's principle always applies: I can measure ten times but only cut once. This should always be kept in mind so that each resection border is measured precisely. The resection border will then be sutured without tension and no surplus.

As cutting too far towards the olecranon process during upper-arm tightening often causes problems in patients with poor healing, we developed the "fish-mouth" incision in our department. This means that an incision in the shape of a fish mouth is made in the axilla, stretching to the middle of the medial side of the upper arm. This leads to a scar in the axilla and in about the upper third of the medial side of the upper arm, which is not so obvious. Furthermore, the fish-mouth incision also achieves tangential tightening in the axilla and vertical tightening in the

upper-arm area, so the troublesome surplus skin and the folds of skin in the axilla and upper third of the upper arm when wearing sleeveless clothes are eliminated.

Every patient must be informed of the possibility of scarring as a result of this operation. Aftercare is also very important. Subsequently, the scars are treated with ointment and silicone dressing.



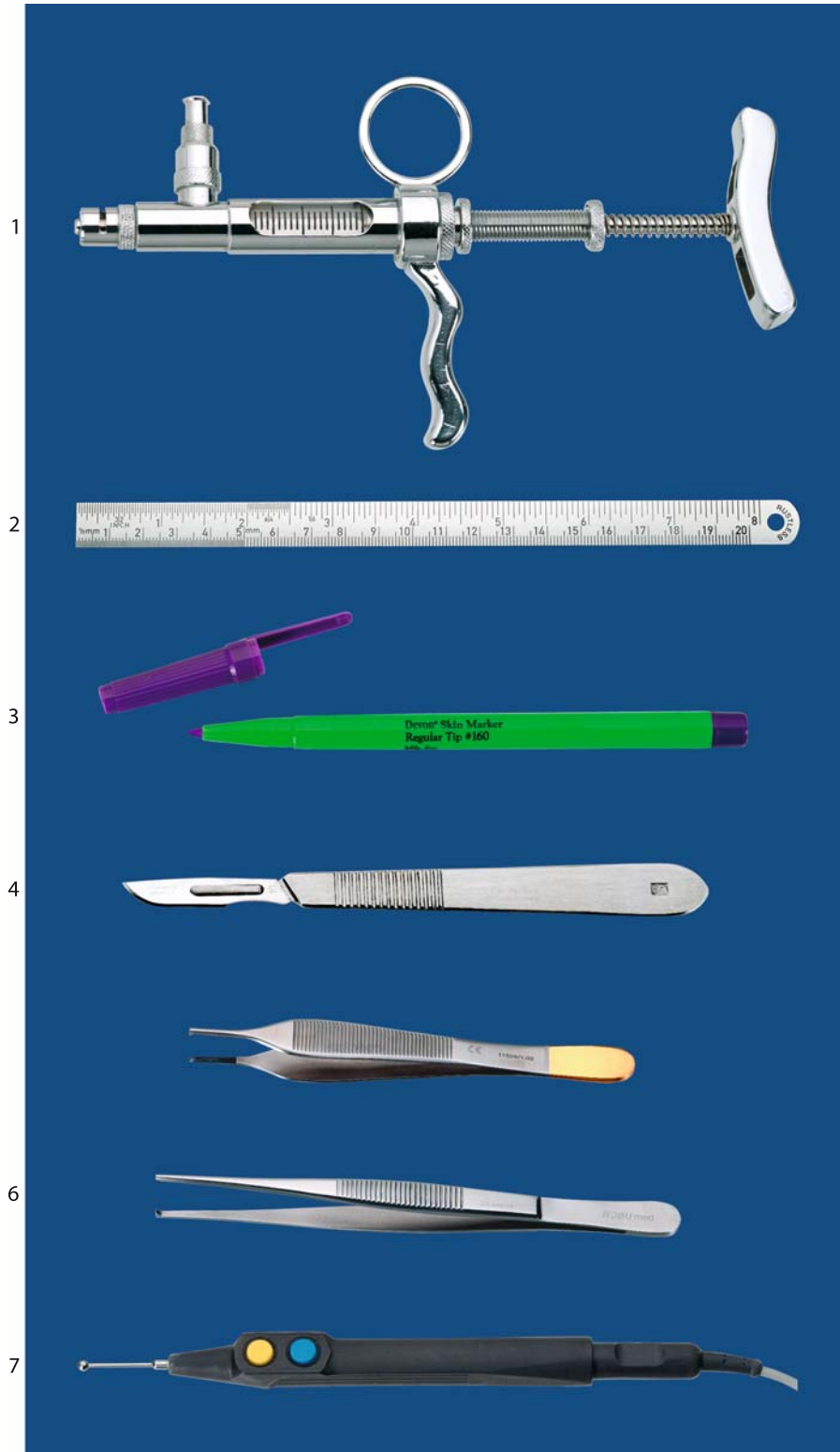


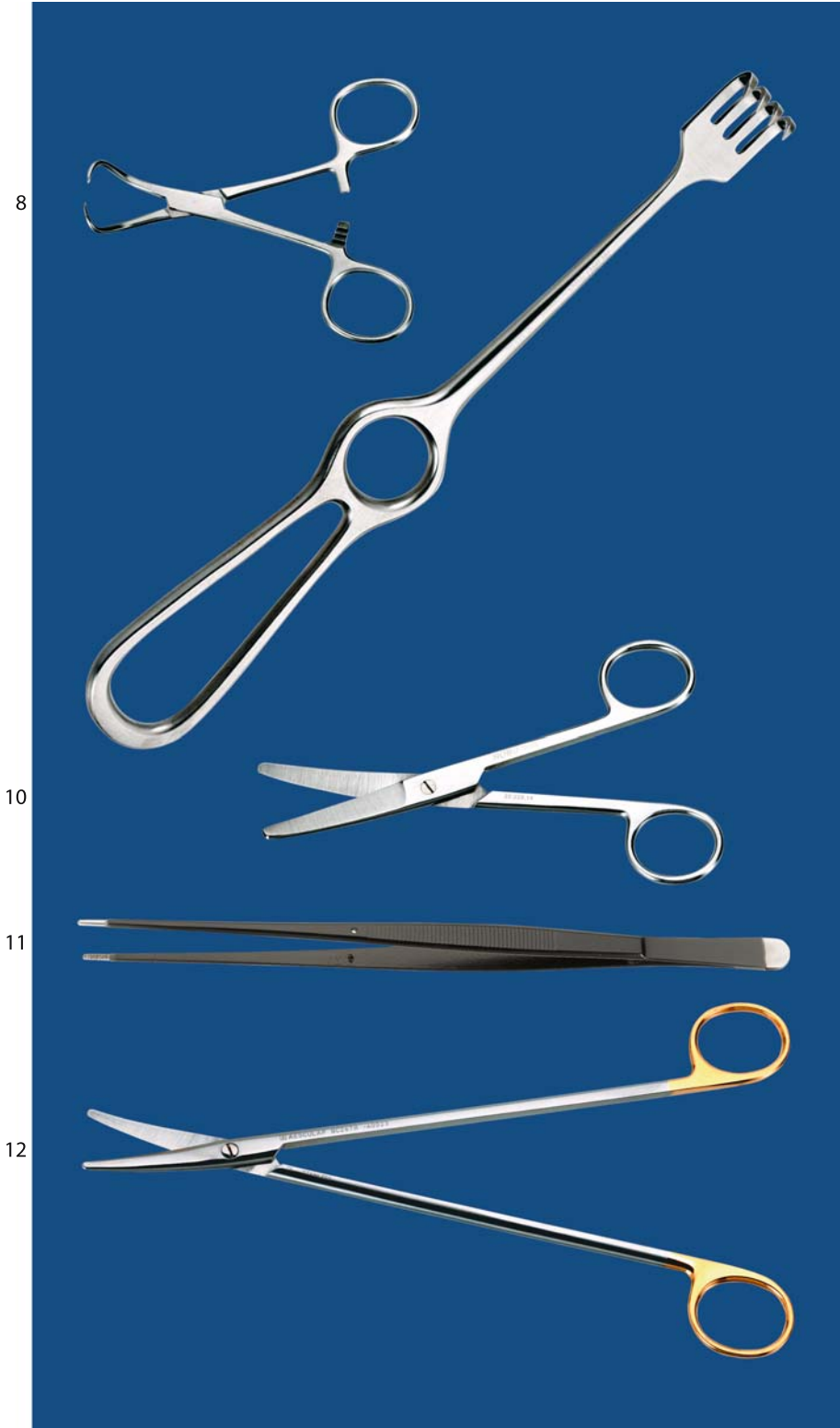
### Anatomical Overview

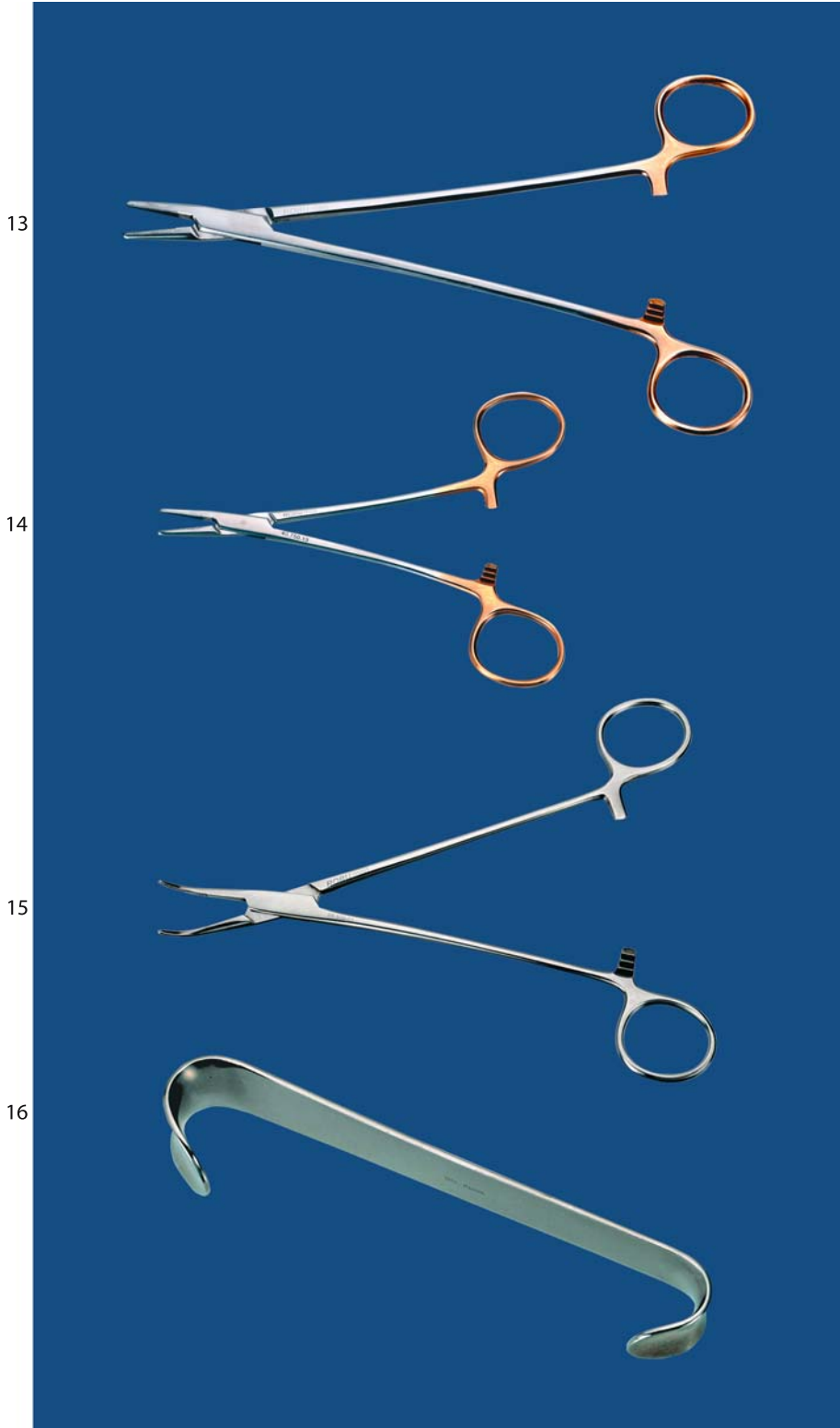
- |  |                                    |
|--|------------------------------------|
| 1. Basilic vein                                    | 6. Brachial plexus                 |
| 2. Cubital fossa                                   | 7. Medial brachial cutaneous nerve |
| 3. M. biceps                                       | 8. Medial bicipital sulcus         |
| 4. Sup. lat. brachi. cut. nerve,<br>axillary nerve | 9. M. triceps                      |
| 5. Axillary fossa                                  | 10. Medial epicondyle              |

### Instruments

- Pump-syringe [1]
- Centimeter rule [2]
- Marking pen [3]
- Scalpel [4]
- Adson tweezers with plate [5]
- Surgical tweezers [6]
- Monopolar electrocoagulation [7]
- Backhaus clamps [8]
- Four-pronged retractor [9]
- Cooper scissors [10]
- Insulated anatomical tweezers for hemostasis [11]
- Large Metzenbaum dissection scissors [12]
- Large needle holder [13]
- Small needle holder [14]
- Curved forceps [15]
- Roux hook [16]







---

### **Duplicate Patient Information**

The patient is first given comprehensive information about the objectives and risks of the procedure on the day of the first consultation.

A written record is kept of this.

One day before the surgical procedure, the patient is again given comprehensive information on two separate occasions: once by the surgeon and once by the surgical resident. All the risks are set down in writing at this time.

### **Preliminary Examinations**

Current preoperative routine laboratory examinations, ECG, chest X-ray, clinical examination.

### **Photographic Documentation**

- Frontal view of the arms with the patient standing.
- Arms abducted by 30°–45° at the shoulder joint.

### **Surgical Planning**

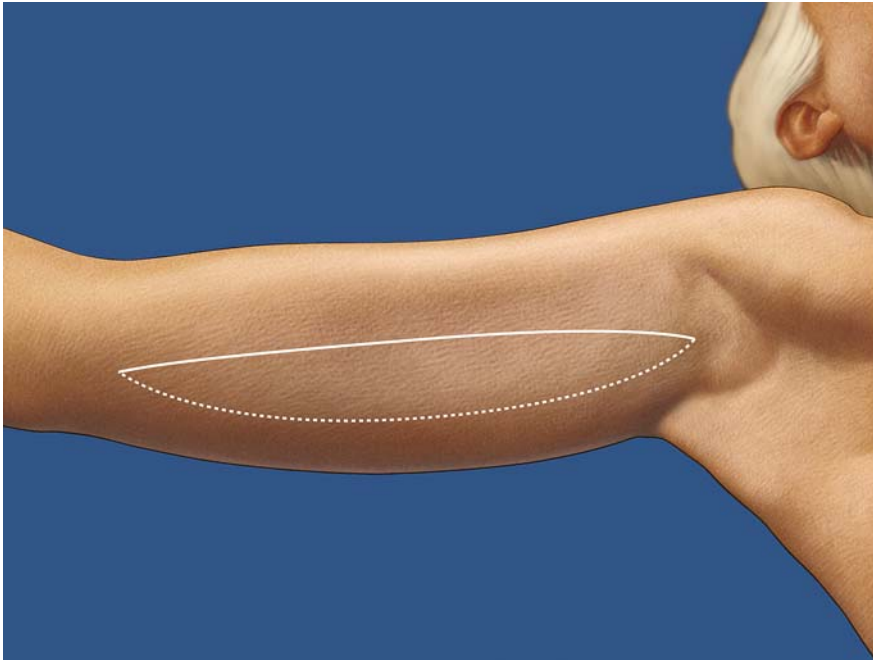
The procedure is carried out under tumescent local anesthesia or under general anesthesia with endotracheal intubation. On the day before the operation the surgeon discusses in detail with the patient which changes he or she wants and how the surgeon can achieve this.

The patient must be warned about unrealistic expectations and must be fully informed about postoperative behavior, in particular about how to care for the scar.

Intraoperative single-shot injection prophylaxis with cefaclor 2 g. Compression dressing, patient is monitored for 24 h.

### **⦿ Preliminary Marking of Incision Lines**

- Before the operation, the areas of surplus skin are marked with the patient standing with his/her arms slightly abducted and bent at the elbow joint to 70°. Optimum preoperative marking is extremely important for brachioplasty. The surgeon must take his/her time and position the incision in such a way that it cannot be seen either from the front or the back when the patient's upper arm is hanging down. In order to do this the surgeon holds the surplus skin together between the thumb and



index finger of his/her left hand and marks the outer resection border with a pen. In general, markings are made for the upper longitudinal incision about two finger widths above the sulcus bicipitalis medialis. The exact course of the lower incision is only defined during the operation. To achieve a symmetrical result, however, the incision is marked approximately before the operation.

If appropriate, the spindlelike resection in the axilla can be extended in an axillary direction by Z-plasty or a vertical ellipse.

In all aesthetic resections of cutaneous/fatty flaps in the head, neck, or body the final resection is carried out in stages in order to ensure that neither too much nor too little is removed, as in both these cases the result would be unsatisfactory. The skill of the aesthetic surgeon is to have a feeling for the tissue, to be able to think in three dimensions, and to be able to fulfill the patient's wishes with a rigorous explanation of the procedure. An aesthetic surgeon can only be successful in the long term if he or she does this.

---

### Mang's Fish-Mouth Technique

In appropriate cases, i.e., when the folds of skin do not extend a long way into the elbow region, a variation of the incision, without extension beyond the cranial third of the upper arm, can be successful. With this incision not only vertical tightening in the upper arm area is achieved, but also tangential tightening in the axilla. The advantage of this incision is that the scar is barely visible, and skin folds in the axilla and upper third of the upper arm can be eliminated very effectively. The scar can hardly be seen at all when sleeveless clothes are worn.

---

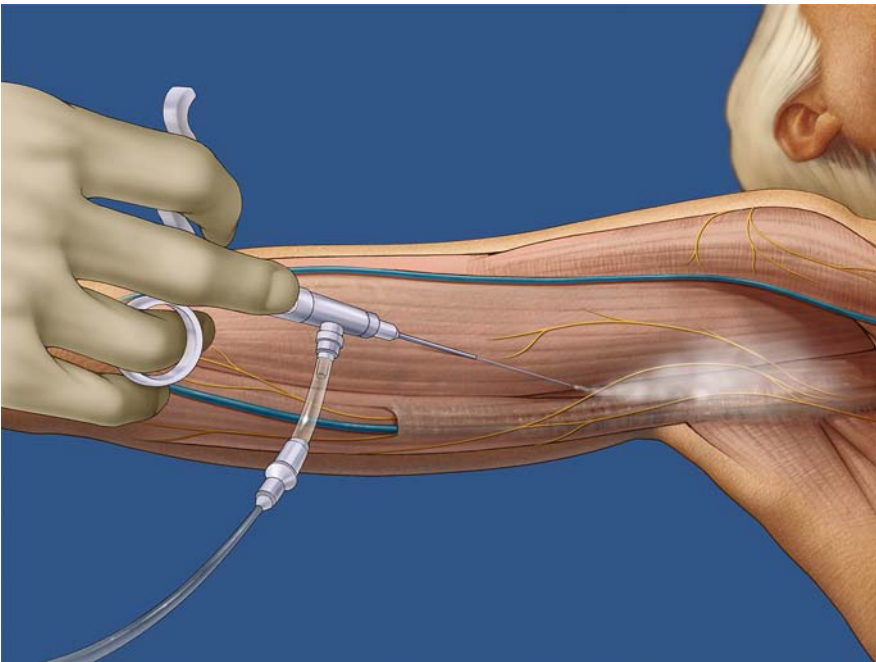
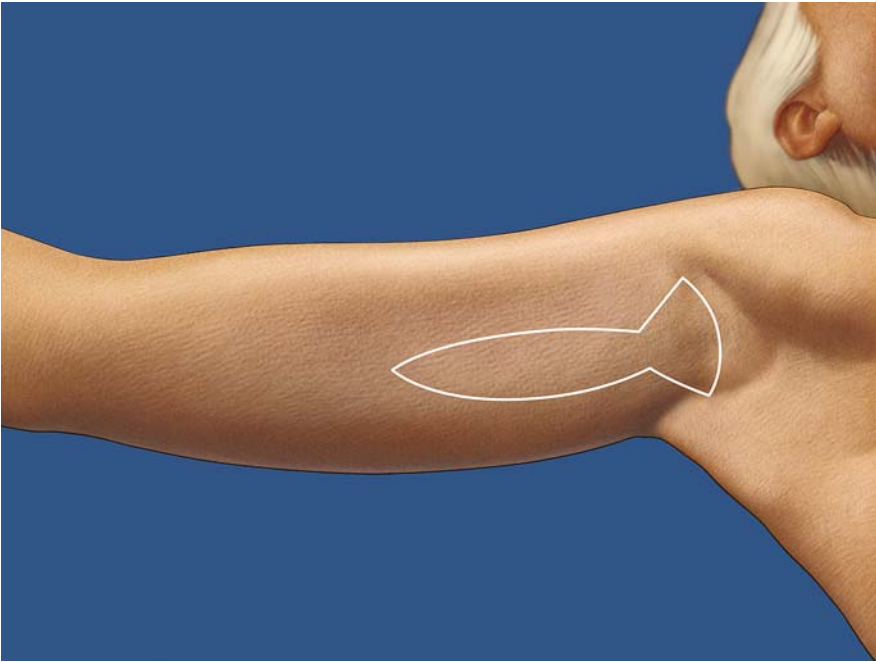
### Positioning, Disinfection

- The patient's arms are abducted by 90° before the operation. Care should be taken to position them correctly so that there is no pressure or traction in order to avoid damaging the brachial plexus. Disinfection with Cutasept is carried out to the edges and to the breast region.

#### ⊙ Tumescence

- Tumescence is then performed without blurring the marked borders. Approximately 200 ml of tumescence solution without the addition of triamcinolone acetonide is injected manually per side (0.9% NaCl, 500 ml, 1% prilocaine 250 mg = 25 ml, epinephrine 0.5 mg, 8.4% NaHCO<sub>3</sub> 5 mEq).
- Tumescence is carried out in the layer where dissection will later be done, i.e., on the fascia of the upper arm, so that the skin/fat flap is separated from the fascia by the injection itself. During tumescence the surgeon can feel the thickness of the flap and can therefore carry out dissection quickly and with almost no bleeding. The tumescence also predetermines the level of dissection, so that no deeper vessels or nerves are damaged.





---

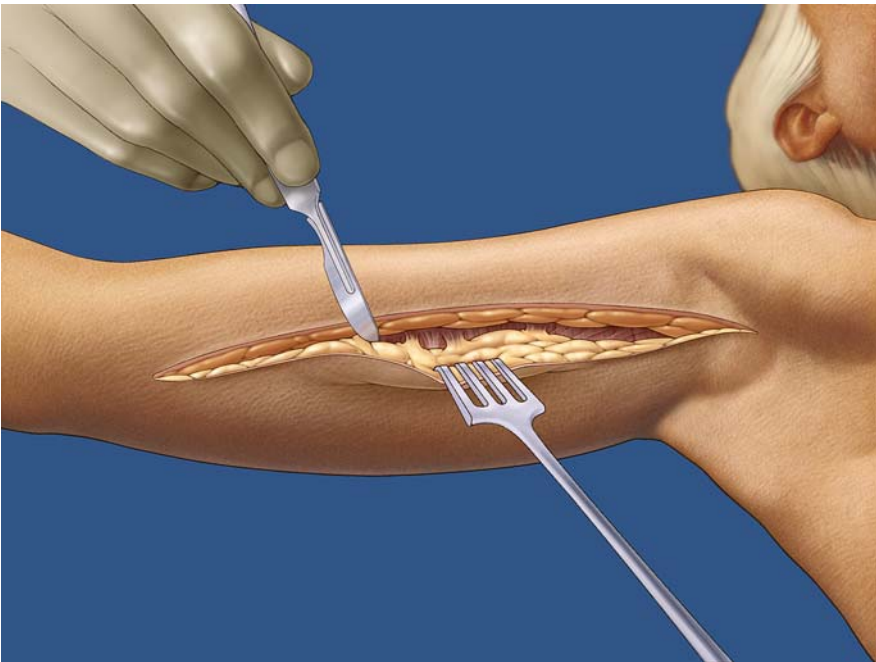
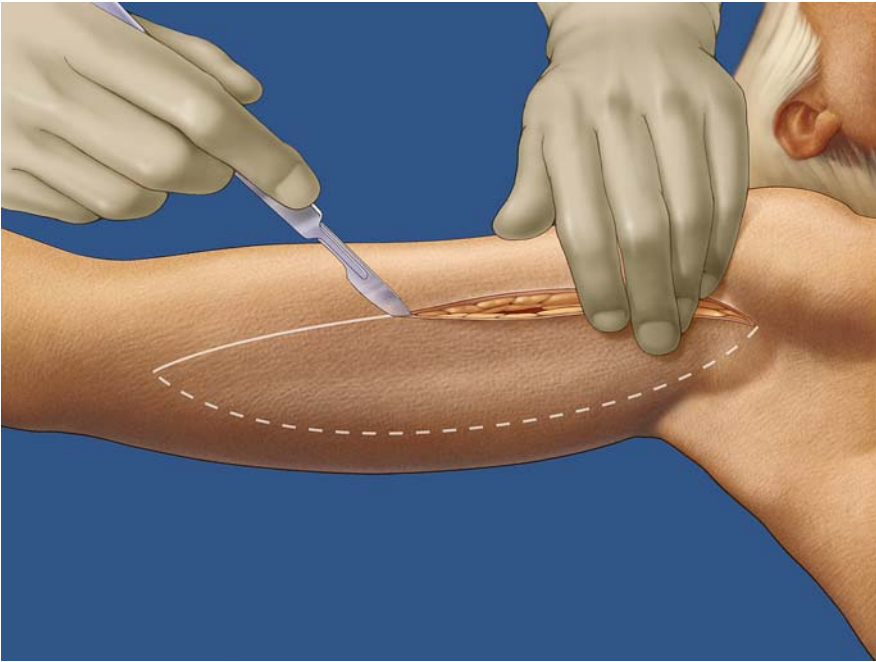
⦿ **Incision**

- The incision starts at the marked line above the sulcus bicipitalis medialis. The incision made with a size 15 scalpel should be wedge-shaped ( $30^\circ$ ), so that when the wound is closed later (equilateral triangle with the deepest point on the upper arm fascia), an inverted scar is not produced.

---

⦿ **Superficial Preparation**

- After the upper, tangential ( $30^\circ$ ) incision has been made, the assistant inserts a sharp retractor and pulls it forward gently so that dissection can be done more easily with a scalpel. It should be ensured that the medial brachial cutaneous nerve is not damaged.



---

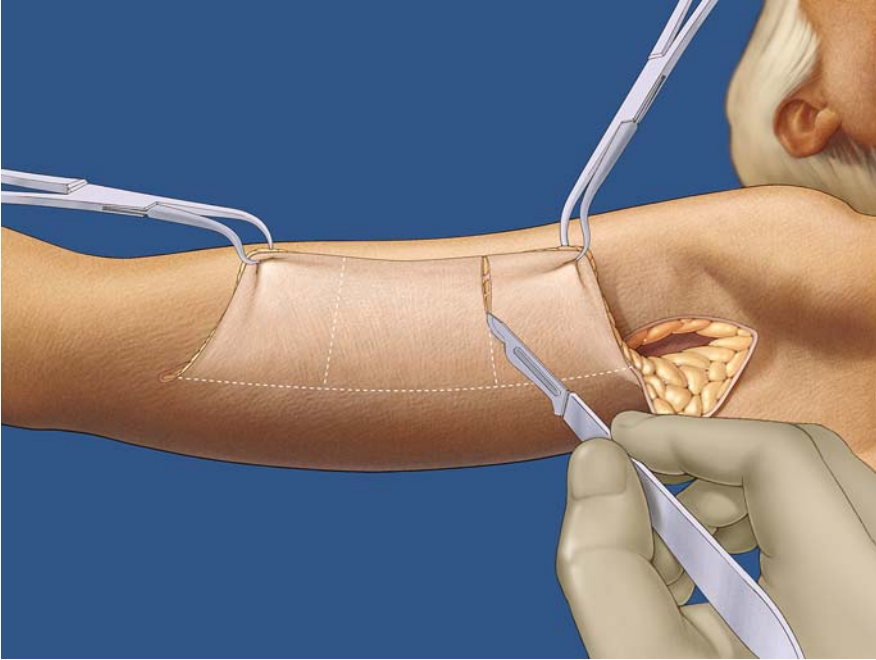
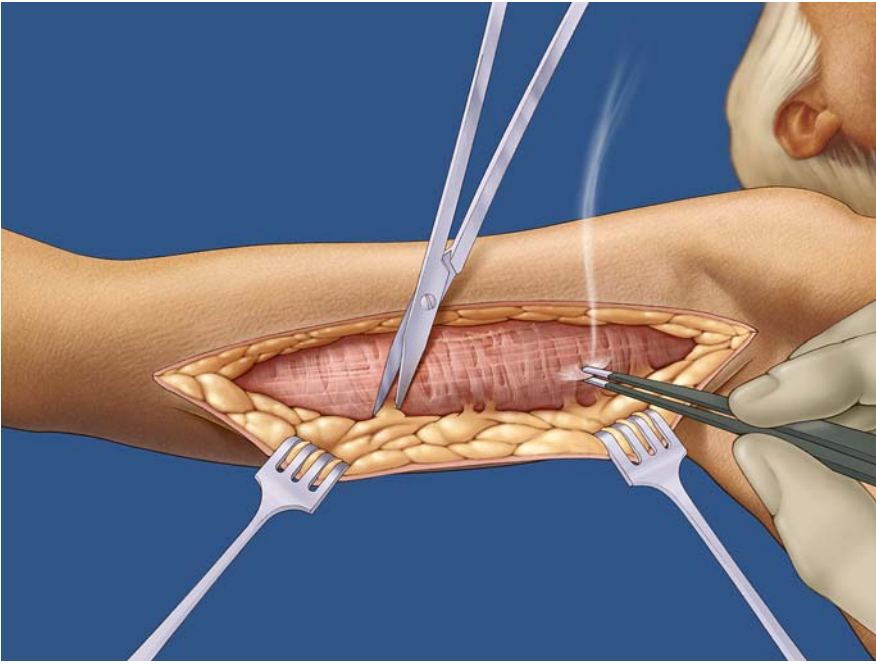
### Deep Preparation, Hemostasis

- The skin flap is best dissected by pulling it upward with two four-pronged retractors. During this procedure the assistant should ensure that the retractors are pulled forward gently. At the same time the assistant can carry out hemostasis with bipolar tweezers. As a result of the tumescence infiltration, the surgical area is clearly visible and not covered with blood. This enables dissection from the fascia of the upper arm to be carried out quickly. The surgeon can do this with either scissors or a scalpel.

---

### ◉ Incision of the Dissected Dermofat Flap in Stages

- Once the skin/fat flap along the fascia of the upper arm has been dissected to deep within the marked resection border, Backhaus clamps are attached to both ends and rotated gently in a cranial direction. Resection of surplus fatty tissue, in particular at the cranial and caudal incision borders, is carried out appropriately. Incision of the dermofat flap at marked sites is then done while monitoring the tension. When doing this it is important that the incisions are made under slight tension stage by stage in line with the cranial incision line to prevent too little skin from being excised, resulting in an unsatisfactory result, or too much skin being excised, resulting in the scar being placed under too much tension (risk of hypotrophic scarring).



---

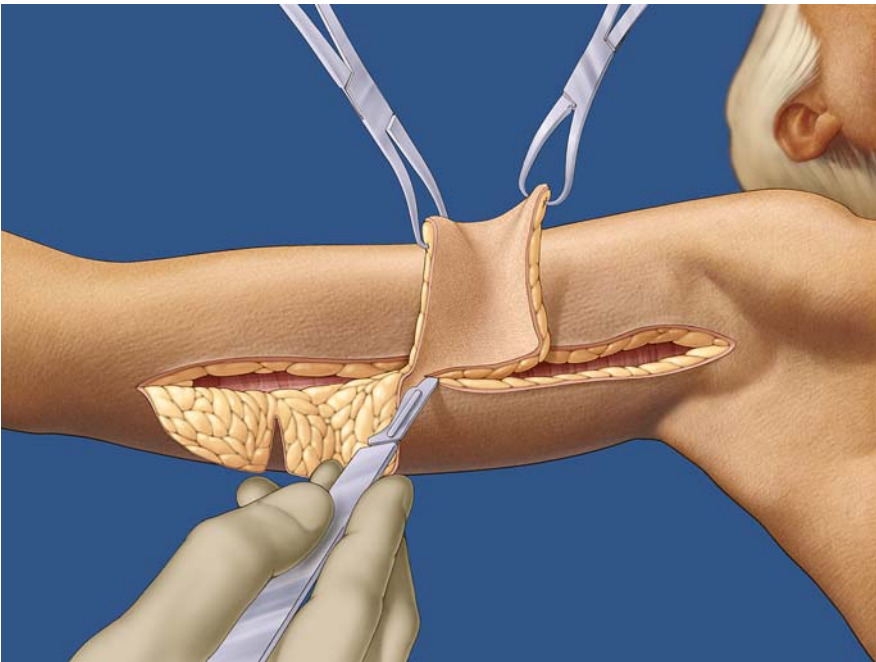
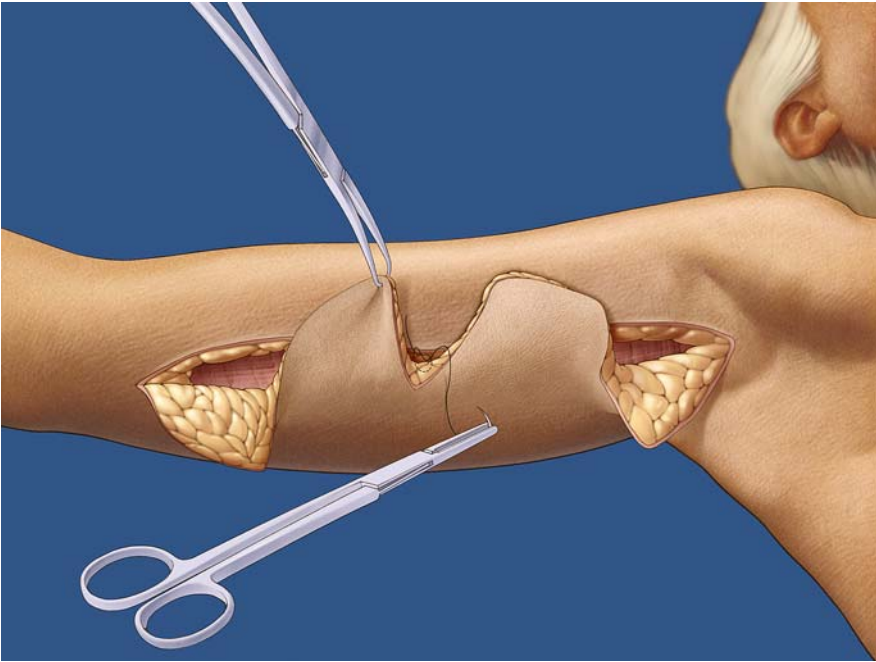
### Fixing of the Skin Flap with 3.0 Monocryl Key Sutures

- 3.0 Monocryl key sutures are placed at the incisions of the marked points. In doing this the correctness of the extent of the incision and later resection can be checked once again. After fixing the skin flap, the surplus sections of skin and possibly of fatty tissue can be seen; these must be removed before skin resection.

---

### ⦿ Resection in Stages

- Resection is carried out in stages while keeping an eye on the resulting skin tension. Following resection, subcutaneous tissue remains on the fascia without undermining. As a result, no wound cavity is created, which would promote seroma formation. Redon drains are not required here.
- Resection is carried out in stages with a size 15 scalpel, and the assistant holds the sections of the flap to be resected upwards under tension with two Backhaus clamps in order to achieve a clean resection border.





---

### • Two-Layer Skin Closure

- The skin edges are closed with concealed subcutaneous interrupted 3.0 Monocryl sutures. Each successive suture bisects the wound length; this prevents “dog ears” at the end of the sutures. It is best if the sutures are started at the distal end and progress to the middle. Suturing can then be started at the proximal end (axilla) and continued to the middle.
- Complete wound closure is then carried out with two-layer 4.0 Monocryl interrupted sutures. The wound is closed, therefore, with so little tension that the cutaneous suturing (running or intracutaneous) then only plays a minor role.

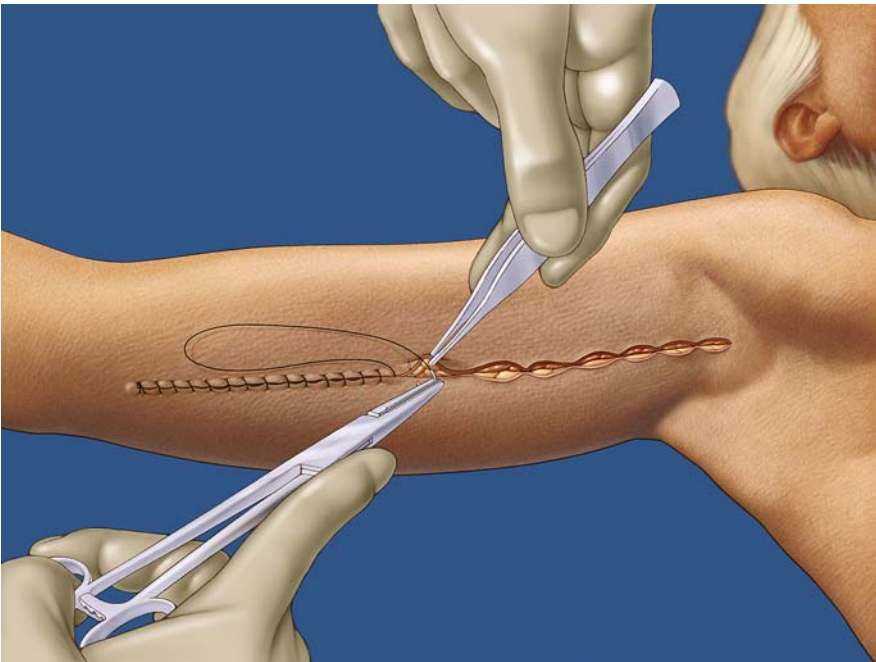
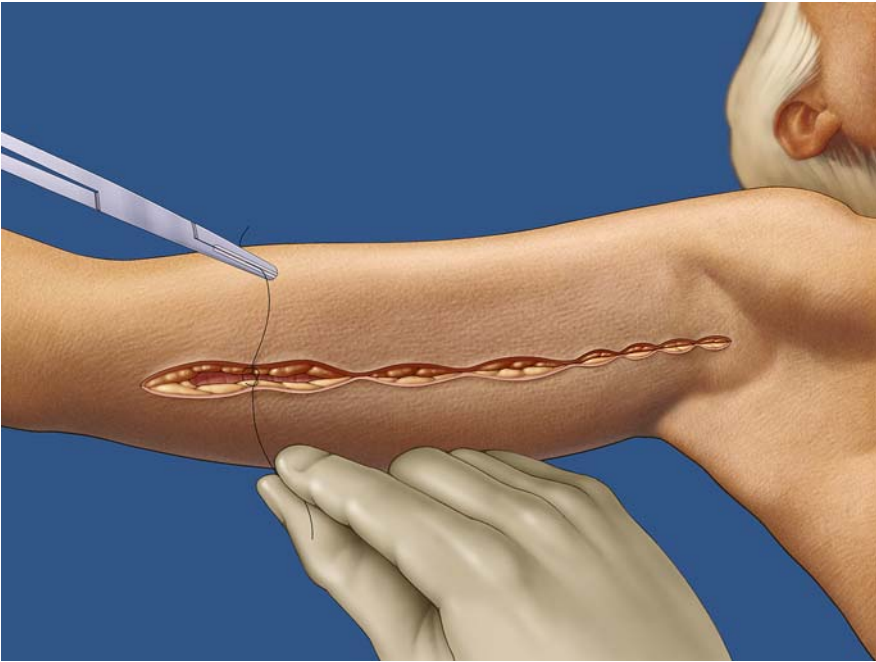
---

### Cutaneous Sutures: Running or Intracutaneous 4.0 Monocryl

- In general, we carry out all cutaneous suturing intracutaneously with 4.0 Monocryl. This suturing method has proved to be the best, as it does not need to be removed and does not cause granulomas. It produces optimum healing of the suture line.

Running sutures should also be mentioned in this manual. A study ( $n = 25$ ) comparing running sutures with intracutaneous sutures showed that results were similar. Running sutures are removed after 8 days.





---

### ● Dressing

- Steri-Strips are first applied as a dressing to relieve the tension on the cutaneous sutures. Afterwards, sterile cotton is wound around the Cuti-plast wound dressing. In addition, the arm is then loosely wrapped with elastic bandages from the wrist to the shoulder.

### Aftercare

The operation can be carried out either on an inpatient or outpatient basis.

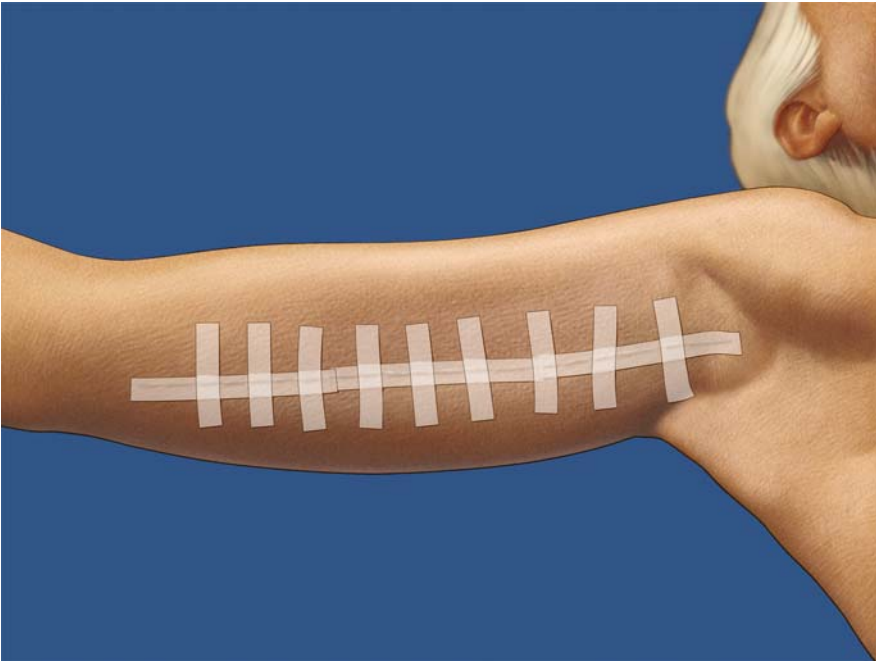
- The dressing is removed on the first postoperative day. The Steri-Strips are left in place for 8 days and can be removed by the patient. During this time there should be antibiotic prophylaxis and the arm should be elevated. The patient should avoid physical exertion for a period of 2–3 weeks in order to permit undisturbed wound healing. To prevent congestion of the lymphatics, lymph drainage can be carried out from the 8th postoperative day.

After removing the Steri-Strips, the patient should treat the scar with dexapanthenol ointment for 2 weeks and then with silicone ointment for a further 2 months. If after 2 months it can be seen that scarring is disturbed, it can be treated, as with all scars, with intralesional injections of triamcinolone crystal suspension 40 mg. With any scar this treatment should be carried out as soon as possible, as these injections improve erythema and bulging scars considerably in the first few months.

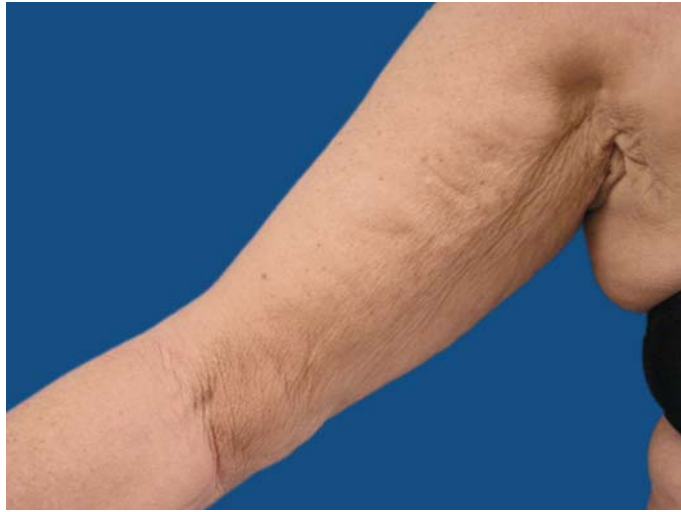In extreme cases hypertrophic scars must be excised after a period of 12 months and treated with stimulating radiation in divided doses for several days immediately after excision. Cooperation with an experienced radiologist is necessary for this.

**Note:**

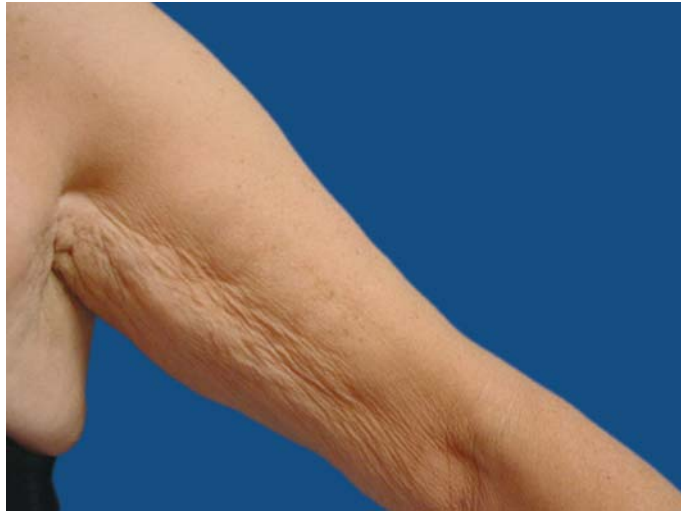It is possible to insert a Redon drain to drain off wound secretions. In most cases, this may be removed as early as the first day after the operation.



**Brachioplasty**



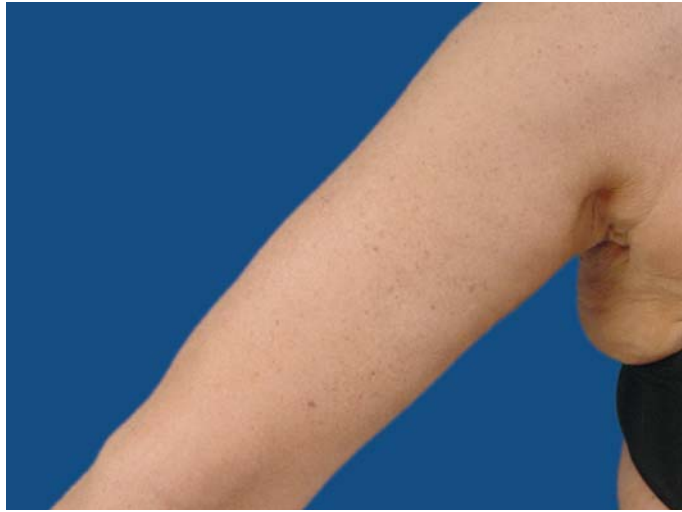Preoperative – right arm



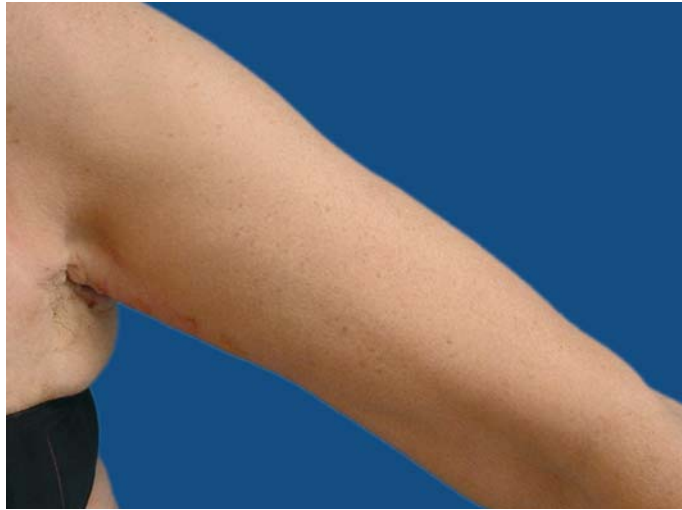Preoperative – left arm

### Results

Patient I: This is a 64-year-old patient with skin folds owing to her age in the entire axilla and upper arm region, extending to the elbow. In this case a longitudinal, spindlelike excision was carried out.



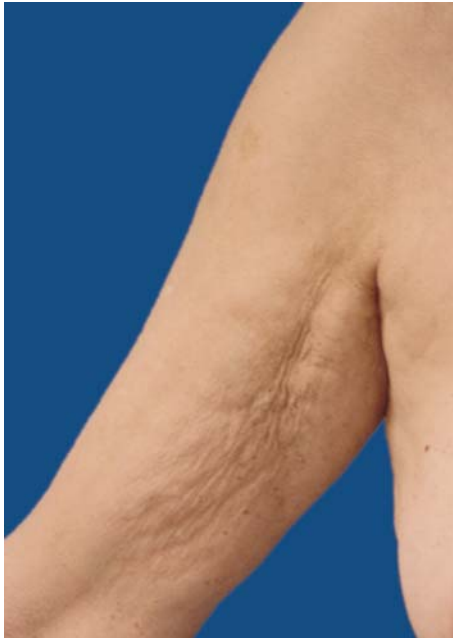Postoperative – right arm



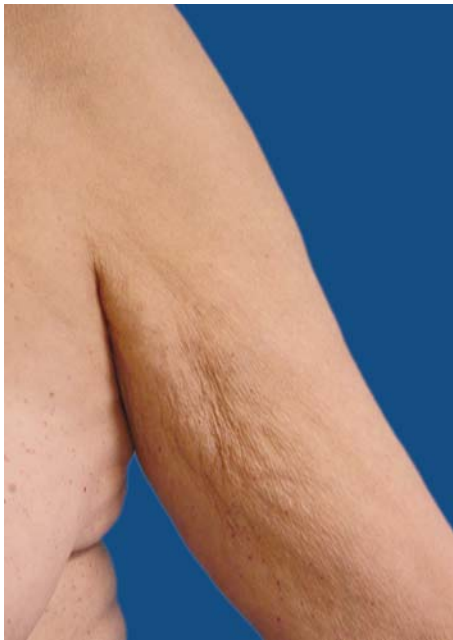Postoperative – left arm

**Patient I: Twelve Months After the Operation**

Twelve months after the operation there is no noticeable scarring, and the skin folds have been eliminated as far as the elbow area.



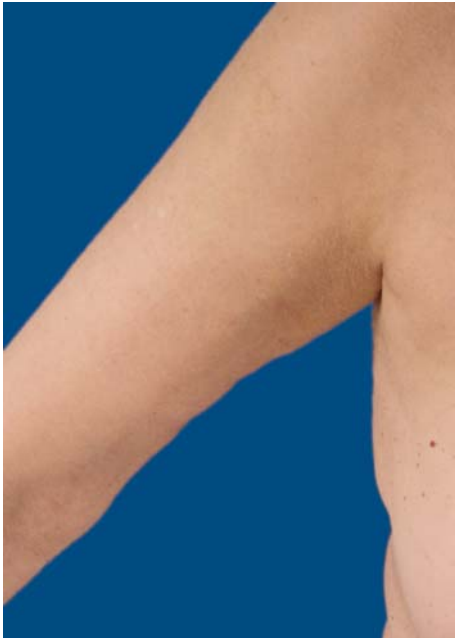Preoperative – right arm



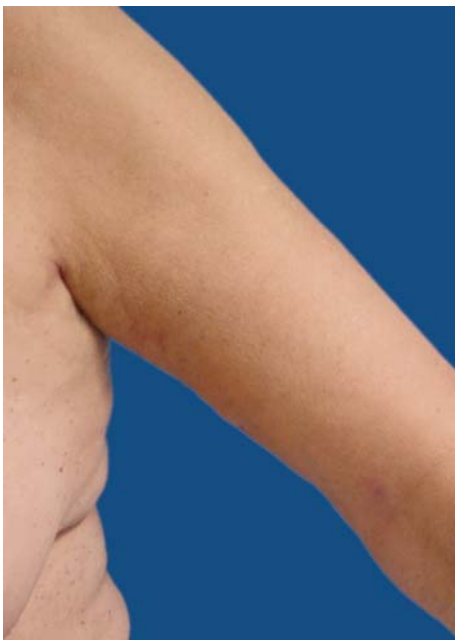Preoperative – left arm

Patient II: This is a 59-year-old patient with folds of skin in the upper third of the upper arm, extending to the axilla.

The “fish-mouth technique” was used for this patient, i.e., the incision was only in the axilla and the upper third of the upper arm. This results in a shorter operation time and less scarring.



Postoperative – right arm



Postoperative – left arm

#### Patient II: Twelve Months After the Operation

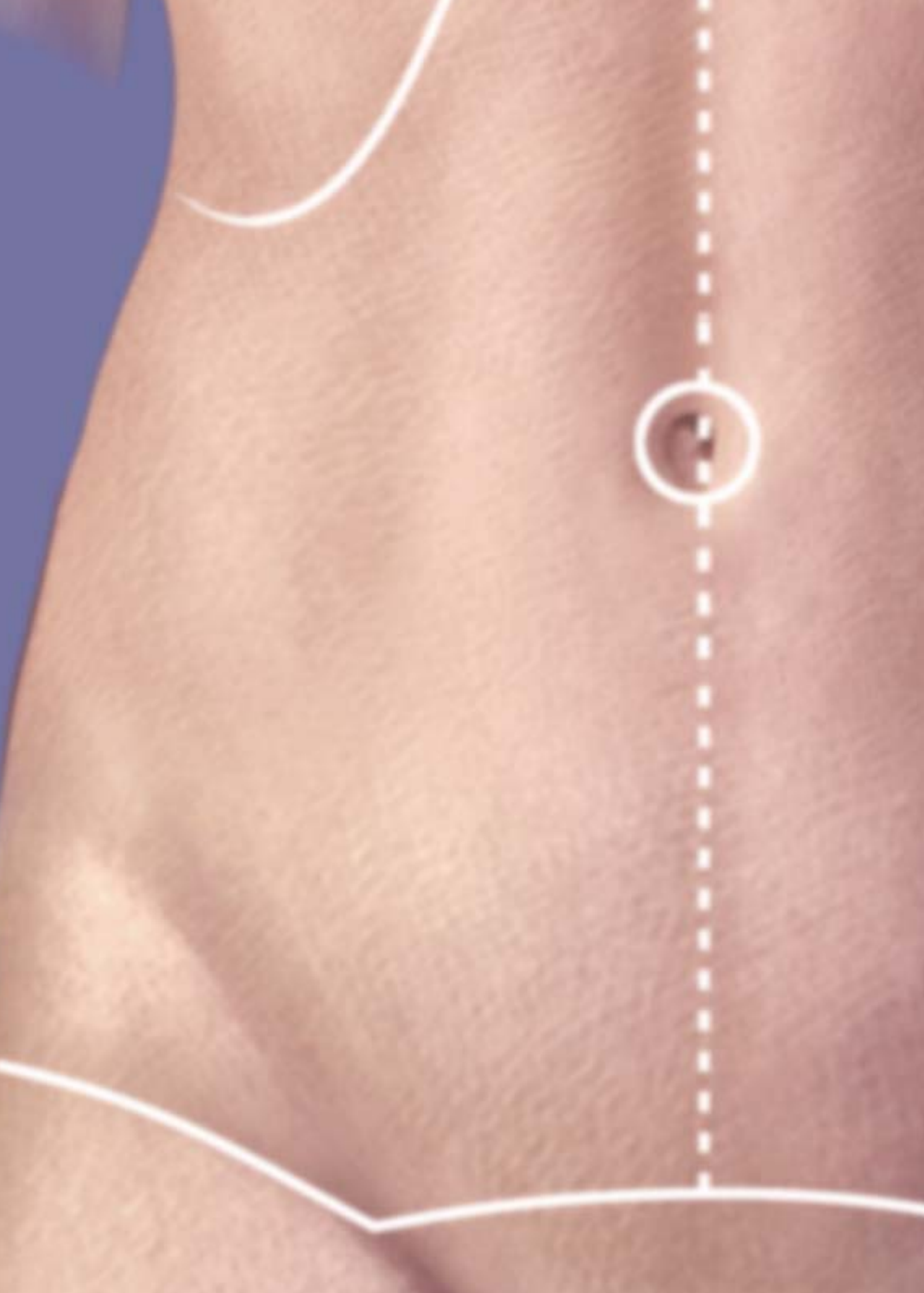
After eliminating the folds, the volume was also reduced. The incision in the axilla and the upper medial part of the upper arm is not visible.

---

## Literature

- Baroudi R (1984) Body sculpturing. *Clin Plast Surg* 11:419–443
- de Souza Pinto EB, Erazo PJ, Matsuda CA, et al (2000) Brachioplasty technique with the use of molds. *Plast Reconstr Surg* 105:1854–1860; discussion 1861–1855
- Gilliland MD, Lyos AT (1997) CAST liposuction: an alternative to brachioplasty. *Aesthetic Plast Surg* 21:398–402
- Gilliland MD, Lyos AT (1997) CAST liposuction of the arm improves aesthetic results. *Aesthetic Plast Surg* 21:225–229
- Goddio AS (1989) A new technique for brachioplasty. *Plast Reconstr Surg* 84:85–91
- Goddio AS (1990) Brachioplasty: new technique. *Ann Chir Plast Esthet* 35:201–208
- Hallock GG, Altobelli JA (1985) Simultaneous brachioplasty, thoracoplasty and mammaplasty. *Aesthetic Plast Surg* 9:233–235
- Hauben DJ, Benmeir P, Charuzi I (1988) One-stage body contouring. *Ann Plast Surg* 21:472–479
- Lillis PJ (1999) Liposuction of the arms. *Dermatol Clin* 17:783–797
- Lockwood T (1995) Brachioplasty with superficial fascial system suspension. *Plast Reconstr Surg* 96:912–920
- Mang WL (1996) *Ästhetische Chirurgie Bd. I*. Einhorn Presse Verlag
- Mang WL (1996) *Ästhetische Chirurgie Bd. II*. Einhorn Presse Verlag
- Nielsen S, Levine J, Clay R, et al (2001) Adipose tissue metabolism in benign symmetric lipomatosis. *J Clin Endocrinol Metab* 86:2717–2720
- Pitanguy J (1981) *Aesthetic Plastic Surgery of Head and Body*. Springer New York Berlin
- Rees TD (1980) *Aesthetic Plastic Surgery*. WB Saunders, Philadelphia
- Regnault P (1983) Brachioplasty axilloplasty and pre-axilloplasty. *Aesthetic Plast Surg* 7:31–36
- Teimourian B, Malekzadeh S (1998) Rejuvenation of the upper arm. *Plast Reconstr Surg* 102:545–551; discussion 552–543





---

<b>Abdominoplasty</b>	
■	Introduction 80
■	Tightening of the Abdominal Wall 80
■	Anatomical Overview 82
■	Instruments 84
■	Duplicate Patient Information 88
■	Preliminary Examinations 88
■	Photographic Documentation 88
■	Surgical Planning 89
■	Postoperative Treatment 90
○	■ Typical Findings: Indications for Tightening the Abdominal Wall 90
■	Marking the Individual Incision Line 92
■	Positioning, Disinfection 94
○	■ Tumescence 94
○	■ Incision 94
○	■ Preparation of the Lower Abdomen 96
■	Incision Around the Navel 96
■	Mobilization and Dissection of the Navel 98
■	Vertical Splitting of the Dermofat Flap as Far as the Base of the Navel 98
■	Complete Mobilization of the Umbilical Stalk 100
■	Dissection of the Upper Abdomen 100
■	Doubling of the Rectus Abdominis Fascia 102
■	Defining the Resection Boundaries with Upper Body Flexed at 30° 104
■	Repositioning of the Navel Using a V-shaped Incision 105
■	Pulling the Navel Out of the V-Shaped Incision with Curved Forceps 106
■	Positioning the Navel 106
■	Trimming of the Skin of the Navel and Adaptation to the V-shaped Incision 108
■	Closure of the Navel in Three Layers 108
■	Fixation of the Surplus Sections of Skin with 2.0 Monocryl Key Sutures 110
○	■ Resection of the Skin in Stages 111
■	Insertion of Redon Drains 112
○	■ Wound Closure in Three Layers 113
○	■ Dressing 114
■	Fitting the Abdominal Belt 114
■	Results 116
■	Literature 118

---

## Introduction

If the result of liposuction in the abdominal area is inadequate or there is an excessive overhang of abdominal skin and subcutaneous adipose tissue, it may be beneficial to perform an abdominoplasty to improve the functional and aesthetic result. In the abdominoplasty, the surplus section of abdominal skin is removed with the attached subcutaneous adipose tissue. In a few cases, resection of the infraumbilical surplus tissue will be sufficient, but usually a complete abdominoplasty with umbilical translocation must be performed to achieve optimal results. In this procedure, tightening of the periumbilical area is also extremely significant, for example, with extreme fold formation following pregnancies. Rarely, there is also slackening of the abdominal muscles. This should be treated prior to tightening of the abdominal wall (e.g., by physiotherapy).

The patient's skin type and age play an important part in this operation. In many cases, it is not possible to remove all the folds and striae and this must be explained to the patient. Furthermore, female patients must avoid pregnancy in the foreseeable future. It is not necessary to achieve a specific weight for this procedure, but a few conditions relating to this should be fulfilled. The body weight should have stabilized several months before the procedure, and this should be at a level the patient can maintain after the procedure.

## Tightening of the Abdominal Wall

An experienced aesthetic surgeon must look carefully at the indications for liposuction and for tightening of the abdominal wall. At present, unfortunately, a decision is taken to carry out liposuction too often, and the patient is later disappointed if the skin then hangs down loosely. Frequently, tightening of the abdominal wall is requested by patients who have increased skin accumulation around the umbilical area and a slack lower abdominal wall following pregnancies. It is also frequently requested by patients who have lost a lot of weight (20–40 kg) and by older patients who have a slack abdominal wall.

If performed correctly, the operation itself will be successful in the long-term and satisfactory for the patient. In relation to the surgical technique, in addition to precise dissection of the abdominal fascia with immediate hemostasis, the incision line in the bikini area must be marked carefully and the repositioning and reconstruction of the navel must be performed well so that the result is satisfactory for the patient. It must be ensured that there are no umbilical or abdominal wall hernias.

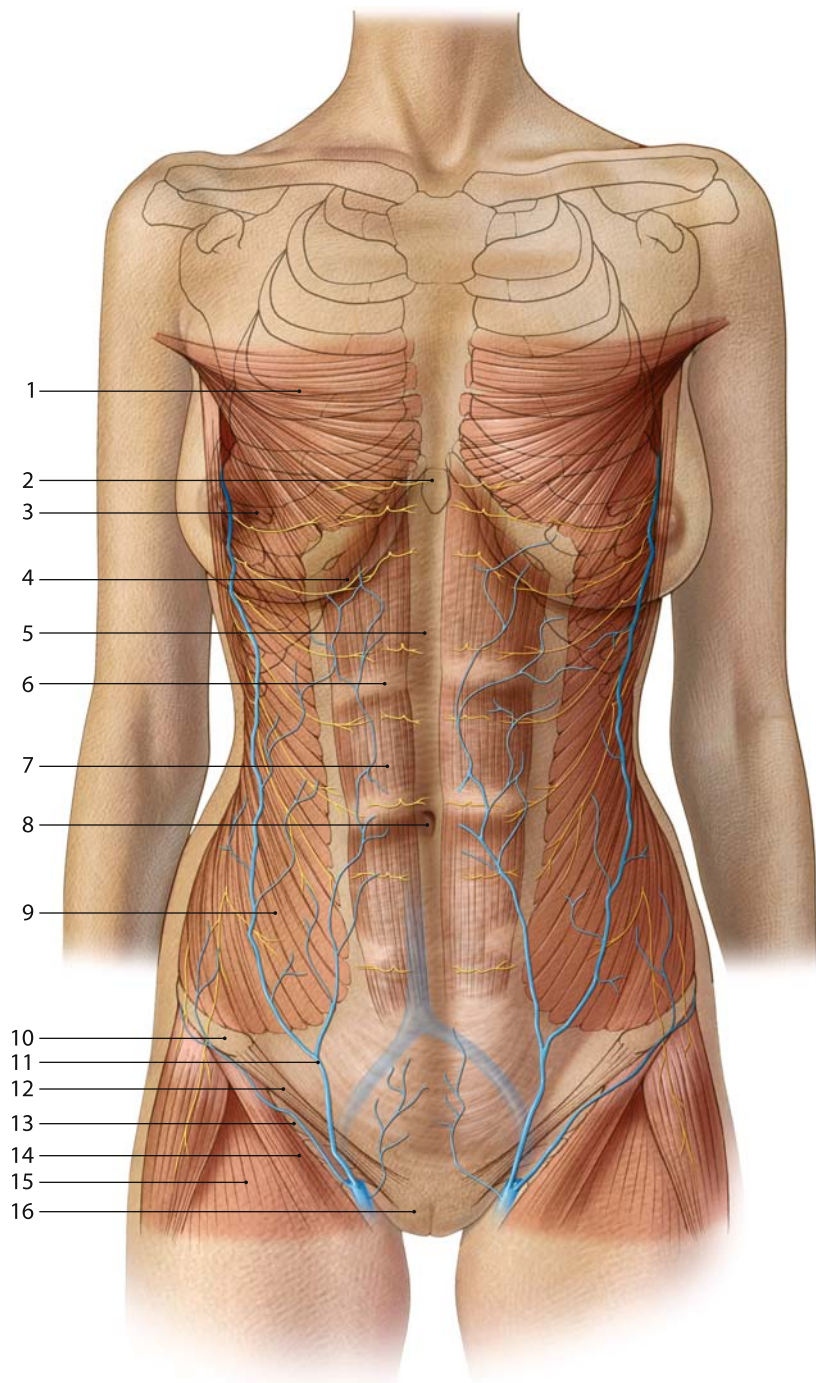
---

For reconstruction of the navel, we have described the method that we find the easiest and most comprehensible and has provided the best results. When making the incision in the bikini area, it should be ensured that no “dog-ears” are formed at the side and that, following complete dissection as far as the costal arch with the upper body slightly angled, resection of the skin is carried out in stages with key sutures in such a way that the skin flap is resected precisely, section by section, and without any significant tension so that necrosis is avoided. The video shows that the fat is resected obliquely, also stage by stage, to avoid any postoperative retraction of the flap. Immediate hemostasis is important so that the Hb value does not fall below 8 mg/dl. It is recommended that obese patients give an autologous donation of blood 4 weeks before the operation. Patients must also be given thrombosis prophylaxis and infection prophylaxis intra-operatively and for 10 days after the operation.

---

### Anatomical Overview

1. M. pectoralis major
2. Xiphoid process
3. M. serratus anterior
4. Costal arch
5. Linea alba
6. Tendinous intersections of recti. abd.
7. M. recti abd.
8. Umbilicus
9. M. obliquus ext. abd.
10. Anterior superior iliac spine
11. Superficial epigastric vein
12. Inguinal ligament
13. Subinguinal sulcus
14. M. sartorius
15. M. rectus femoris
16. Mons pubis



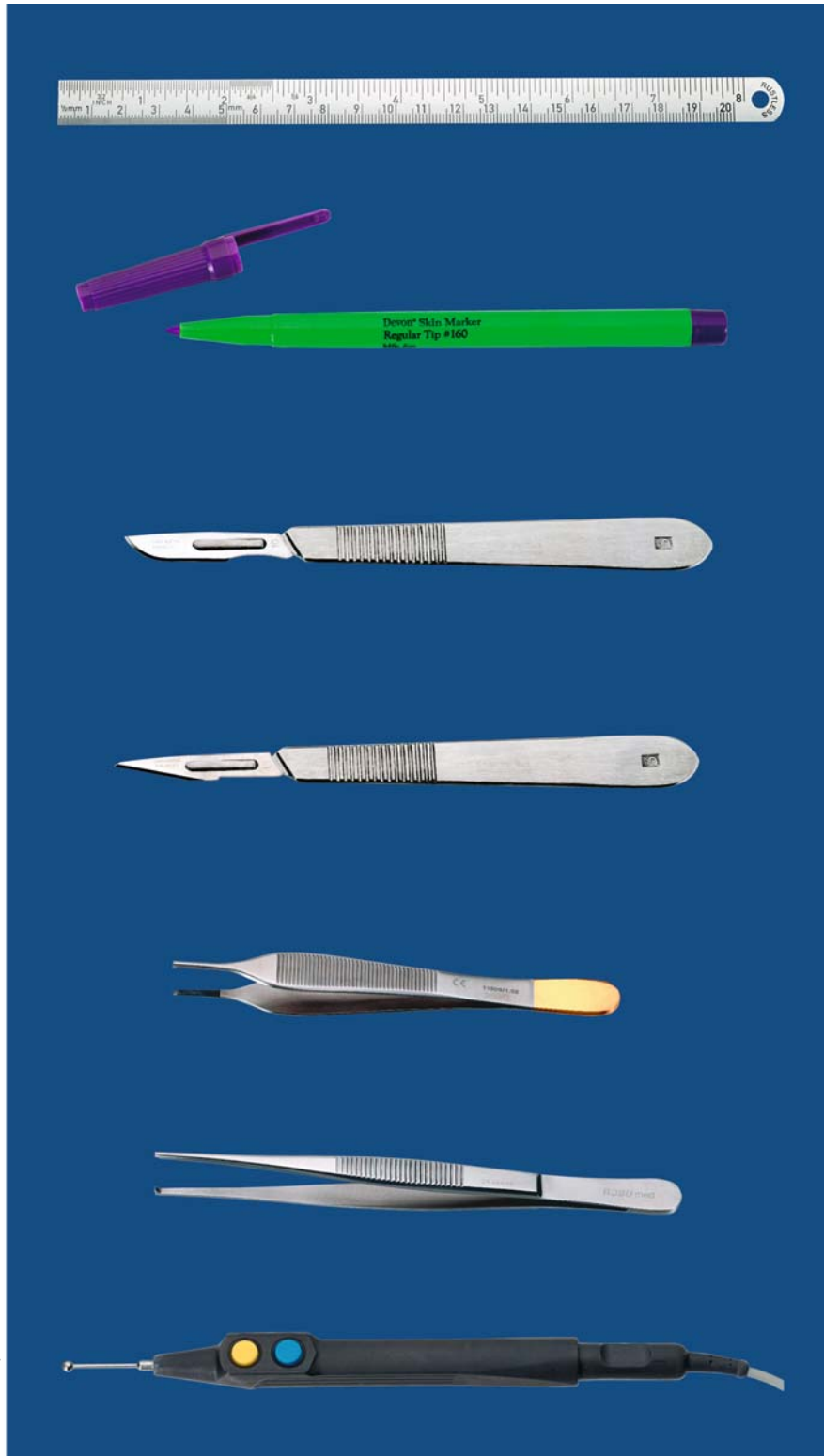
---

**Instruments \***

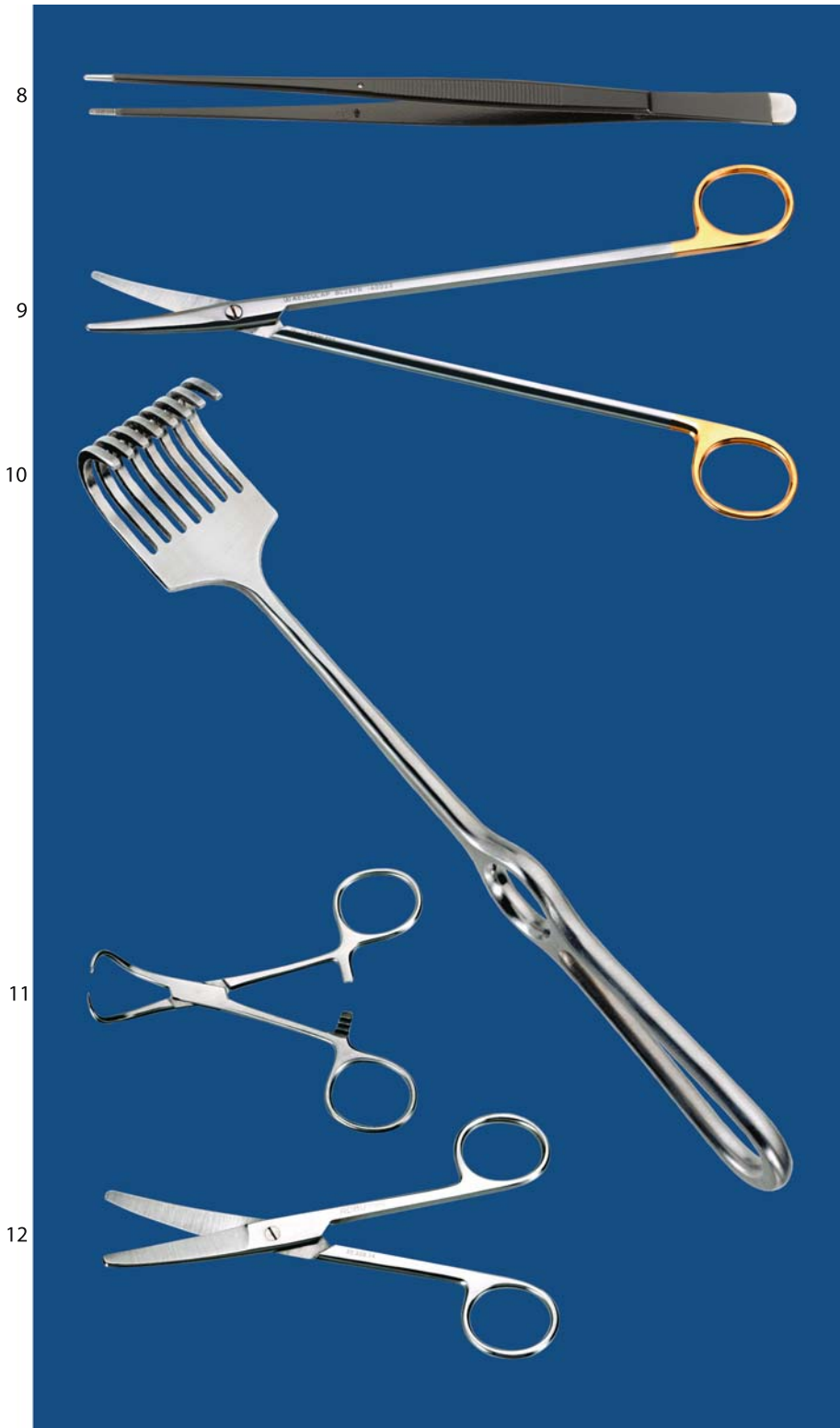
- Sterile centimeter rule [1]
- Sterile marking pen [2]
- Scalpel size 10 blade [3]
- Scalpel size 11 blade [4]
- Adson tweezers with plate [5]
- Surgical tweezers [6]
- Monopolar electrocoagulation [7]
- Insulated anatomical tweezers for hemostasis [8]
- Metzenbaum dissection scissors [9]
- Rake retractor [10]
- Backhaus clamps [11]
- Cooper scissors [12]
- Langenbeck retractor (large) [13]
- Needle holder, large [14]
- Needle holder, small [15]
- Redon introducer [16]
- Curved forceps (for hemostasis) [17]
- Delicate, long, single-pronged wound retractor [18]

---

\* Robumed, Postfach 162, 78502 Tuttlingen, Germany  
BBD Aesculap GmbH, Am Aesculap-Platz, 78532 Tuttlingen, Germany









---

### **Duplicate Patient Information**

The patient is first given comprehensive information about the objectives and risks of the procedure on the day of the first consultation.

A written record is kept of this.

One day before the surgical procedure, the patient is again given comprehensive information on two separate occasions: once by the surgeon and once by the surgical resident. All the risks are set down in writing at this time.

Severe blood loss requiring a transfusion of blood or blood components occurs rarely. An autologous blood donation may be very sensible for obese patients and for extensive reconstructions of the abdominal wall.

It is possible to avoid damaging the internal abdominal organs by carrying out an ultrasound examination before the operation and by ruling out hernias. Otherwise, if there is an umbilical hernia, the abdominal cavity may be opened up during the dissection of the navel. As the wound surface is large, the patient must be made aware that postoperative bleeding, hematomas, and wound-healing disturbances may occur following the operation. Therefore, the operation must be performed in the hospital, careful postoperative wound checks must be carried out, and thrombosis and antibiotic prophylaxis must be given.

If the scars are taut, they may enlarge and this may result in thick, distended, discolored, painful scars.

### **Preliminary Examinations**

- Current preoperative routine laboratory tests, ECG, chest X-ray
- Clinical examination of the patient with ultrasound findings to rule out hernias
- Possibly two autologous blood donations

### **Photographic Documentation**

- Patient in standing position from the front
- Patient in standing position from two sides
- Patient in standing position from behind

---

## Surgical Planning

Tightening of the abdominal wall is indicated if the skin no longer shrinks following substantial weight loss, or after a pregnancy that has overstretched the abdominal skin and, as a result of this, the elastic fibers of the skin have been destroyed (cellulite) or the abdominal muscles have been strained and have moved away from one another in the center, which has resulted in divarification with a midline hernia. Retracted and painful scars following a gynecological operation (caesarian section) can also be a reason for tightening the abdominal wall.

If the patient is severely overweight, weight loss before the operation is necessary. In rare cases, tightening of the abdominal wall may be combined with liposuction.

The operation is performed under general anesthesia. The type of incision depends on the type and amount of surplus skin.

On the day before the operation, the surgeon has a discussion with the patient about the changes requested by him/her and the performance of the operation itself.

The incision is marked precisely on the patient, who should be in a standing position. When doing this, it should be ensured that a median line runs from the xiphoid process over the navel to the mons pubis and that there are no differences in the sides when drawing the line. A vertical incision is to be avoided. If there is not too much surplus skin, it is better to site the incision slightly more cranially.

The incision line is usually to be marked through the layer of fat and the surplus skin. A good estimation of how high the incision must be to avoid the necessity of a vertical incision can be made before the operation. This is the surgeon's art.

Whether the incision line is horizontal or W-shaped is not important. The important factor is the patient's individual anatomical characteristics, and the individual incision line should be adapted to these.

Thrombosis prophylaxis with s. c. fractionated heparin given once daily should be started the day before the operation. This thrombosis prophylaxis should be continued for 10 days after the operation, as one of the main risks in tightening of the abdominal wall is the danger of thrombosis and embolism.

Intraoperative infection prophylaxis with cefaclor 2 g.

---

### Postoperative Treatment

In order to relieve the pressure on the sutures, it is necessary to position the bed in a specific way for the first 3 days after the operation. The knees should be at an angle and the upper body slightly raised. The patient should be mobilized as early as the first day after the operation to prevent blood clots forming. Initially, there should be no extension of the upper body, so that wound healing is not impaired. Frequent movement of the legs is good, as this promotes the return blood flow.

On the second day after the operation, the Redon drains are removed, the dressing is changed, and a special compression girdle is fitted.

Thrombosis prophylaxis (fractionated heparin s.c.) and antibiotic protection (oral cefaclor) should be carried out for 10 days after the operation.

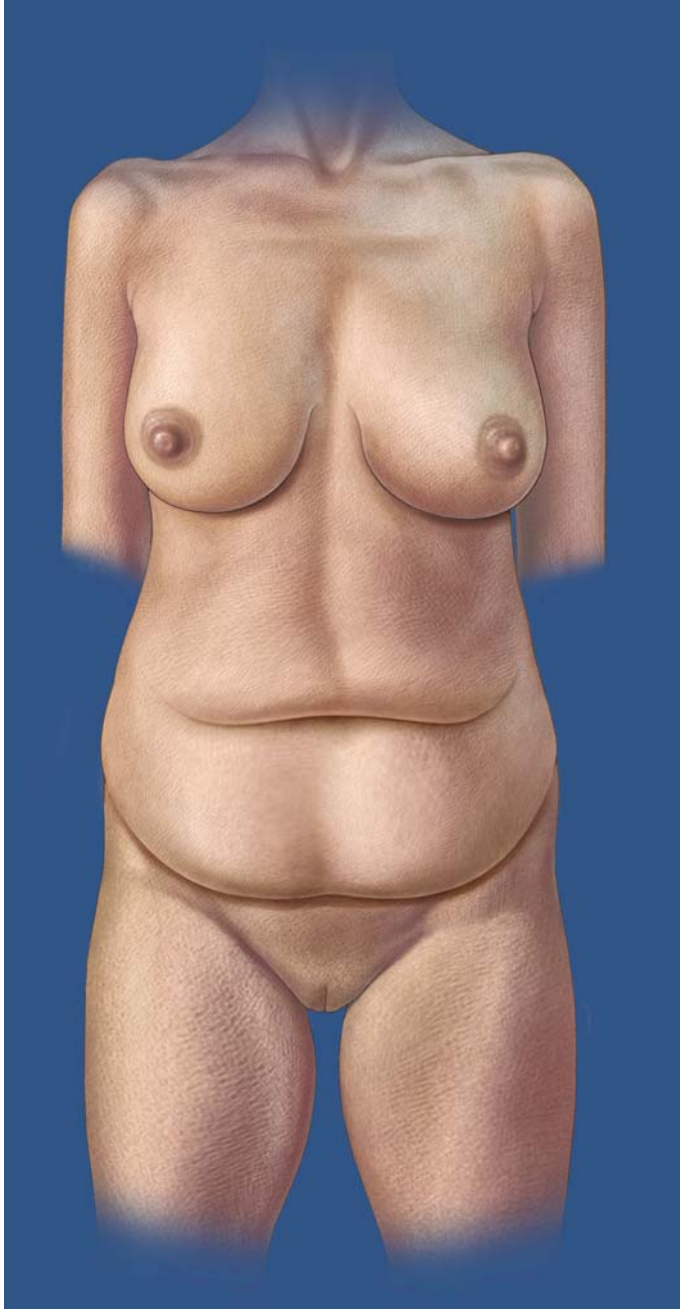
The compression girdle should be worn for 4 weeks; then intensive care should be taken of the scar with silicone gel and/or silicone plasters.

It is possible to resume sporting activities after 8 weeks.

#### ⦿ **Typical Findings: Indications for Tightening the Abdominal Wall**

The limit of the indications for liposuction in the area of the abdomen/hips is exceeded if either the skin is slack and cracked (severe cellulite) following pregnancies or all the skin of the lower abdomen is slackened as a result of the aging process or extreme weight loss.

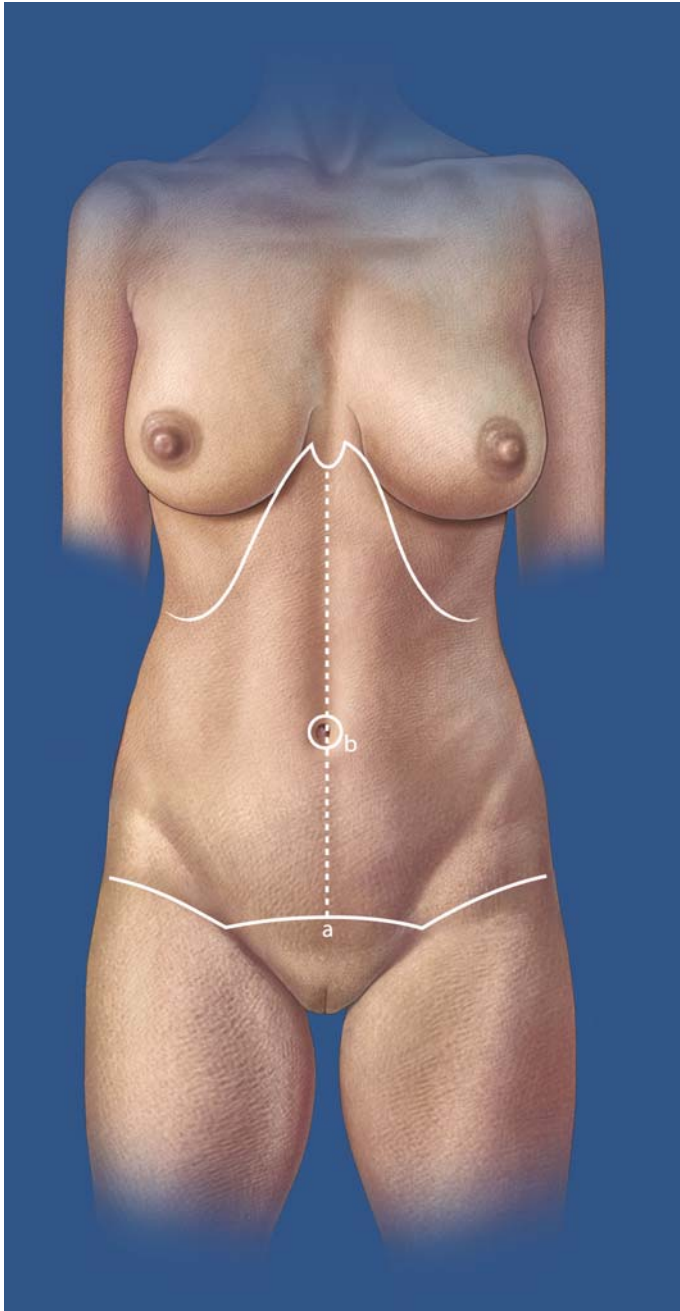
The incision line is marked through the surplus skin and should not be extended beyond this laterally and cranially in the bikini region.



---

### Marking the Individual Incision Line

- Before the operation, the midline from the xiphoid process to the mons pubis and the W-shaped or arched horizontal incision line will be marked on the patient, who should be standing. The horizontal incision line should be marked in the pubic hair boundary to approximately 3–4 cm caudal to the anterior superior iliac spine on both sides or steeper/straighter according to the requirements and the patient's characteristics. Therefore, the most wide-ranging incision variations are possible, depending on the individual findings for the patient. It is important that the incision line is marked in the relaxed skin tension lines, preferably does not extend beyond the bikini region, and is selected in such a way that a vertical incision is not required. It may also be useful to mark the course of the costal arch for orientation.



- a: Lower border of the incision edge
- b: Lower boundary of the navel



---

### Positioning, Disinfection

- The operation is performed with the patient in a supine position. The upper body is raised by 30° and the hips and knee are slightly flexed. It should be ensured that the extremities are well padded and positioned. An indwelling catheter is inserted that should be left in place for 24 h.

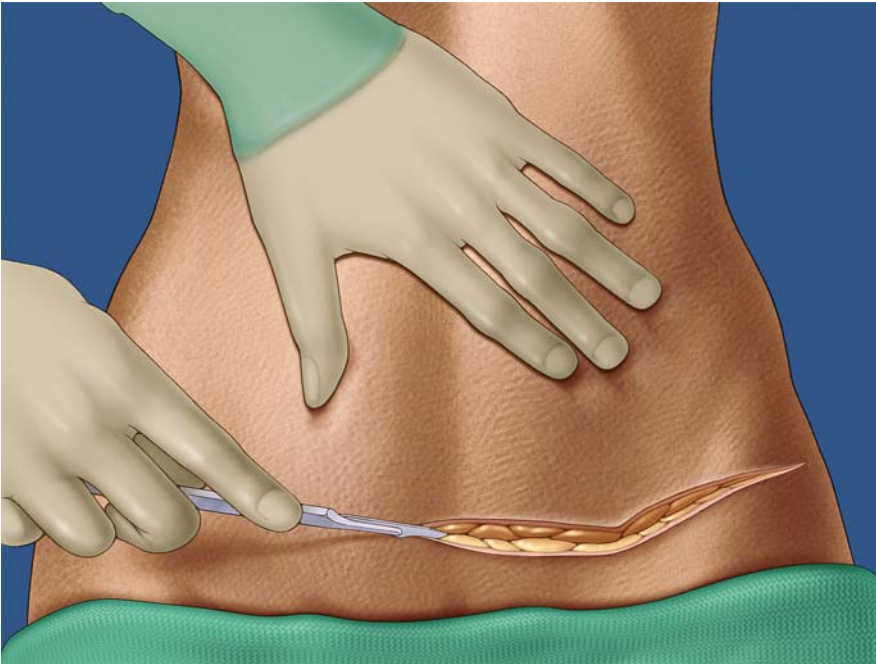
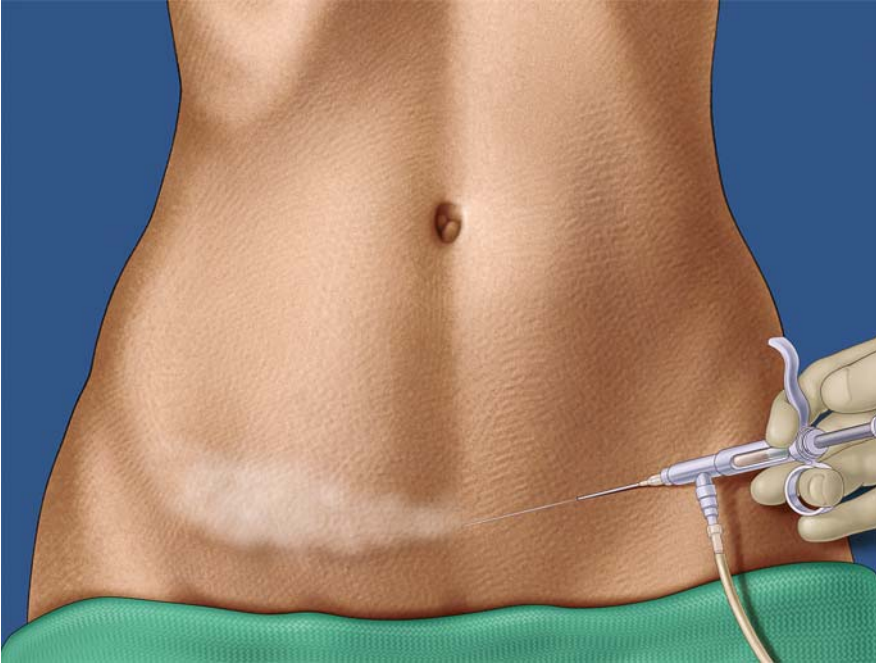
### • Tumescence

- Following disinfection and sterile draping, the incision is tumefied with 500 ml tumescence solution (0.9% NaCl 500 ml, 1% prilocaine 250 mg = 25 ml, epinephrine 0.5 mg, 8.4% NaHCO<sub>3</sub> 5 mEq). The tumescence solution (500 ml) should not be injected more than twice, and this will not be necessary. Larger quantities of tumescence solution given under general anesthesia may increase the danger of thrombosis and cause hypervolemia and even pulmonary edema.

---

### • Incision

- Following the individually marked incision line, a sharp incision is made with the size 10 scalpel as far as the rectus fascia. The scalpel should be introduced at an angle of 30° so that the resection edges can be brought together later, section by section, without the formation of cavities below and depressions above. The subsequent scar is a sign of a wellperformed abdominoplasty.



---

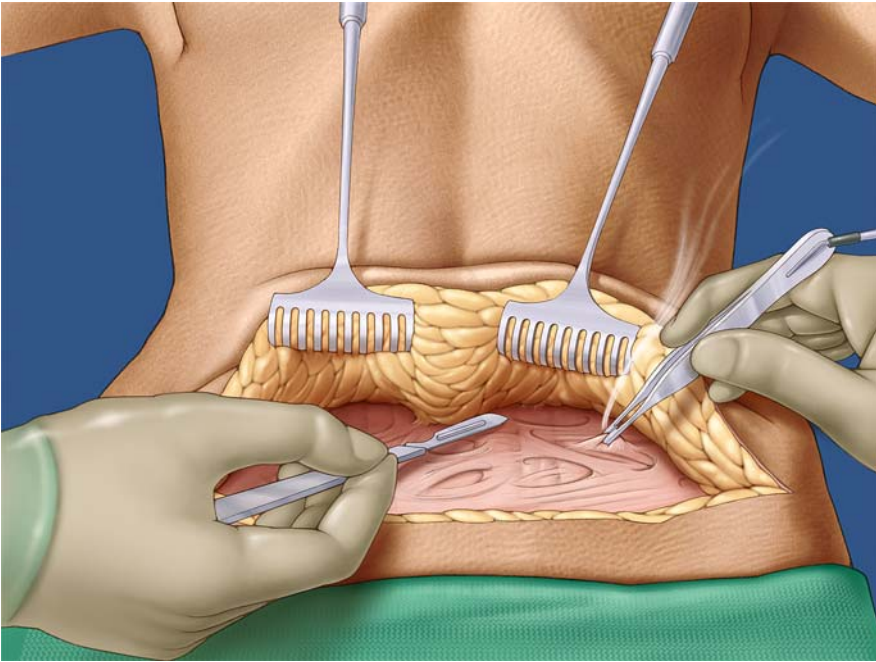
### ● Preparation of the Lower Abdomen

- After the abdominal fascia has been identified, the cutaneous/fatty flap is dissected cranially along the superficial fascia. The correct layer can be easily dissected with both sharp and blunt instruments. The perforating vessels are electrocoagulated.
- Dissection must be performed with careful hemostasis, as otherwise there may be a drop in the Hb value later owing to the large wound surface. The abdominal fascia must be handled carefully and perforations must be avoided. Purse-string suturing can also be carried out if there is more severe bleeding. If the fascia is damaged, this must be closed immediately with 3.0 Vicryl interrupted sutures.

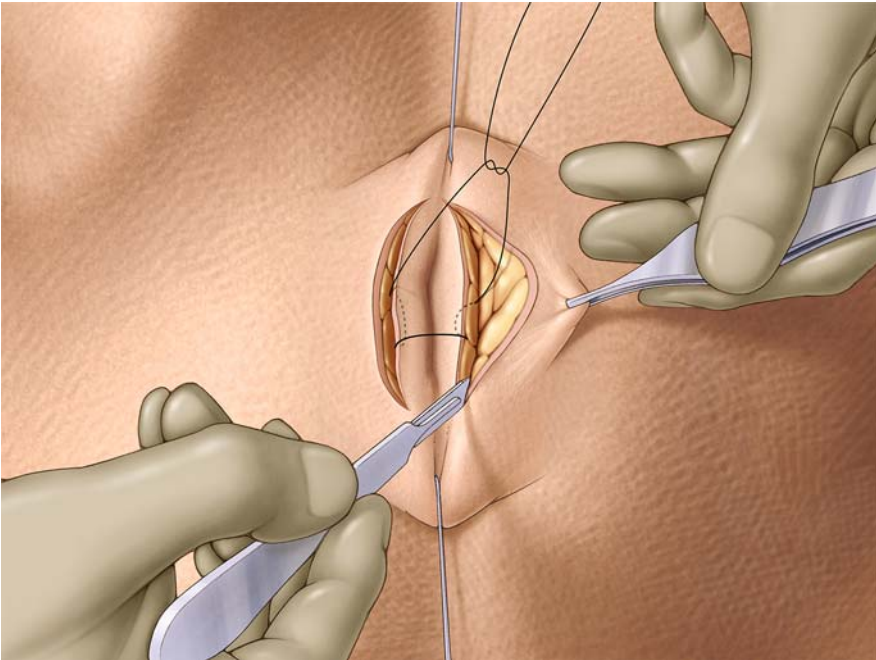
---

### Incision Around the Navel

- If dissection is performed in the lower abdomen as far as the level of the navel, a circular incision should be made around the navel. The assistant holds the cranial and caudal areas of the region taut with two single-pronged retractors so that the incision can be made easily.



Holding suture



Single-pronged retractor

---

### Mobilization and Dissection of the Navel

- Here the dermofat flap is mobilized away from the navel. The assistant then holds the dissection area taut with the two single-pronged retractors and using surgical tweezers. In the further dissection with the Metzenbaum dissection scissors it must be ensured that the umbilical stalk is sufficiently thick and that a wide base is created during the dissection to prevent later perfusion disorders of the navel.

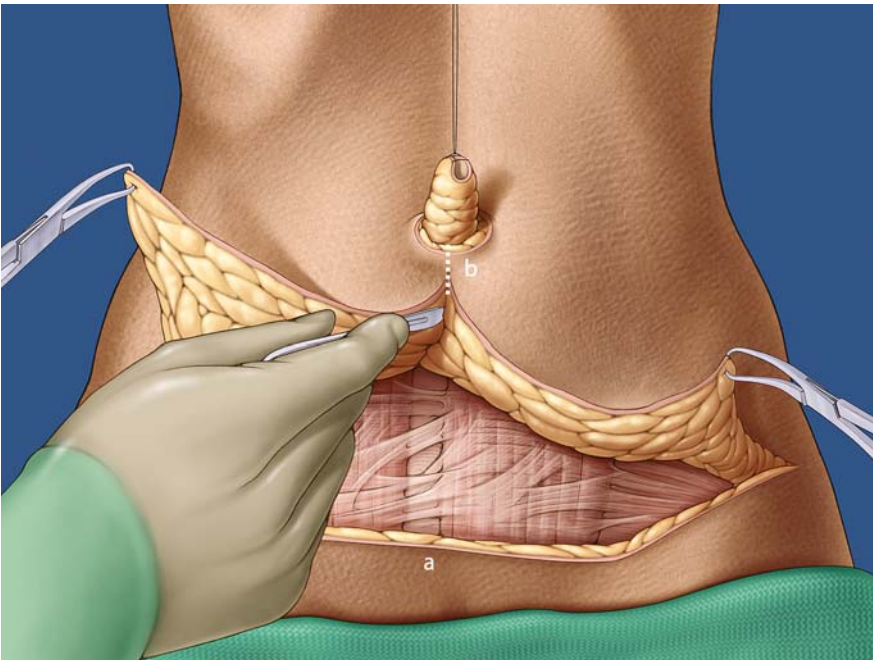
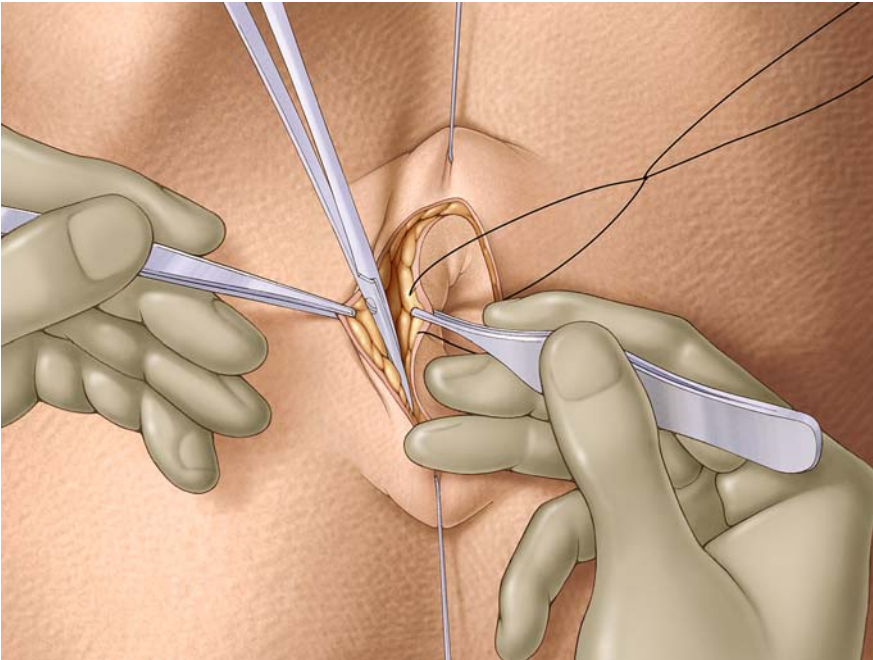
Bleeding should be stopped carefully with the bipolar tweezers.

---

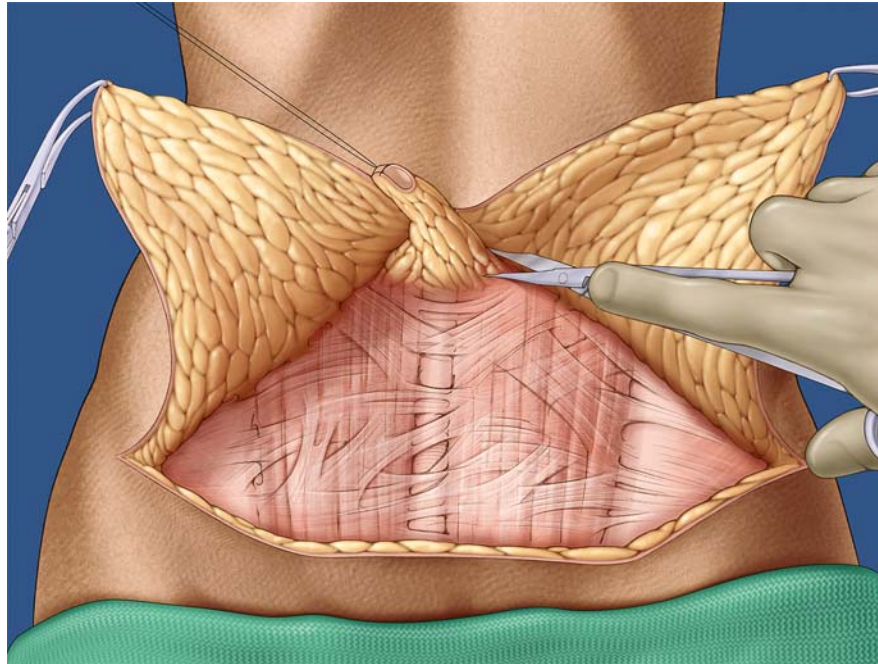
### Vertical Splitting of the Dermofat Flap as Far as the Base of the Navel

- To facilitate further cranial dissection, the dermofat flap is incised longitudinally in the median line from the edge of the wound to the navel. The assistant pulls the edges of the wound upwards with two Backhaus clamps. A large wound retractor can also be used for obese patients.
- The length of the median line between the two points a and b is precisely such that later, after resection of the skin, the edges of the wound meet section by section without a vertical incision being necessary. In relation to this, point a, the border of the incision edge, varies depending on the surplus skin, i.e., the more surplus skin that is present, the deeper point a is located. If there is less surplus skin, this point (a) must be correspondingly higher so that later there will be only a horizontal scar.





a: Lower border of the incision edge  
b: Lower boundary of the navel

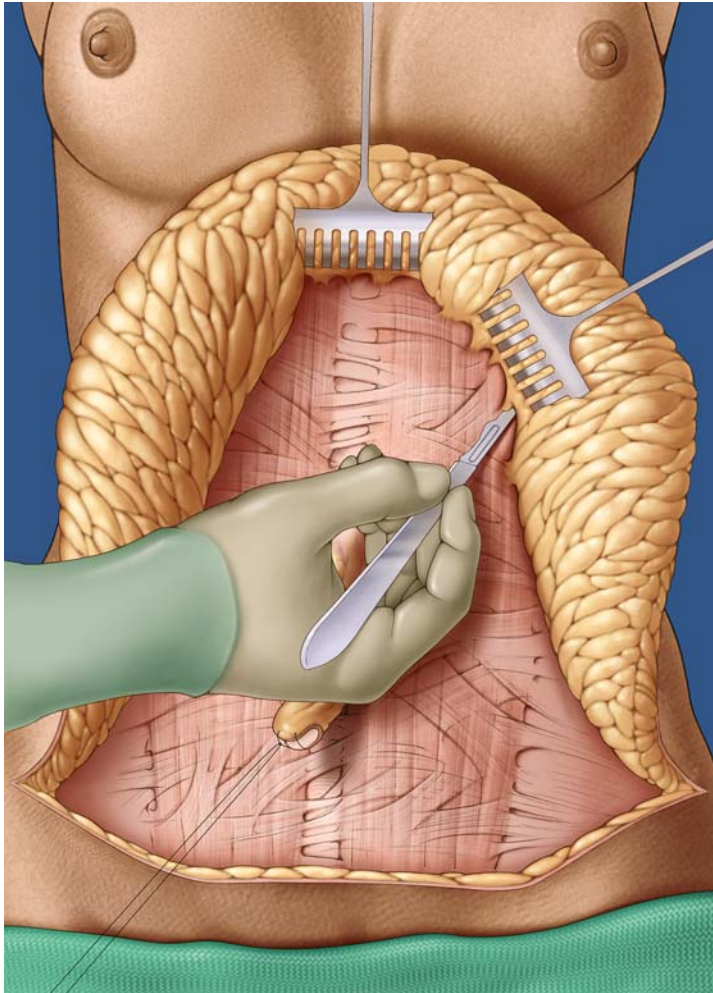


#### **Complete Mobilization of the Umbilical Stalk**

- By vertically dividing the dermofat flap, it is easy to dissect the umbilical stalk cleanly and with a broad base while it is in view. The supplying vessels must be retained at the base. If an umbilical hernia or hernias of the abdominal wall have been diagnosed before the operation, these should be treated appropriately during the operation. The wound surfaces and the navel should be covered during the procedure with moist, warm compresses.

#### **Dissection of the Upper Abdomen**

- Following mobilization of the cutaneous/fatty flap, dissection is continued in a lateral direction as far as the xiphoid process and the costal arch (forming the waist).
- The lateral dissection can be performed deeply and bluntly. To do this, a moist compress should be wrapped around the right middle and index fingers and the entire lateral section, from the lateral costal arch to the iliac crest, can thus be pushed away bluntly.



- The assistant must ensure immediate hemostasis at all times by using the bipolar or monopolar tweezers. Depending on the surgeon's preference, sharp dissection can be done with the size 10 scalpel blade or with large dissection scissors.

It may be useful to use an illuminated retractor in the vicinity of the xiphoid process and at the base of the ribs. There is an increased possibility of bleeding with dissection of the xiphoid process in the area of the costal arch using a sharp instrument. The bleeding must be controlled by immediate and rapid coagulation or purse-string suturing.

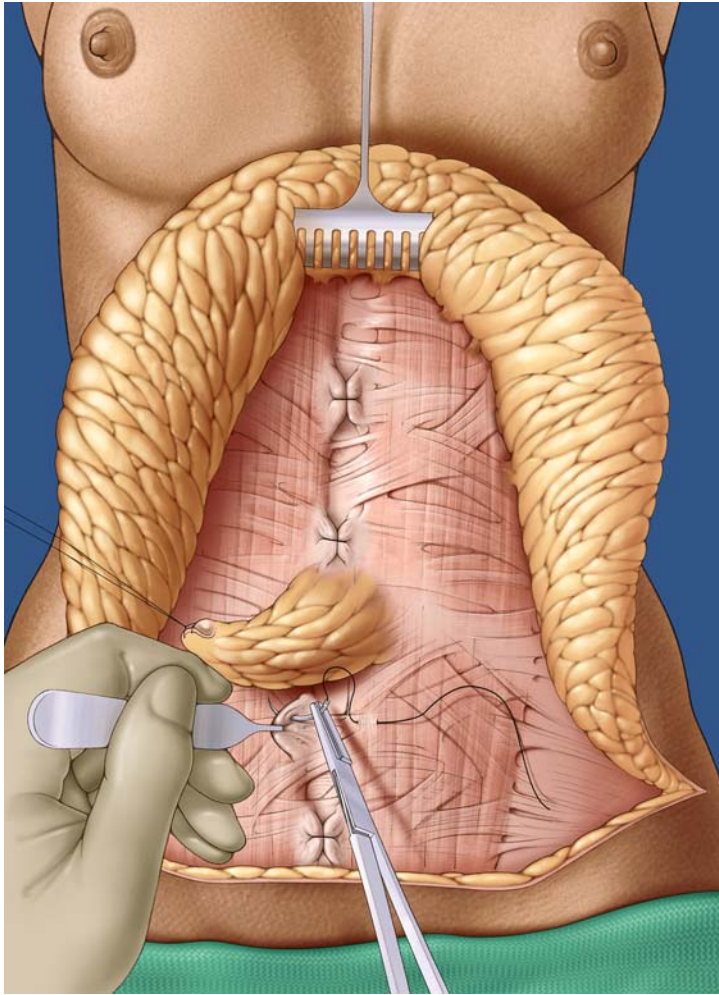


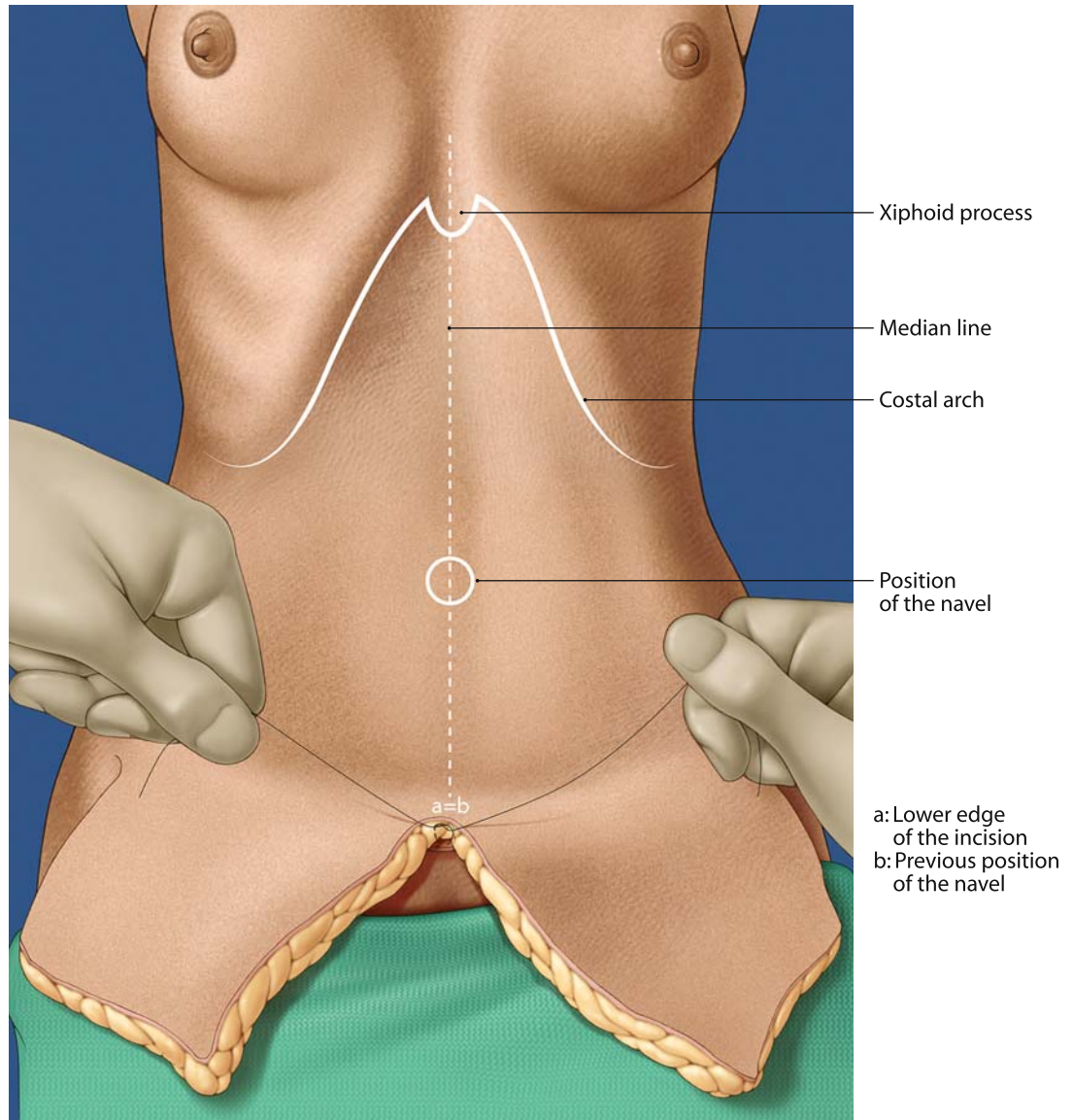
---

### **Doubling of the Rectus Abdominis Fascia**

In patients who have lost a lot of weight after being severely overweight, there is sometimes overstretching of the abdominal muscles so that these move away from one another in the center. In extreme cases, a midline hernia occurs. Appropriate surgical treatment should then be carried out for these.

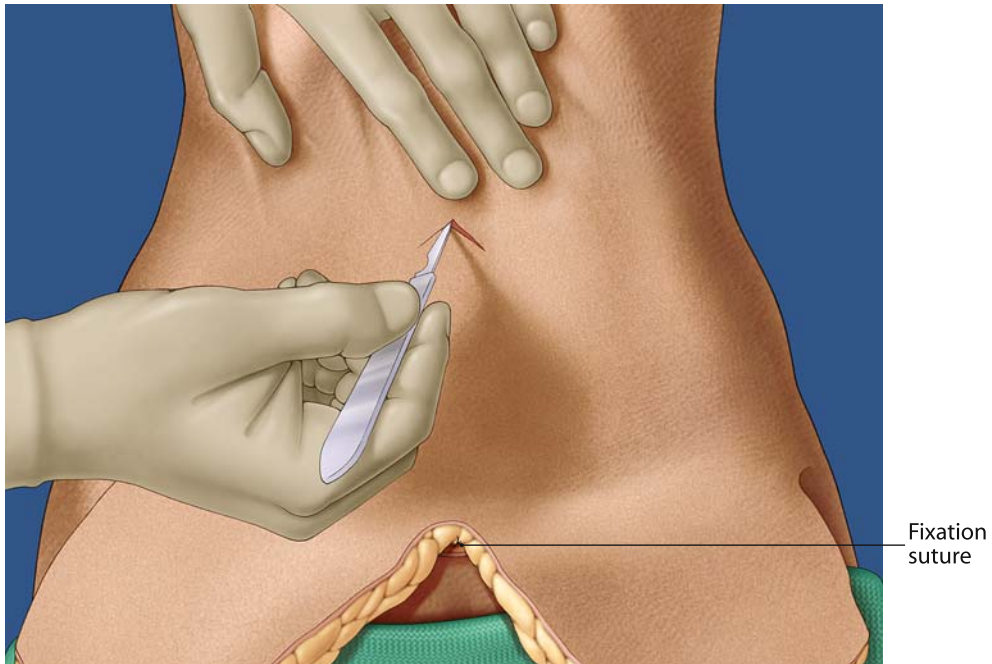
- In order to achieve a good result for the tightening of the abdominal wall, doubling of the fascia longitudinally is routinely carried out with o Vicryl sutures (interrupted mattress sutures) and, depending on the findings, doubling obliquely. This doubling of the fascia must be based on the individual findings. This allows a good base to be created for the later skin/fat tightening.
- For body contouring, suction can also be carried out in the area of the hips during the operation via the open abdominal wall. There are many variations in aesthetic/plastic surgery for optimizing the result. However, a basic requirement is good basic knowledge and mastery of standard operations.





### Defining the Resection Boundaries with Upper Body Flexed at 30°

- Following prior precise wound revision and hemostasis, the entire cutaneous/fatty flap is pulled down under traction with the upper body flexed (30°) to define the boundaries for later resection. In an ideal case, point b will meet point a. This ensures that a vertical excision will not be necessary and therefore no troubling scar will occur. If the abdominal wall is very slack, the distance may be greater. In such cases, it is important that the later scar is formed section by section, without tension and that it is not retracted and there is no surplus skin with a distended overhang.



### Repositioning of the Navel Using a V-shaped Incision

- To ensure the scar is aesthetically pleasing a V-shaped incision is made at the new insertion site of the navel following prior confirmation of the correct position. The easiest method of doing this is for the surgeon to feel the umbilical stalk beneath the dermofat flap with his middle finger, to determine the position by exerting slight pressure in a cranial direction with the middle finger and by marking a point corresponding to the tip of the finger with a marking pen using the other hand.

---

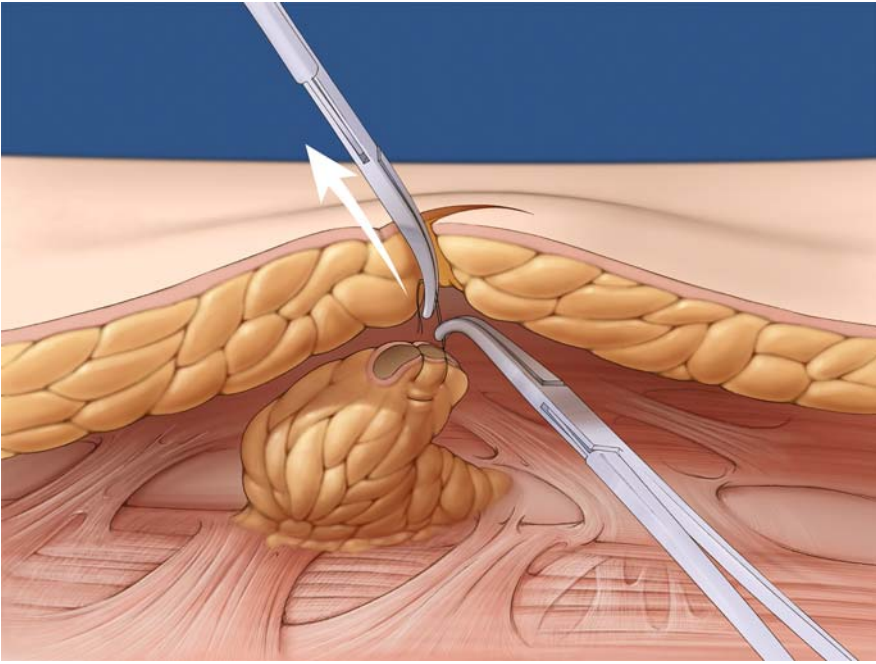
### **Pulling the Navel Out of the V-Shaped Incision with Curved Forceps**

- With the aid of long curved forceps the navel is gripped at the holding sutures and pulled upward.

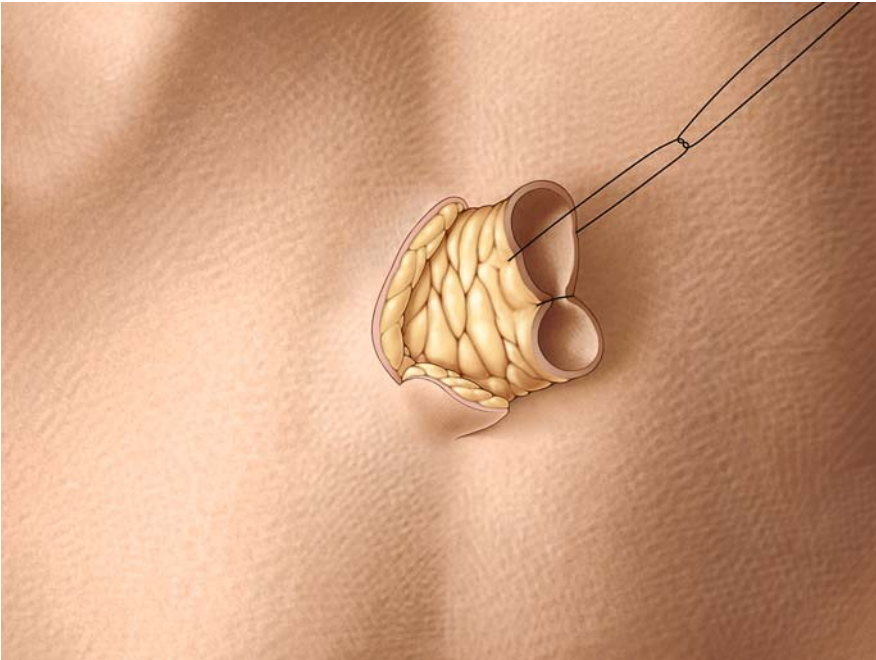---

### **Positioning the Navel**

- The navel is positioned outwardly and fits into the correct position in the external cutaneous incision without tension.



Abdominoplasty





---

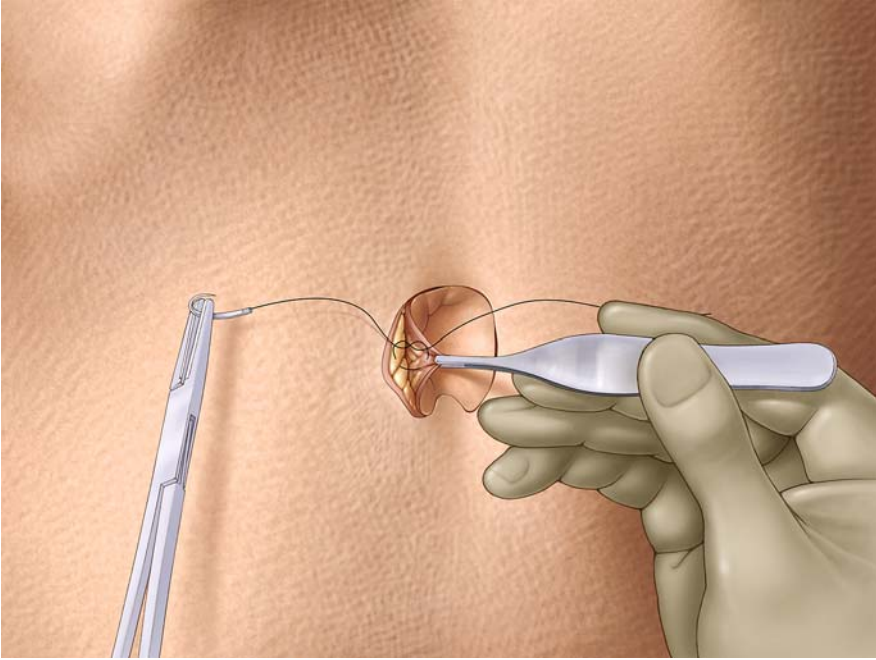
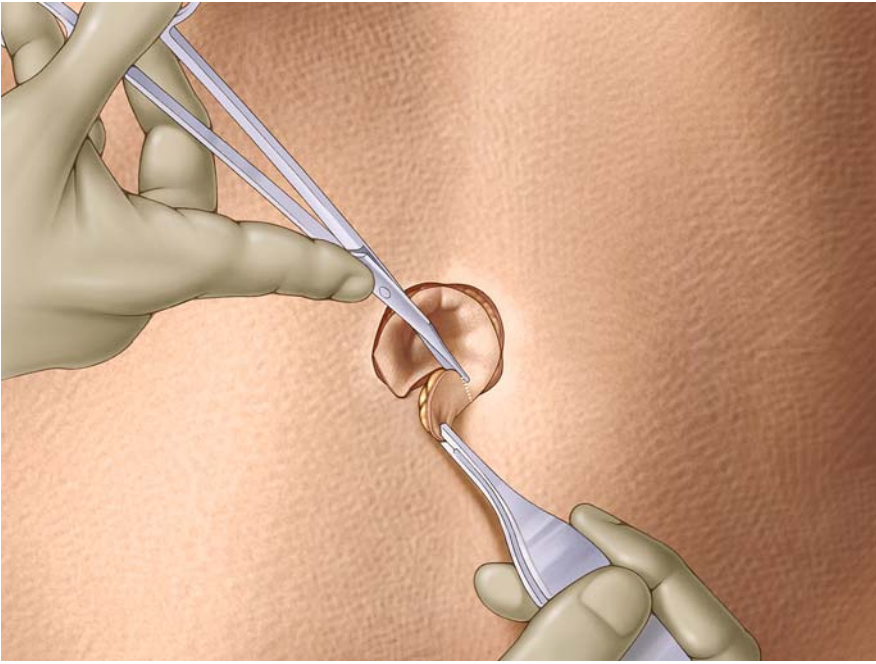
### Trimming of the Skin of the Navel and Adaptation to the V-shaped Incision

- To interrupt a circular navel scar line the lower third of the navel is removed to correspond with the V-shaped incision in the abdominal wall. This simple and effective method of reconstruction of the navel prevents disturbances to wound healing, necrosis of the navel, and cosmetically unpleasant changes in the area of the navel. The navel thus has a natural appearance.

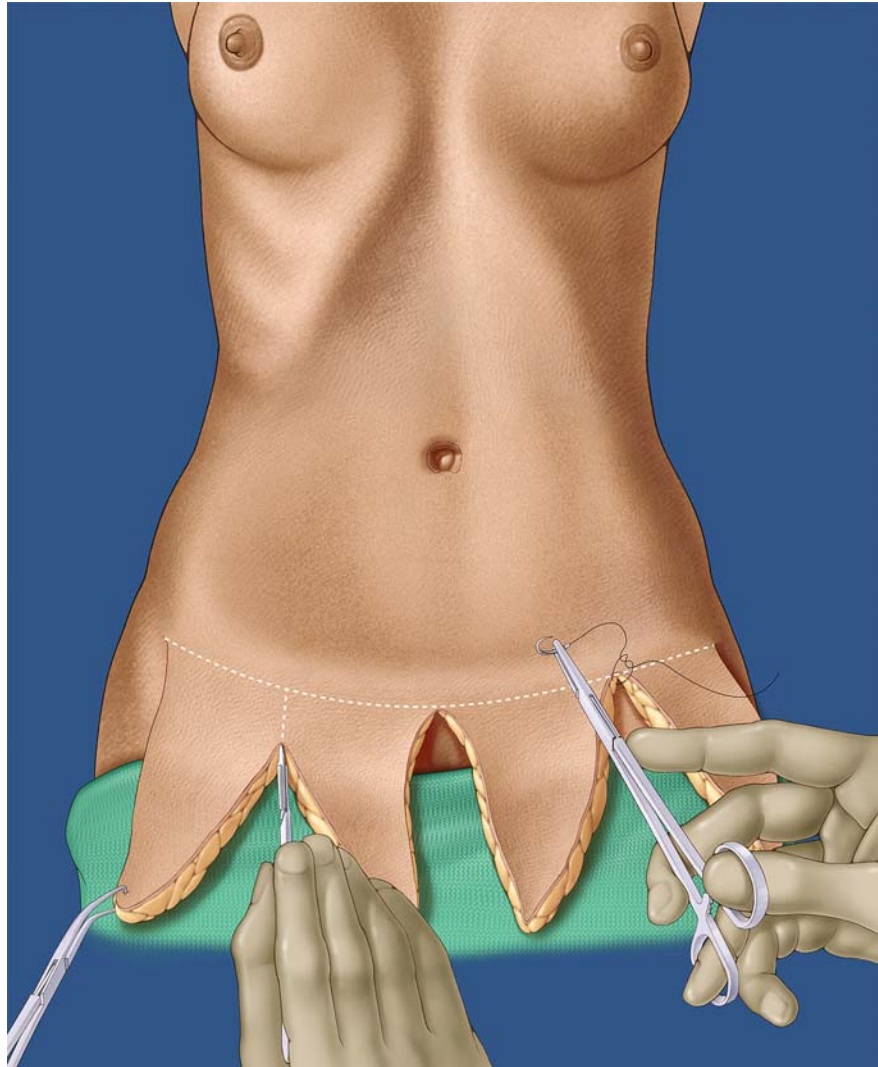
---

### Closure of the Navel in Three Layers

- In order to avoid later disturbances to healing and necrosis, the navel must be fixed in place in three layers. At the base, this is with deep fixation with absorbable suture material of strength 3.0. To allow further perfusion and stabilization of the navel using the peri-umbilical adipose tissue, 5.0 Monocryl interrupted sutures are then inserted. The skin is adapted with continuous intracutaneous suturing with 4.0 Monocryl. This ensures that the navel is well stabilized, has contact with the dermo-fat flap on all sides and that no serous swellings can form in spaces.

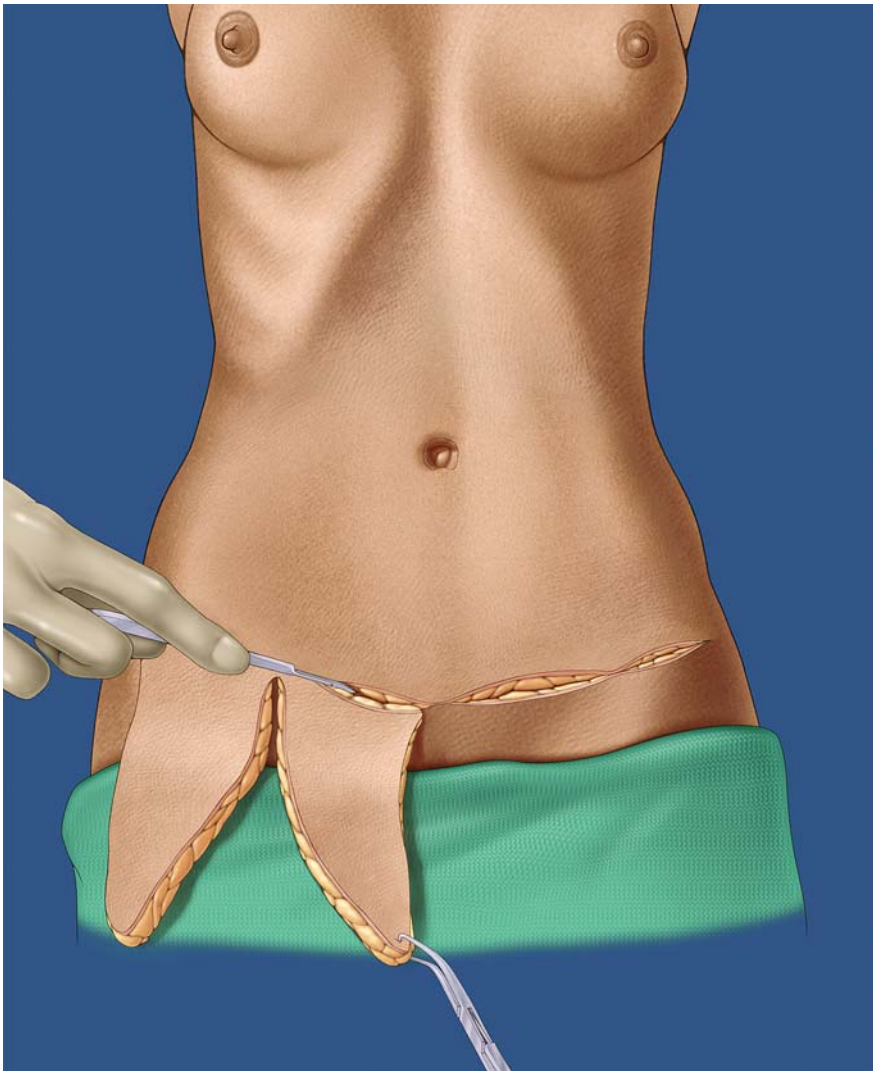






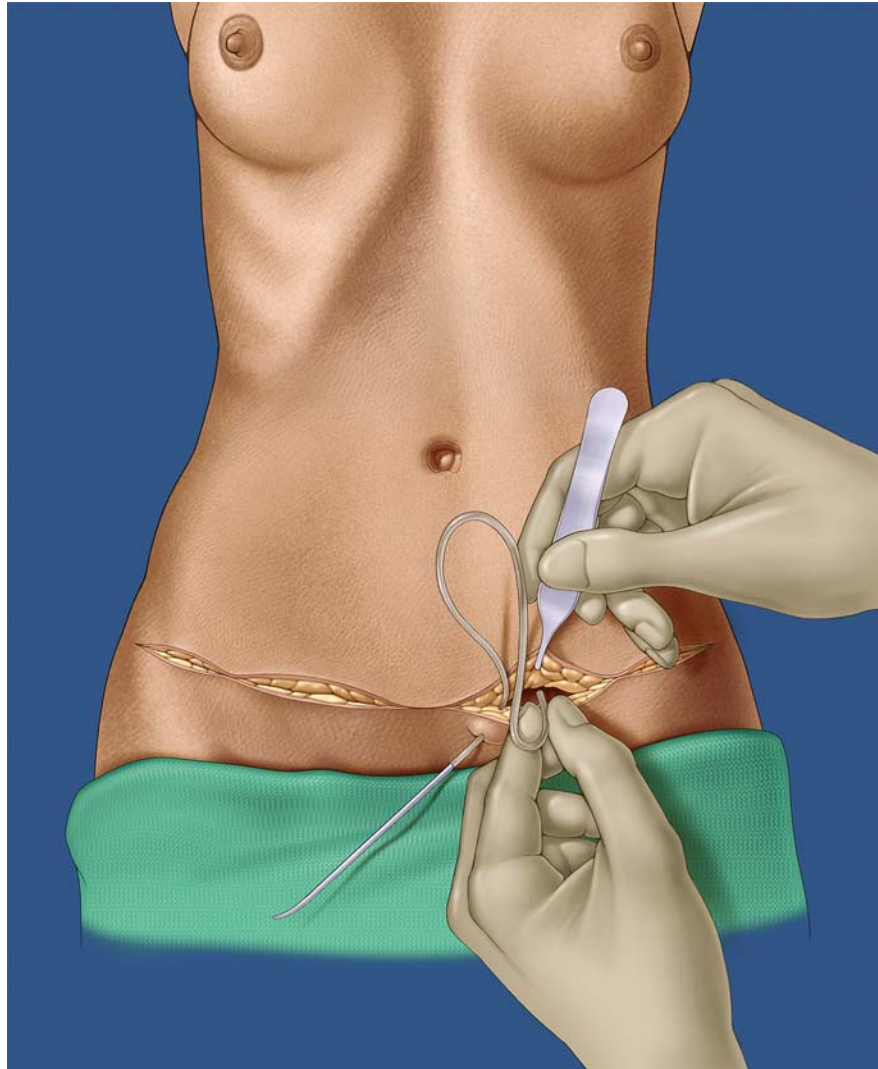
#### Fixation of the Surplus Sections of Skin with 2.0 Monocryl Key Sutures

- The surplus skin is pulled down under slight traction to define the resection boundaries. 2.0 Monocryl key sutures are placed at equal intervals, and this allows the surgeon to identify as early as this stage of the operation how far the resection must be taken laterally if “dog-ears” are to be avoided. The incision can be extended in a lateral direction at this stage of the operation, depending on this. The trick for all tightening operations is that the amount of skin that must be removed can be defined exactly prior to resection by positioning key sutures. This ensures that the later result will be good and the scar pleasing.
- The individual key sutures are placed one after the other so that individual corrections can be made at any time.



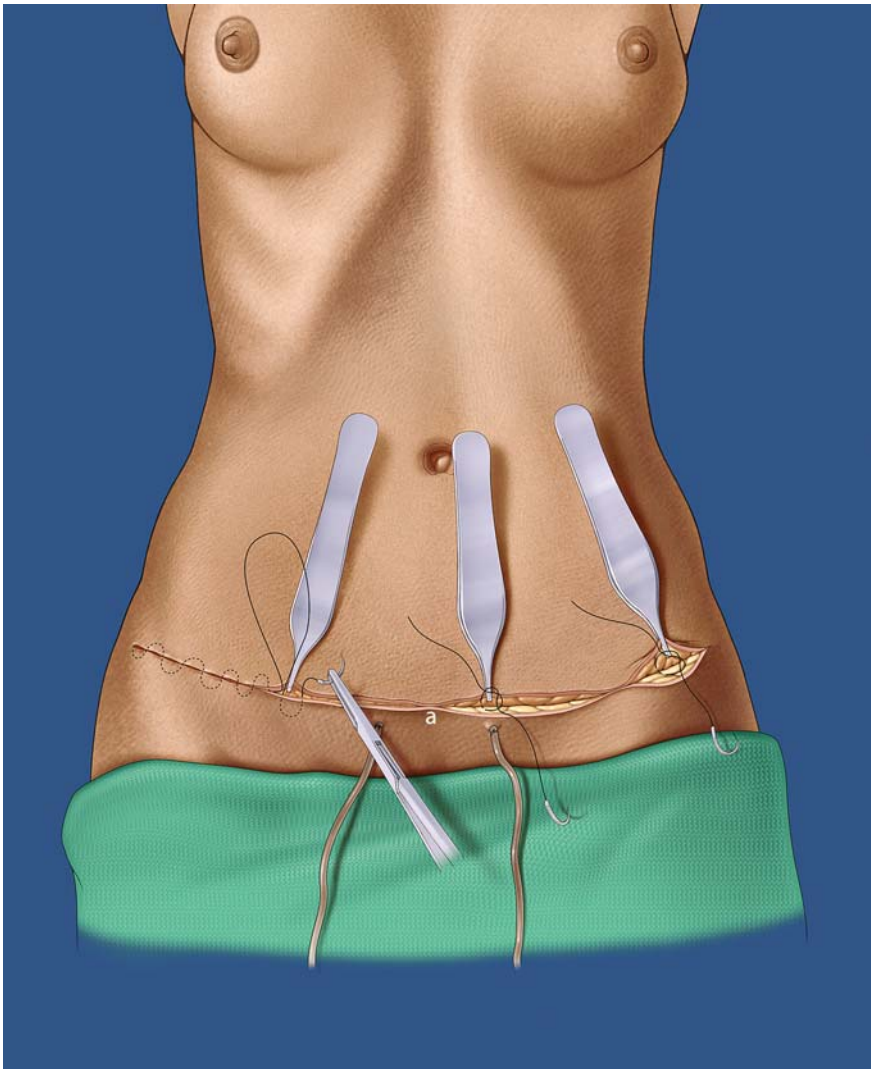
#### ○ Resection of the Skin in Stages

- Resection of the skin is performed with regular checks on the tension of the remaining skin. The skin/fat resection should be performed at an angle of  $70^\circ$  so that the lower border of the incision of  $30^\circ$  meets the upper border of the incision section by section with no retraction or bulging.
- After the resection has been completed, particles of fat and surplus skin that spoil the result should be removed. The lateral edges of the incision should also be checked and any “dog-ears” must be evened out.



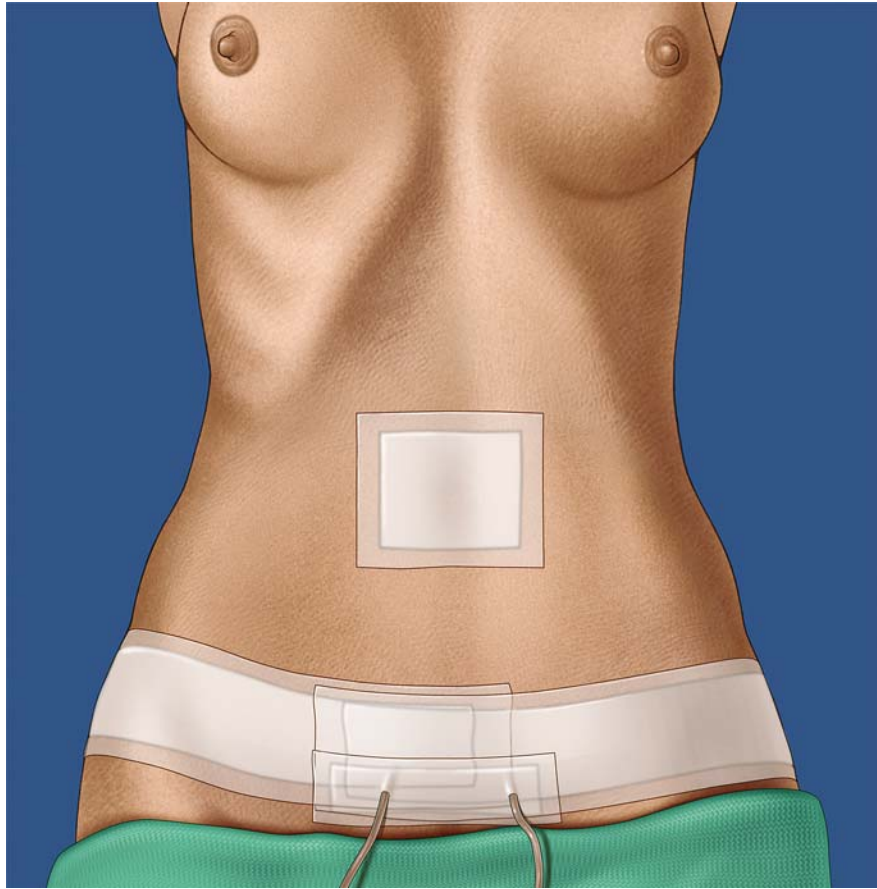
#### Insertion of Redon Drains

- Two size-12 Redon drains leading out onto the shaved mons pubis are inserted into two sections of the lower abdomen before the skin is closed. The Redon drains are removed after the second postoperative day and the catheter is removed after 24 h.



#### ◉ **Wound Closure in Three Layers**

- Skin closure is carried out layer by layer, first with concealed 2.0 Monocryl interrupted sutures, then with concealed 3.0 Monocryl subcutaneous interrupted sutures. Finally, the wound is closed with running 4.0 Monocryl sutures. For this, it is important that suturing begins at the lateral ends on both sides so that the two sutures meet at point a. This prevents the skin being uneven in the lateral area and produces the desired traction in a medial direction.



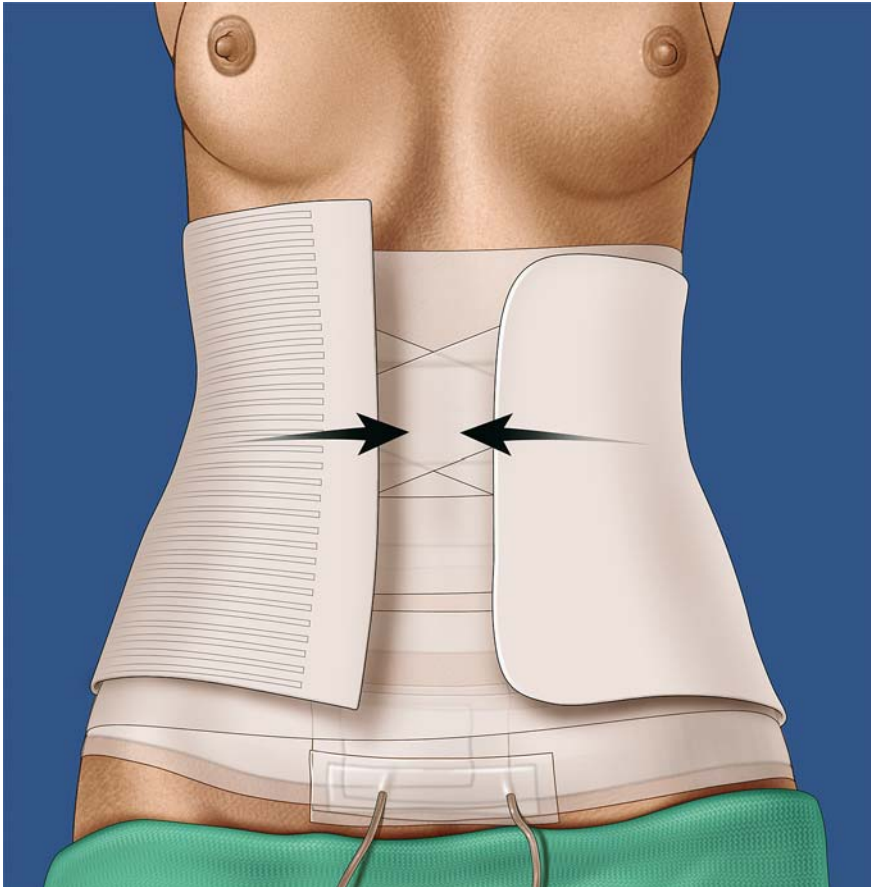
● **Dressing**

- The navel is packed with a fine gauze soaked in betadine (Beta-isadona) ointment and covered with Cutiplast. The other incisions are closed with adhesive Steri-Strip dressings. These dressings can be removed after 8 days when the wound is checked. The Tensoplast adhesive dressing remains in place until the Redon drains are removed. A special compression girdle is then fitted that should be worn for 6 weeks. The fresh scars are treated with dexapanthenol ointment for 14 days after the operation, then with silicone ointment or silicone plasters for 2 months.

**Fitting the Abdominal Belt**

- In addition to a Tensoplast bandage, an abdominal belt is also used until the Redon drains are removed. This ensures good compression on the detached wound surfaces, which prevents serous swellings and bleeding. During this time, the patient should have bed rest in a slightly angled supine position with the upper body raised.





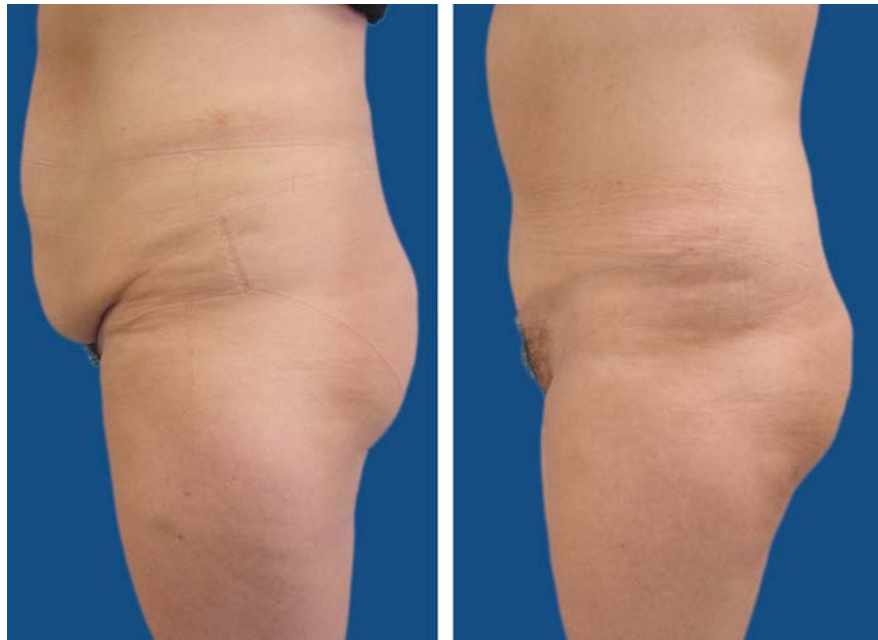- The abdominal belt should be fitted with traction. It should be loosened if the patient has difficulty breathing. Thrombosis and infection prophylaxis must be carried out during the patient's stay in the hospital.

**Note:**

For safe dissection of the navel, it is important to ensure that the tissue is fully supplied with blood. However, if too much adipose tissue is left, this may cause elevated pressure on the repositioned navel. In addition, the 'steal phenomenon' may result, since the adipose tissue left behind may require part of the blood supply. Compression of the abdominal wall using the abdominal bandage should not be too severe, as this may cause necroses of the distal end of the flap ("most poorly perfused area").

The distal end of the wound must **never** be undermined!

Deep fixation of the navel requires precise localisation of the navel opening. A two-layer wound closure may be used if desired.



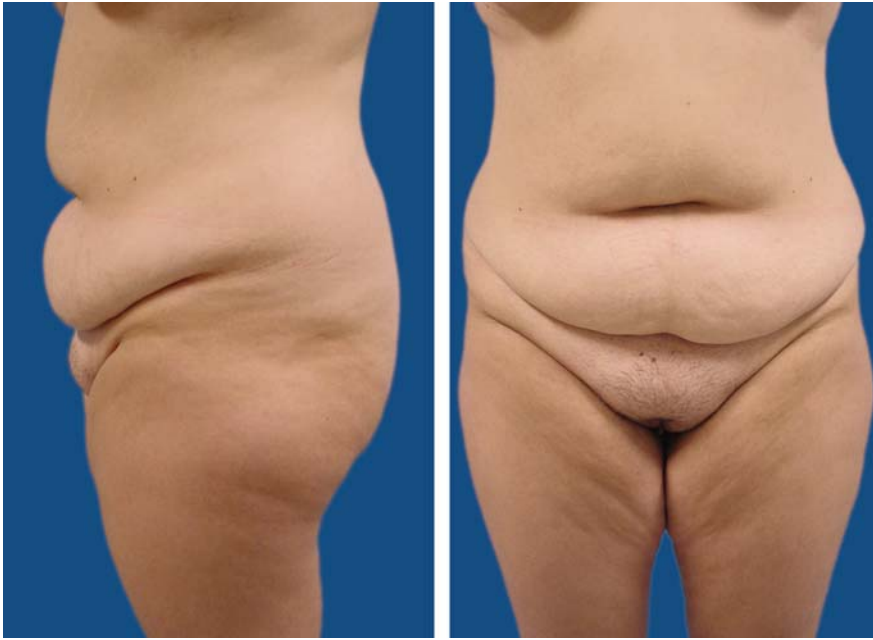Preoperative

Postoperative

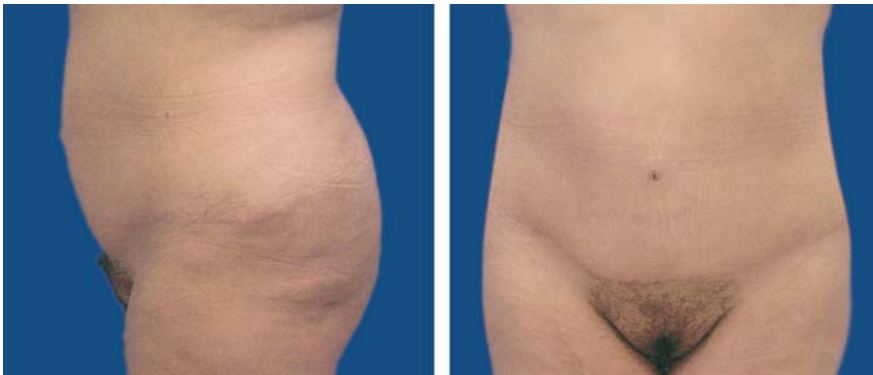### Results

Patient I: This is a 46-year-old female patient after three pregnancies with divarification of the recti and fat flap. Doubling of the fascia was carried out in addition to the skin/fat resection and repositioning of the navel.

Twelve months after the operation. Normal wound healing, good contouring of the abdomen and hips.



Preoperative



Postoperative

Patient II: This is a 49-year-old female patient following substantial weight loss (40 kg).

Twelve months after the operation. Healthy scar.

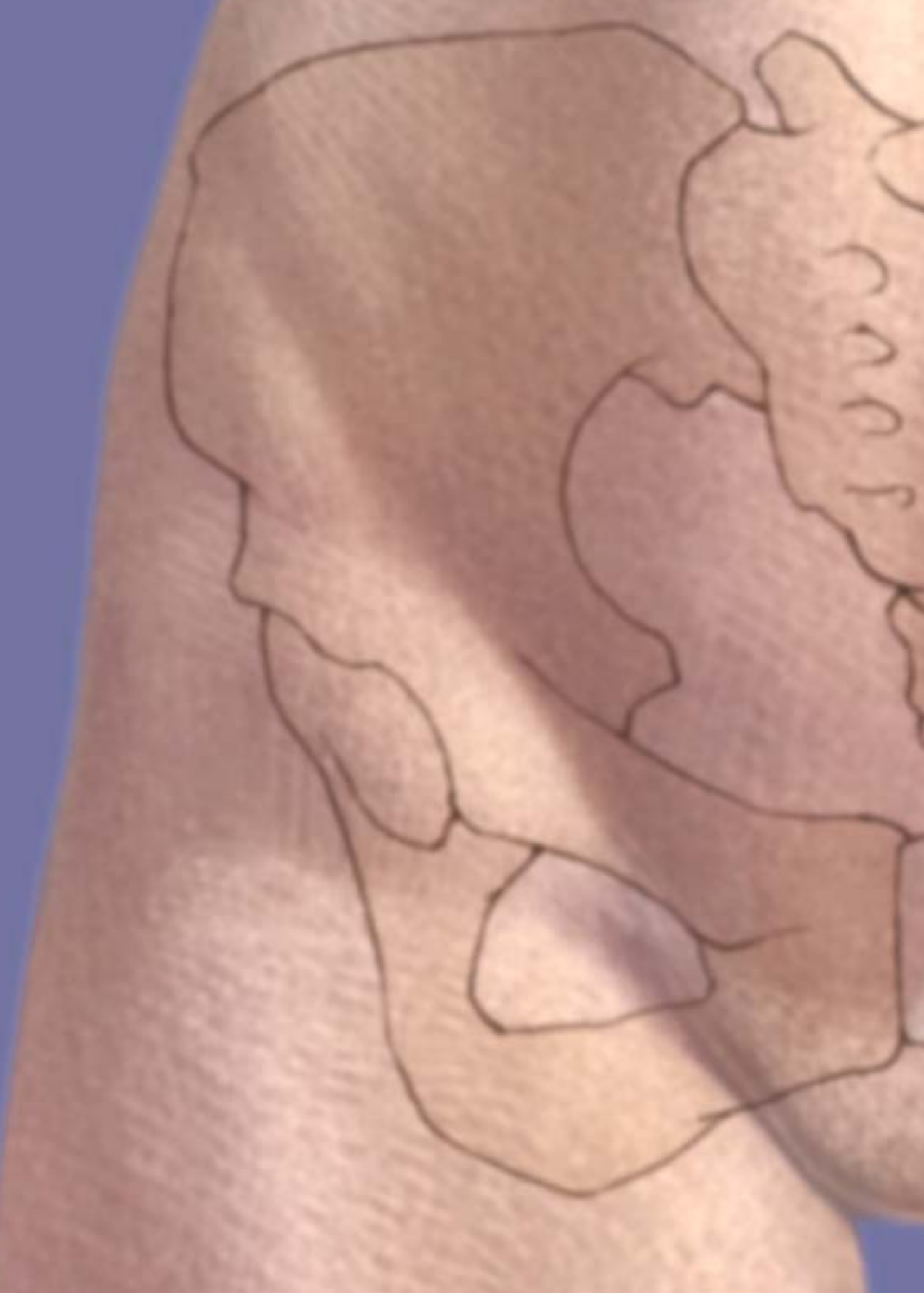


---

## Literature

- Abramson DL (1998) Tumescant abdominoplasty: an ambulatory office procedure. *Aesthetic Plast Surg* 22: 404–407
- Aly AS, Cram AE, Chao M, et al (2003) Belt lipectomy for circumferential truncal excess: the University of Iowa experience. *Plast Reconstr Surg* 111: 398–413
- Bang RL, Behbehani AI (1997) Repair of large, multiple, and recurrent ventral hernias: an analysis of 124 cases. *Eur J Surg* 163:107–114
- Bukowski TP, Smith CA (2000) Monfort abdominoplasty with neoumbilical modification. *J Urol* 164:1711–1713
- Byun MY, Fine NA, Lee JY, et al (1999) The clinical outcome of abdominoplasty performed under conscious sedation: increased use of fentanyl correlated with longer stay in outpatient unit. *Plast Reconstr Surg* 103:1260–1266
- Cao H, Zheng Z, Song W (2000) Abdominoplasty with a combined technique of lipectomy and liposuction (in Chinese). *Zhonghua Zheng Xing Wai Ke Za Zhi* 16:348–350
- Cardenas-Camarena L, Gonzalez LE (1998) Large-volume liposuction and extensive abdominoplasty: a feasible alternative for improving body shape. *Plast Reconstr Surg* 102:1698–1707
- Carwell GR, Horton C E Sr (1997) Circumferential torsoplasty. *Ann Plast Surg* 38:213–216
- Cho BC, Lee J H, Ramasastry SS, et al (1997) Free latissimus dorsi muscle transfer using an endoscopic technique. *Ann Plast Surg* 38:586–593
- Felmerer G, Muehlberger T, Berens von Rautenfeld D, et al (2002) The lymphatic system of the deep inferior epigastric artery perforator flap: an anatomical study. *Br J Plast Surg* 55:335–339
- Fenn CH, Butler PE (2001) Abdominoplasty wound-healing complications: assisted closure using foam suction dressing. *Br J Plast Surg* 54:348–351
- Flageul G, Elbaz JS, Karcenty B (1999) Complications of plastic surgery of the abdomen. *Ann Chir Plast Esthet* 44:497–505
- Franco T, Franco D (1999) Neomphaloplasty: an old and new technique. *Aesthetic Plast Surg* 23:151–154
- Furness PD 3rd, Cheng EY, Franco I, et al (1998) The prune-belly syndrome: a new and simplified technique of abdominal wall reconstruction. *J Urol* 160:1195–1197; discussion 1216
- Germain MA, Barreau-Pouhaer L, Missana MC (1997) Breast reconstruction using free rectus abdominis myocutaneous flap (in German). *Chirurgie* 122:364–368
- Germain MA, Barreau-Pouhaer L, Missana MC, et al (1997) Rectus abdominis myocutaneous flaps (in German). *Chirurgie* 122:360–362
- Grolleau JL, Lavigne B, Chavoin JP, et al (1998) A predetermined design for easier aesthetic abdominoplasty. *Plast Reconstr Surg* 101:215–221
- Hage JJ, Karim RB (1998) Abdominoplastic secondary full-thickness skin graft vaginoplasty for male-to-female transsexuals. *Plast Reconstr Surg* 101:1512–1515
- Heddens CJ (2001) Belt lipectomy: procedure and outcomes. *Plast Surg Nurs* 21:185–189, 199; quiz 191
- Honig JF, Hecker JW (1998) Indications and technique of the M-U abdominal incision and initial clinical results of modified abdominoplasty (in German). *Zentralbl Gynakol* 120:262–268
- Illouz YG (1999) Liposuction of the abdomen. *Ann Chir Plast Esthet* 44:481–495
- Karnes J, Salisbury M, Schaeferle M, et al (2002) Hip lift. *Aesthetic Plast Surg* 26:126–129
- Kurul S, Uzunismail A (1997) A simple technique to determine the future location of the umbilicus in abdominoplasty. *Plast Reconstr Surg* 100:753–754

- 
- Lampe H, Wolters M (2001) Possibilities and limits of ambulatory surgery: demands and reality in plastic surgery (in German). *Kongressbd Dtsch Ges Chir Kongr* 118:642–646
- Le Louarn C, Pascal JF (2000) High superior tension abdominoplasty. *Aesthetic Plast Surg* 24:375–381
- Lee MJ, Mustoe TA (2002) Simplified technique for creating a youthful umbilicus in abdominoplasty. *Plast Reconstr Surg* 109:2136–2140
- Mang WL (1980) *Techniken und Methoden der modernen Medizin*. Steinkopff Verlag
- Mang WL (1996) *Ästhetische Chirurgie Bd. II*. Einhorn Presse Verlag
- Massiha H, Montegut W, Phillips R (1997) A method of reconstructing a natural-looking umbilicus in abdominoplasty. *Ann Plast Surg* 38:228–231
- Massiha H (2002) Superior positioning of the ptotic umbilicus in abdominoplasties and TRAM flaps. *Ann Plast Surg* 48:508–510
- Micheau P, Grolleau JL (1999) Incisional hernia. Patient management. Approach to the future operated patients (in French). *Ann Chir Plast Esthet* 44:325–338
- Nguyen TT, Kim KA, Young RB (1997) Tumescent mini abdominoplasty. *Ann Plast Surg* 38:209–212
- Ohana J, Karcenty B, Mekouar R, et al (1999) “Modern” combined abdominoplasty (in French). *Ann Chir Plast Esthet* 44:463–479
- Park MC, Lee JH, Chung J, et al (2003) Use of internal mammary vessel perforator as a recipient vessel for free TRAM breast reconstruction. *Ann Plast Surg* 50:132–137
- Pollock H, Pollock T (2000) Progressive tension sutures: a technique to reduce local complications in abdominoplasty. *Plast Reconstr Surg* 105:2583–2586; discussion 2587–2588
- Pravecek EJ, Worland RG (1998) Tumescent abdominoplasty: full abdominoplasty under local anesthesia with i.v. sedation in an ambulatory surgical facility. *Plast Surg Nurs* 18:38–43
- Schoeller T, Wechselberger G, Otto A, et al (1998) New technique for scarless umbilical reinsertion in abdominoplasty procedures. *Plast Reconstr Surg* 102:1720–1723
- Schoeller T, Bauer T, Gurunluoglu R, et al (2003) Modified free paraumbilical perforator flap: the next logical step in breast reconstruction. *Plast Reconstr Surg* 111:1093–1098
- Sensoz O, Arifoglu K, Kocer U, et al (1997) A new approach for the treatment of recurrent large abdominal hernias: the overlap flap. *Plast Reconstr Surg* 99:2074–2078
- Shestak KC (2000) Progressive tension sutures: a technique to reduce local complications in abdominoplasty. *Plast Reconstr Surg* 105:2587–2588
- Zukowski ML, Ash K, Spencer D, et al (1998) Endoscopic intracorporeal abdominoplasty: a review of 85 cases. *Plast Reconstr Surg* 102:516–527



---

## Thigh and Buttock Lift

- Introduction 122
- Anatomical Overview 124, 125
- Instruments 126
- Duplicate Patient Information 130
- Preliminary Examinations 130
- Photographic Documentation 130
- ■ Surgical Planning 131
  - Positioning, Disinfection 132
- ■ Tumescence 132
  - Incision of the Skin 134
- ■ Preparation 134
  - Deep Dissection and Hemostasis 136
  - Definition of Resection Boundaries 136
  - Skin Resection 138
  - Fixation Suture on the Pubic Bone with 2.0 Monocryl 138
  - Second Fixation Suture on the Inguinal Ligament 140
- ■ Deep Wound Closure and Insertion of a Redon Drain (no. 10) 140
  - Intracutaneous Skin Closure 142
- ■ Dressing 142
  - Buttock Lift: Positioning, Disinfection 144
- ■ Incision Line 144
- ■ Incision 144
- ■ Wedge-Shaped Dermolipectomy 146
  - Transverse Incision Through the Resected Area 148
- ■ Hemostasis, Deep Wound Closure, Insertion of a Redon Drain 148
- ■ Two-Layer, Tension-Free Wound Closure 150
- ■ Dressing 150
  - Postoperative Treatment: Course of Action After the Operation; Precautionary Measures 152
- Results 152
- Literature to Buttock Lift 154
- Literature to Thigh Lift 155

---

## Introduction

This is a delicate and often unsatisfactory area of aesthetic surgery. The operation is requested by women over 50, and usually the patients expect too much. In horizontal and inguinal tightening of the thigh, the traction component is often so high that it later results in an unsightly scar, and after only a few months the inner side of the thigh develops creases. In the case of skin that has significant cellulite and slackness of the thighs as far as the knee area, it may be possible to carry out tightening in a vertical direction in a similar way to upper arm tightening, and this can be discussed with the patient. It should be made clear to the patient, however, that this may produce an unsightly scar.

The technique in an inner thigh lift is similar to that used with the upper arm, namely, a deep, subcutaneous dissection on the fascia and a step-by-step skin resection that has previously been drawn precisely. The crucial point when it comes to horizontal, inguinal thigh lifts is the strong traction forces. It is important in this operation that the thigh flaps are “hung” at two points in order to reduce the traction forces on the skin. First, this subcutaneous cutaneous/fatty flap is fixed to the periosteum of the pubic bone with a nylon suture. Laterally the inguinal ligament must be visualized. This is where the second anchorage takes place in order to prevent dehiscence and subsequent descent of the scar. Yet despite hanging at these two points, long-term results are often unsatisfactory. Patients should be told this when they are given information about the operation. Nevertheless, the distress of patients is often so great that they are prepared to put up with these disadvantages and therefore often still want the operation.

When tightening the inside of the thigh, after fixing the two anchoring sutures with the upper body slightly flexed, the excess cutaneous/fatty flap is resected without tension and without steps, so that after the operation a tension-free wound in the bikini area is produced, which must be treated appropriately postoperatively using ointments and silicone plasters. For an additional 3 weeks, antibiotic protection must also be given and the patients must wear a specially adapted girdle.

The same applies to the buttock lift. In this operation the problem is the incision line and the visible scar. With a buttock lift, the incision line should not be much beyond the buttock crease, since this scar is very unsightly. Similarly, the resection must be carried out in a wedge shape in the form of an equilateral triangle, so that the deepest point, the so-called zero point of the fascia corresponds exactly to the changed crease

---

and the resulting suture lies in what will be the new buttock fold. Otherwise there is problematic scar formation that is very difficult to correct.

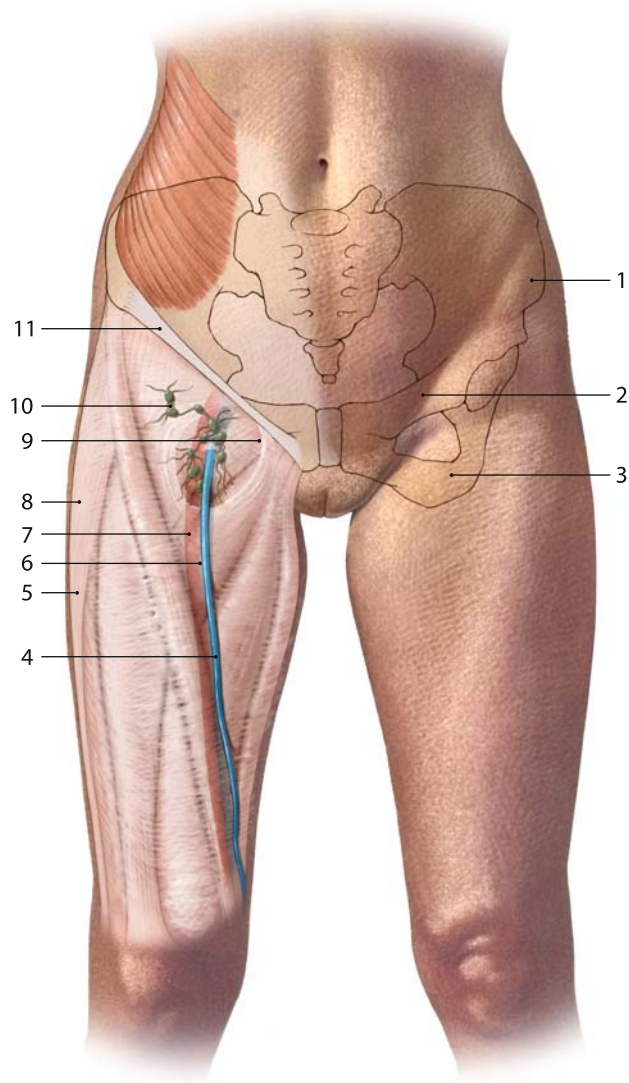
In general, one should not combine liposuction with lifting operations, since this may impair the healing process and increase the risk of thrombosis and embolism.

When the skin is still young and elastic, it is possible to remove smaller limited deposits of fat by means of isolated liposuction. If skin has lost its elasticity through aging or major weight loss, a lifting operation is recommended to achieve cosmetic improvements. Often, the loose skin on the inner side of the thigh is operated on together with the loose skin on the buttock, since this is a cosmetic unit. This operation, which is frequently requested, is also demonstrated in the video.

Generally, the operation is largely without complications. Nevertheless, there may be isolated cases of complications during or after the surgical intervention, despite taking the greatest care. More severe bleeding is stopped immediately during the operation. Pressure damage on nerves and soft tissues resulting from incorrect positioning should be avoided. These injuries recede, however, after a few days in most cases. This also applies to skin damage resulting from disinfectant.

After the operation there may be pain and tension that can sometimes last for a lengthy period. There is also sometimes swelling in the area of the joints, which may last for up to 6 months and can be treated easily by lymph drainage. The risk of thrombosis is extremely rare since blood-thinning measures are used, surgical stockings are worn, and there is early mobilization.

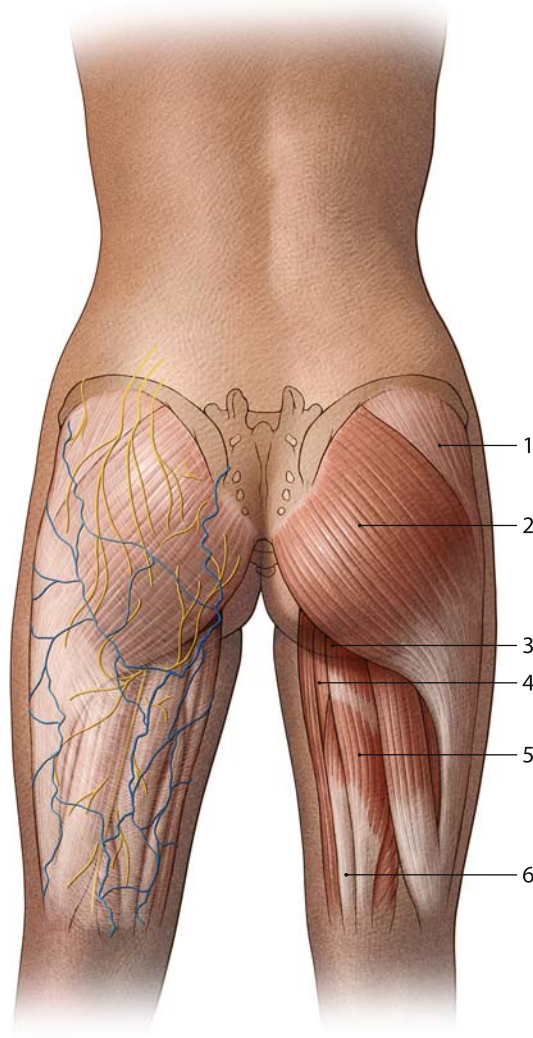
The main complication is permanent scar formation as a result of impaired wound healing. Occasionally, if there is a predisposition to this, thick, bulging, discolored, and painful scars are produced (scar proliferation; hypertrophic scars). With prompt treatment of the scar changes using injections of 40 mg triamcinolone, a corrective operation can be avoided.



### Anatomical Overview

- |                                  |                                      |
|----------------------------------|--------------------------------------|
| 1. Anterior superior iliac spine | 7. Femoral artery                    |
| 2. Pubic bone                    | 8. M. tensor fascia lata             |
| 3. Hip bone                      | 9. Saphenous opening                 |
| 4. Long saphenous vein           | 10. Inguinal superficial lymph nodes |
| 5. Iliotibial tract              | 11. Inguinal ligament                |
| 6. Femoral vein                  |                                      |





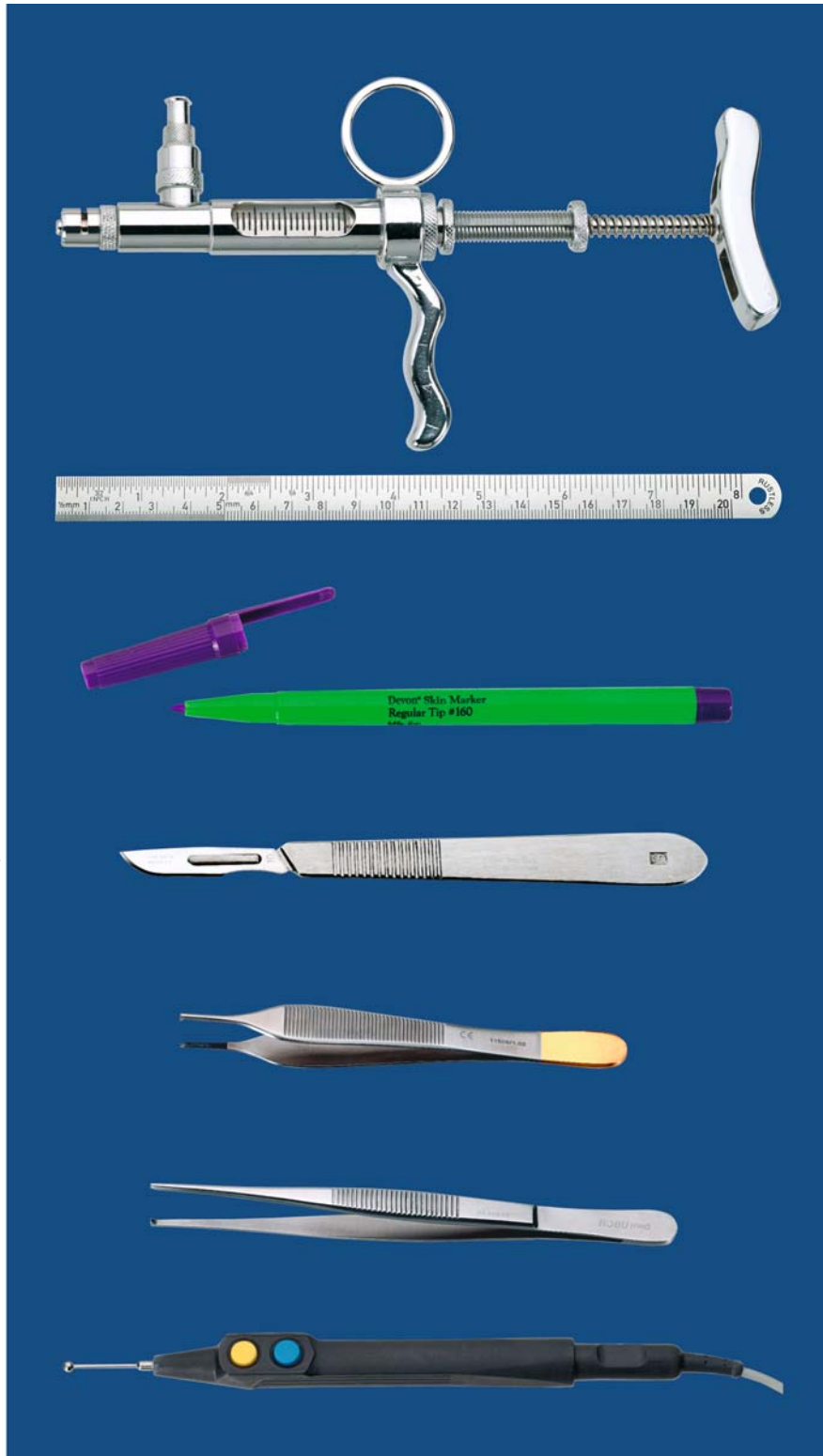**Anatomical Overview**

- 1. Gluteal fascia
- 2. M. gluteus maximus
- 3. Gluteal fold
- 4. M. adductor magnus
- 5. M. biceps femoris
- 6. M. semimembranosus

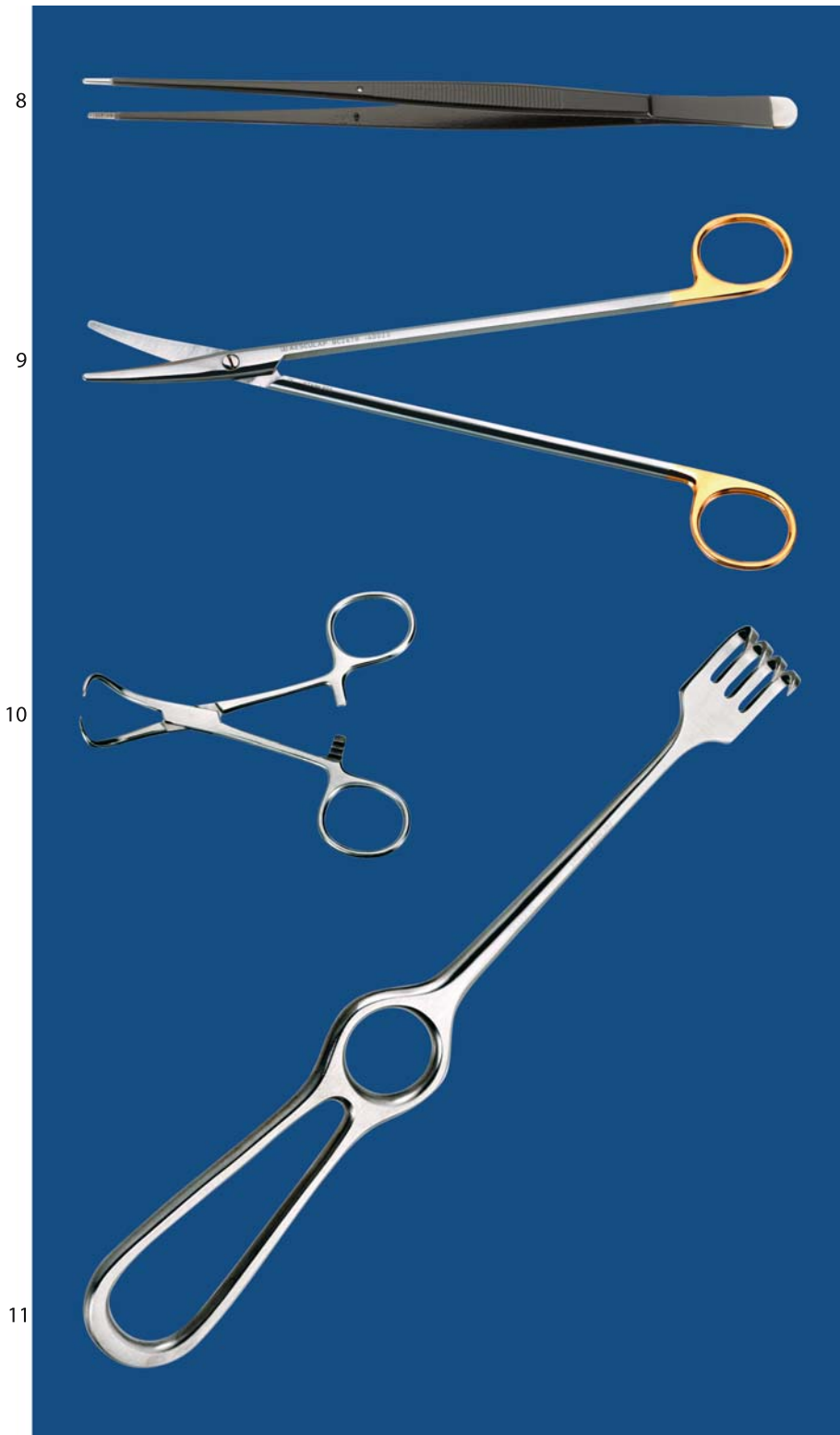


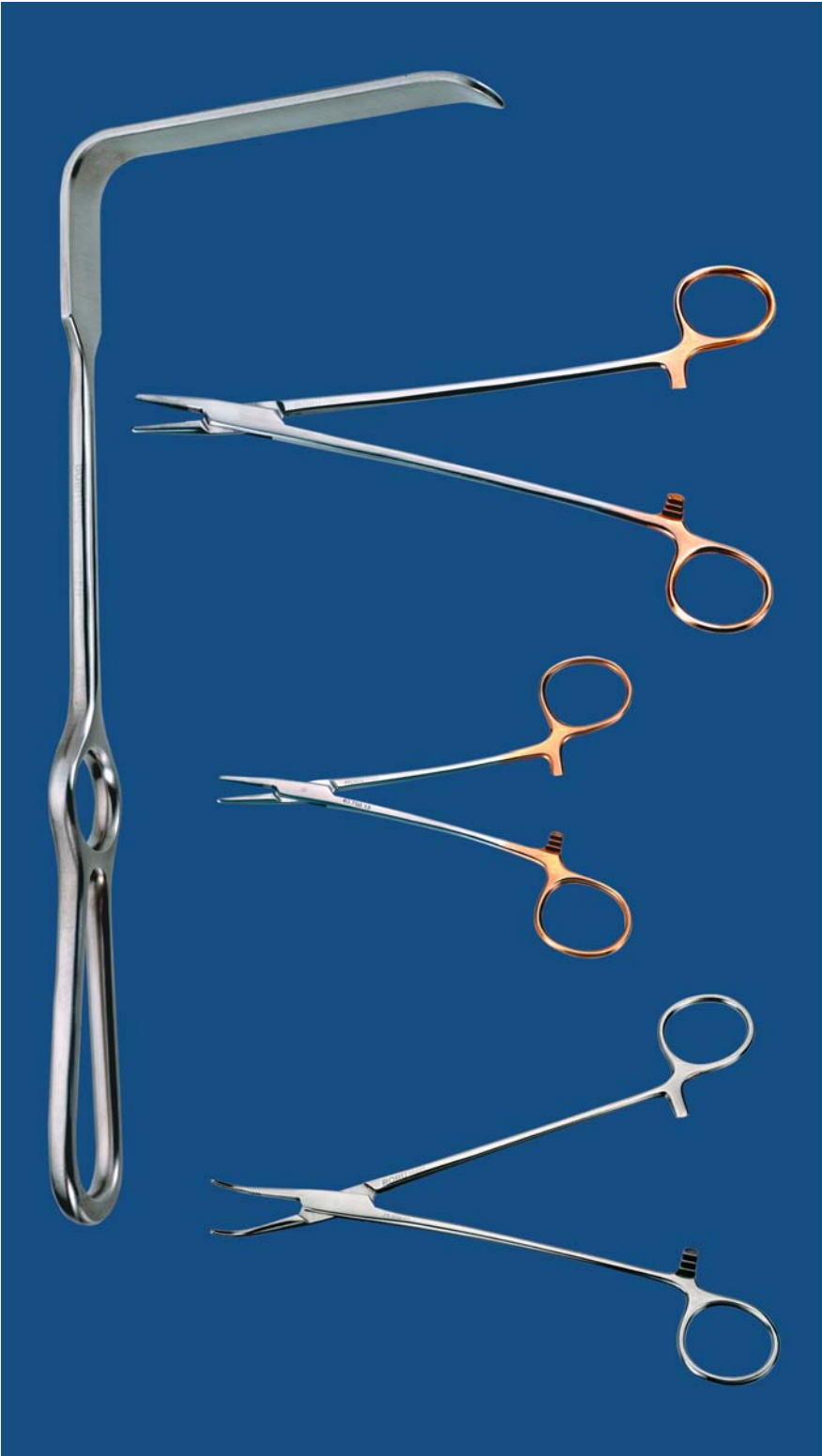
### Instruments

- Pump-syringe [1]
- Sterile centimeter rule [2]
- Sterile marking pen [3]
- Scalpel [4]
- Adson tweezers with plate [5]
- Surgical tweezers [6]
- Monopolar electrocoagulation [7]
- Insulated anatomical tweezers for hemostasis [8]
- Metzenbaum dissecting scissors [9]
- Backhaus clamps [10]
- Sharp four-pronged retractor [11]
- Large Langenbeck retractor [12]
- Large needle holder [13]
- Small needle holder [14]
- Curved forceps for hemostasis [15]



Thigh and Buttock Lift





12

13

14

15

**Thigh and Buttock Lift**

---

### **Duplicate Patient Information**

The patient is first given comprehensive information about the objectives and risks of the procedure on the day of the first consultation. A written record is kept of this.

One day before the surgical procedure, the patient is again given comprehensive information on two separate occasions: once by the surgeon and once by the surgical resident. All the risks are set down in writing at this time.

Although one tries to achieve symmetry before the intervention by precisely drawing the areas of skin that are to be removed, after the operation there may still be small differences between the sides. If this is very unsightly, it is possible to compensate by making a small extra intervention under local anesthesia without a need to admit the patient. During the first few weeks after the operation, the scars frequently move caudally.

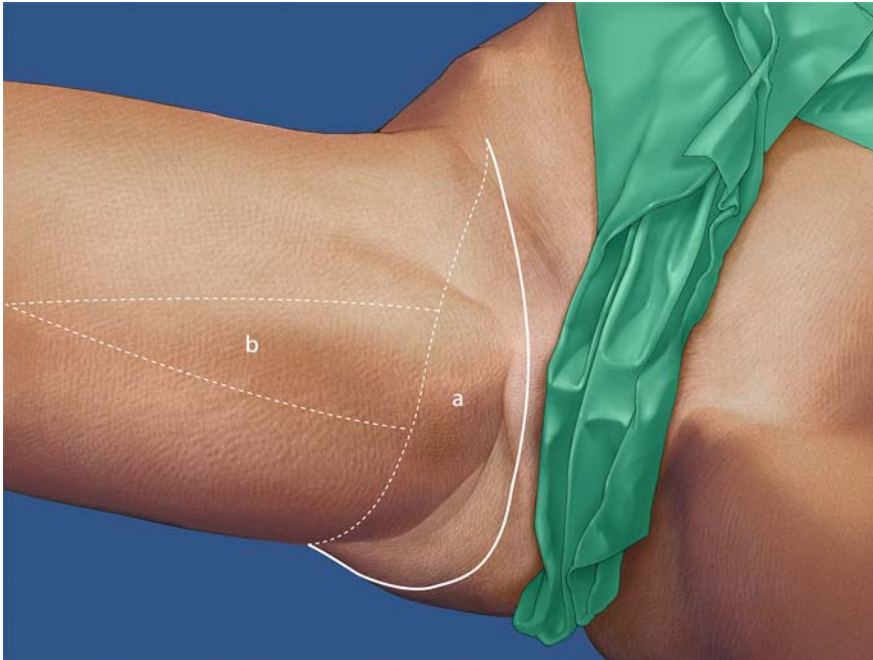If the patient is also given a buttock lift, he/she must be made aware that the shape is primarily determined by the musculature and cannot be substantially changed by the intervention.

### **Preliminary Examinations**

- Current preoperative routine laboratory tests, ECG, chest X-ray if the patient is over 50.
- Clinical examination of the patient.

### **Photographic Documentation**

- Frontal view of patient standing, torso and legs
- Side view of patient standing
- Rear view of patient standing



### • Surgical Planning

The operation is performed under general anesthesia with endotracheal intubation. Before the intervention the affected area is shaved. The day before the operation the surgeon carrying out the operation discusses with the patient in detail what he/she wants in terms of changes and how the surgeon can achieve this, and draws the incision lines and resection boundaries precisely. The patient must be warned about having unrealistic expectations and be given detailed information about postoperative measures in order to avoid scar formation as far as possible. Intraoperative single-shot infection prophylaxis with cefaclor 2 g, treatment in the hospital, Steri-Strip dressing, thrombosis (fractionated heparin 1 ampule i.m. preoperatively and 3 days postoperatively) and embolism prophylaxis, special girdle.

If the loss of elasticity and slackness of the skin is confined to the upper third of the thigh, the operation may be carried out in a half-moon shaped skin/fat resection in this area (a). The scar is then located in the groin and runs into the buttock crease. There is no scar on the inner side of the thigh. This is the operation that is wanted most frequently and is also presented in detail in the video.

If the overstretching and therefore loose skin stretches over the whole inner side of the thigh as far as the knee, then it is necessary to carry out additional vertical removal of skin/fat, depending on the extent of the skin on the inner side of the thigh (*b*). The scar is then located in the groin and on the inner side of the thigh, depending on how far the slackness of the skin extends, to just above the knee.

If there is also pronounced wrinkling of skin on the buttock, then a skin/fat resection must be carried out here as well. The scar then will be in the buttock crease and runs forwards into the inguinal region. The resection lines are drawn before the operation with the patient in a standing position. It must be kept in mind here that the incision line in the area of the inguinal fold should be relatively high (two fingerwidths in the cranial direction) since the scars always descend slightly over time and then could be visible in the upper leg area.

The incision in the groin, which is at the height of the pubic hair boundary laterally, generally runs above the inguinal fold to the thigh-perineal crease and finishes at the innermost part of the buttock crease, which is lengthened accordingly if there is also a buttock lift.

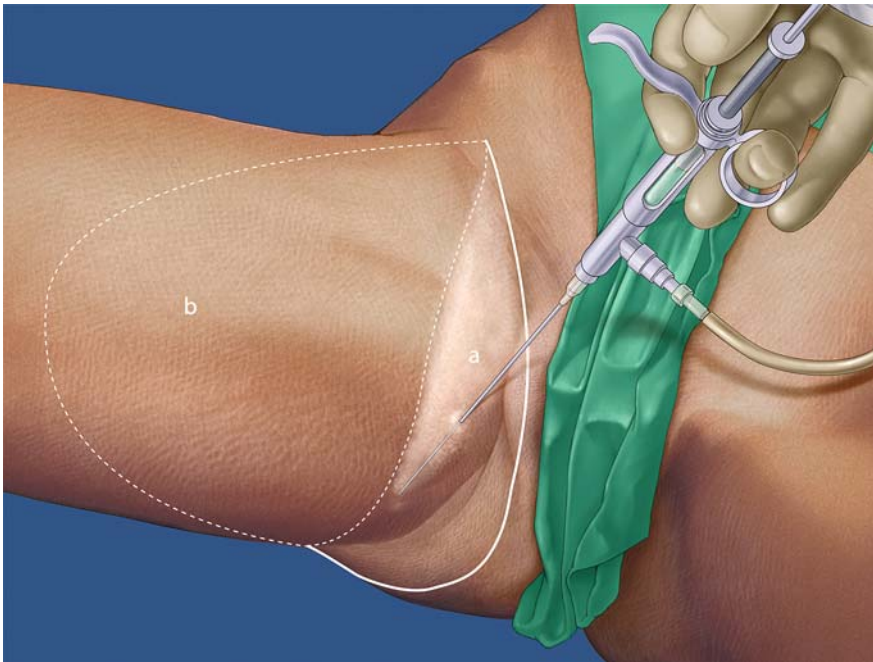
If only a buttock lift is carried out, then only the resection in the area of the buttocks is drawn according to the extent desired.

### Positioning, Disinfection

- For the operation, the patient is placed on the operating table in a supine position with the knees as far apart as the shoulders and the hips flexed at an angle of 30°. If extensive removal of skin is required, for example, if there has been extreme weight loss, then it may be necessary to use a urinary catheter both during and shortly after the operation.

### ⦿ Tumescence

- After shaving and careful disinfection of the whole operating area, the tumescence solution (0.9% NaCl 500 ml, 1% prilocaine 250 mg = 25 ml, epinephrine 0.5 mg, 8.4% NaHCO<sub>3</sub> 5 mEq) is infiltrated into the skin area to be resected along the predrawn incision and dissection boundaries. For each side, depending on the extent of the flabby skin, one needs between 250 and 500 ml of tumescence solution. The tumescence solution is pumped in manually, until a taut elastic skin tension and the typical blanching effect are noted.



The resection area (*a*) is, as in all tightening operations, only established when, following dissection (*b*), the exact superfluous skin has been fixed using key sutures. Consequently, the same basic principle always applies that before the skin flap is resected one makes the incision on the resection line that has been pulled over and only then carries out the whole dissection.

Dissection boundary is dependent on how far the loose skin extends.



---

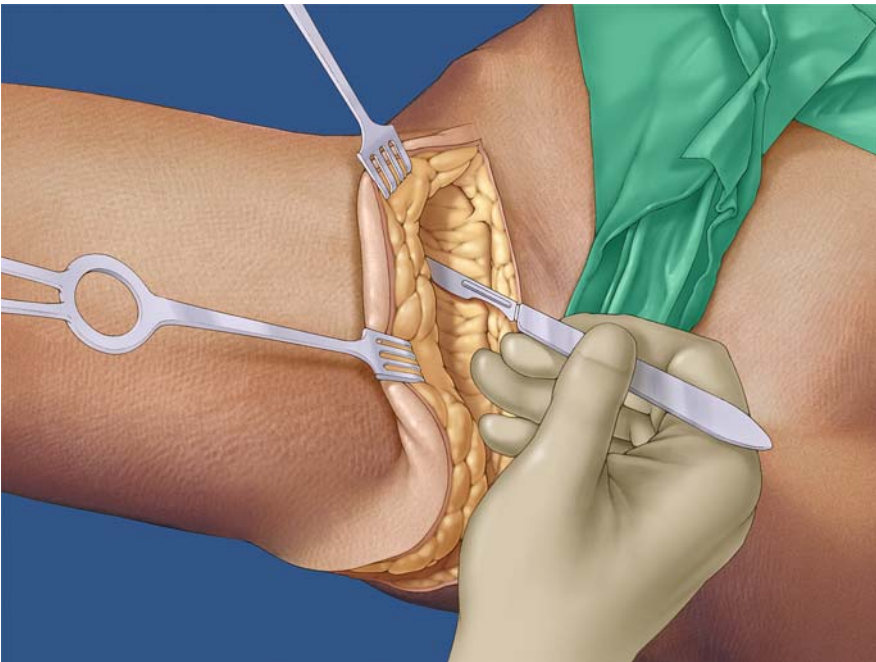
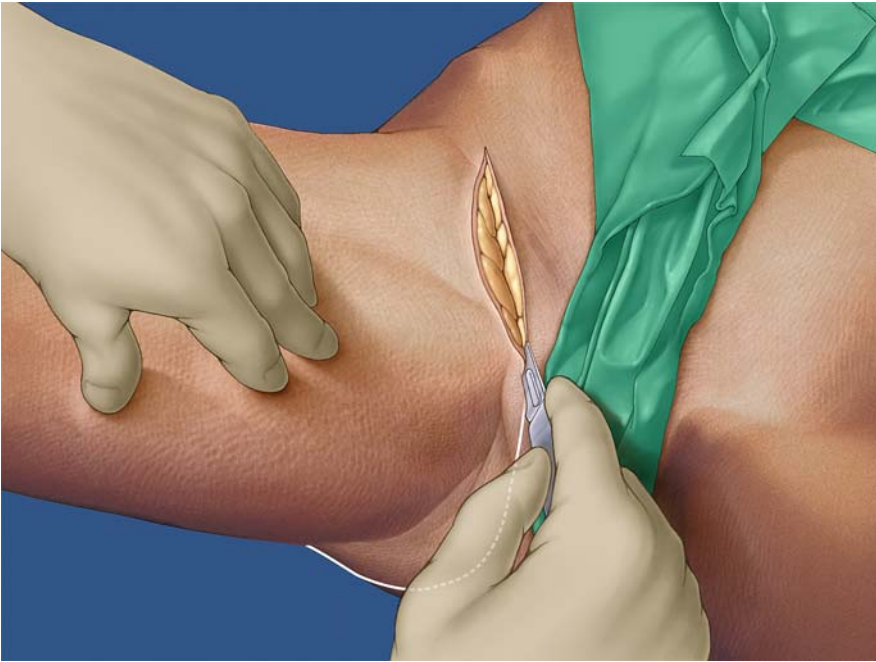### ◉ Incision of the Skin

- The incision is made according to the marks made preoperatively. Note that the incision line runs for approximately two fingerwidths to the cranial side of the groin, since the scar moves caudally owing to the later traction.
- The incision is made using a size 10 scalpel, radically, as far as the subcutaneous adipose tissue and may, without repositioning the patient, be continued as far as the middle third of the buttock region. If no buttock lift is indicated, the incision should be as far as possible into the buttock region so that the posterior part of the thigh is also tightened and modeled.

---

### ◉ Preparation

- When dissecting away the cutaneous/fatty flap, the assistant uses two sharp retractors and holds these under tension so that the dissection using sharp instruments can be carried out without any problems. It is rigorously dissected off as low down the thigh as the extent of the slackness demands.



---

### Deep Dissection and Hemostasis

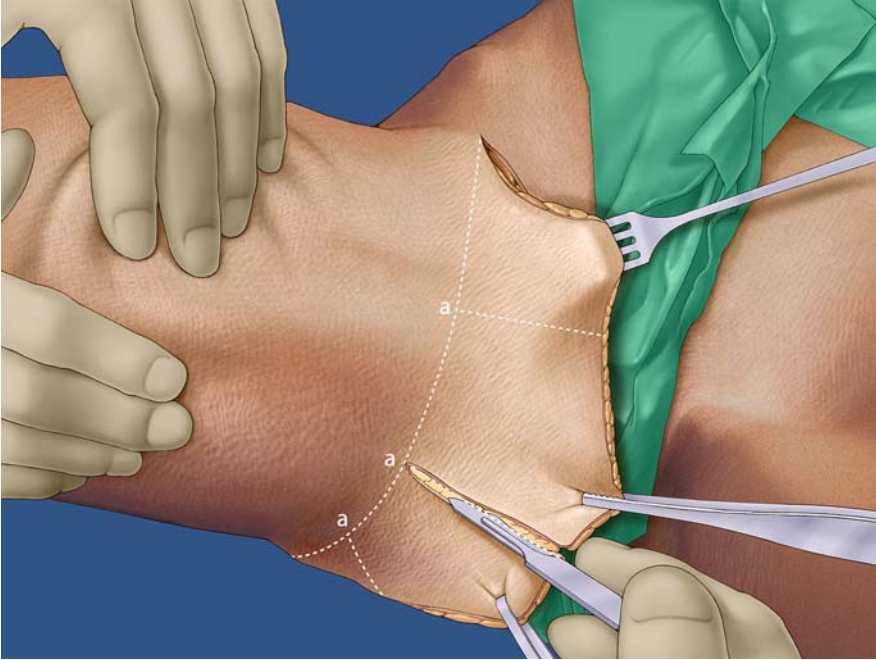
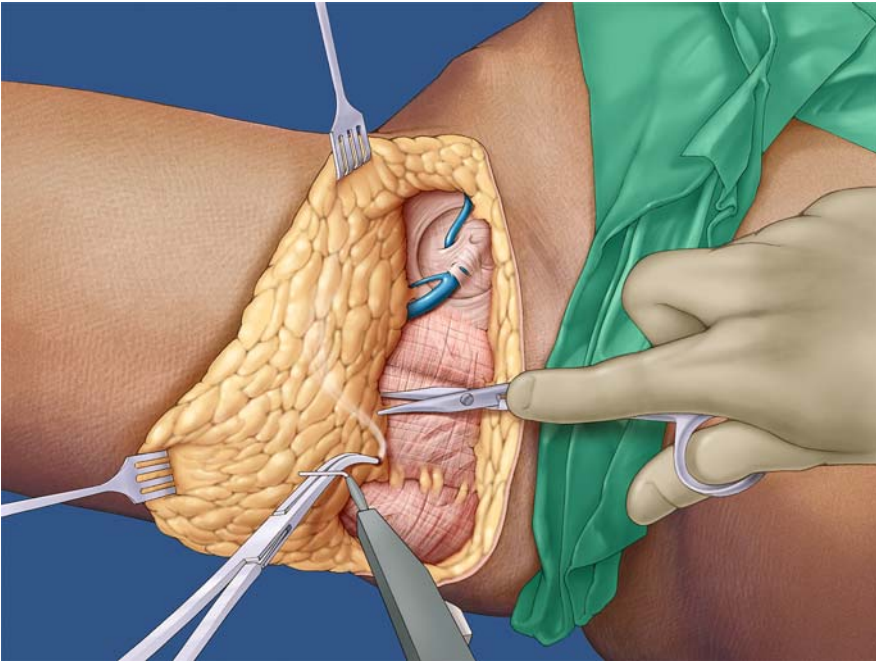
- Deep dissection is carried out using the Metzenbaum dissecting scissors by pulling the cutaneous/fatty flap caudally. Bleeding is stopped using bipolar or monopolar tweezers. If dissection is carried out in the correct layer, precisely above the thigh fascia, no vessel ligatures are required.
- Deep dissection is taken as far as was drawn on the day before the operation (dissection area) and discussed with the patient.

Only in rare cases do we carry out a vertical incision in addition to the inguinal incision, since most patients when they are given detailed information about the operation have problems with the prospect of what is usually a visible scar. If, however, there is very loose skin as far down as the knee, this incision line cannot be avoided.

---

### Definition of Resection Boundaries

- The assistant pushes the area of skin that has been dissected away in a cranial direction. Similarly, the cutaneous flap is pulled upwards with a sharp retractor and surgical tweezers in a cranial direction. The thigh is rotated inwards by the assistant so as to achieve as straight a position as possible, as is it would be in the standing position. The skin incisions are made precisely in these positions so that step by step the incision points (*a*) correspond with the cranial inguinal incision.



---

### **Skin Resection**

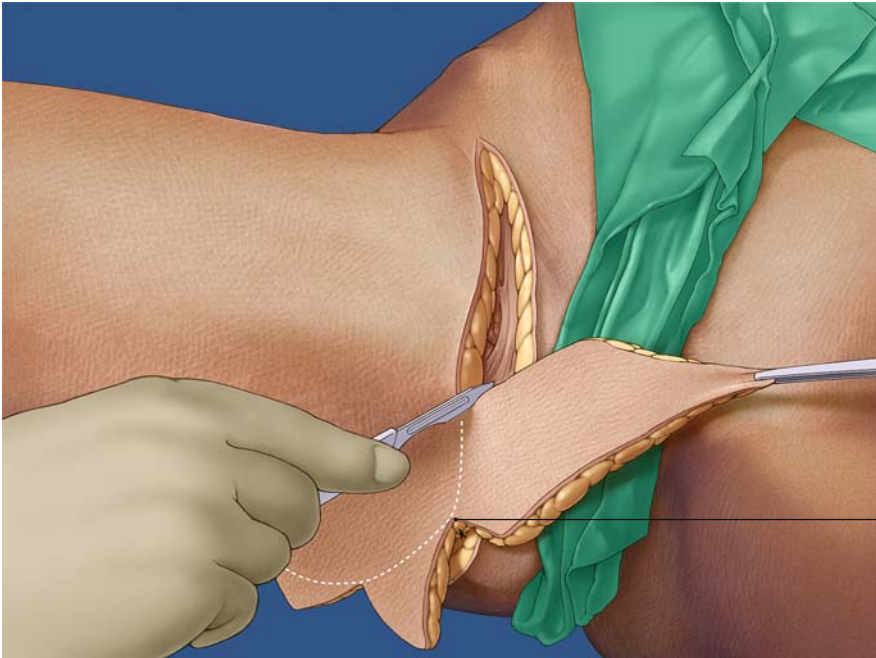
- Skin resection is performed with precise monitoring of the resulting tension on the cutaneous suture. The resection boundaries are dictated by the positions of the key sutures, which are taken out again after the resection, because the cutaneous flap – and this is the most important part of the operation – needs to be anchored deeply at two points with permanent sutures in order to achieve a satisfactory long-term result.
- After the skin resection residual areas of fat are removed. In the process it should be noted that subcutaneous fat is removed in the shape of a wedge, so that later joining can be step by step without any excess material. For all lifts concerning skin and extremities, it is important to have wedge-shaped joining in the form of an equilateral triangle. This prevents formation of seromas, promotes good wound healing, and therefore scar healing.

---

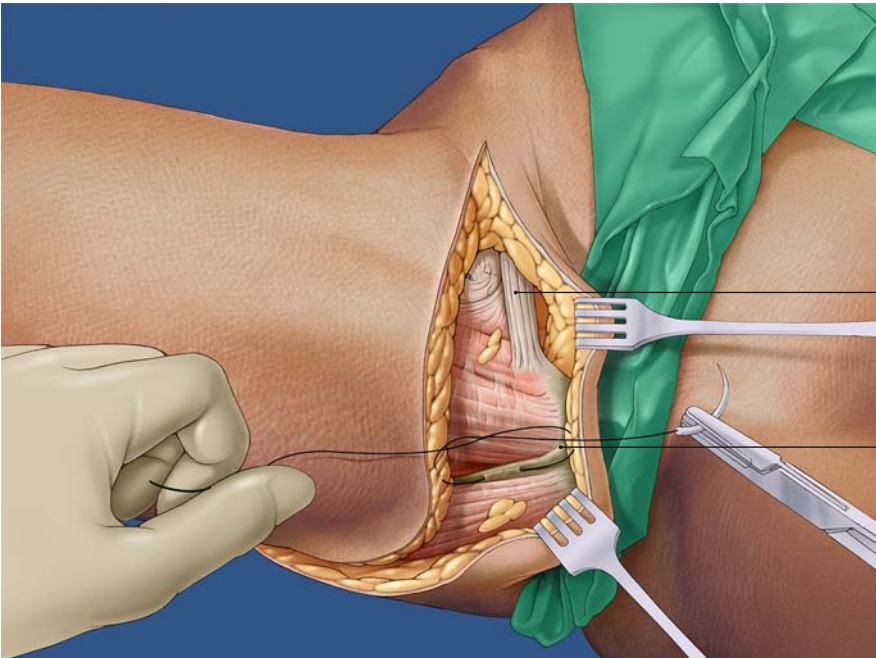
### **Fixation Suture on the Pubic Bone with 2.0 Monocryl**

- Following skin resection the inguinal ligament is dissected deeply using dissecting scissors. The same applies to the pubic bone further caudally. The periosteum of the pubic bone can be felt easily. Suturing to connect the subcutaneous fascia and adipose tissue of the cutaneous flap with the periosteum of the pubic bone may be carried out using a 2.0 Monocryl suture. We have the best experience with Monocryl and there has never been any impairment to wound healing. Owing to the long absorption rate, Monocryl has the same life as a monofilament cutaneous suture.





Key suture



Inguinal ligament

Periosteum of the mons pubis

---

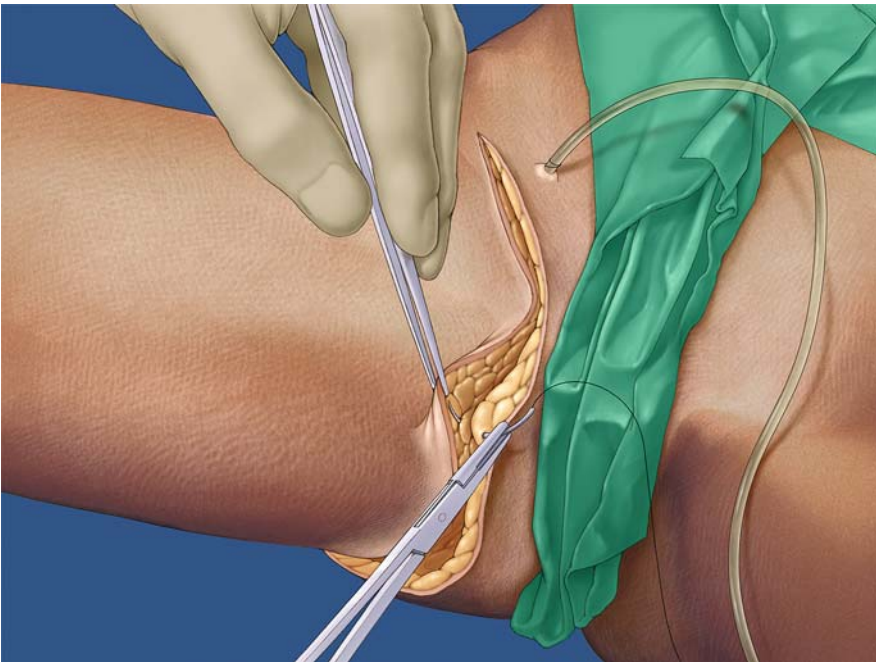
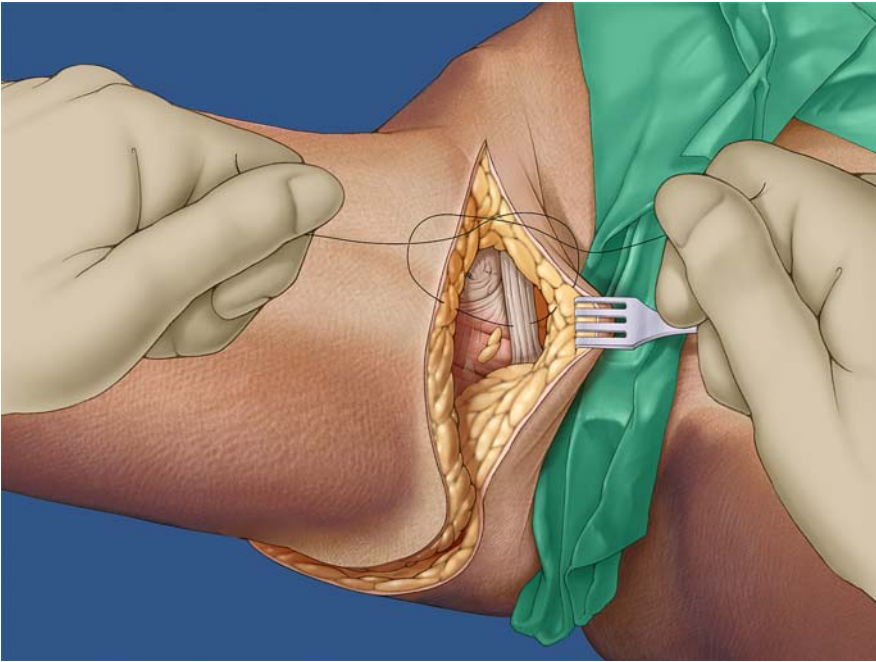
### Second Fixation Suture on the Inguinal Ligament

- After the deep demonstration of the inguinal ligament has taken place over its whole length using dissecting scissors, the subcutaneous adipose sheath with the subcutaneous fascia is anchored to the inguinal ligament using 2.0 Monocryl interrupted sutures, to distribute the main weight, avoid secondary descent of the scars and divarification of the labia majora.

---

### ● Deep Wound Closure and Insertion of a Redon Drain (no. 10)

- Before deep wound closure, the flap is trimmed and the excess fatty tissue is resected. After dissection of the subcutaneous fascia (Scarpa's fascia) this is closed by means of deeply concealed 3.0 Monocryl interrupted sutures. This suture and the two fixation sutures on the inguinal ligament and the periosteum of the pubic bone ensure that little tension is placed on the final subcutaneous and cutaneous suture. This is important to ensure good healing of the scar later on. Redon drains size 10 are inserted.





---

### Intracutaneous Skin Closure

- After subcutaneous adaptation using 3.0 Monocryl interrupted sutures, the skin is closed without tension with a running intracutaneous 4.0 Monocryl suture. Dog-ears should be avoided and if they are present, they should be corrected at the caudal end of the incision line running into the buttock crease.
- If, following a thigh lift, a buttock lift is carried out, the patient is turned onto his/her stomach, but in the same position.
- The intervention is completed with a 4.0 running intracutaneous Monocryl suture.\*

---

### ⦿ Dressing

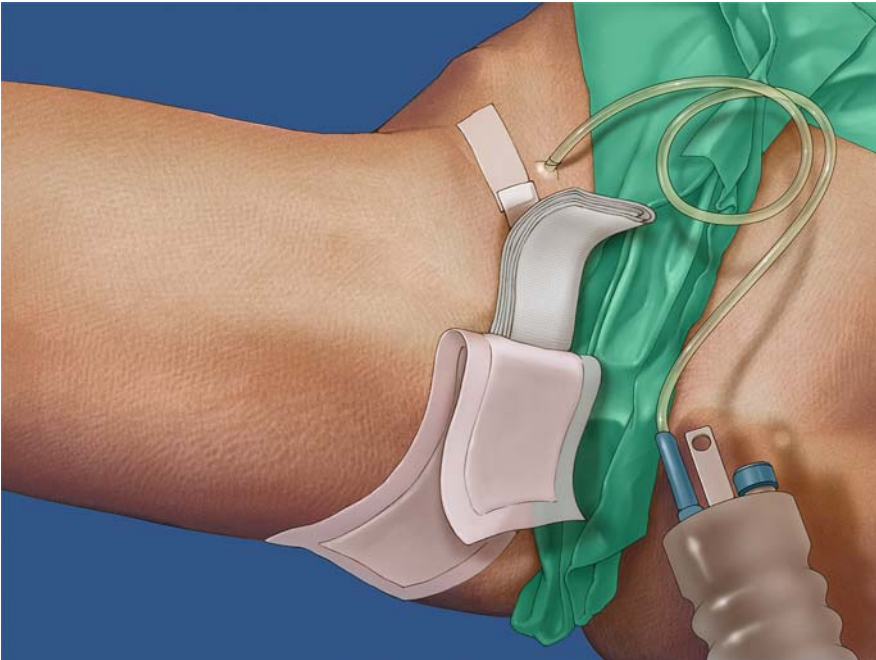
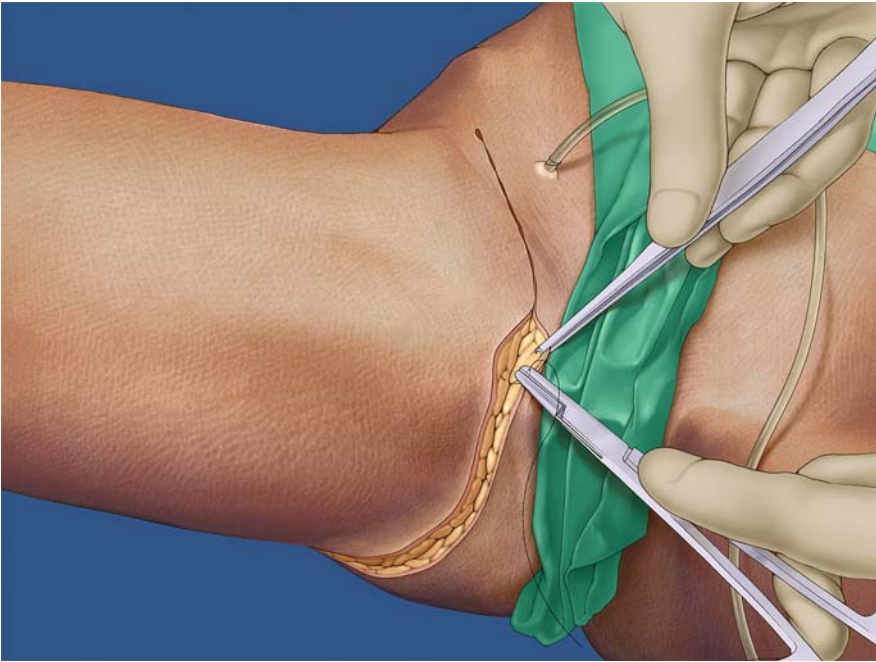
- Dressing is with Steri-Strips that are removed after 8 days once the wound has been checked. For the first 2 days after the operation compression dressings and Cutiplast with special girdles are used. The Redon drain can be removed on the first or second day after the operation, depending on the results. Antibiotics and thrombosis prophylaxis should be given.

**Note:**

If the fixation shown here appears to be too static, then it is possible to suture the thigh fascia to the deep pubic fascia for dynamic anchoring instead of fixation to the periosteum of the pubic bone.

---

\* Ethicon GmbH & Co, Schüsselberg 8, 73453 Abtsgemünd, Germany  
Serag-Wiessner, Zum Kugelfang 8–12, 95119 Naila, Germany



---

### Buttock Lift: Positioning, Disinfection

- It is crucial, as with all lifting operations, to ensure that the preoperative drawing is correct, so that the wedge-shaped resection later produces a scar that lies exactly in the buttock crease. This means that later on it will be scarcely visible.

### ○ Tumescence

Tumescent pretreatment of the tissue is the norm in aesthetic operations today. When buttock lifts are carried out, approximately 200 ml of the tumescence solution (0.9 % NaCl 500 ml, 1 % prilocaine 200 mg = 20 ml, epinephrine 0.5 mg, 8.4 % NaHCO<sub>3</sub> 5 mEq) is sufficient.

If the buttock lift is combined with a thigh lift, which is something frequently wanted upwards of a certain age, both the incision lines are joined in such a way as to achieve a homogeneous radial tightening of the whole thigh and buttock area. Unfortunately, patients often have too high expectations and forget that the shape of the buttock is primarily determined by the shape of the musculature and not by fatty accumulations and loose skin.

Owing to the tumescent infiltration, the operating area is free from blood, thereby ensuring safe, simple, and quick dissection.

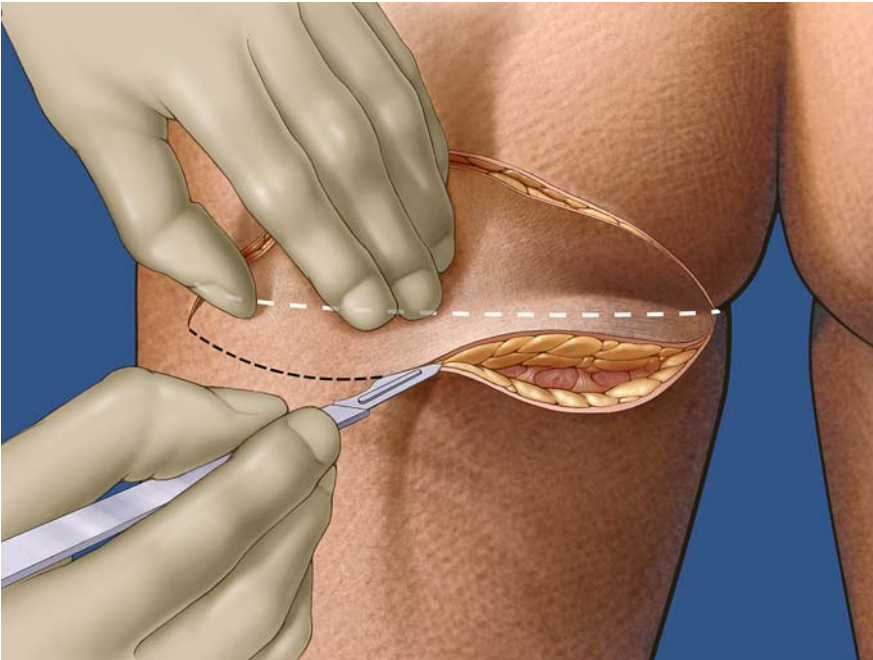
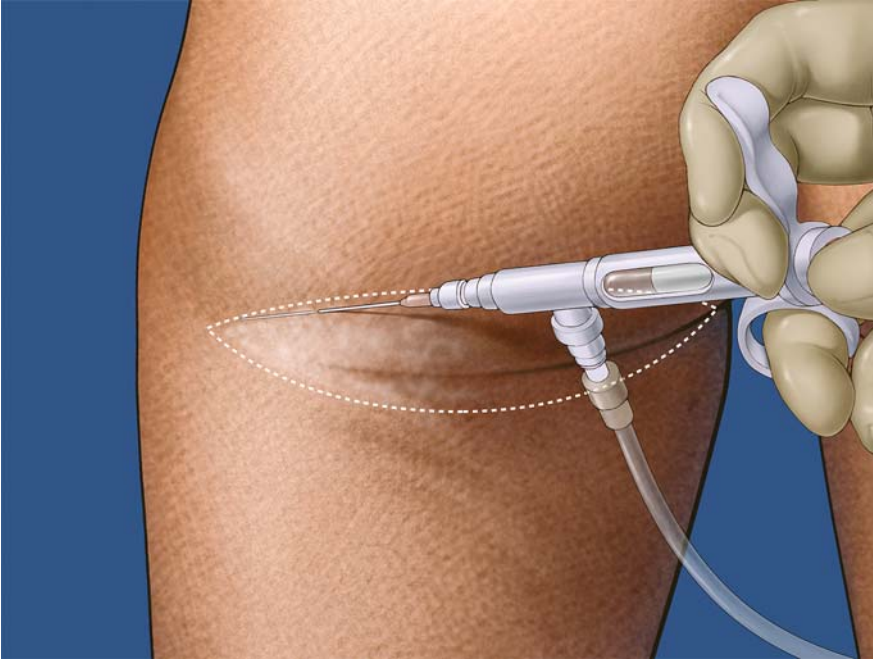
---

### ○ Incision Line

- Preoperatively the incision line is drawn precisely with the patient in a standing position. The intended line of the subsequent buttock crease is marked, and the distances to the caudal and cranial incision margin are measured to ensure they are of the same length. By pinching together the buttock crease with both hands the extent of resection can be determined. It is recommended that one should always be conservative at the beginning. Over time one must explore the limits as an aesthetic surgeon, but one should always bear in mind that it is easier to correct excesses than it is to correct deficits.

### ○ Incision

- Using a no. 10 scalpel a wedge shape is cut at an angle of approximately 70° downwards as far as the fascia of gluteus maximus. The deepest point of the wedge excision on the muscle fascia should be at the level of what will be the new buttock crease. The resection boundaries should be equivalent to an equilateral triangle, which later, following buttock lift and closure, produces the new buttock crease.

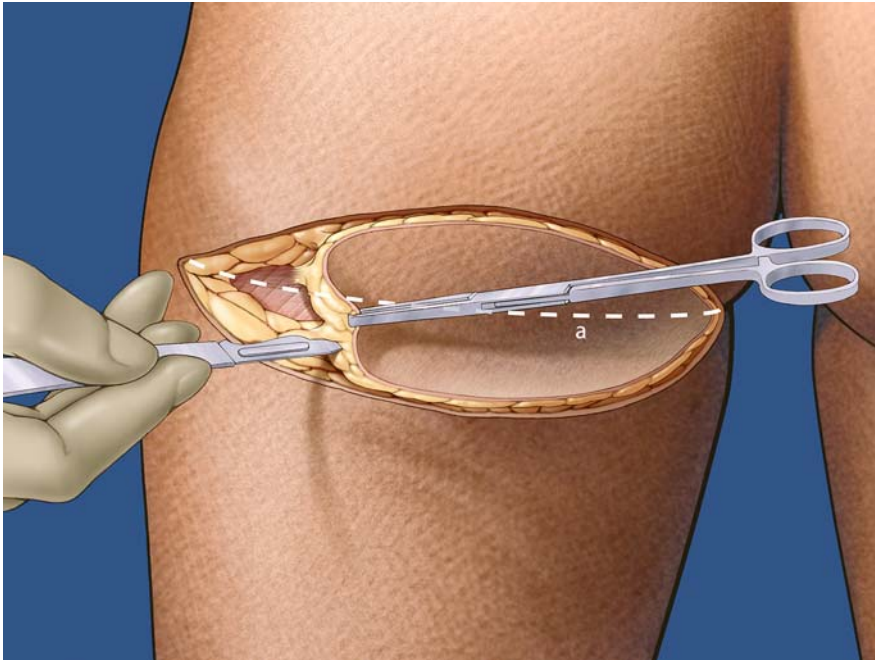


---

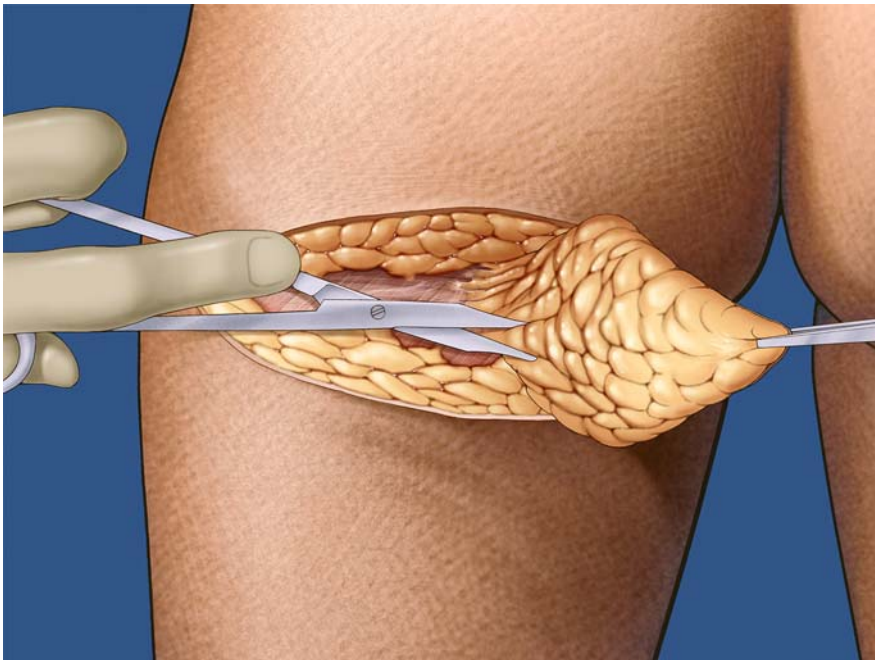
### Wedge-Shaped Dermolipectomy

- After the deep fat layer has been cut through in the shape of a wedge with a 70° angle using the no. 10 scalpel, the cutaneous/fatty flap is deeply dissected away in full using dissecting scissors from the fascia of the gluteus maximus.





a: Intended line produces subsequent buttock crease



---

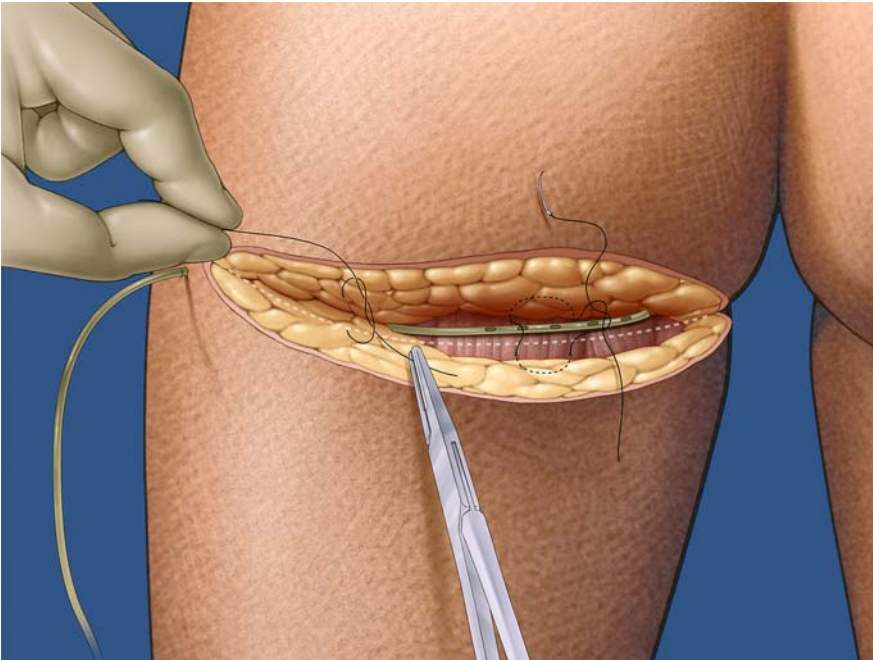
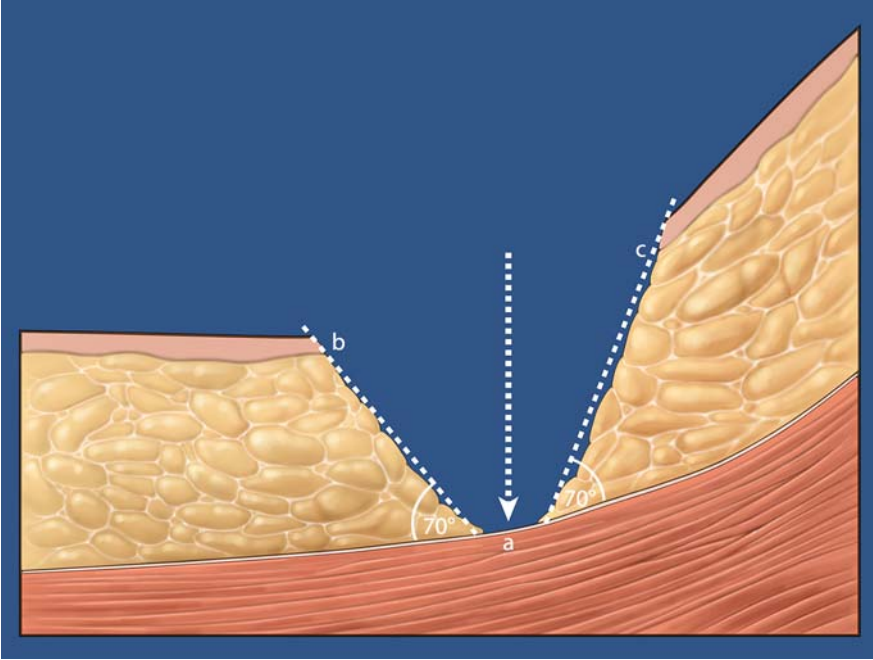
### Transverse Incision Through the Resected Area

- The deepest point of the wedge excision must be on the buttock crease that is to be defined later. The resection boundaries correspond to an equilateral triangle ( $a-b = a-c$ ) that after tightening and closure produce the new buttock crease.

---

### ⦿ Hemostasis, Deep Wound Closure, Insertion of a Redon Drain

- Following precise hemostasis and insertion of a no. 10 Redon drain, the first deep 3.0 Monocryl sutures are positioned in order to fix the buttock crease.





---

### ◉ Two-Layer, Tension-Free Wound Closure

- 3.0 Monocryl subcutaneous interrupted sutures are used. This removes the tension from the final, running, intracutaneous 4.0 Monocryl suture. This suture material has the major advantage that it heals without irritation, hardly produces any suture granulomas, does not need to be removed, has a long life, and produces excellent aesthetic results.

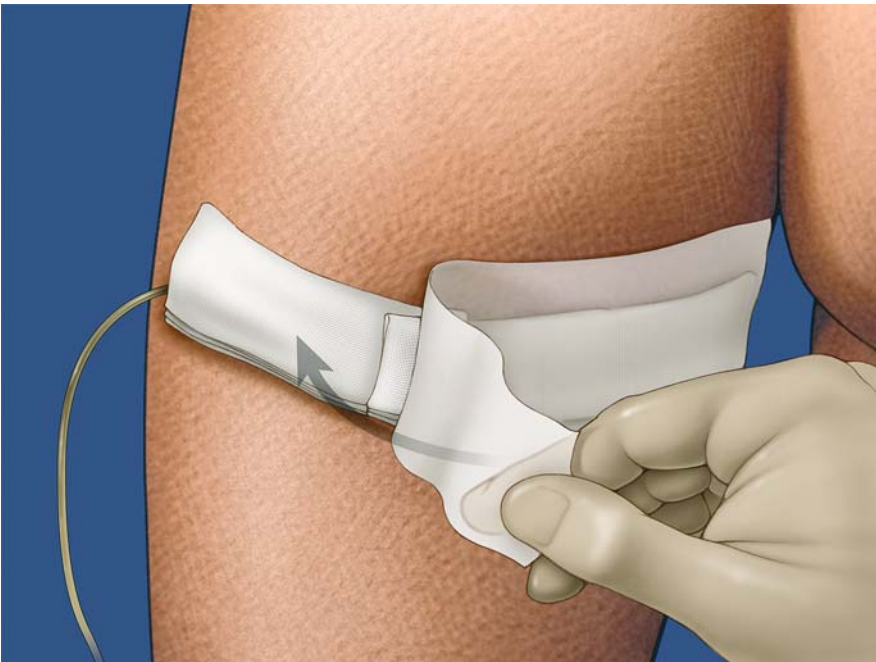
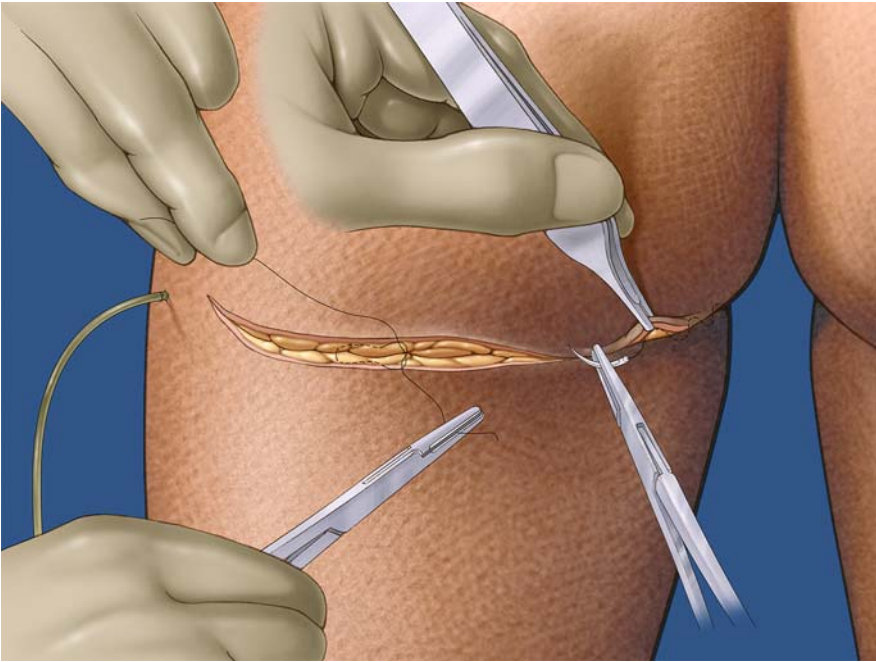
---

### ◉ Dressing

- A Steri-Strip dressing is applied directly to the wound. Eight days after the operation, this is removed once the wound has been checked. For days, Cutiplast and compression bandages are used to prevent edema and thrombosis. Postoperatively, a special girdle that has been made to measure prior to the operation should be worn for 4 weeks. Infection prophylaxis should be 2 g cefaclor.

**Note:**

The method of buttock lift shown here is indicated where there is surplus skin coverage. If, however, there is little surplus skin and the redefining of the buttock crease is a priority, then a more time-consuming surgical technique is required. In this case, the epithelium is removed from the skin area which has been marked out and the skin area is separated at the level of the new buttock crease as far as the gluteal fascia. After thinning out the caudal and cranial dermofat flaps, these are anchored to the gluteal fascia thus defining the new buttock crease.



---

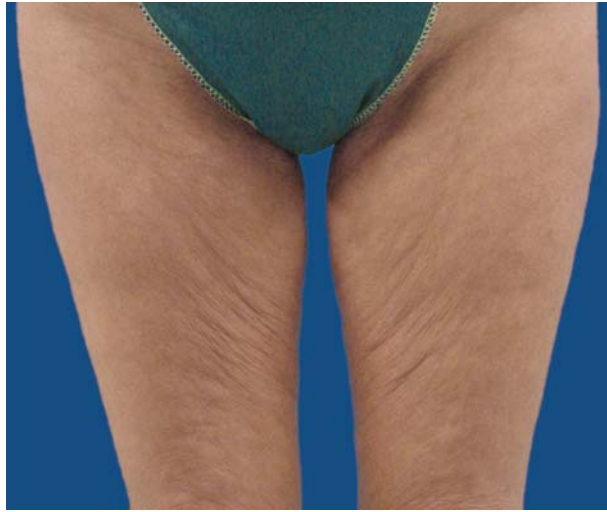**Postoperative Treatment:****Course of Action After the Operation; Precautionary Measures**

- Correct postoperative treatment after thigh and buttock lifts is very important to ensure long-term satisfactory results.
- For 24 h after the operation there should be bed rest and monitoring on the ward. Careful mobilization aided by a nurse starts the day after the operation. Moving the thighs apart should be avoided so as to prevent unnecessary traction on the wound. So as not to impair wound healing, any tension on the sutures should be avoided when the patient stands up. Legs should be moved regularly to promote the return blood flow.
- The Redon drains are removed painlessly after 1–2 days. While the patient is on the ward, lymph drainage and physiotherapy are recommended.
- The fresh scars are treated postoperatively for 3 weeks using dexpenthanol ointment and subsequently treated with silicone plasters for 2 months. The made-to-measure compression girdle should be worn for 4 weeks after the operation to prevent swelling and edema. After this one can resume sport activities.
- Antibiotic prophylaxis with cefaclor and embolism prophylaxis using low-molecular-weight heparin is only indicated during the stay on the ward.

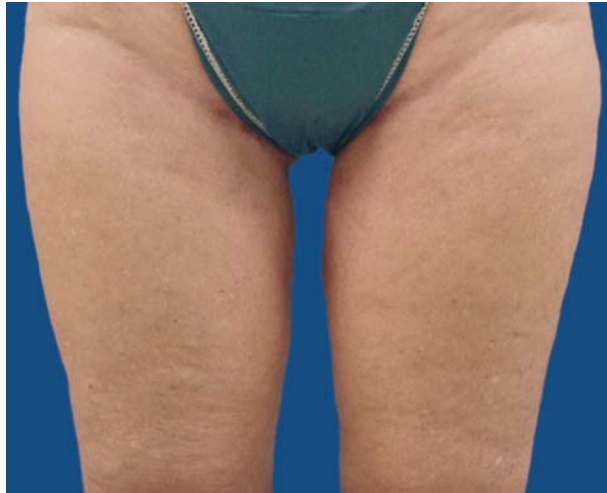**Results**

Patient I: This is a 62-year-old female patient with typical wrinkling in the upper third of the medial thigh. In this case inguinal tightening has been carried out without a vertical incision. The cutaneous flap was anchored on the periosteum and the inguinal ligament. Intensive scar treatment was carried out for 6 months.

Twelve months after the operation. Weight gain of the patient and sports activities in the gym. Healthy scars owing to good wound healing and intensive treatment of the scar.



Before the operation – frontal view



After the operation – frontal view

---

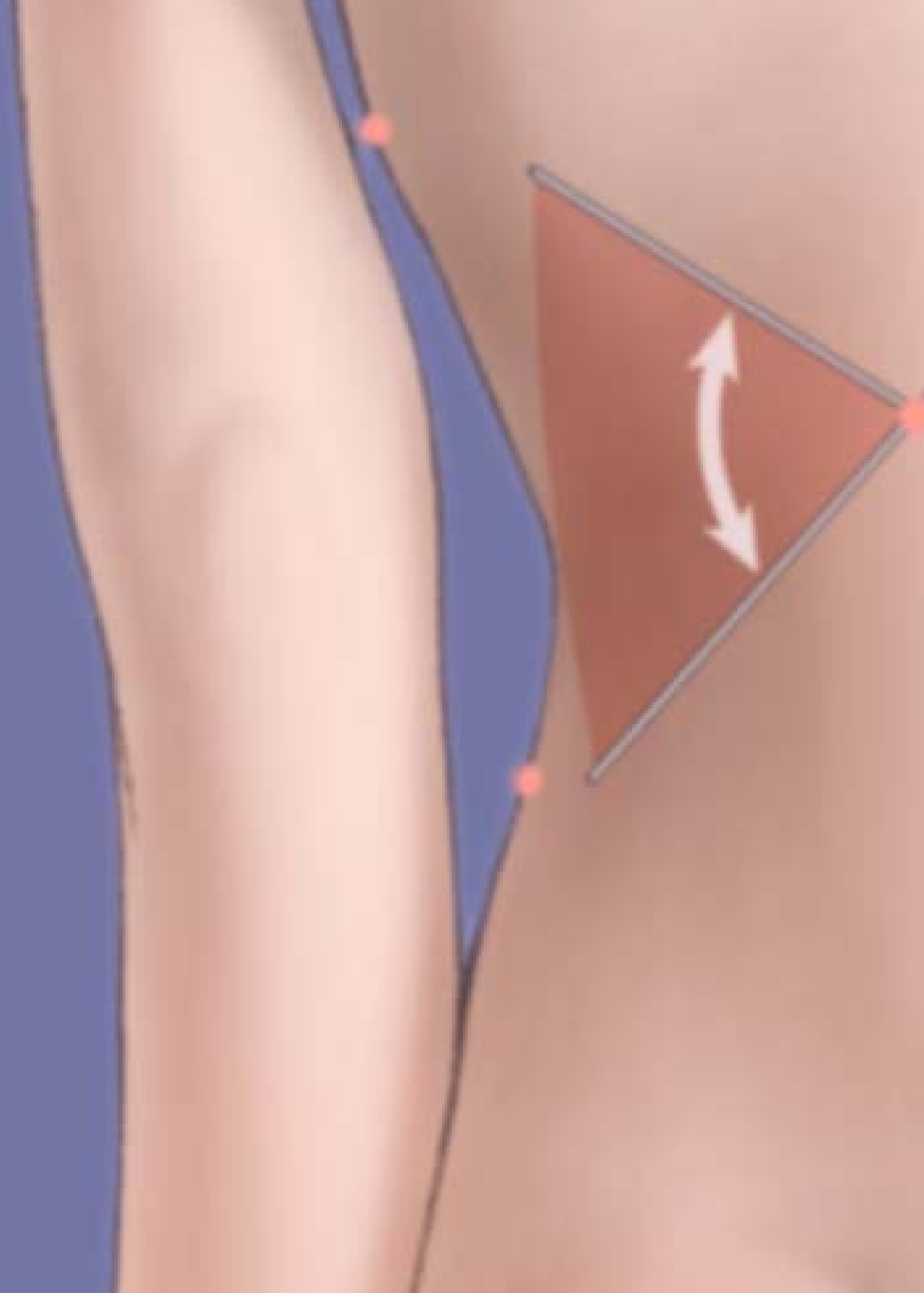
## Literature to Buttock Lift

- Collantes E; Veroz R, Escudero A, et al (2000) Can some cases of 'possible' spondyloarthropathy be classified as 'definite' or 'undifferentiated' spondyloarthropathy? Value of criteria for spondyloarthropathies Spanish Spondyloarthropathy Study Group. *Joint Bone Spine* 67:516–520
- Ersek RA, Salisbury AV (1995) The saddle lift for tight thighs. *Aesthetic Plast Surg* 19:341–343
- Goddio AS (1991) Skin retraction following suction lipectomy by treatment site: a study of 500 procedures in 458 selected subjects. *Plast Reconstr Surg* 87:66–75
- Greis PE; Kuhn JE, Schultheis J, et al (1996) Validation of the lift-off test and analysis of subscapularis activity during maximal internal rotation. *Am J Sports Med* 24:589–593
- Heddens CJ (2001) Belt lipectomy: procedure and outcomes. *Plast Surg Nurs* 21:185–189, 199; quiz 191
- Lavigne P, Lorient de Rouvray TH (1994) The superior gluteal nerve. Anatomical study of its extrapelvic portion and surgical resolution by trans-gluteal approach (in French). *Rev Chir Orthop Reparatrice Appar Mot* 80:188–195
- Lewis JR Jr (1980) Body contouring. *South Med J* 73:1006–1011
- Lockwood TE (1991) Transverse flank-thigh-buttock lift with superficial fascial suspension. *Plast Reconstr Surg* 87:1019–1027
- Lockwood T (1993) Lower body lift with superficial fascial system suspension. *Plast Reconstr Surg* 92:1112–1122; discussion 1123–1115
- Pascal JF, Le Louarn C (2002) Remodeling bodylift with high lateral tension. *Aesthetic Plast Surg* 26:223–230
- Pitanguy I (1981) *Aesthetic Plastic Surgery of Head and Body*. Springer Heidelberg New York Berlin
- Pitanguy I, Ceravolo M (1983) Our experience with combined procedures in aesthetic plastic surgery. *Plast. Reconst. Surg* 71:56–63
- Schwetlick G, Weber U, Klingmuller V, et al (1990) The vascularized pedicled flap of superior gluteal artery to hip bone chip – a new concept in the revascularization of hip necrosis in adults (in German). *Unfallchirurgie* 16:75–79
- Teimourian B, Adham MN (1982) Anterior periosteal dermal suspension with suction curettage for lateral thigh lipectomy. *Aesthetic Plast Surg* 6:207–209

---

## Literature to Thigh Lift

- Candiani P, Campiglio GL, Signorini M (1995) Fascio-fascial suspension technique in medial thigh lifts. *Aesthetic Plast Surg* 19:137–140
- Ersek RA, Salisbury AV (1995) The saddle lift for tight thighs. *Aesthetic Plast Surg* 19:341–343
- Lockwood TE (1988) Fascial anchoring technique in medial thigh lifts. *Plast Reconstr Surg* 82:299–304
- Lockwood T (1993) Lower body lift with superficial fascial system suspension. *Plast Reconstr Surg* 92:1112–1122; discussion 1123–1115
- Pitanguy I (1981) *Aesthetic Plastic Surgery of Head and Body*. Springer Heidelberg New York Berlin
- Pratt CA, Buford JA, Smith JL (1996) Adaptive control for backward quadrupedal walking V. Mutable activation of bifunctional thigh muscles. *J Neurophysiol* 75:832–842
- Schoeller T, Meirer R, Otto-Schoeller A, Wechselberger G, Piza-Katzer H (2002) Medial thigh lift free flap for autologous breast augmentation after bariatric surgery. *Obes Surg* 12:831–834
- Schultz RC, Feinberg LA (1979) Medial thigh lift. *Ann Plast Surg* 2:404–410
- Spirito D (1998) Medial thigh lift and DE.C.LI.VE. *Aesthetic Plast Surg* 22:298–300
- Stadelmann WK (2002) Intraoperative lymphatic mapping to treat groin lymphorrhea complicating an elective medial thigh lift. *Ann Plast Surg* 48:205–208
- Teimourian B, Adham MN (1982) Anterior periosteal dermal suspension with suction curettage for lateral thigh lipectomy. *Aesthetic Plast Surg* 6:207–209



---

## Liposuction

- Introduction 159
- Instruments 160
- Duplicate Patient Information 163
- Preliminary Examination 163
- Surgical Planning 164
- ■ Anatomy of Liposuction of the Abdomen, Hips, Thighs 164
  - Anatomical Overview 165
- Anatomy of Liposuction of the Hips, Back, Thighs, Buttocks (Body Contouring) 166
  - Anatomical Overview 167
- ■ Anatomy of Liposuction of the Axilla, Chest, Hips, Lateral Side of the Thighs 168
  - Anatomical Overview 168
- Anatomy of Liposuction of the Medial/Lateral Side of the Thighs, Knee 170
  - Anatomical Overview 170
- Anatomy of Liposuction of the Medial Part of the Thighs, the Knees, Calves, Ankles 172
  - Anatomical Overview 172
- Anatomy of Liposuction of the Calf and Ankles 172
  - Anatomical Overview 172
- Anatomy of Liposuction of the Breast, Axilla, Upper Arms 174
  - Anatomical Overview 175
- Anatomy of Liposuction of a Double Chin 176
  - Anatomical Overview 177
- ■ Mechanical and Manual Tumescence 178
  - Location of the Incision Sites from the Rear 180
  - Location of the Incision Sites from the Front 180
  - Schematic Diagram of Mang's Tumescence Liposuction Technique 182



- 
- Cross-Section of the Skin Before Tumescence 182
  - Cross-Section of the Skin Following Tumescence 182
  - Cross-Section of the Liposuction Technique 184
  - Cross-Section of the Tissue 6 Months After Liposuction with Preservation of the Infrastructural Connective Tissue (ICT) 184
    - Technique 188
    - Disinfection 188
  - Manual Liposuction 190
  - Mechanical Liposuction 190
  - Procedure 190
  - Dressing 191
  - Aftercare 192
  - Results 193
  - Literature 199

- Detailed instructional films on liposuction of double chins, abdomen/hips and thigh/knee are provided on the DVD.

---

## Introduction

In 1921, a French surgeon carried out curettage on the knee area of one of his patients in order to achieve an improvement in the shape. This procedure was later combined with suction, until in the end curettage was abandoned. Prof. Fournier introduced the cross technique in 1987, achieving impressive results with regard to the evenness of the skin.

The shape and size of the cannulas used for liposuction have continued to change and develop. The pioneers of liposuction were Ilouz, Fournier, and Klein. An ultrasound-assisted method was first introduced in 1982. Another technique that protects the tissue by using vibrating cannulas was introduced by an American, W.P. Coleman, in 2000.

As this book is intended to impart basic knowledge, the tumescence technique demonstrated in the accompanying video is manual liposuction, as this is most suitable for learning the new technique of liposuction from the beginning. Admittedly, this technique is time-consuming, but it achieves good results and can be learned reliably.

Of all the additional instruments used at the Bodenseeklinik, the best when it comes to large areas of liposuction has proved to be the MicroAire (MicroAire Surgical Instruments, Charlottesville, VA, see figure on p. 162) system (tissue-sparing; suction without much bleeding; comfortable for the surgeon to operate; almost pain-free suction; time-saving). The size of cannulas varies between 2 and 4 mm; at the beginning of suction 3 mm cannulas should be used (extremities, saddle area). In very corpulent patients, 4 mm cannulas can be used in the abdominal area. For delicate modeling in the neck, buttock, knee, and ankle areas, 2 mm cannulas are sufficient.

The protective technique of tumescent liposuction has considerably reduced the high risks of dry suction under general anesthetic (thrombosis, blood loss, embolism, infection, scarring, skin unevenness, hematoma). If the tumescence solution containing local anesthetic as well as vasoconstrictors is injected beforehand general anesthesia is not necessary. The patient receives only sedation and intraoperative monitoring (IV access, pulse, blood pressure, O<sub>2</sub> saturation, and ECG monitoring). Adding adrenaline to the solution as a vasoconstrictor reduces the risk of the patient losing a large amount of blood and prevents large hematomas from developing.

In addition, the incidence of complications can be drastically reduced by perioperative thrombosis and embolism prophylaxis [single-shot

cefactor 2 g, Mono Embolex IM (low molecular weight heparin) before, during, and after the operation]. In a study carried out by the American Society of Dermatologic Surgery there were no cases of embolism, thrombosis, or infection in 15,336 patients treated with tumescent liposuction.

Problems can result, however, from the use of too much tumescence solution, which can place considerable strain on the circulation. The decisive factor is the tumescence solution used.

The first tumescent local anesthesia with lidocaine was described and documented by Klein as a local anesthetic solution. Mang's solution uses prilocaine as a local anesthetic in an even smaller dose (the smallest dose allowing almost painless suction was determined in a clinical study), as it exhibits the least toxicity. The prilocaine plasma levels were considerably below those for lidocaine.

Mang's solution used for tumescent local anesthesia

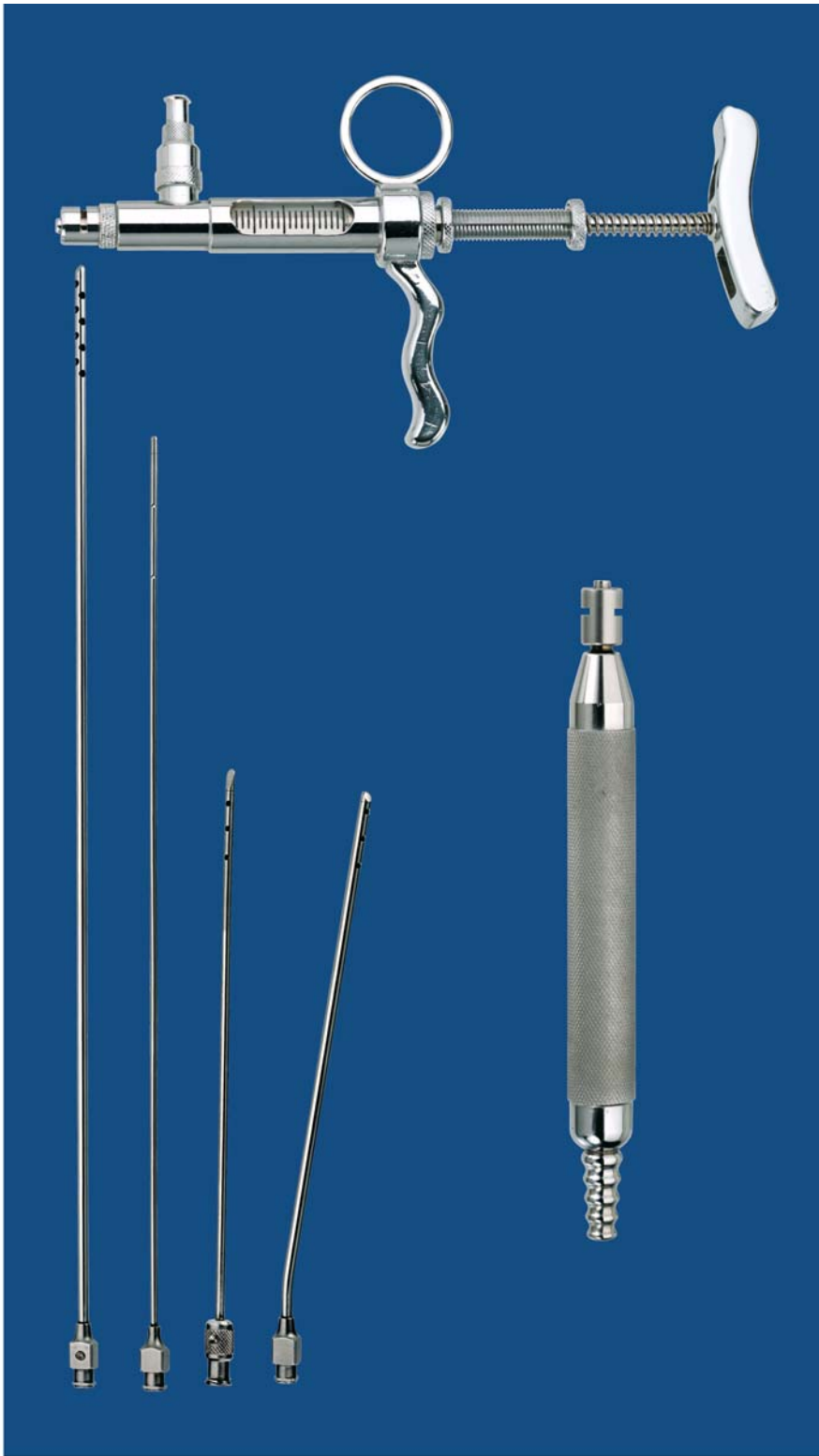Compound	Quantity	
0.9% Na Cl	3,000 ml	500 ml
Prilocaine 1%	150 ml	25 ml
Epinephrine	3 mg	0.5 mg
NaHCO <sub>3</sub> 8.4%	30 mEq	5 mEq
Triamcinolone acetone	30 mg	5 mg

### Instruments

- Tumesence syringe [1]
- Liposuction cannulas 2–3.5 mm [2, 3]
- Liposuction cannulas for double chins [4, 5]
- Handpiece [6]
- Handle with tube and cable [7]
- Liposuction cannulas 3 mm and 4 mm [8]
- MicroAire\* reciprocator [9]
- Tumesence with pump, see video

\* Tap Med, Gutshof 15-17, 34270 Schauenburg-Hoof, Germany

MicroAire Surgical Instruments LLC, 1641 Edlich Drive, Charlottesville, VA 22911, USA



Liposuction



7

8

9

---

### Duplicate Patient Information

The patient is first given comprehensive information about the objectives and risks of the procedure on the day of the first consultation. A written record is kept of this. All the risks are set down in writing at this time. It should be made clear that the patient may experience pain during the operation and that occasionally pressure damage may occur to the nerves and soft tissue. This will subside again in the space of a few weeks. The loss of a large amount of blood necessitating blood transfusions does not normally occur when the tumescence technique is used. Bloody effusions and a feeling of numbness in the operation site can occur after the procedure. Dimpling and the limits of the possibilities of liposuction must also be explained to the patient, as must the risk of thrombosis and embolism as well as the small scars that will occur at the insertion sites. In rare cases allergic reactions can occur in the skin, mucous membranes, heart, circulation, kidneys, or nerves. For this reason liposuction should be carried out on an inpatient basis with stand-by and monitoring.

If there are considerable irregularities in contour, the patient should be advised to have a corrective operation.

### Preliminary Examination

- Current, preoperative routine laboratory tests with APC resistance and glucose-6-phosphate dehydrogenase. ECG and chest X-ray if the patient is 49 years old or over. The patient should undergo a clinical examination, in particular to identify hernias in the abdominal region and varicose veins, congestion of the lymphatics, etc. in the lower extremities.
- Photographic documentation according to the problem zone: images taken from the front, side and from behind with the patient standing.

---

### **Surgical Planning**

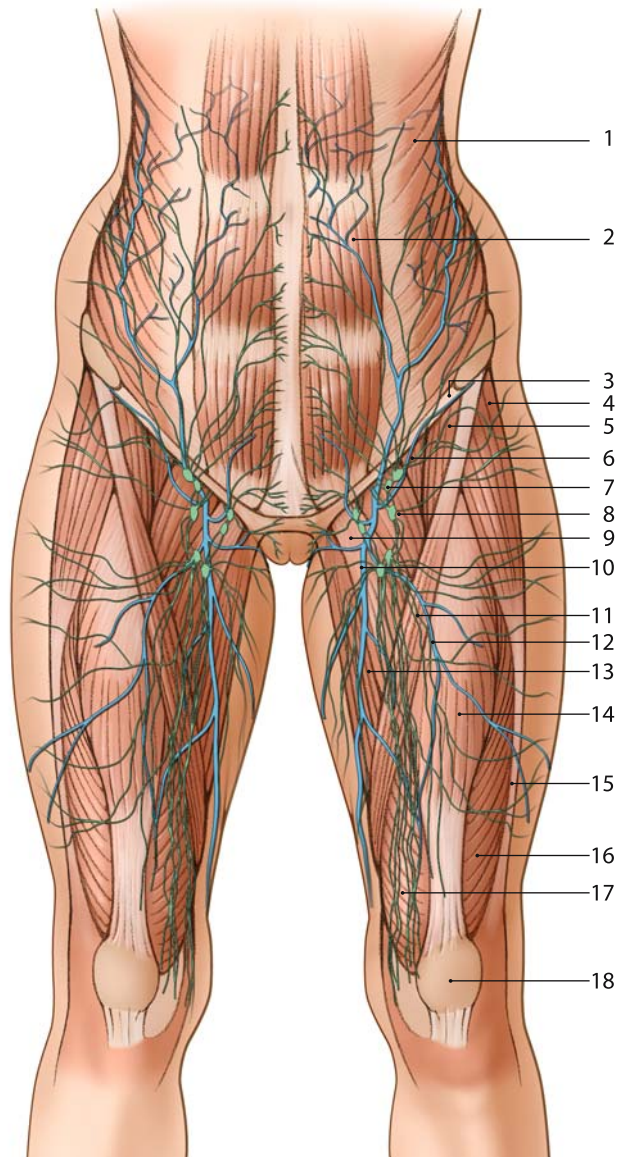
The operation enables deposits of fat to be reduced in a defined area of the body surface that cannot be reduced by dietary measures or sporting activity alone. Surplus fat is removed by suction in order to reduce the thickness of the fatty layer of the skin. The amount of fat removed is limited by the loss of body fluids and blood. For this reason liposuction is not a procedure for reducing general obesity.

On the day before the operation the surgeon discusses with the patient in detail which changes he or she wants and how this will be achieved. The areas to be removed by suction and the tumescence borders are marked exactly. In order to keep the operation risk as low as possible the patient should be made aware that he or she should not take any anticoagulants such as acetylsalicylic acid before the operation. The patient should also not smoke before the operation as this causes a reduction in perfusion. The risk of blood clots forming in the body also increases if the patient is taking contraceptives. In such cases the patient should stop smoking 2 weeks before the procedure and for the duration of the wound-healing period at the very least.

Intraoperative single-shot infection prophylaxis should be carried out with 2 g cefaclor and inpatient treatment and thrombosis/embolism prophylaxis before the operation and for 1 day after the operation with one ampule of fractionated heparin s.c. A special girdle should be fitted.

#### **• Anatomy of Liposuction of the Abdomen, Hips, Thighs**

Liposuction of the abdominal/hip region is the most frequently requested procedure, particularly by men. Only individual zones should ever be treated with liposuction, i. e., abdomen/hips or outer and inner thighs and buttock region (saddle area), as first the amount of tumescence that can be injected is limited (maximum 6 l) and second the procedure would be too stressful for the patient. As the navel region is particularly sensitive, a lot of tumescence must be used here. Liposuction of both hips or the upper and lower abdomen is carried out in a fan shape with the patient frequently changing position. Liposuction should be carried out carefully in the upper abdominal area, and a thin layer of fat should be left below the skin, as otherwise dimples will form and there can be loose skin.



### Anatomical Overview

- |                                     |                                       |
|-------------------------------------|---------------------------------------|
| 1. M. obliquus ext. abdominis       | 10. Long saphenous vein               |
| 2. M. rectus abdominis              | 11. M. sartorius                      |
| 3. Inguinal ligament                | 12. Saphenous vein, lateral accessory |
| 4. M. tensor fasciae latae          | 13. M. gracilis                       |
| 5. M. iliacus                       | 14. M. rectus femoris                 |
| 6. M. iliopsoas                     | 15. Iliotibial tract                  |
| 7. Superficial inguinal lymph nodes | 16. M. vastus lateralis               |
| 8. M. pectineus                     | 17. M. vastus medialis                |
| 9. M. adductor longus               | 18. Patella                           |



---

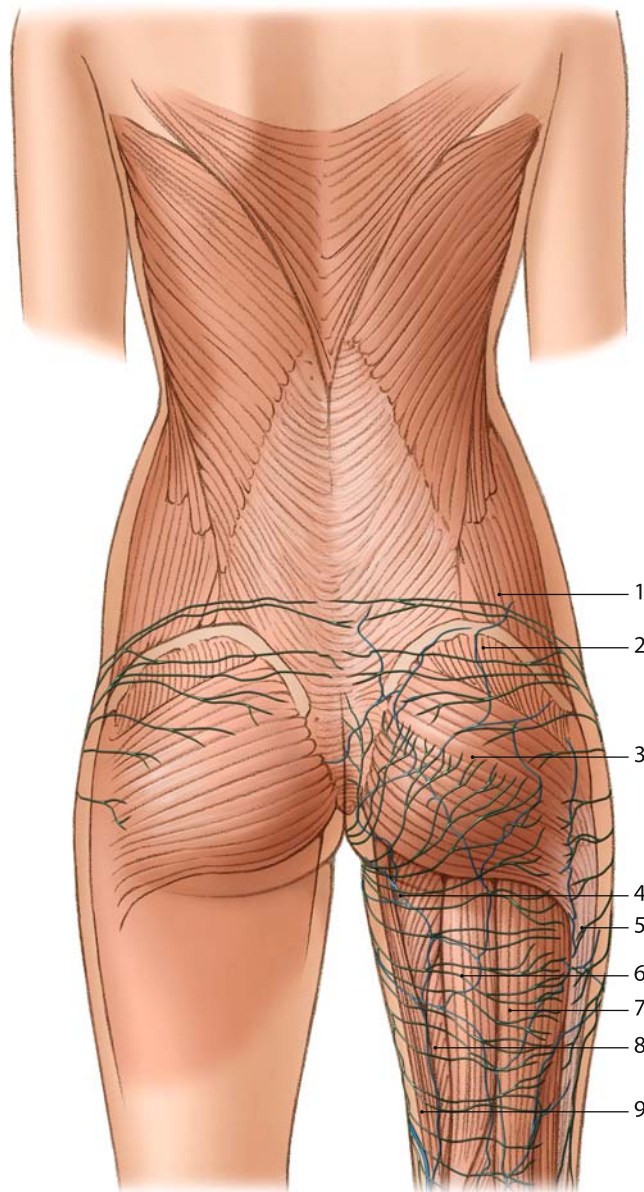
### **Anatomy of Liposuction of the Hips, Back, Thighs, Buttocks (Body Contouring)**

Liposuction of the so-called saddle area is the procedure requested most by women (body contouring of the hips, the lateral and medial sides of the thighs, buttocks). After the fat deposits have been marked precisely, an aesthetic result is achieved by carrying out liposuction homogeneously through 360° without the formation of dimples, by changing the patient's position on the operating table, and by checking again at the end of the operation, with the patient standing up, whether the contours have been suctioned well. The more experienced a surgeon is, the more he or she can remove. Novices must be very cautious and restrained, as dimples are more difficult to correct than residual deposits of fat, which can be removed without any problems after 6 months.

Successful liposuction of the back can only be achieved if tunneling is carried out cautiously using a low-level vacuum (maximum 0.4 at), leaving a layer of fat on the subcutaneous tissue, and through a fibrotic/tightening effect being achieved by the tunneling.

Caution must also be exercised when carrying out liposuction of the buttock region since if too many fat cells are removed, dimples can form and there can be loose skin.

Modeling of the hips and the medial and lateral sides of the thighs can be achieved very successfully using liposuction, as the skin here generally produces a good tightening effect.



### Anatomical Overview

1. M. obliquus ext. abdominis
2. Gluteal fascia
3. M. gluteus maximus
4. M. adductor magnus
5. Iliotibial tract
6. M. semitendinosus
7. M. biceps femoris
8. M. semimembranosus
9. M. gracilis

---

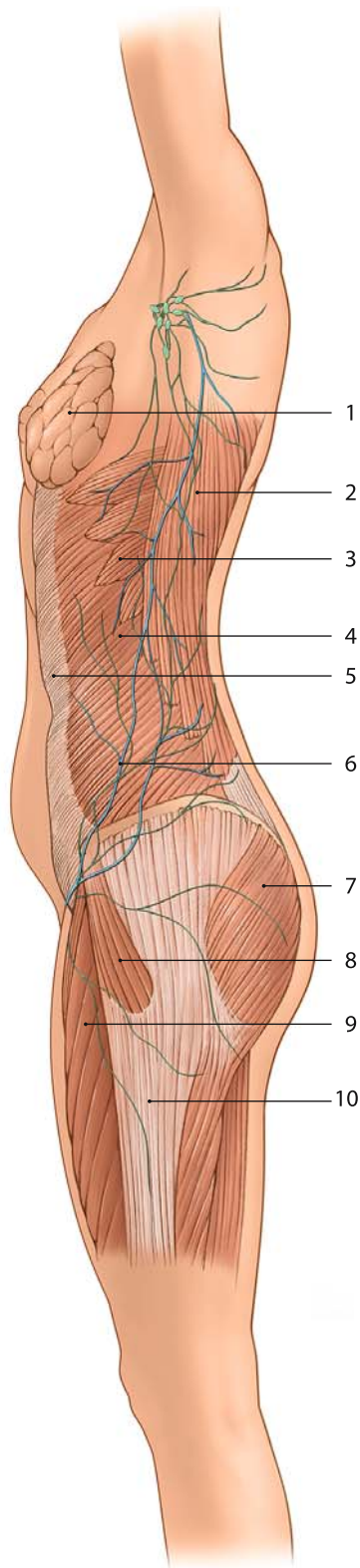
### **Anatomy of Liposuction of the Axilla, Chest, Hips, Lateral Side of the Thighs**

In principle, liposuction can be carried out in any area of the body where there are aesthetically intrusive deposits of fat. This is the main advantage of the tumescence technique.

Because of the anatomical situation of the axilla, the surgeon has to be very careful. It is better to leave out the axillar region to prevent injuries.

#### **Anatomical Overview**

1. Breast
2. M. latissimus dorsi
3. M. serratus anterior
4. M. obliquus ext. abdominis
5. Sheath of rectus abdominis
6. Superficial circumflex iliac vein
7. M. gluteus maximus
8. M. tensor fasciae latae
9. M. vastus lateralis
10. Iliotibial tract



### • Anatomy of Liposuction of the Medial/Lateral Side of the Thighs, Knee

The contours of the lower extremities are very well suited to liposuction, in particular the deposits of fat on the lateral and medial sides of the thighs and the knees. Before the operation varicosity of the long and short saphenous veins and any lymphatic diseases must be taken into account.

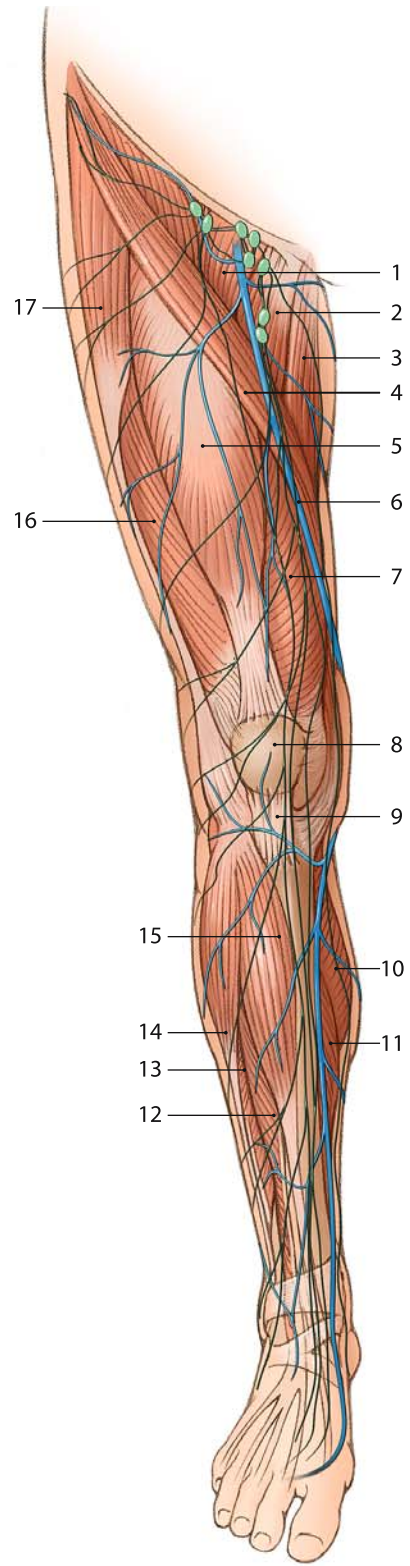
The thighs must not be skeletonized, i. e., all the fat must not be removed, as this leads to a very poor cosmetic result. A sufficient subcutaneous layer of fat must be left.

As long as pure fat is appearing; the procedure can be continued without risk. When the fat becomes mixed with tumescence solution and finally only tumescence solution appears in the tube; the procedure should be ended in order to prevent skeletonization and the formation of dimples.

Liposuction in this region is shown in detail on the DVD.

#### Anatomical Overview

1. M. pectineus
2. M. adductor longus
3. M. gracilis
4. M. sartorius
5. M. rectus femoris
6. Long saphenous vein
7. M. vastus medialis
8. Patella
9. Patellar ligament
10. M. gastrocnemius
11. M. soleus
12. M. extensor digitorum longus
13. M. peroneus brevis
14. M. peroneus longus
15. M. tibialis anterior
16. M. vastus lateralis
17. M. tensor fascia latae



## Anatomy of Liposuction of the Medial Part of the Thighs, the Knees, Calves, Ankles

Liposuction of the lower extremities is usually carried out as two separate procedures: first the lateral and medial sides of the thighs and the knee area, then the calf and ankle region. If only the medial side is to be altered, the medial side of the ankle, calf, knee, and thigh can be treated in one procedure; particular attention must be paid to thrombosis and embolism prophylaxis during this procedure. The patient should be mobilized immediately after the operation.

### Anatomical Overview

- |                      |                               |
|----------------------|-------------------------------|
| 1. M.adductor magnus | 7. Long saphenous vein        |
| 2. M.gracilis        | 8. M.gastrocnemius            |
| 3. M.semitendinosus  | 9. M.soleus                   |
| 4. M.rectus femoris  | 10. M.flexor digitorum longus |
| 5. M.sartorius       | 11. Patellar ligament         |
| 6. M.vastus medialis | 12. Patella                   |

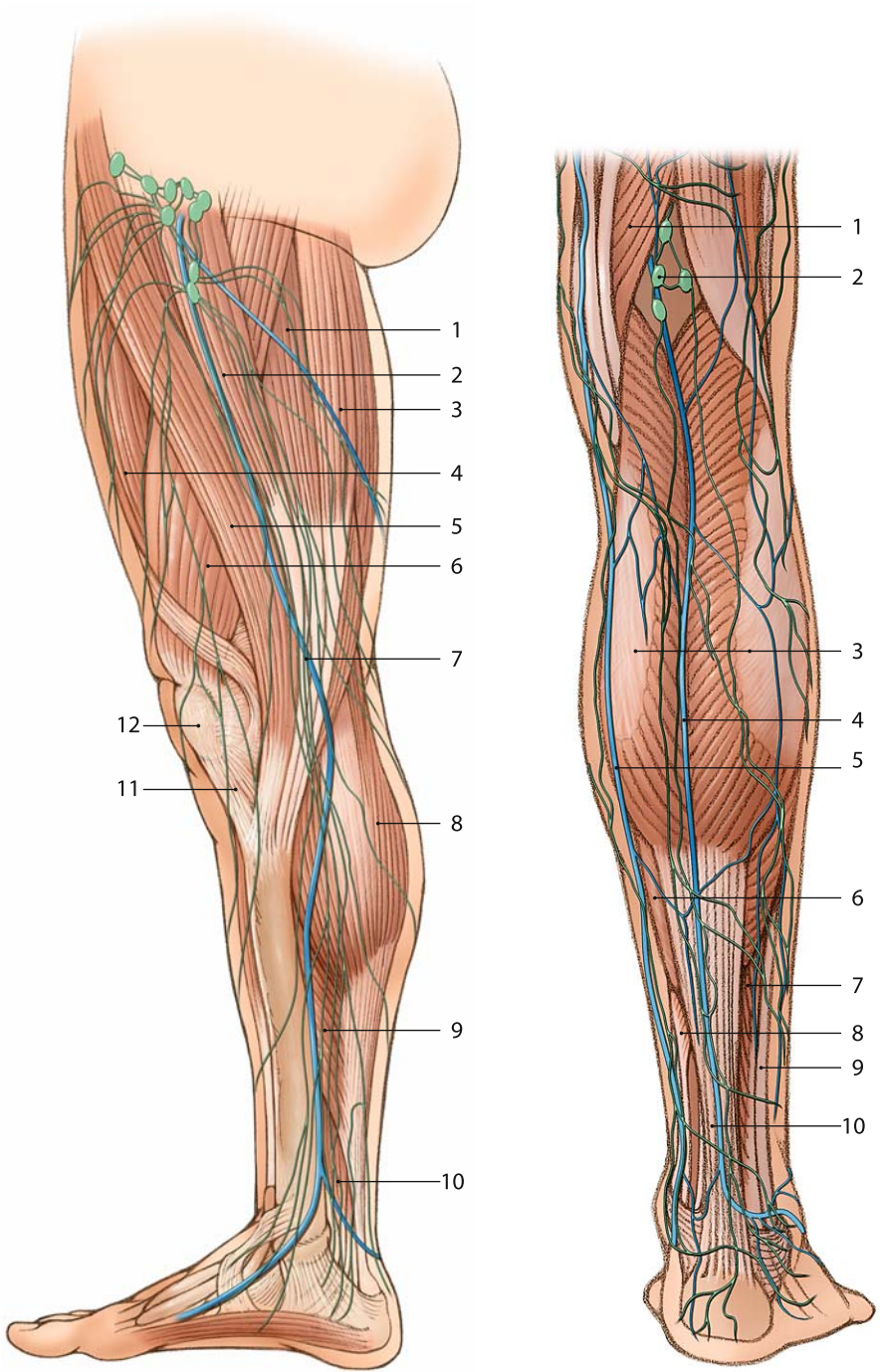
## Anatomy of Liposuction of the Calf and Ankles

Unfortunately, fat calves often result from muscular hypertrophy. When performing liposuction of the calves the surgeon must have a lot of experience and be very careful to avoid causing dimples. For this reason caution must be exercised during liposuction of the calves and ankles. A 2-mm cannula with a vacuum that is not too high must be used (no higher than 0.6 at). After the operation immediate mobilization and the fitting of a compression girdle are advisable.

### Anatomical Overview

- |                          |                              |
|--------------------------|------------------------------|
| 1. M.semimembranosus     | 6. M.soleus                  |
| 2. Popliteal lymph nodes | 7. M.flexor hallucis longus  |
| 3. M.gastrocnemius       | 8. M.flexor digitorum longus |
| 4. Short saphenous vein  | 9. M.peroneus longus         |
| 5. Long saphenous vein   | 10. Achilles tendon          |





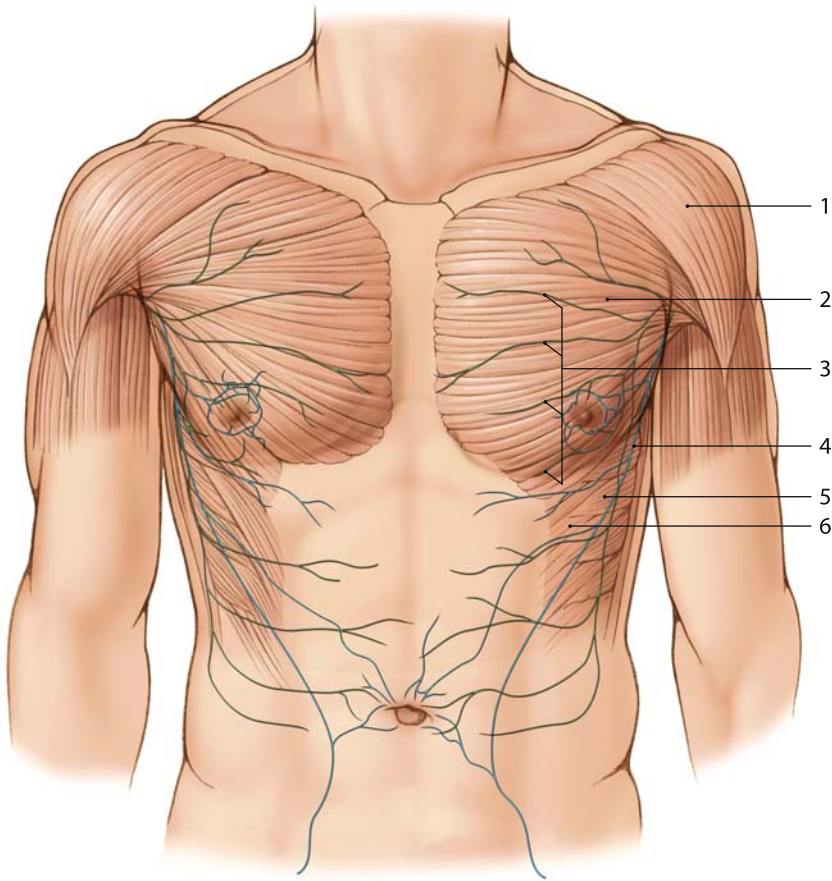


---

### **Anatomy of Liposuction of the Breast, Axilla, Upper Arms**

Gynecomastia in men can be treated very well by means of tumescent liposuction. Preoperative investigation of the breast area by means of mammography or ultrasound is necessary.

The entire breast area can be removed by suction by means of two small incisions that are not visible. Axillary fat can be removed during the same operation if required.



**Anatomical Overview**

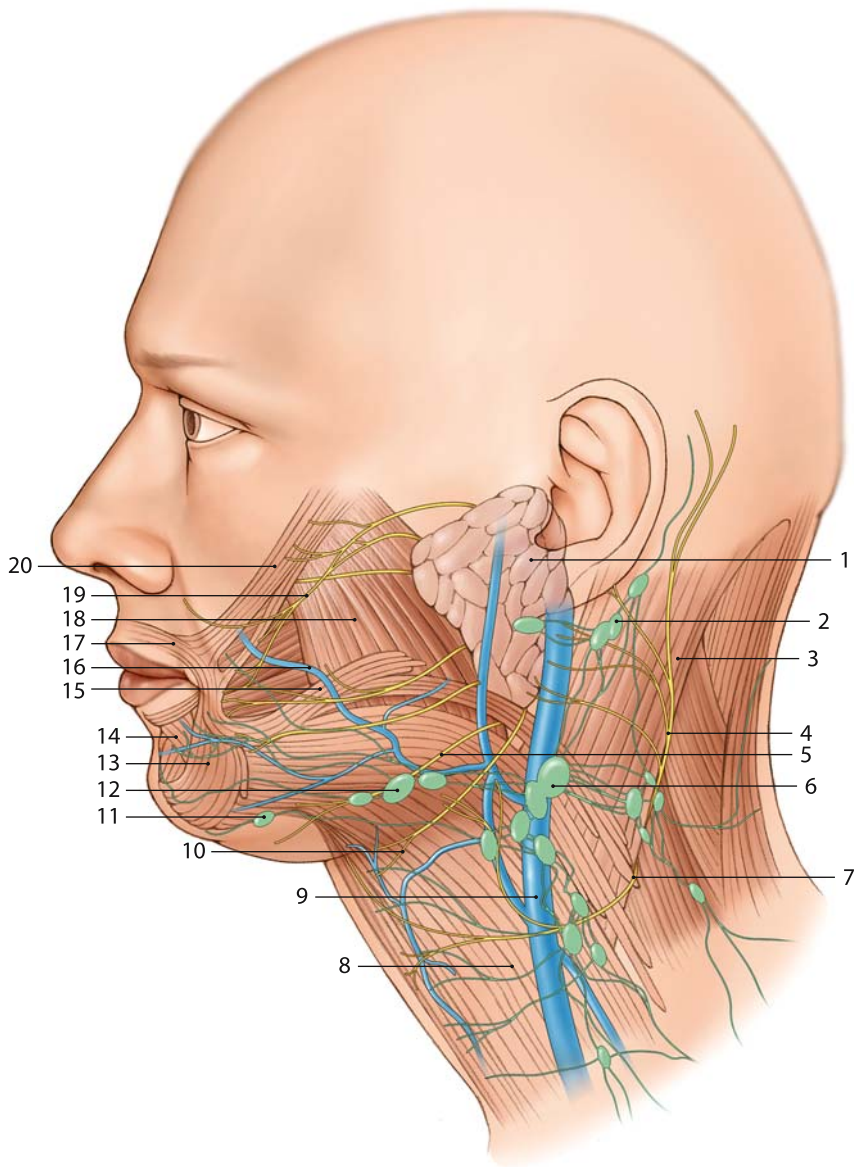
- |                                  |                          |
|----------------------------------|--------------------------|
| 1. Deltoid muscle                | 4. Lateral thoracic vein |
| 2. M. pect. major                | 5. M. serratus anterior  |
| 3. Superficial lymphatic vessels | 6. M. obliquus ext.      |

---

- **Anatomy of Liposuction of a Double Chin**

Two small submental incisions and a retroauricular incision are made. With a quantity of tumescence solution of 300–500 ml the entire submental region extending deep into the neck area can be removed by liposuction. If required, the lateral cheek areas can also be removed. The procedure is often combined with a facelift.

After the operation a compression dressing is worn for approximately 1 week so that the submental skin that has been detached in the neck area can adapt after liposuction to the areas where fat has been removed. Just by tunneling with the 2 mm cannula, scar contractions occur, which result in a tightening effect.



### Anatomical Overview

- |   |                                   |
|---|-----------------------------------|
| 1. Parotid gland                            | 11. Submental lymph nodes         |
| 2. Mastoid lymph nodes                      | 12. Submandibular lymph nodes     |
| 3. Sternocleidomastoid muscle               | 13. M. depressor anguli oris      |
| 4. Great auricular nerve                    | 14. M. depressor labii inferioris |
| 5. Mandibular margin branch                 | 15. M. risorius                   |
| 6. Lateral superficial cervical lymph nodes | 16. Facial vein                   |
| 7. Transverse nerve of the neck             | 17. M. orbicularis oris           |
| 8. M. platysma                              | 18. M. masseter                   |
| 9. External jugular vein                    | 19. Buccal branch                 |
| 10. Cervical branch                         | 20. M. zygomaticus major          |

### • Mechanical and Manual Tumescence

Tumescence solution can be applied either manually with an injection syringe or mechanically with a pump. In the manual technique the injection syringe is connected to the tumescence solution via a one-way cock. The manual technique requires a lot of time and effort and has the same results as the mechanical injection of solution via a pump. In this technique the pump is connected with the system via a three-way or six-way cock so that the tumescence solution can be applied evenly and homogeneously via three or six cannulas, also saving time.

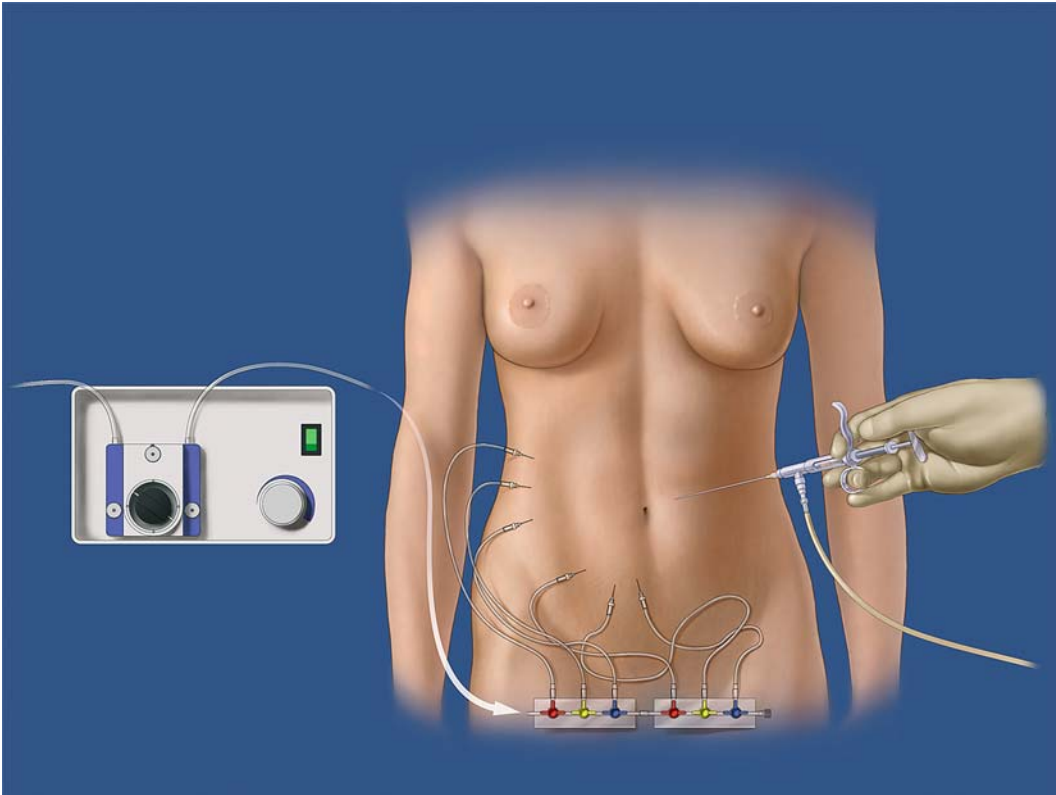
For liposuction in the abdominal/hip area about 6 l of tumescence solution is needed. Manual application of the solution takes 90 min; application using the pump takes 45 min.

After applying all the tumescence solution, it should be given at least 30 min to take effect. During this time disinfection and sterile draping of the patient are carried out. Mang's tumescence solution (0.9% NaCl 3,000 ml, 1% Prilocaine 1,500 mg = 150 ml, epinephrine 3 mg, Na HCO<sub>3</sub> 8.4% 30 mEq, triamcinolone acetonide 30 mg) should still be limited to 6 l for patients weighing up to 80 kg. If the patient weighs more than this and is in good general condition, the amount of tumescence can be increased to 7 l.

The best temperature for the solution is 30 °C (warm cabinet).

The prepared tumescence solution should be injected within 1 h of preparation. The solution must only be prepared (sterile preparation) by a qualified person supervised by a doctor.

The surgeon must apply the tumescence himself/herself, as in so doing he/she can see exactly how much tumescence solution flows into each fat deposit. He/she can therefore already begin to estimate during tumescence from which regions the most fat cells will need to be removed. Tumescence solution that has been opened must not be reused under any circumstances.



Mechanical

Manual

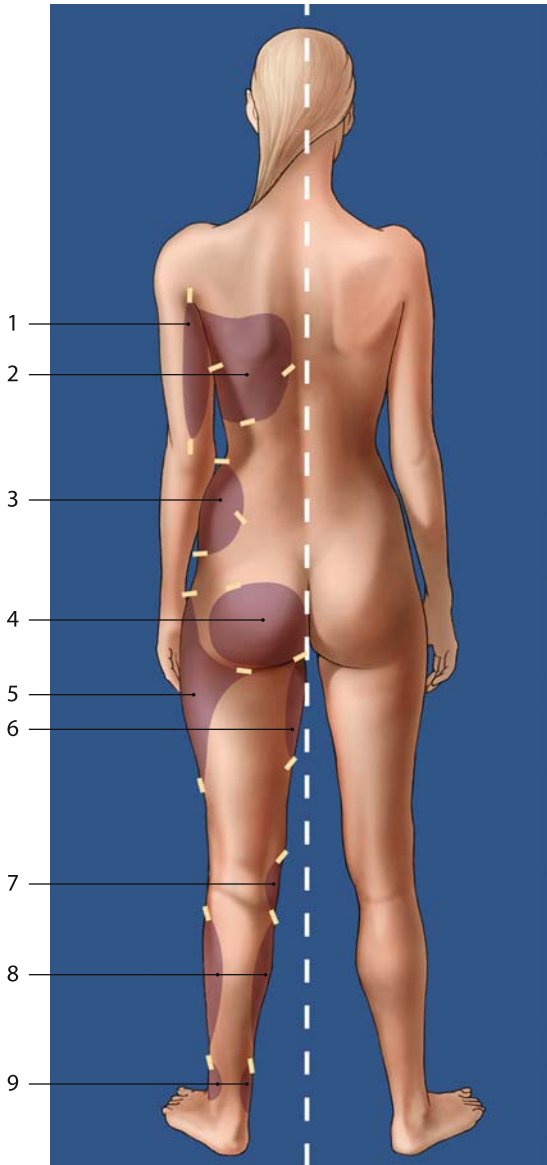
---

### Location of the Incision Sites from the Rear

- Shoulders: Three incisions. At the lateral, medial and caudal ends of the collection of fat.
- Buttocks: Three incisions. One in the upper quadrant and two in the lateral and medial parts of the gluteal fold.
- When treating a problem zone a general rule of thumb is that at least three incisions are necessary, one of which should be at the lowest point to allow the tumescence solution to drain. This prevents congestion as well as prolonged swelling and infection. If it becomes apparent during liposuction that another incision is necessary, this can be made without problem, as these are microincisions that will not be visible after 6 months. Instead of sutures, Steri-Strips are applied to the incisions for 8 days.

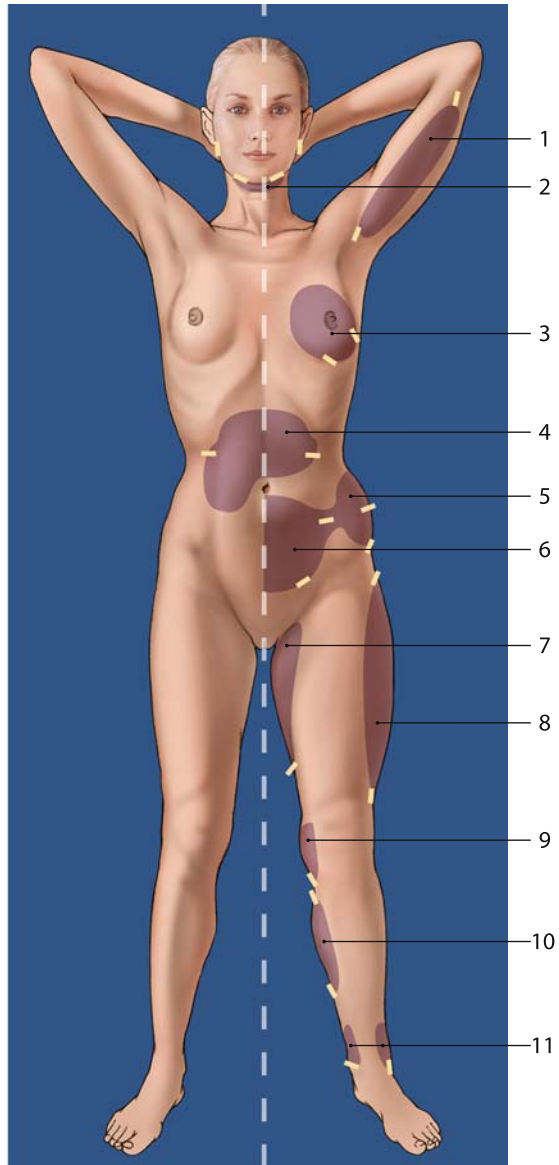
### Location of the Incision Sites from the Front

- Submental region: Four incisions – two in the submental area, two on the earlobes.
- Upper arms: Lateral condyle and ventral muscle belly of the biceps muscle.
- Breast: At three o'clock laterally, at six o'clock caudally where the collections of fat protrude.
- Upper abdomen: Three fingerwidths caudal to the costal margin on each side.
- Hips: Four incisions divided between the individual quadrants.
- Lower abdomen: Four incisions, two in the bikini area and two at the level of the navel half-way between the iliac crest and the navel.
- Lateral side of the thighs: Three incisions, one below the trochanter, one at the lowest point of the collection of fat and one in the gluteal fold.
- Medial side of the thighs: Two incisions, one incision midway between the inguinal region and the knee at the lowest point of the collection of fat and one dorsally in the gluteal fold.
- Knees: Two incisions located cranially and caudally to the fat deposit.
- Calves: Four incisions. Two lateral, two medial.
- Ankles: Three incisions. Two dorsal (caution: Achilles tendon!), one ventral at the area of attachment of the tibialis anterior tendon.



- 1
- 2
- 3
- 4
- 5
- 6
- 7
- 8
- 9

- 1. Axilla, upper arm
- 2. Shoulder, back
- 3. Hips
- 4. Bottom
- 5. Outer thigh
- 6. Inner thigh
- 7. Knee
- 8. Calves
- 9. Ankles



- 1
- 2
- 3
- 4
- 5
- 6
- 7
- 8
- 9
- 10
- 11

- 1. Upper arms
- 2. Submental region
- 3. Chest
- 4. Upper abdomen
- 5. Hips
- 6. Lower abdomen
- 7. Inner thigh
- 8. Outer thigh
- 9. Knee
- 10. Calves
- 11. Ankles



---

## **Schematic Diagram of Mang's Tumescent Liposuction Technique**

### **Cross-Section of the Skin Before Tumescence**

The diagram shows normal fat cells, embedded in the infrastructural connective tissue (ICT). In dry liposuction under anesthesia, these connective tissue structures are largely destroyed, causing blood loss, hematomas, and the formation of dimples under the skin. This is avoided by using the tumescence technique.

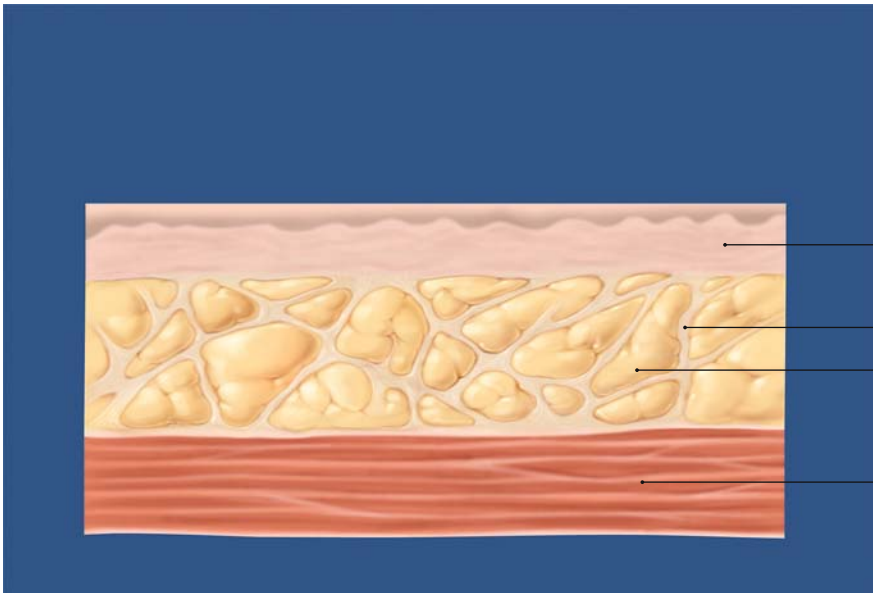
---

### **Cross-Section of the Skin Following Tumescence**

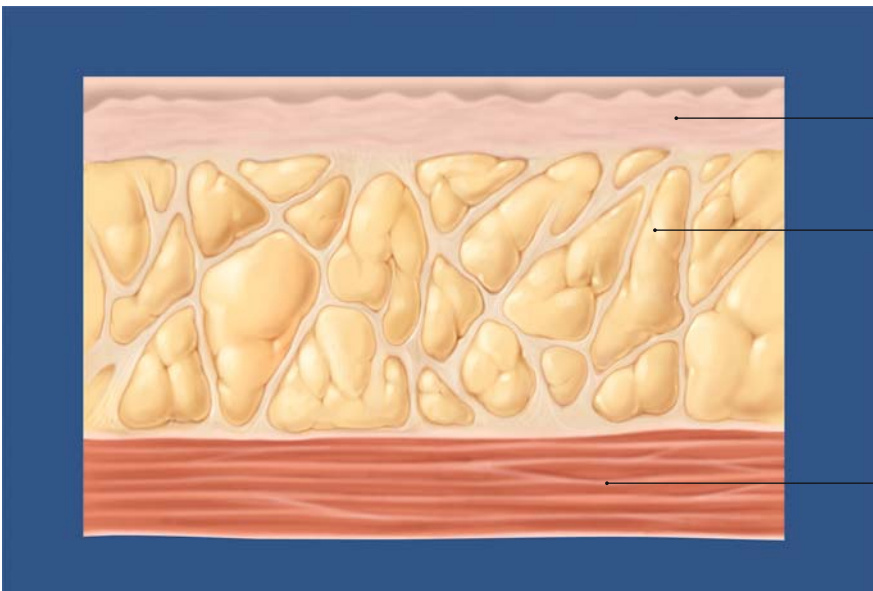
Tumescent local anesthesia (TLA) refers to the infiltration of the skin and subcutis with a large quantity of very diluted local anesthetic (below 0.1%) with adrenalin (less than 1 mg/l) and  $\text{NaHCO}_3$  until the tissue swells sufficiently.

TLA results in good anesthesia and hemostasis and means that the patient is responsive and mobile. Using TLA the procedure can be carried out without additional anesthesia.

Removing the tissue that is full of tumescence solution during liposuction does not cause any blood loss and, in particular, preserves the surrounding tissue.



1. Epidermis
2. Infrastructural supporting tissue
3. Normal fat cells
4. Muscles



1. Epidermis
2. Tumefied fat cells
3. Muscles

---

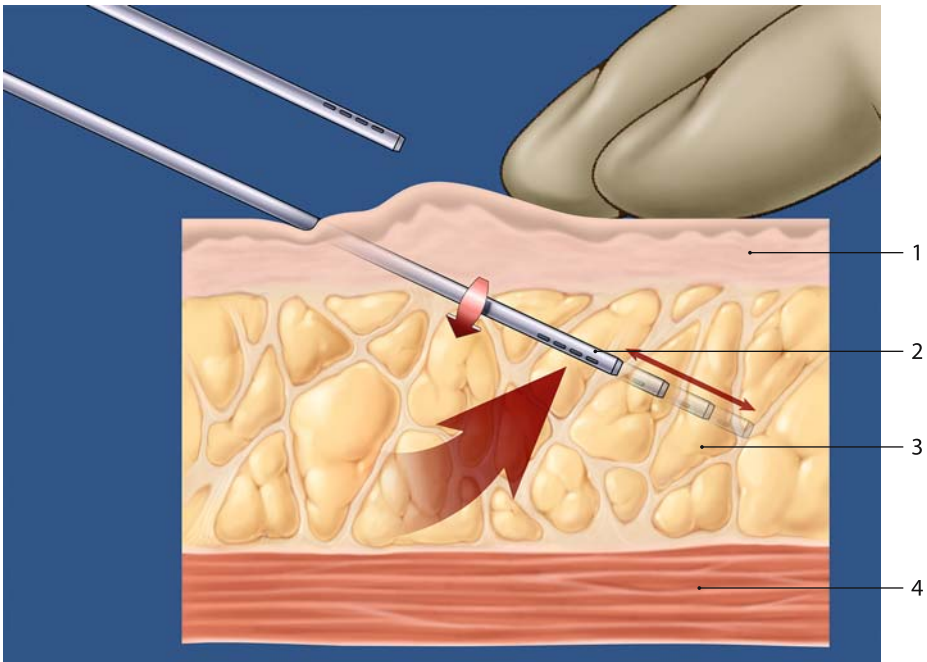
### **Cross-Section of the Liposuction Technique**

Liposuction is carried out with 2.0–4.0 mm cannulas. Because the fat cells are hygroscopic they are softened by tumescence and can therefore be removed by suction atraumatically and selectively without damaging the surrounding tissue (infrastructural supporting tissue). With a movement similar to that of a violin bow, moving constantly in a 180° radius and never stopping in one place, the entire area of fat is removed by suction, starting at the bottom and working upwards towards the epidermis. The skill is in leaving a thin layer of fat below the epidermis so that dimples are not formed later and a good tightening effect is achieved.

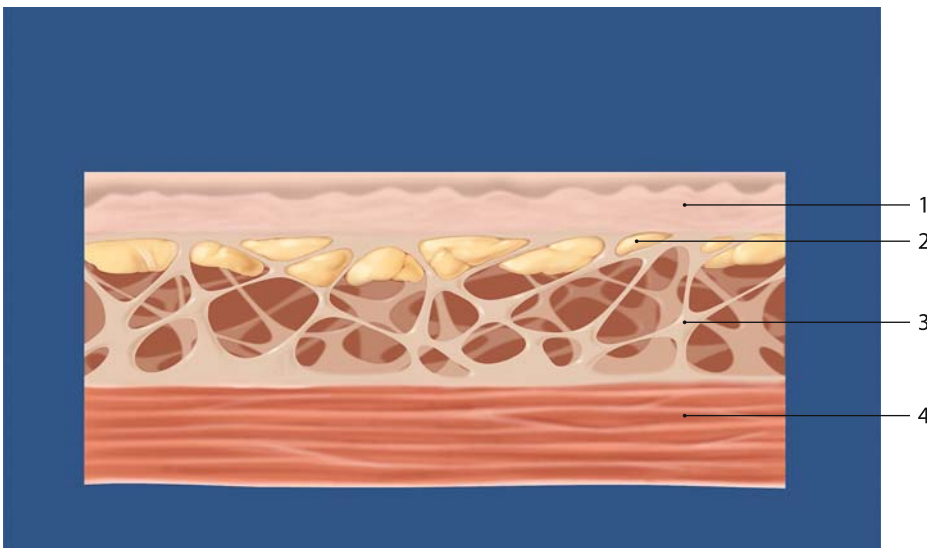
---

### **Cross-Section of the Tissue 6 Months After Liposuction with Preservation of the Infrastructural Connective Tissue (ICT)**

Six months after liposuction using the tumescence technique and cannulas less than 4.0 mm in size you can see that the infrastructural connective tissue has been preserved.




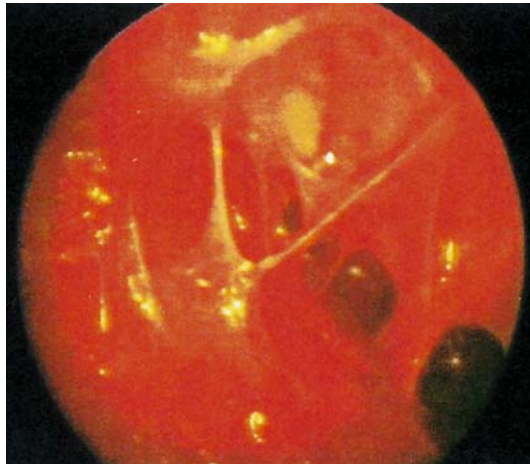
1. Epidermis
2. 2.0 – 4.0 mm cannula
3. Tumefied fat cells
4. Muscle

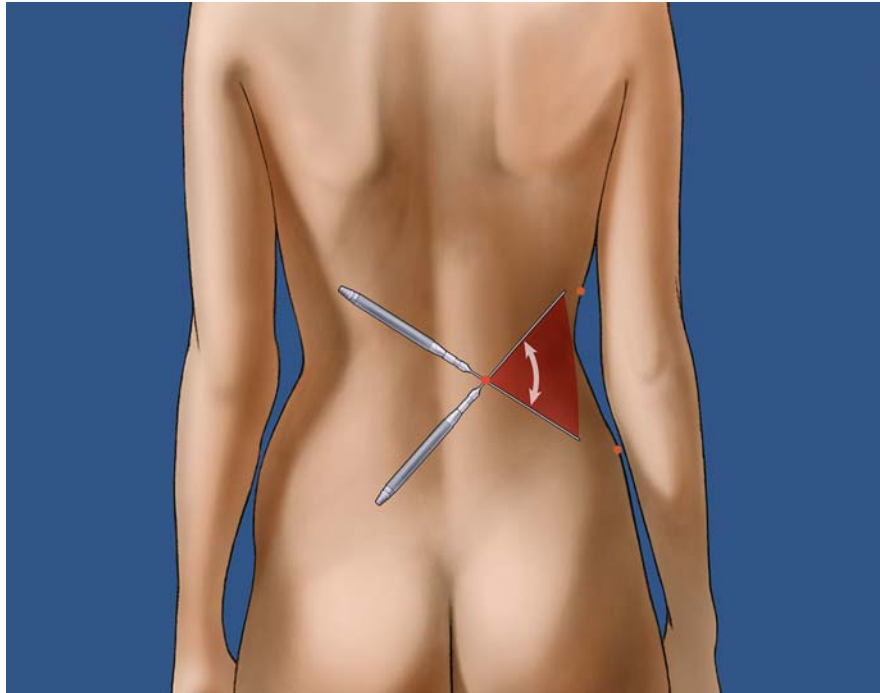


1. Epidermis
2. Film of fat
3. Infrastructural supporting tissue (ISM)
4. Muscles

The endoscopic image shows the intraoperative findings. The most important point when carrying out liposuction is that a so-called fat film is preserved in the upper section and that the connective tissue below it is preserved. This causes the “chewing gum” effect whereby the undamaged connective tissue septa contract after liposuction, tightening the skin.

You can see from the aspirate, which contains almost entirely fat with no blood, that only a small amount of tissue has been destroyed.





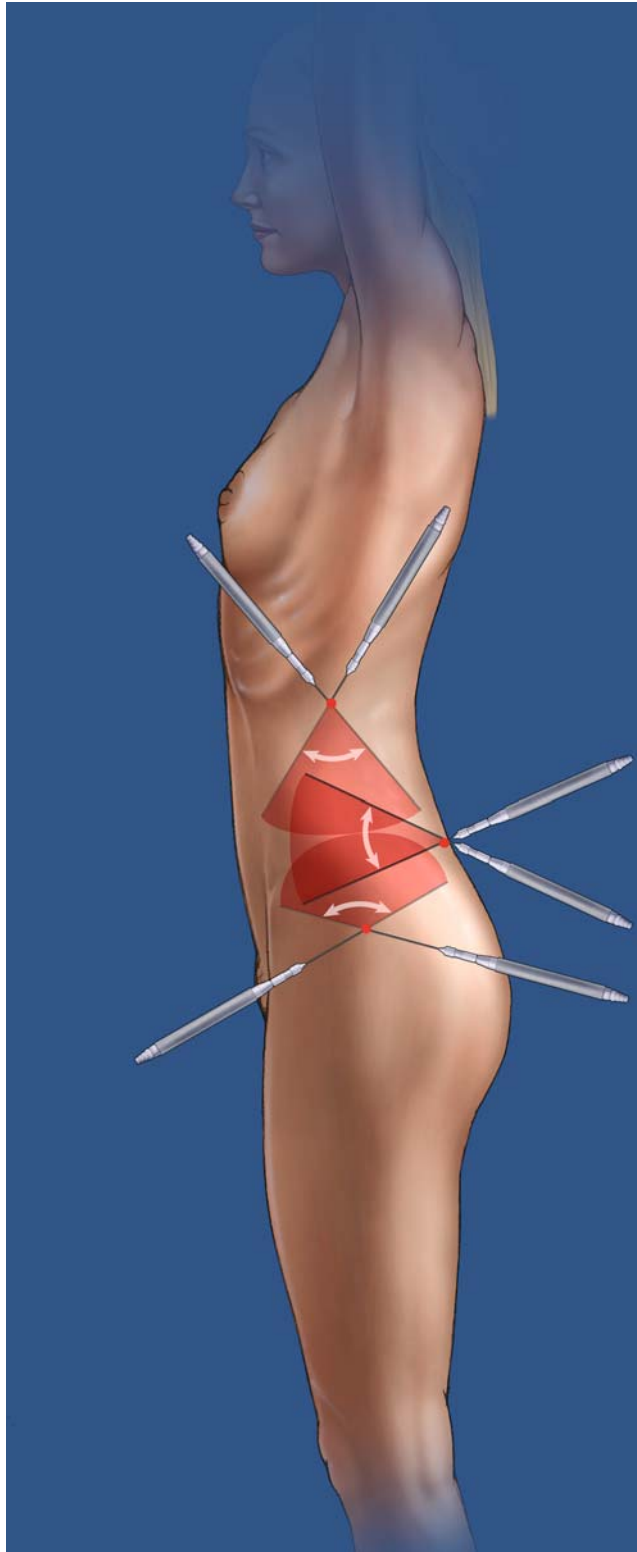
Fan-shaped suction of regions ( $>90^\circ$ )

### Technique

- The full extent of each fat deposit is marked precisely on the standing patient. The problem zones must be marked with small circles, increasing in size until they reach the edges. By doing this you can start to plan before the operation where the largest quantities need to be removed.

### Disinfection

- Disinfection is carried out before tumescence.



Fan-shaped suction of regions (>90°) from several positions



---

### Manual Liposuction

- The injection into the adipose tissue can be done by hand, in which case the quantity of solution used must be constantly checked and attention must be paid to achieving an even distribution. This method takes about 1.5 h.

### Mechanical Liposuction

- The injections can also be carried out with an electric pump. When doing this, you must always ensure that the cannulas are in the correct position. The pump transfers the tumescence solution via a distribution system (3–6 connectors); it must always be ensured that the solution is injected evenly and not too rapidly.

As the patient is responsive and mobile, tumescence/liposuction of any part of the body is possible. Tumescence can be discontinued when the areas to be treated show the so-called blanching effect, i.e., are white and elastic. A maximum of 6 l of solution should be injected in order to avoid cardiac or neurological irritation. The process lasts approximately 45 min. Tumescence and liposuction should be carried out with anaesthesiology monitoring and stand-by.

### Procedure

- After thorough disinfection, again an incision is made with a size 11 scalpel. This incision is not sutured later and cannot be seen. This process is completely free of pain because of tumescence. The liposuction cannulas can be inserted without much pressure, and the openings should point towards the subcutis. At the beginning of the procedure the cannula should not be more than 4.0 mm. At the end of the procedure, after the majority of the fat has been removed, a 2.0–3.0 mm cannula is used for delicate modeling. The tumescence technique allows the procedure to be carried out with almost no bleeding.
- Tumescence allows the tissue to be tunneled without much effort. Novices should not initially use the assisted system, but should carry out liposuction manually in order to get a feel for the tissue. In order to achieve an even result, the same amount must be removed from all sides at angles of 90, 180 and 360°. The fat should be removed using smooth, constant, forward and backward movements, similar to the movement of a violin bow. The fat should always be removed from within the predetermined level and in a fan shape. Several incisions are necessary to reach the problem zones well, and one of these should always be at the lowest point of the problem area to allow the tumescence to drain. As long as

pure fat appears the procedure can be continued without risk. When the fat becomes mixed with tumescence solution and then only tumescence solution appears, the procedure should be ended in order to avoid skeletonization and the formation of dimples. Ideally, a “fat film” should be left directly under the skin during liposuction. Liposuction should therefore always be carried out from the deepest layers to the upper ones.

- Because the procedure is carried out under local anesthesia it is possible for the patient to roll over; therefore, all areas can be reached easily and evenly. This is a particular advantage for achieving homogeneous liposuction, as it brings about a tightening effect without the formation of dimples.
- Because the patient is mobile all problem areas on the face and the body can be treated. It should be ensured that suction is carried out evenly and in one plane in order to avoid contour irregularities. This is harder to even out than residual persistent deposits, which can be corrected without any problems.
- To make sure the wound is well drained, an incision must be positioned at the lower pole of the area to be removed during liposuction. Contouring can also be carried out from here. If the patient experiences pain, a strong, fast-acting analgesic can be given via the venous cannula. Synthetic opioids, e.g., piritramide (Dipidolor®), have proved effective in these circumstances.
- Liposuction should be carried out on an inpatient basis and requires a lot of experience. An experienced surgeon will preserve a thin layer of fat below the skin.
- When using the aspirator it is important that there is a constant vacuum of about 0.8 (Atmos Medizintechnik aspirator\*).

### Dressing

- After liposuction, Steri-Strips are applied to the insertion sites. The wounds are not closed further because of the desired drainage effect. The Steri-Strips can be removed by the patient after 8 days. The dressing is applied with the patient standing up. Absorbent pads take up the fluid produced in the first few days after the procedure. A compression girdle is worn for a few weeks after the operation. Antibiotic cover and thrombosis prophylaxis should be given.

\* Atmos Medizin Technik GmbH&Co KG, Ludwig-Kegel-Str. 16, 79853 Lenzkirch, Germany

---

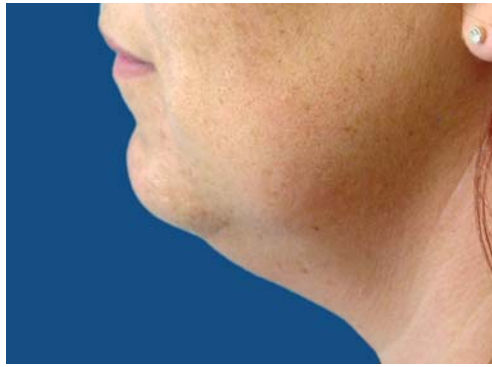### Aftercare

- The patient is monitored for 24 h after the operation, during which time he or she should move about as much as possible (1 h lying down, 20 min walking up and down in the room so that the tumescent fluid drains).
- On the 1st postoperative day the entire dressing is changed and a compression girdle is fitted before counteracts swelling and pain and to help adapt the skin to the changed contours of the body. This compression girdle also encourages the skin to tighten and should be worn for at least 4 weeks after the operation.
- Two weeks after the operation the skin can be treated with moisturizing body lotion, massaged gently on a daily basis into the areas of skin treated. Physical exertion, sport, and exposure to direct sunlight are permitted after 4 weeks.

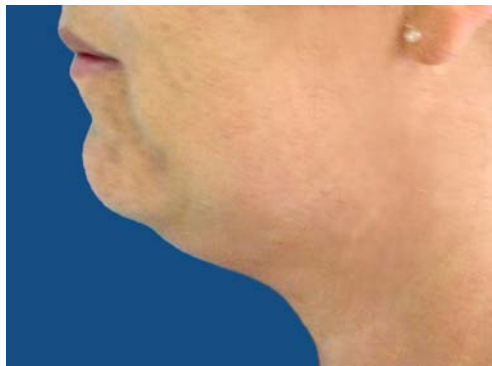We recommend training in the gym after liposuction. A “top body” or “washboard stomach” can normally only be achieved by liposuction in combination with strenuous physical training, not by liposuction alone.

With the help of liposuction, fat cells are permanently removed. Since the fat cells do not grow back, liposuction treatment produces a permanent effect. However, further changes to the shape of the body are possible. The results of the operation are dependent on the patient’s general health, the condition of the skin, the patient’s age and weight, and the hormonal content of the body, among other things. In particular, significant weight gain caused by nutrition will result in the layer of adipose tissue increasing again even in the treated area, as the remaining fat cells will fill out. Occasionally, wavelike unevenness or dimples become visible on the surface of the skin, but these usually reduce again within 6 months.

As with all aesthetic procedures, corrective operations may be necessary if the results of the treatment do not meet the patient’s expectations or if an unsatisfactory aesthetic result is produced because of wound-healing disturbances, infections, postoperative bleeding, etc.



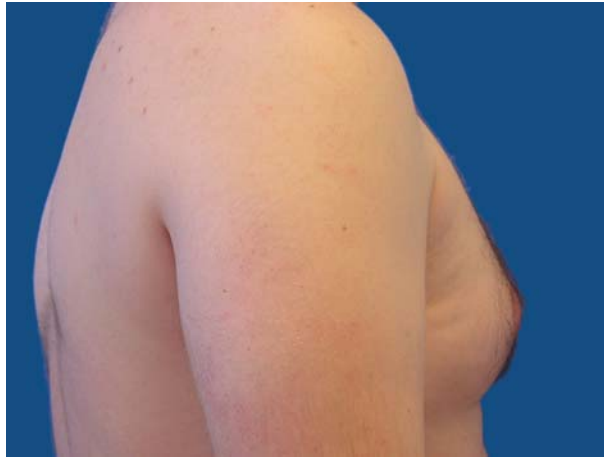
Before treatment



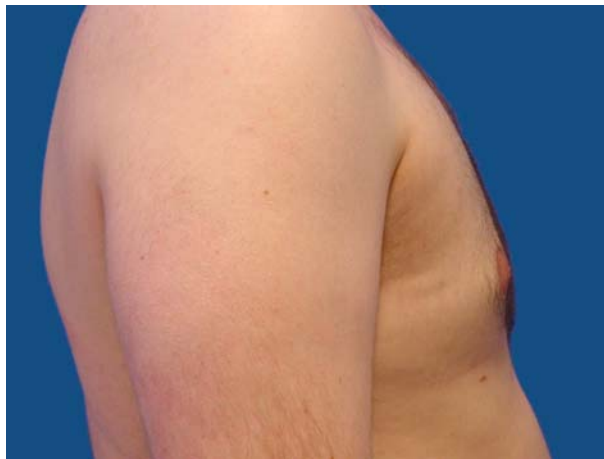After treatment

### Results

Patient I: Liposuction in the submental region of a 38-year old patient.  
Side view 12 months later.

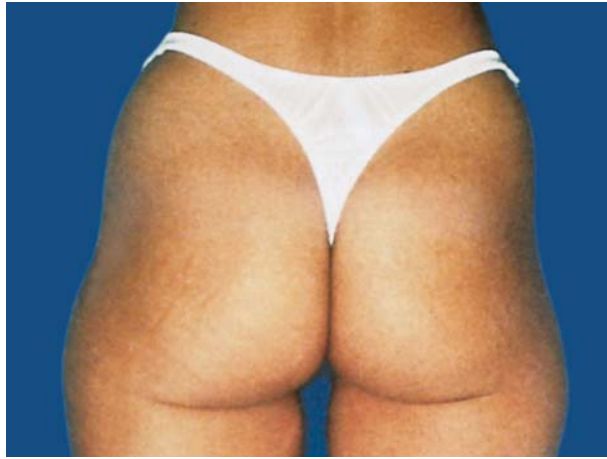

Before treatment

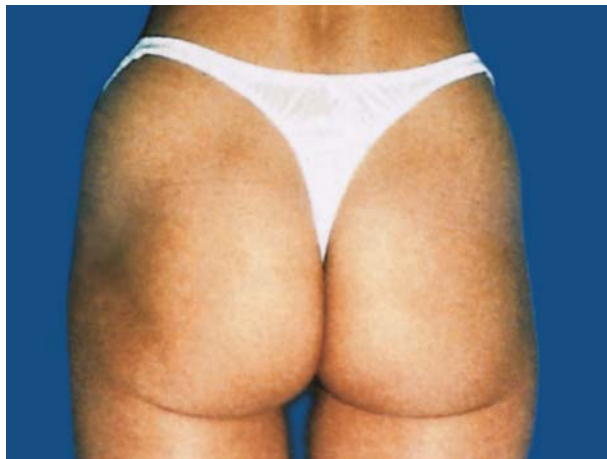

After treatment

Patient II: A major problem for men predominantly aged over 45 is deposits of fat in the chest area. Good, long-lasting results are obtained using the tumescence technique presented here. Side view 12 months later.

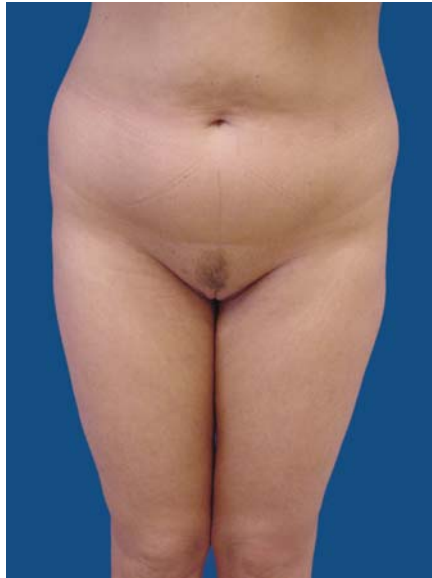

Before treatment

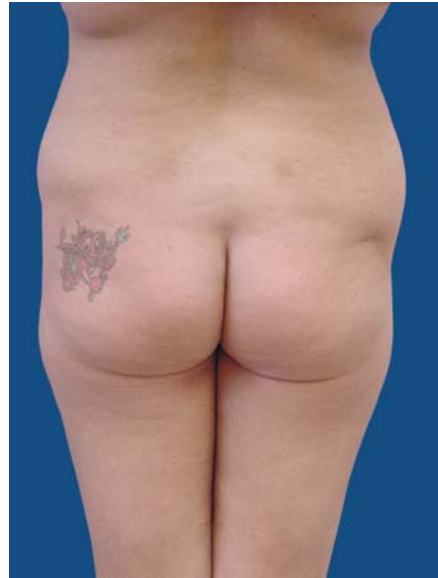

After treatment

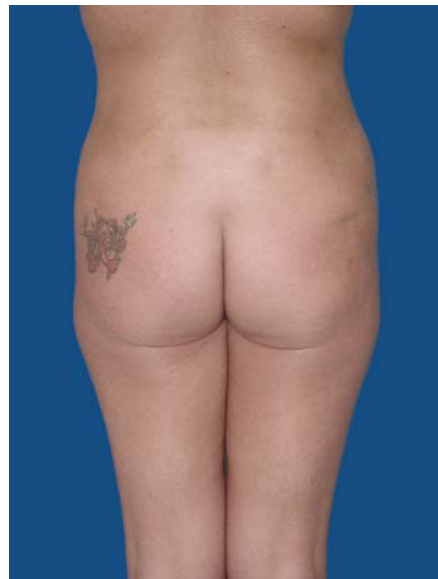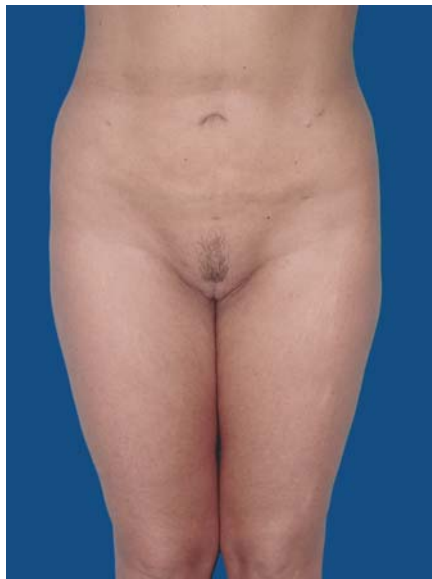Patient III: Saddle area before and 6 months after treatment.



Frontal view before the operation

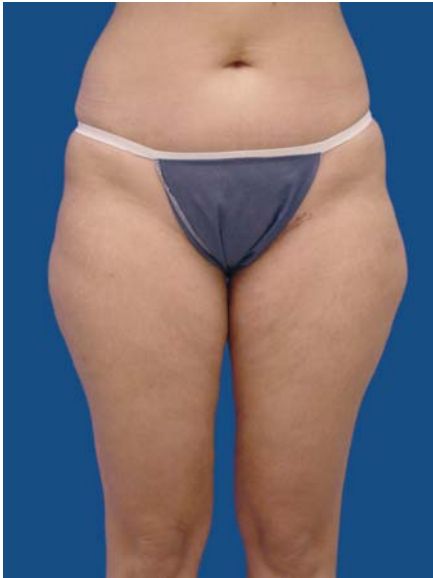

Posterior view before the operation

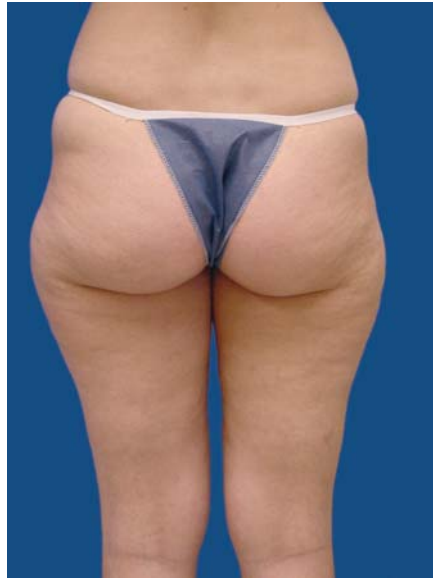

Frontal and posterior view 12 months after the operation

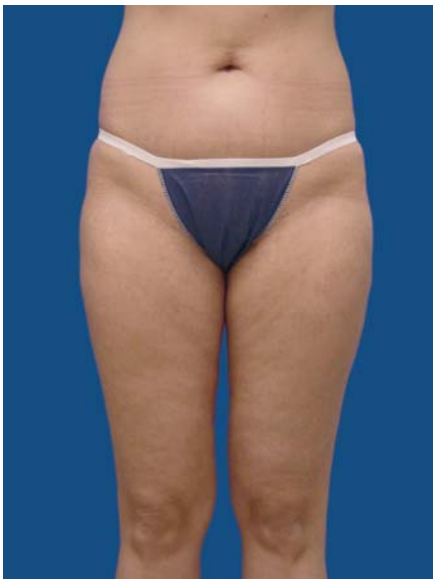Patient IV: A 39-year-old patient with collections of fat in the hip and abdominal areas, and 12 months after tumescent liposuction of abdomen, hips and mons pubis.



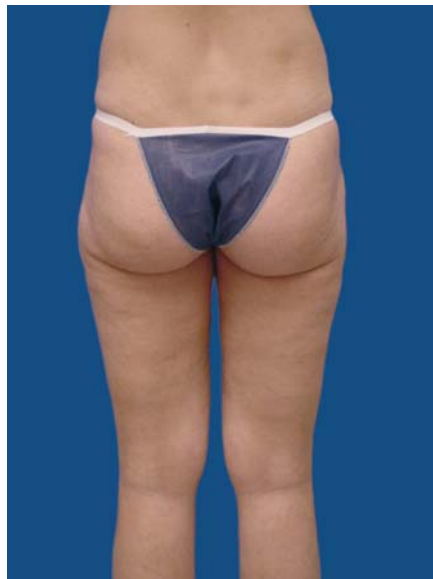Frontal view before the operation



Posterior view before the operation



Frontal view after the operation



Posterior view after the operation

Patient V: Patient with collections of fat around the hips, lateral and medial sides of the thighs and the buttock region, and view after modeling of the abdomen, hips and buttocks, 12 months after the operation.

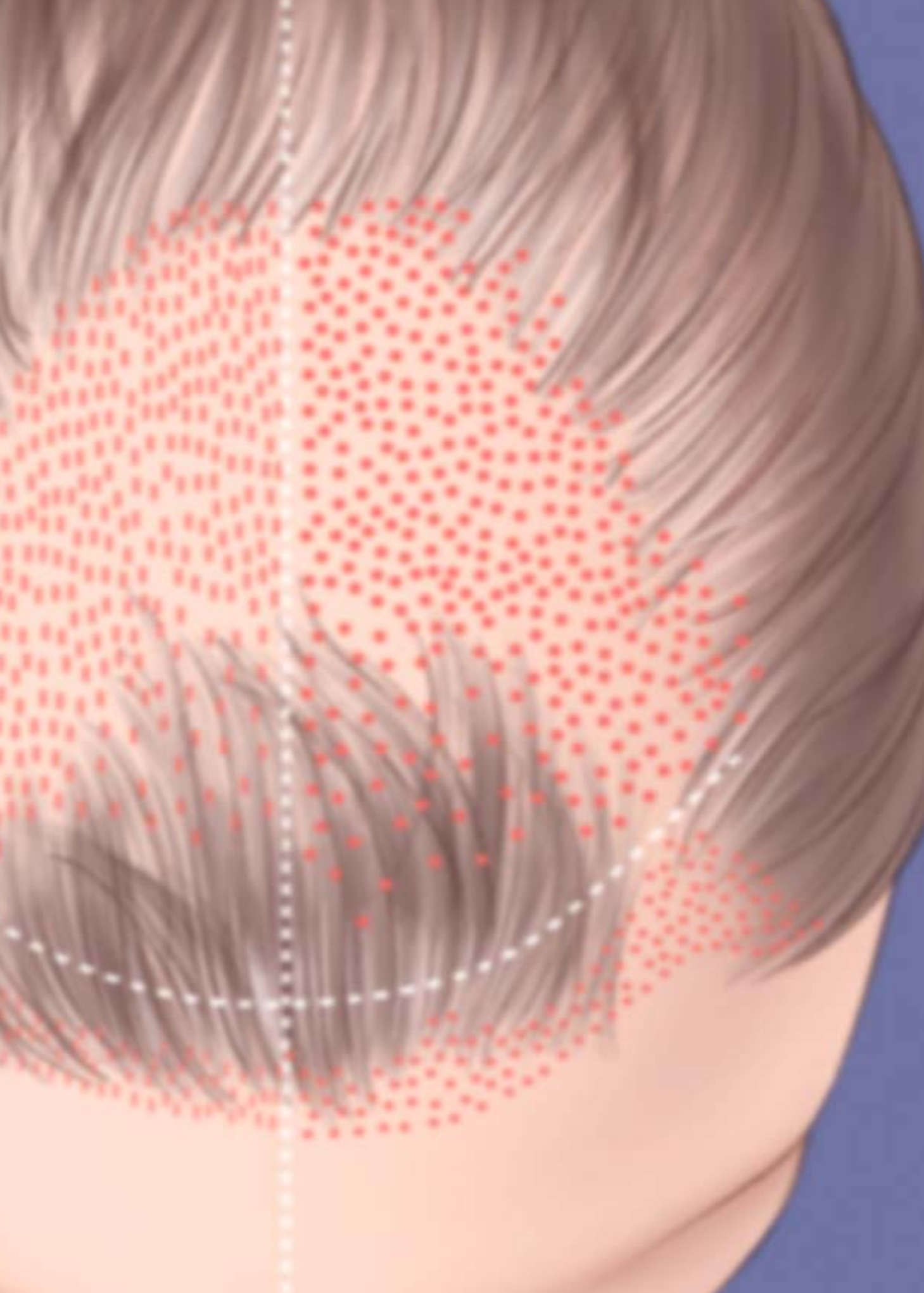


## Literature

- Adanali G, Erdogan B, Turegun M, et al (2002) A new T-shaped adaptor for easy quick and efficient fat harvesting during liposuction. *Aesthetic Plast Surg* 26:340–344
- Al-basti HA, El-Khatib HA (2002) The use of suction-assisted surgical extraction of moderate and large lipomas: long-term follow-up. *Aesthetic Plast Surg* 26:114–117
- Al-Shareef Z, Hamour OA, Al-Shlash S, et al (2002) Laparoscopic treatment of hepatic hydatid cysts with a liposuction device. *JLS* 6:327–330
- Ali RS, Garrido A, Ramakrishnan V (2002) Stacked free hemi-DIEP flaps: a method of autologous breast reconstruction in a patient with midline abdominal scarring. *Br J Plast Surg* 55:351–353
- Augustin M, Zschocke I, Sommer B, et al (1999) Sociodemographic profile and satisfaction with treatment of patients undergoing liposuction in tumescent local anesthesia. *Dermatol Surg* 25:480–483
- Augustin M, Vanscheidt W, Sattler G, et al (1999) Tumescent technique for local anesthesia. Use and prospectives of a new anesthetic method (in German). *Fortschr Med* 117:40–42
- Badin AZ, Moraes LM, Gondek L, et al (2002) Laser lipolysis: flaccidity under control. *Aesthetic Plast Surg* 26:335–339
- Bauer T, Gruber Sund Todoroff B (2001) Peri-areolar approach in pronounced gynecomastia with focus-plasty and liposuction (in German). *Chirurg* 72:433–436
- Beck-Schimmer Bund Pasch T (2002) Tumescent technique for local anesthesia (in German). *Anesthesiol Intensivmed Notfallmed Schmerzther* 37:84–88
- Bruno G, Abbiati Gund Amadei F (2000) Lipoplastics of legs: our experience with a new cannula compared with classical technique. *Aesthetic Plast Surg* 24:401–405
- Cao H, Zheng Zund Song W (2000) Abdominoplasty with a combined technique of lipectomy and liposuction (in Chinese). *Zhonghua Zheng Xing Wai Ke Za Zhi* 16:348–350
- Cardenas Restrepo JC, Munoz Ahmed JA (2002) New technique of plication for miniabdominoplasty. *Plast Reconstr Surg* 109:1170–1177; discussion 1178–1190
- Cardenas-Camarena L, Cardenas A, Fajardo-Barajas D (2001) Clinical and histopathological analysis of tissue retraction in tumescent liposuction assisted by external ultrasound. *Ann Plast Surg* 46:287–292
- Cardenas-Camarena L, Andino-Ulloa R, Mora RC, et al (2002) Laboratory and histopathologic comparative study of internal ultrasound-assisted lipoplasty and tumescent lipoplasty. *Plast Reconstr Surg* 110:1158–1164; discussion 1165–1156
- Cardenas-Camarena Lund Guerrero MT (2002) Improving nasal tip projection and definition using interdomal sutures and open approach without transcolumellar incision. *Aesthetic Plast Surg* 26:161–166
- Commons GW, Halperin B, Chang CC (2001) Large-volume liposuction: a review of 631 consecutive cases over 12 years. *Plast Reconstr Surg* 108:1753–1763; discussion 1764–1757
- Gausas RE (1999) Technique for combined blepharoplasty and ptosis correction. *Facial Plast Surg* 15:193–201
- Goes JC, Landecker A (2002) Ultrasound-assisted lipoplasty (UAL) in breast surgery. *Aesthetic Plast Surg* 26:1–9
- Goyen MR (2002) Lifestyle outcomes of tumescent liposuction surgery. *Dermatol Surg* 28:459–462
- Grotting JC, Beckenstein MS (2001) Cervicofacial rejuvenation using ultrasound-assisted lipectomy. *Plast Reconstr Surg* 107:847–855
- Gupta SC, Khiabani KT, Stephenson LL, et al (2002) Effect of liposuction on skin perfusion. *Plast Reconstr Surg* 110:1748–1751
- Hasche E, Hagedorn M, Sattler G (1997) Subcutaneous sweat gland suction curettage in tumescent local anesthesia in hyperhidrosis axillaris (in German). *Hautarzt* 48:817–819

- Heddens CJ (2001) Belt lipectomy: procedure and outcomes. *Plast Surg Nurs* 21:185–189, 199; quiz 191
- Herr J, Hofheinz H, Hertl C, et al (2003) Is there evidence for excessive free radical production in vivo during ultrasound-assisted liposuction? *Plast Reconstr Surg* 111:425–429
- Horn LC, Fischer U, Hockel M (2001) Occult tumor cells in surgical specimens from cases of early cervical cancer treated by liposuction-assisted nerve-sparing radical hysterectomy. *Int J Gynecol Cancer* 11:159–163
- Huang JI, Beanes SR, Zhu M, et al (2002) Rat extramedullary adipose tissue as a source of osteochondrogenic progenitor cells. *Plast Reconstr Surg* 109:1033–1041; discussion 1042–1033
- Huss FR, Kratz G (2002) Adipose tissue processed for lipoinjection shows increased cellular survival in vitro when tissue engineering principles are applied. *Scand J Plast Reconstr Surg Hand Surg* 36:166–171
- Ilhan H, Tokar B (2002) Liposuction of a pediatric giant superficial lipoma. *J Pediatr Surg* 37:796–798
- Iyer SG, Lim J, Lim TC (2002) Aspiration for gross cystic disease of breast: a technique using liposuction apparatus. *Plast Reconstr Surg* 110:1810–1811
- Jacob CI, Kamminer MS (2002) The corset platysma repair: a technique revisited. *Dermatol Surg* 28:257–262
- Karmo FR, Milan MF, Silbergleit A (2001) Blood loss in major liposuction procedures: a comparison study using suction-assisted versus ultrasonically assisted lipoplasty. *Plast Reconstr Surg* 108:241–247; discussion 248–249
- Klein JA (1987) The tumescent technique for liposuction surgery. *J Am Acad Cosmetic Surg* 4:263–267
- Klein JA (1993) Tumescent technique for local anesthesia improves safety in large volume liposuction. *Plast Reconstr Surg* 92:1085–1098
- Klein JA (1998) Intravenous fluids and bupivacaine are contraindicated in tumescent liposuction (letter). *Plastic Reconstr Surg* 102:2516–2518
- Klotz DA, Howard J, Hengerer AS, et al (2001) Lipoinjection augmentation of the soft palate for velopharyngeal stress incompetence. *Laryngoscope* 111:2157–2161
- Lampe H, Wolters M (2001) Possibilities and limits of ambulatory surgery: demands and reality in plastic surgery (in German). *Kongressbd Dtsch Ges Chir Kongr* 118:642–646
- Lew D (1996) The use of autogenous fat grafts in the correction of facial asymmetries. *Atlas Oral Maxillofac Surg Clin North Am* 4:67–81
- Maiolo C, Cervelli V, De Fede MC, et al (2002) Soft tissue composition in upper leg lipodystrophy: application of dual energy x-ray absorptiometry. *Aesthetic Plast Surg* 26:345–347
- Malet T (2000) Reinjection of autologous fat in moderately deep upper lid sulci of anophthalmic sockets. *Orbit* 19:139–151
- Malur S, Bechler J, Schneider A (2001) Endoscopic axillary lymphadenectomy without prior liposuction in 100 patients with invasive breast cancer. *Surg Laparosc Endosc Percutan Tech* 11:38–41; discussion 42
- Mang WL (1999) Tumescent local anesthesia. Interview with Prof Dr Werner Mang on the developmental state of this new local anesthesia method. Interview by Werner Rossling/Hinrich Kuster (in German). *Urologe A* 38:615–616
- Mang WL (2002) *Manual of Aesthetic Surgery* 1. Springer Berlin Heidelberg New York
- Mang WL, Sawatzki K, Materak J (1999) Tumescent technique in aesthetic plastic surgery with low doses of prolocain solution. *Am J Cosmet Surg* 16
- Mang WL, Materak J, Kuntz S (1999) Liposuktion in Tumeszenzlokalanästhesie – Grenzen der Prilocaindosierung. *Z Hautkrankheiten* 93(74):157–161
- Markey AC (2001) Liposuction in cosmetic dermatology. *Clin Exp Dermatol* 26:3–5

- Matarasso A (2002) Suction mammoplasty: the use of suction lipectomy alone to reduce large breasts. *Clin Plast Surg* 29:433–443
- May JW Jr, Silverman RP, Kaufman JA (1999) Flap perfusion mapping: TRAM flap after abdominal suction-assisted lipectomy. *Plast Reconstr Surg* 104:2278–2281
- Morrison W, Salisbury M, Beckham P, et al (2001) The minimal facelift: liposuction of the neck and jowls. *Aesthetic Plast Surg* 25:94–99
- Navarro-Viana F (2001) Rhytidectomy assisted with ultrasound techniques: the ultra-lipo-lift technique. *Aesthetic Plast Surg* 25:175–180
- Noodleman FR, Harris DR (2002) The laser-assisted neck lift: modifications in technique and postoperative care to improve results. *Dermatol Surg* 28:453–458
- Perkins SW (2000) Achieving the “natural look” in rhytidectomy. *Facial Plast Surg* 16:269–282
- Price MF, Massey B, Rumbolo PM, et al (2001) Liposuction as an adjunct procedure in reduction mammoplasty. *Ann Plast Surg* 47:115–118
- Regidor PA, Schmidt M, Walz KA, et al (2001) Liposuction for “body contouring” in gynecology (in German). *Zentralbl Gynakol* 123:153–157
- Saray A, Ocal K, Berberoglu M (2001) Endoscopic balloon dissection for removal of lipomas via transaxillary route. *Aesthetic Plast Surg* 25:463–467
- Sattler G, Sommer B, Bergfeld D, et al (1999) Tumescence liposuction in Germany: history and new trends and techniques. *Dermatol Surg* 25:221–223
- Sattler G, Sommer B (2000) iporecycling: a technique for facial rejuvenation and body contouring. *Dermatol Surg* 26:1140–1144
- Schwarz M (2001) Pitfalls in liposuction (in German). *Kongressbd Dtsch Ges Chir Kongr* 118:669–670
- Scuderi N, Paolini G, Grippaudo FR, et al (2000) Comparative evaluation of traditional ultrasonic and pneumatic assisted lipoplasty: analysis of local and systemic effects efficacy and costs of these methods. *Aesthetic Plast Surg* 24:395–400
- Senen D, Adanali G, Ayhan M, et al (2002) Contribution of vitamin C administration for increasing lipolysis. *Aesthetic Plast Surg* 26:123–125
- Sommer B, Sattler G (1998) Tumescence local anesthesiaImprovement of local anesthesia methods for surgical dermatology (in German). *Hautarzt* 49:351–360
- Sommer B, Sattler G (2000) Current concepts of fat graft survival: histology of aspirated adipose tissue and review of the literature. *Dermatol Surg* 26:1159–1166
- Thomas J (2001) Adjunctive tumescent technique in massive resections. *Aesthetic Plast Surg* 25:343–346
- Tung TC (2001) Endoscopic shaver with liposuction for treatment of axillary osmidrosis. *Ann Plast Surg* 46:400–404
- Valeriani M, Mezzana P, Madonna Terracina FS (2001) Liposculpture and lipofilling of the gluteal-trochanteric region: anatomical analysis and technique. *Acta Chir Plast* 43:95–98
- Voigt M, Walgenbach KJ, Andree C, et al (2001) Minimally invasive surgical therapy of gynecomastia: liposuction and exeresis technique (in German). *Chirurg* 72:1190–1195
- Walgenbach KJ, Riabikhin AW, Galla TJ, et al (2001) Effect of ultrasonic assisted lipectomy (UAL) on breast tissue: histological findings. *Aesthetic Plast Surg* 25:85–88
- Ziccardi VB (2000) Adjunctive cervicofacial liposuction. *Atlas Oral Maxillofac Surg Clin North Am* 8:81–97
- Zuk PA, Zhu M, Mizuno H, et al (2001) Multilineage cells from human adipose tissue: implications for cell-based therapies. *Tissue Eng* 7:211–228



---

## Hair Transplantation

- Introduction 204
- Norwood Classification of Types of Hair Loss 206
- Instruments 206
  - Basic Instrument Set (Sterilizable) 206
  - Instruments for Graft/Follicular Unit Preparation 208
  - Instruments for Micropunch Technique 210
  - Instruments for Microslit Technique 210
- ■ Preparation of the Patient, Hairline Design 212
- ■ Donor Area 212
- ■ Local Anesthesia, Tumescence 212
- ■ Donor Strip Harvesting 214
  - Skin Closure with Continuous Sutures 214
- ■ Follicular Unit Preparation (Minigrafts, Micrografts, Single Hairs) 216
- ■ Recipient Area, Holes and Slits 216
- ■ Transplantation Channels: Micropunches (a), Microdrills (b) and Erbium YAG-Laser (c) 218
- ■ Transplantation 218
  - Aftercare 220
  - Postoperative Precautions 220
  - Result 220
  - Literature 222

---

## Introduction

Hair transplantation has been requested by many men since it is known that new methods (micropunch technique, slit technique, laser-assisted) do not leave any visible scars. The hairs that are transplanted from the back of the head rarely fall out, and the procedure is atraumatic and virtually painless. A special team is necessary for hair transplantations. This is made up of a surgeon and at least two trained assistants who prepare the hair follicles. Besides precise preparation of the hair follicles, correct insertion of the hair follicles at the correct angle using either the micropunch or the slit technique is extremely important. This is the only way to achieve a natural result; it is the art of the hair transplant surgeon. For this reason we have a dedicated hair transplantation team at the Bodenseeklinik who carry out only hair transplantations. The only way to produce good, lasting results is practice, experience, and the precise preparation and insertion of the hair follicles.

In the hair transplantation chapter a clear overview is given of what must be done to achieve successful hair transplantation. In addition to the precise harvesting of an appropriate donor strip from the back of the head with atraumatic closure, successful hair transplantation involves microscopic preparation of the hair follicles and insertion of the implants either by the micropunch technique or the slit technique, using either one or more follicles in either a manual or a laser technique. The precise insertion technique is determined individually for each patient and each area.

Beauty ideals vary a great deal, but thick, shiny hair is desirable in all cultures because it is a symbol of health and youth. Even the ancient Egyptians saw it as a catastrophe if someone's hair became thinner and thinner. In our society as well, where a youthful appearance plays a very important role, thick, healthy hair is a great advantage. In the Western world roughly every second man is affected by hair loss. The most common form of hair loss is so-called androgenetic alopecia, masculine type hair loss (see Fig. 1 – Norwood classification of types of hair loss).

The hormone dihydrotestosterone plays a key role in androgenetic alopecia. This hormone is formed from the male sex hormone testosterone under the influence of a particular enzyme. Dihydrotestosterone causes hair to become thinner and thinner in particular places such as the brow, temples and the crown and finally to fall out.



---

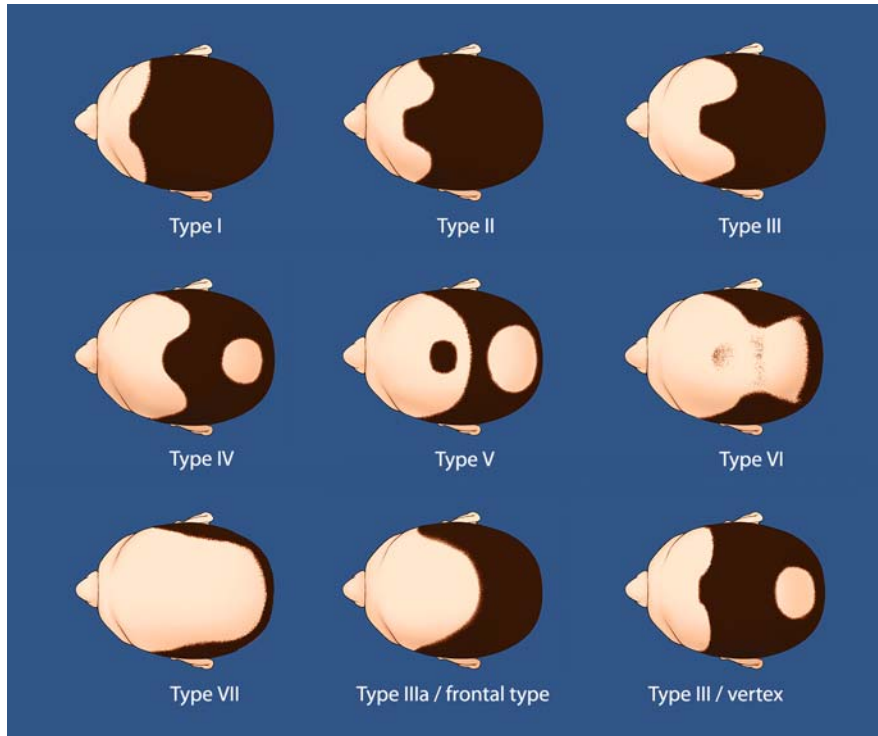
The decisive factor when it comes to hair transplantation is that hair on the back of the head (coronal hair), facial hair and body hair are immune to the hormone dihydrotestosterone. This explains why hairs taken from the back of the head and transplanted to bald patches do not then fall out. They continue growing and produce healthy hair, which can be washed, blow dried, and dyed normally.

Transplantation of a patient's own hair is a skillful redistribution of healthy hair follicles to bald patches and, with the new methods available, results in a natural appearance.

Considerations before hair transplantation: The patient's hair should be allowed to grow as long as possible so that the harvest area can be covered with the remaining hair and is not visible. The patient should not take any anticoagulants.

The procedure is carried out under local anesthesia.

After the operation a loose-fitting hat (e.g., baseball cap) should be worn.



## Norwood Classification of Types of Hair Loss

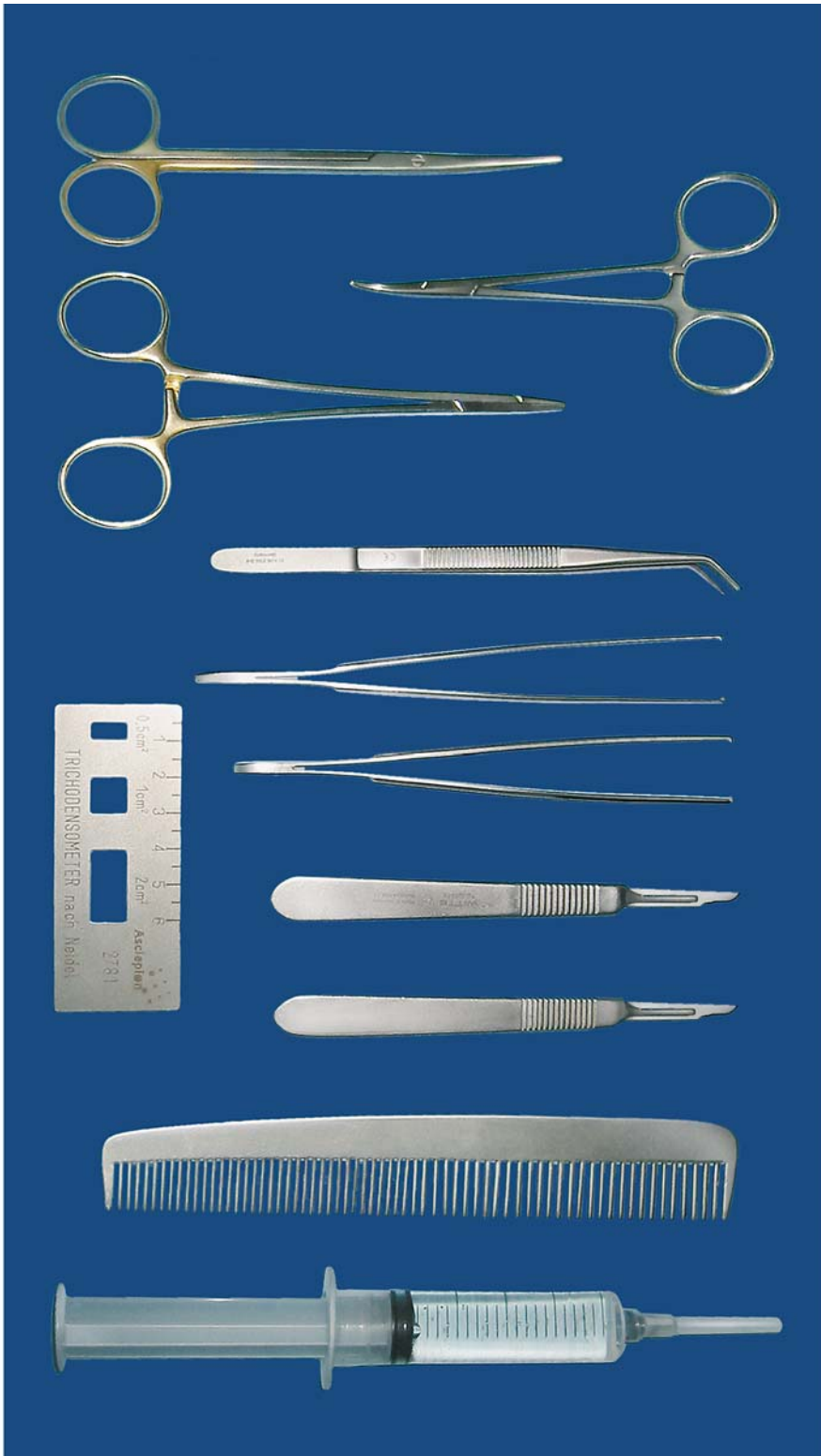### Instruments

#### Basic Instrument Set (Sterilizable) \*

- Scissors, small [1]
- Mosquito forceps, small [2]
- Needle holder, small [3]
- Dissecting forceps [4]
- Delicate tissue forceps [5]
- Tissue forceps, small [6]
- Metal matrix for trichodensitometry (Neidel) [7]
- Scalpel handle (blades available: sizes 10, 11, 15) [8]
- Metal comb [9]
- Syringe, Luer LOK 20 cc, for tumescence with saline 0.9% [10]

\* Robumed, Postfach 162, 78502 Tuttlingen, Germany

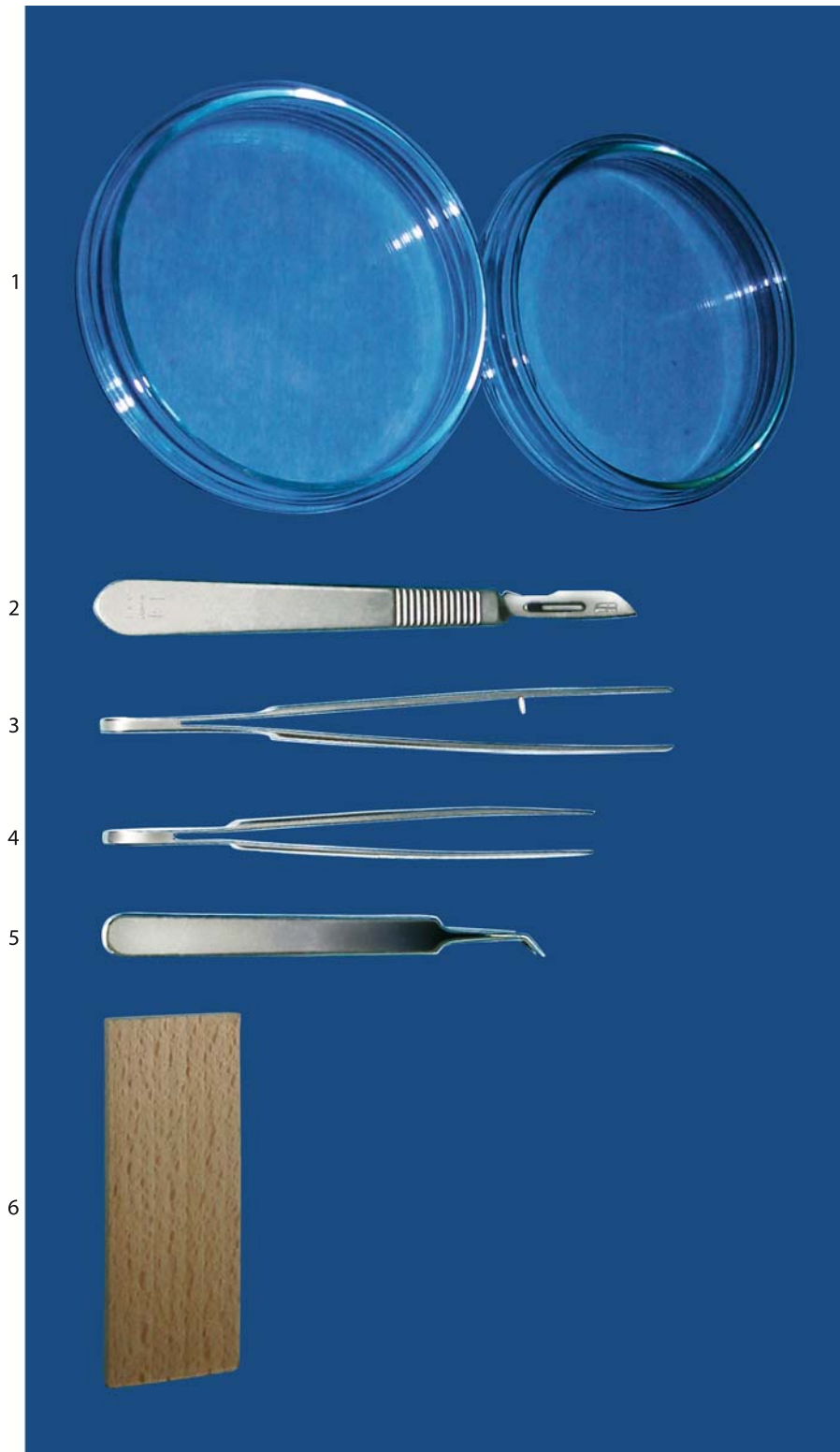



**Hair Transplantation**

### **Instruments for Graft/Follicular Unit Preparation**

- Petri dishes with saline 0.9 % [1]
- Scalpel handle (blades available: no. 10) [2]
- Delicate tissue forceps [3]
- Extremely delicate dissecting forceps [4]
- Forceps for micro- and minigrafting (implantation) [5]
- Wood for preparation [6]



---


### **Instruments for Micropunch Technique**

- Micropunch 0.8 mm diameter [1]
- Micropunch 1.0 mm diameter [2]
- Handpiece for micropunch, autoclavable (hand engine) [3]

---

### **Instruments for Microslit Technique**

- Sharp point ( $15^{\circ}/22.5^{\circ}/30^{\circ}/45^{\circ}$  pointed tip) [1]
- Handle [2]



---

- ◉ **Preparation of the Patient, Hairline Design**

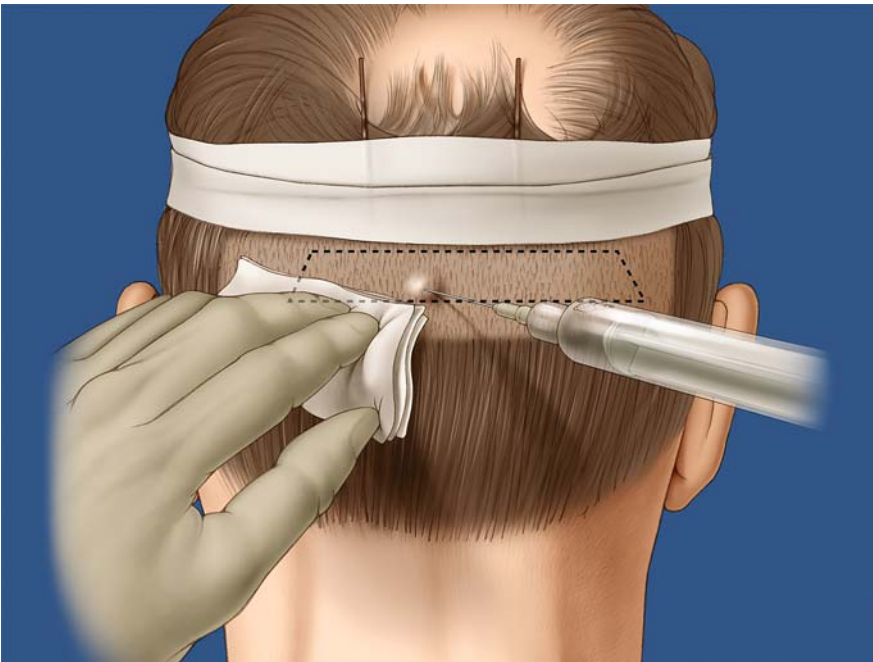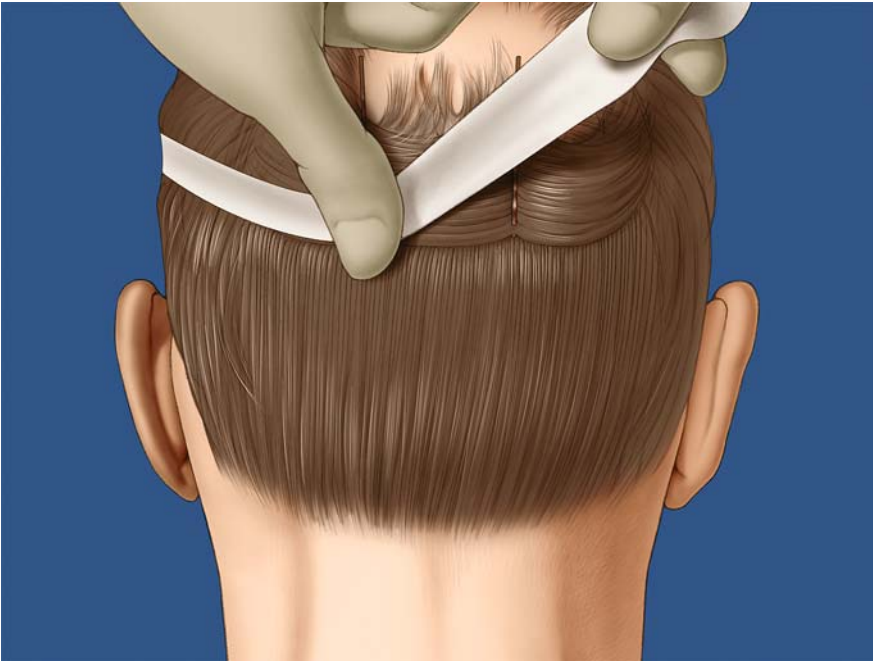- ◉ **Donor Area**

- The donor area should not be more than 2 cm above an imaginary line connecting the tips of the patient's ears behind the head. Be careful not to harvest an overly large skin strip so that you will not have to discard hair follicles later.
- When determining the size of the donor area, keep the preparation capacity of your transplantation team in mind! Only shorten hairs whose follicles are to be dissected later. Leave the remaining hairs as long as possible so that they will cover the donor site after transplantation.
- Measure follicle group density, i. e., follicular units per square centimeter.
- With this figure, the number of follicular units to be transplanted can be calculated from the total area of the donor strip.

---

- ◉ **Local Anesthesia, Tumescence**

- Local anesthesia with articaine and adrenaline (e.g., B. Ultracain DS-forte, Septanest with adrenaline 1/100,000) is administered in the form of a ring block below the harvest site, using an intradermal injection technique.
- This is followed by intradermal infiltration anesthesia using 0.5 % prilocaine with adrenaline.
- Injection of a 0.9 % saline solution is employed to achieve tumescence of the donor area.
- Caution: Inject the tumescence solution intradermally and subdermally; subgaleal injection is contraindicated! This precaution prevents injury to major nerves and blood vessels during the subsequent skin incision.



---

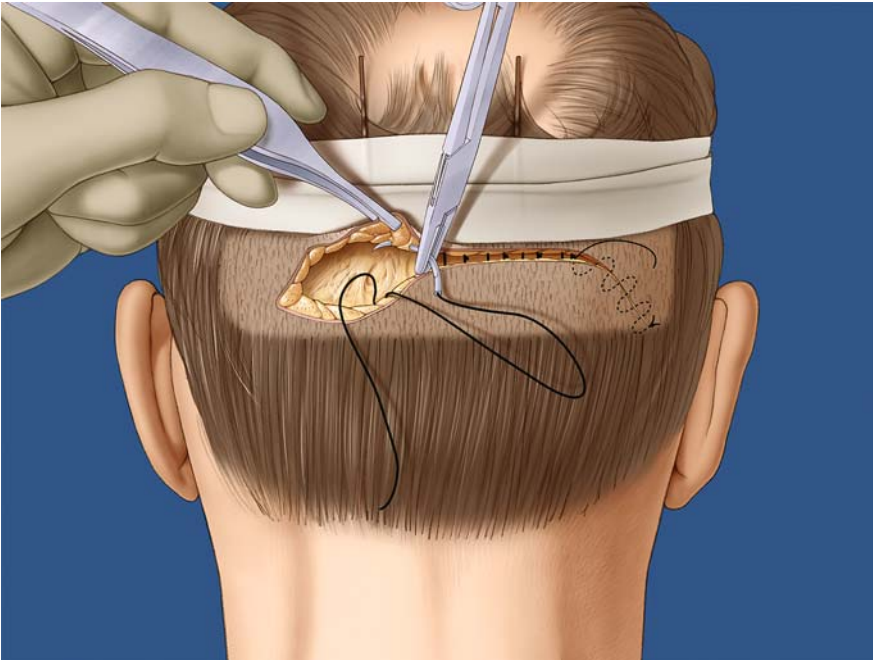
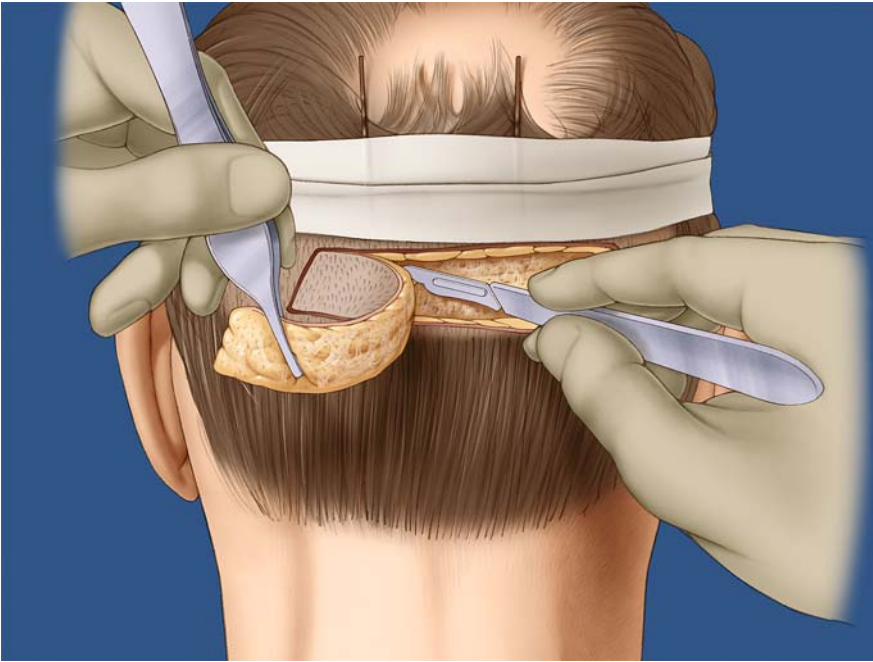
### ◉ Donor Strip Harvesting

- Remove a trapezoidal donor strip with the base of the trapezoid in a caudal position!
- Avoid transection of the hair follicles by making an incision at an angle of about 45° and cutting exactly parallel to the direction of hair growth.
- The upper incision angle can vary. Use a magnifying device with a power of 2×. Multiple incisions at the same location cause transection, and thus destruction, of the hair follicle.
- Cautiously excise the strips; pull gently to detach them below the hair roots in the fatty layer.
- Do not injure the vascular-neural bundle. To avoid injuring the galea at all costs, the best policy is: hands off the galea!
- Place the harvested strip into a sterile cooled 0.9% saline solution immediately.
- No mobilization. No opening of the galea.
- Hemostasis should be carried out on the galea only and not near the hair follicle.
- Pull the edges of the wound together over the donor site using monofilament absorbable sutures (2×0 or 0), e.g., Monocryl.
- Insert the needle into the skin and out again below the hair roots; use a concealed knot. With this technique, the wound edges are already optimally adapted; smaller hemorrhages are automatically compressed.

### ■ Skin Closure with Continuous Sutures

- Perform skin closure with running sutures; use non-absorbable monofilament sutures (e.g., Prolene or Resolon 4×0).
- Make sure that the cutaneous sutures are not under tension and that the needle is inserted superficially. Inserting the needle too deeply may result in hair follicle necrosis and ultimately scar-tissue alopecia.
- When harvesting, dissecting or transplanting hair follicles, avoid doing anything that will result in trauma or reduced perfusion.





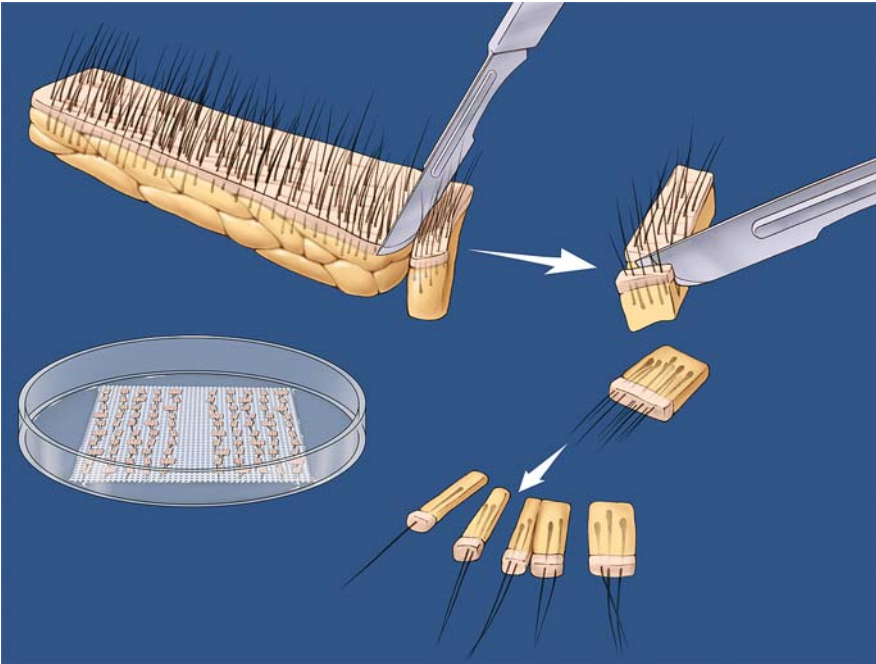
---

### ◉ Follicular Unit Preparation (Minigrafts, Micrografts, Single Hairs)

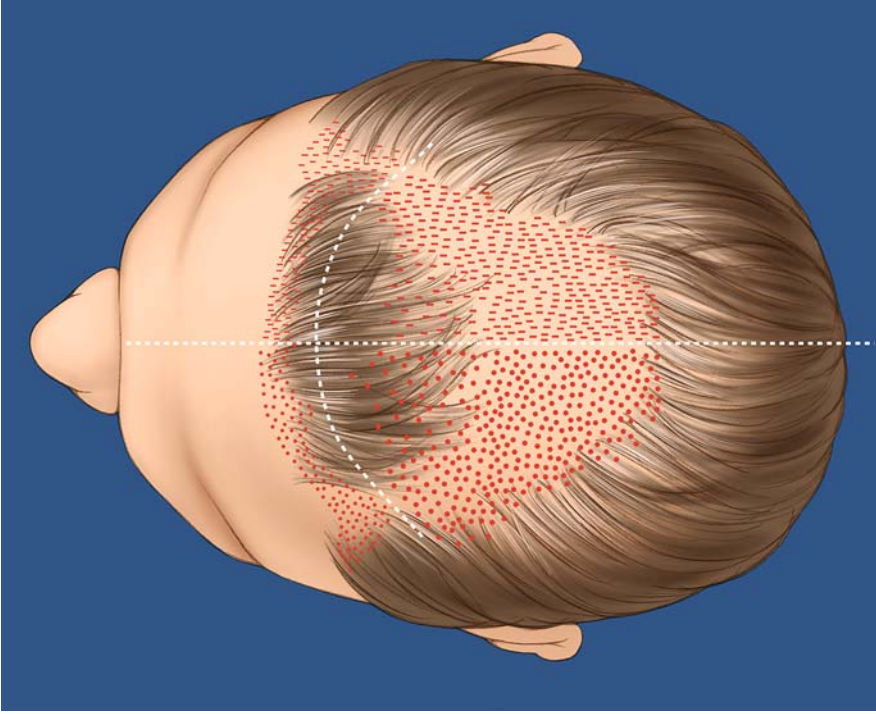
- The donor strip is placed on a non-slip sterile wooden board and sliced into small segments. Work with magnifying spectacles or a binocular microscope.
- Avoid transection. Fix the skin firmly. Avoid multiple incisions.
- The segments are divided further into strips; the follicular units are now arranged in a row on a piece of gauze.
- As part of the preparation work, the units are separated and sorted into single-hair units or units containing 2–4 hairs.
- For larger numbers of hair transplants, two to three trained surgical assistants are required for the preparation work.
- Replace scalpel blades frequently. Do not crush the hair follicles!
- The dissected follicular units are sorted into rows of 10 units each.
- A total of 10 rows per gauze strip and Petri dish equals 100 follicular units or grafts. Cool the saline solution sufficiently before use. Keep the transplants moist at all times!

### ◉ Recipient Area, Holes and Slits

- Ring blockade with articaine and adrenaline (e.g., *Ultracain DS-forte* or *Septanest* with adrenaline 1/100,000). Be careful to use an intradermal injection technique and avoid subgaleal infiltration.
- Infiltration with prilocaine 0.5% with adrenaline in the treatment area.
- In addition, inject 0.9% saline solution to achieve intradermal and subdermal tumescence. Allow 10–15 min for the solution to take effect.
- Be careful to work in the direction of hair growth. The use of a magnifying device with a power of 2–4× is recommended. Following the hairline design, punch out 0.8 mm holes for transplants containing 1–2 hairs.
- After punching between 5 and 10 holes, make a test transplant to determine whether the transplants can be inserted without any problems. For example, check whether the size and depth of the holes are sufficient.
- Never transplant hair only along the marked line, as this results in an unsightly “pearl necklace effect”. A feathered hairline is the effect you want to achieve: “irregular regularity” is the key word here! Use the laser for bald areas; switch to cold steel methods in areas still covered by dense hair. Make continual test transplants to check the suitability of the holes. If necessary, change the laser setting. Use slender angled tweezers.



Hair Transplantation



● **Transplantation Channels: Micropunches (a), Microdrills (b) and Erbium YAG-Laser (c)**

- Use micropunches with a diameter of 0.8 mm, 1.0 mm or, in rare cases, 1.2 mm to avoid an unaesthetic tufted “doll’s head” effect.
- Be sure to select micropunches that permit lateral skin ejection and have an internal ground surface.
- The distance between hairs is increased by tumescence. The microholes are placed between healthy hair roots.
- In patients with very dense remaining hair, employ a slit technique using chisel blades or 15°, 30° or 45° Sharpoint blades.
- Measure the number of holes or slits per square centimeter for the documentation.
- The holes or slits must be counted consecutively to guarantee correspondence with the number of prepared follicular units.
- Transplantation of follicular units with a sharp angled microtweezers (e.g., Micro 2000 made by Medicon). Perform non-traumatic implantation with no crushing of hair roots. The follicular units are placed on moist gauze strips draped over the back of the surgeon’s left hand; they are picked up individually with the microtweezers and then transplanted.
- Keep the follicular units moist!

● **Transplantation**

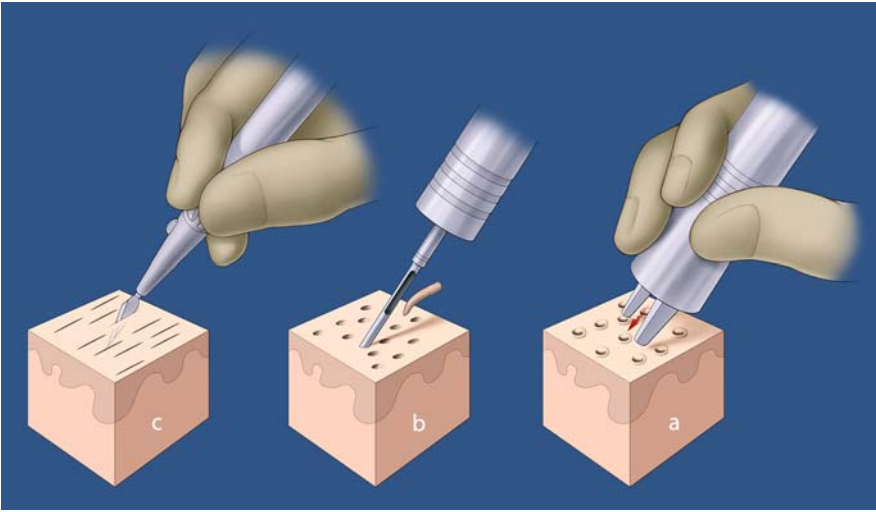
- Use swabs to keep the transplantation area clean and free of blood. Crusted dried blood prevents a clear overview of the surgical area.

During hair transplantation, a systematic approach is vital!

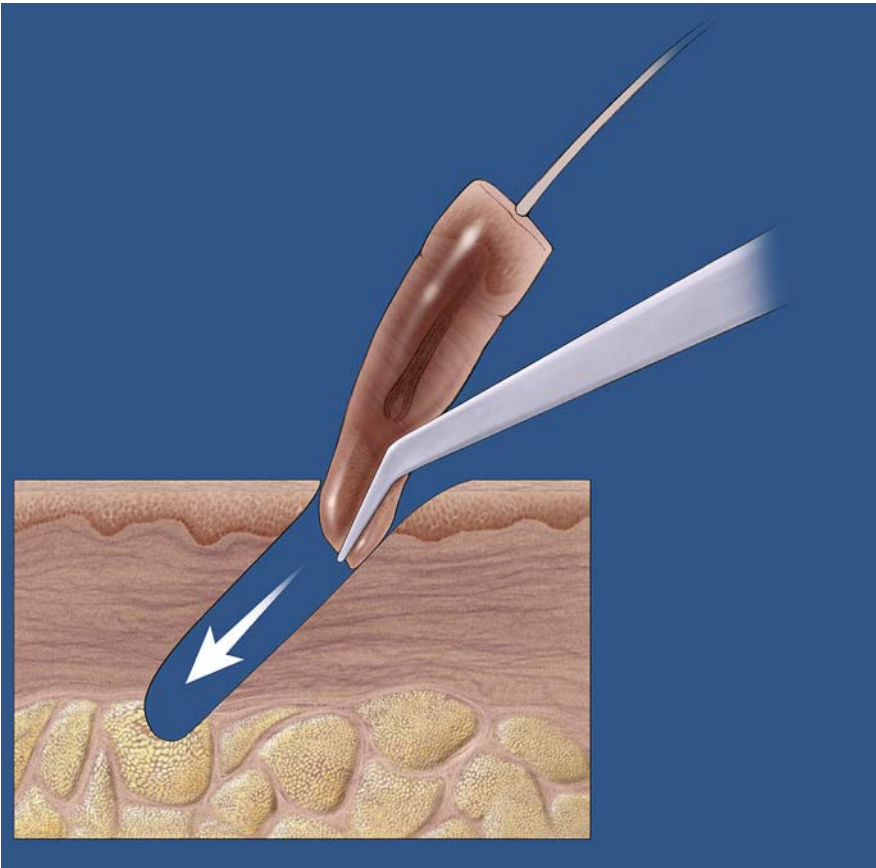
- When placing transplants in holes, the end of the transplant should be flush with the skin surface.
- When placing transplants in slits, the transplants should project 0.5–1.0 mm above skin level.

Never insert the transplants too deep since cysts are likely to form in 2–3 months in patients with deep transplants.

Since the effect of adrenaline and tumescence wears off after 2–3 h, stay within the time limits for the transplantation procedure.



Hair Transplantation



---

## **Aftercare**

### **Postoperative Precautions**

No bandage is necessary with modern surgical methods. There is no permanent visible scarring. The same criteria apply, however, after a hair transplantation as after any other operation in the facial area.

- Infection prophylaxis is given for 3 days after the operation. From the 3rd day the patient can wash his or her hair with a mild chamomile shampoo. The hair can then be washed daily. The hair transplants are fixed securely and firmly.
- After a maximum of 2 weeks all crusts should have disintegrated with washing; crusts delay wound healing. Rough manipulation should be avoided, particularly in the 1st postoperative week, as there is a risk of postoperative bleeding.

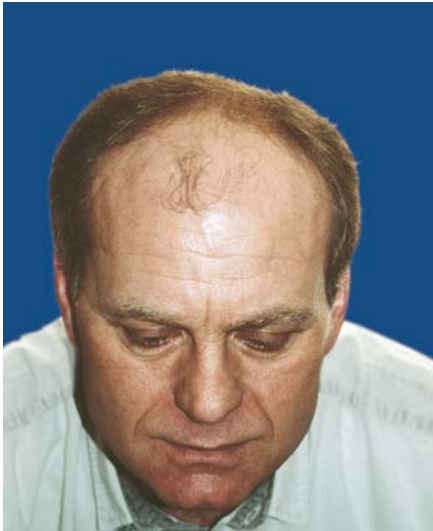
The patient can be professionally and socially active again 1 week after the operation.

After 6 weeks vasodilating hair lotion should be used. The crusts disintegrate quickly with regular washing.

## **Result**

A 50-year-old patient with Norwood type V hair loss, and 12 months after the operation, following two procedures with a total of 3,120 follicular units.





Before the operation



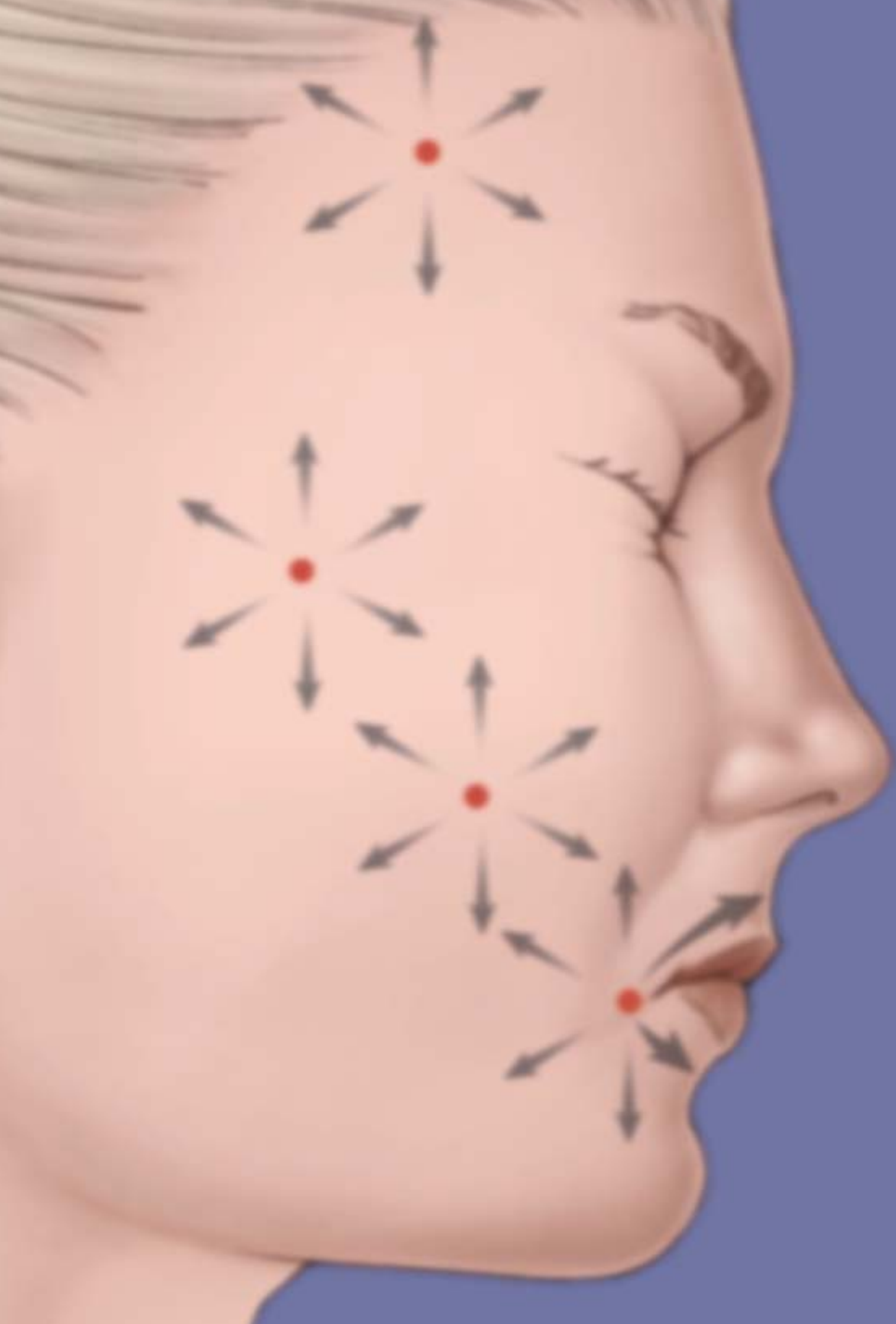
After the operation

## Literature

- Benett R (1988) Fundamentals of cutaneous surgery. Mosby, St Louis, pp 709–719
- Bernstein RM, Rassmann WR, Seager D, Shapiro R, Cooley JE, Norwood OT, Stough DB, Beehner M, Arnold J, Limmer BL, Avram MR, McClellan RE, Rose PT, Blugerman G, Gandelman M, Cotterill PC, Haber R, Jones R, Vogel JE, Moy RL, Unger WP (1998) Standardizing the classification and description of follicular unit transplantation and mini-micrografting techniques. *Dermatol Surg* 24:957–963
- Devine JW, Howard PS (1985) Classification of donor hair in male pattern baldness and operations for each type. *Facial Plast Surg* 2:189–190
- Farber GA (1982) The punch scalp graft. *Clin Plast Surg* 9:207–220
- Hill TG (1984) Enhancing and survival of full-thickness grafts. *J Dermatol Surg Oncol* 10:639–642
- Limmer B (1997) The density issue in hair transplantation. *Dermatol Surg* 23:747–750
- Lucas MWG (1988) The use of minigrafts in hair transplantation surgery. *J Dermatol Surg Oncol* 14:1389–1392
- Lucas MWG (1990) Micro and mini hair grafting. *J Dermatol Surg Oncol* 16:69–70
- Lucas MWG (1991) Large vs small grafts, slits vs holes, vol 2, no 1. *Hair Transplant Forum*, pp 1–3
- Lucas MWG (1994) Planning a hair transplantation: the artist's touch. *Am J Cosmet Surg* 11:315–319
- Marritt E (1984) Single-hair transplantation for hairline refinement: a practical solution. *J Dermatol Surg Oncol* 10:962–963
- Montagna W (1992) Atlas of normal human skin. Springer, New York, p 314
- Morrison ID (1981) An improved method of suturing the donor site in hair transplant surgery. *Plast Reconstr Surg* 67:378–380
- Neidel FG (1995) Zur Technik der Eigenhaarverpflanzung mit Mini- und Mikrografts. *Dermatol Bild* 10:9–19
- Neidel FG (1997) Haartransplantationen. In: Schulz H, Altmeyer P, Stücker M, Hoffmann K (eds) *Ambulante Operationen in der Dermatologie*. Hippokrates, Stuttgart, pp 112–113
- Neidel FG, El-Gammal S (1994) Non-invasive evaluation of growth rates of mini- and micrografts in hair transplantation. 5th Congress of the International Society for Aesthetic Surgery, Berlin, April 22–24, 1994
- Neidel FG, Altmeyer P, Finkel B (1998) Laser-assistierte autologe Haarfollikeltransplantation – LAAHT. In: Mang WL, Bull HG (eds) *Ästhetische Chirurgie*. Einhorn, Reinbek, pp 118–121
- Neidel FG, Fuchs M, Krahl D (1999) Laser-assisted autologous hair transplantation with the Er:YAG laser. *J Cutan Laser Ther* 1:229–231
- Nordström REA (1971) Hair transplantation. The use of hair-bearing compound grafts for correction of alopecia due to chronic discoid lupus erythematosus, traumatic alopecia and male pattern baldness [Suppl 1]. *Scand J Plast Reconstr Surg* (Thesis and academic dissertation)
- Nordström REA (1980) Hair growth in subcutaneously buried composite hair-bearing skin grafts. *Scand J Plast Reconstr Surg* 16:91–93
- Nordström REA (1981) Micrografts" for improvement of the frontal hairline after hair transplantation. *Aesthetic Plast Surg* 5:97
- Nordström REA (1981) Reconstruction of the temporal hairline. *Aesthetic Plast Surg* 5:103–106
- Nordström REA (1985) Punch hair grafting methods. *Facial Plast Surg* 2:205
- Nordström REA (1985) Special techniques in surgical hair replacement. *Facial Plast Surg* 2:207



- 
- Norwood OT, Shiell RC (1984) Hair transplant surgery, 2nd edn. Charles C Thomas, Springfield, Ill
- Okuda S (1939) The study of clinical experiments of hair transplantation. *Jpn J Dermatol Urol* 46:135
- Orentreich N (1959) Autografts in alopecias and other selected dermatological conditions. *Ann NY Acad Sci* 83:463
- Pinski JB (1984) How to obtain the "perfect" plug. *J Dermatol Surg Oncol* 10:953-956
- Unger WP, Shapiro R (2004) Hair transplantation. Dekker, New York, Basel



---

## Adjuvant Therapies Including Spacelift

- Introduction 227
- Local Anesthesia 228
  - Nerve Exit Points, Supraorbital Nerve, Infraorbital Nerve, Mental Nerve 228
- ■ Biological Implants 229
  - Injection Technique 230
    - Report – Technique:
    - Collagen and Hyaluronic Acid 231
    - Crystalline Polylactic Acid (Sculptra®) 234
    - Contouring Using the Mang Method 236
    - See also Vol. 1, pp. 226–238
- ■ Botulinum Toxin 238
  - Report – Technique 239
  - See also Vol. 1, pp. 244–250
- ■ Mang’s Spacelift 244
  - Introduction 244
  - Indications 244
  - Instruments 246
  - Technique 246
  - Injection Technique 246
  - Diagram of the Fat Injection 252
  - Three-Dimensional Diagram of Fat Injection into Subcutaneous Tissue 252
  - Increasing the Density of the Connective Tissue Following Breakdown of Fat Droplets 254
- ■ Dermabrasion 256
  - Introduction 256
  - Report – Technique 256
  - See also Vol. I, pp. 251–256
- Chemical Peeling 259
  - Introduction 259
  - Report – Technique 260
  - See also Vol. 1, pp. 274–278

- 
- ■ Erbium YAG Laser 262
    - Introduction 262
    - Report – Technique 262
    - See also Vol. 1, p. 269
  
  - ■ Hyal System® 264
    - Introduction 264
    - Report – Technique 265
    - Follow-up Treatment 268
  
  - Literature 269

---

## Introduction

Adjuvant therapies should be included in the repertoire of every aesthetic surgeon. It would exceed the scope of this manual to describe all adjuvant therapies in detail. Anyone who wishes to undertake further training in this field can find detailed information primarily in dermatological textbooks.

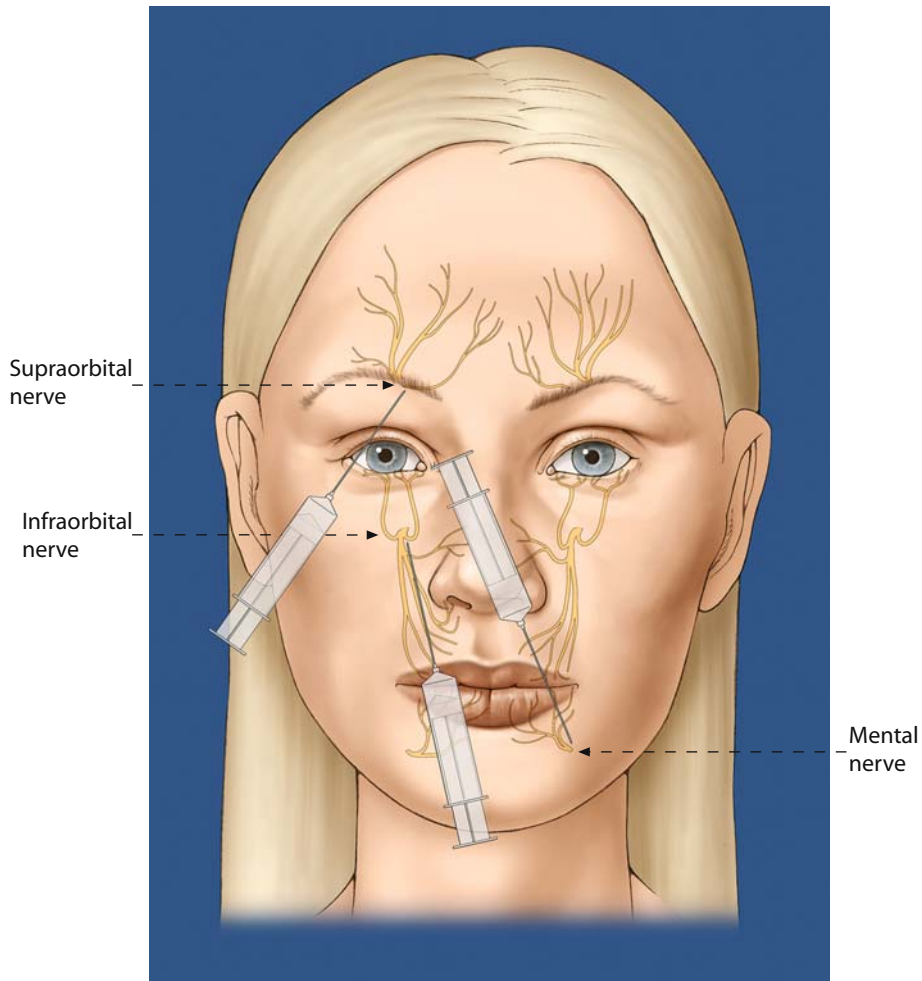
Therefore, a few important adjuvant therapies will be dealt with only briefly in this volume. Please refer to the texts in Volume I of the manual for the basic information.

Dermabrasion, chemical peeling, and erbium-YAG laser treatment are examined methodically, but only very briefly to provide an understanding of the basic principles. Adjuvant therapies are very often combined with surgery, and an experienced aesthetic surgeon will choose appropriate treatments, depending on the types of wrinkles and skin type.

We do not use injectable alloplastic materials, as damage may occur that is extremely difficult to correct and, in a few cases, even irreparable. The use of autologous fat injections (Mang's spacelift) and biological implants, such as collagen and hyaluronic acid, is preferred. The decision to use botulinum toxin injections must be based on stringent criteria. The results for forehead wrinkles are good and the treatment can be repeated at intervals of 6 months.

The euphoria generated by laser therapy in the early 1990s has not entirely satisfied expectations for the treatment of the "aging face." The laser is not a "miracle weapon," but has now attained an established place in the field of adjuvant therapies. We primarily use the ultrapulse CO<sub>2</sub> laser for skin resurfacing. This has already been described in detail in the audiovisual aids in Volume I (pp. 258–268).

The surgeon must decide whether to perform dermabrasion, chemical peeling, or laser therapy for wrinkles in the perioral region on the basis of his/her experience and his/her own judgment. Dermabrasion with a diamond cylinder gives good long-term results with no scarring or abnormal pigmentation for moderately deep lip wrinkles in younger patients. Chemical peeling (e.g., trichloroacetic acid 35%) may be useful for older patients with deeper wrinkles. Erbium-YAG laser provides the best results for wrinkles in the perioral region and particularly the area of the lower eyelids.



## Local Anesthesia

### Nerve Exit Points, Supraorbital Nerve, Infraorbital Nerve, Mental Nerve

If adjuvant therapies are not combined with operations (e.g., a facelift), they are performed under local anesthesia and as day-case treatment. Nerve block anesthesia with Ultracain 1% (articaine) and additional adrenaline have proved to be successful. When treating the entire face by laser or chemical peeling, light sedation also can be induced with Dormicum (midazolam) with anesthesiology stand-by. No more than 30 ml 1% local anesthesia solution should be injected. Particularly sensitive areas (e.g., lips) can be infiltrated separately, in addition to nerve block anesthesia.

With all operations carried out as day cases, a venous line and, if necessary, antibiotic prophylaxis are recommended.

---

### Biological Implants \*

Only endogenous (bone, cartilage, fascia, connective and adipose tissue, etc.) and biosynthetic materials (collagen, hyaluronic acid) are used at our clinic.

We do not use alloplastic materials (e.g., silicone and paraffin oils, PMMA, etc.) since they can cause unpredictable and sometimes irreparable damage.

The most important principle in aesthetic surgery is health before beauty. Avoid all new materials that have not undergone long-term testing. This applies not only to injectable materials but also to breast implants and suture material. Injectable collagen is an ultrapurified bovine collagen of type I. Depending on the concentration (35–65 mg/ml), this material is available in various ready-to-use ampules with a local anesthetic.

The injection of the dermal filler substance has been given correctly if the aesthetically disturbing area is overcorrected and the skin becomes white (blanching effect). This technique can be used to treat all wrinkles in the facial area (glabella, eyes, nasolabial folds, lips), acne and accident scars, and also to augment cheeks and lips. If collagen is to be used, a test must be performed with 0.2 ml of collagen on the inside of the forearm 4 weeks prior to treatment to rule out allergies.

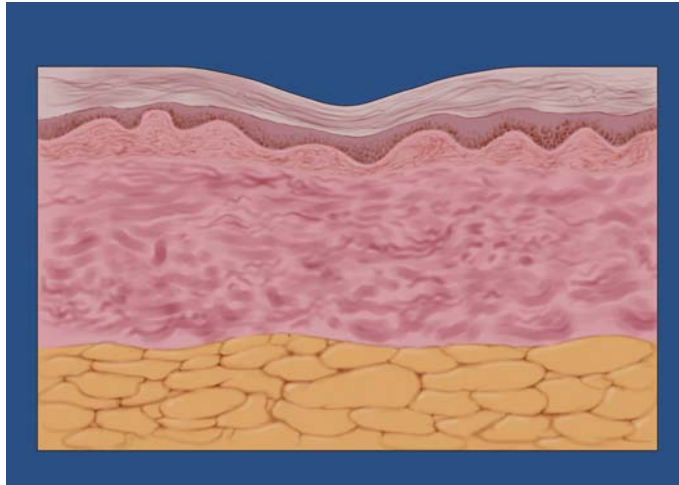
This test is not necessary if hyaluronic acid is used. This substance is also fully biodegradable, but it is a polysaccharide, not a protein compound. This means there is nearly no allergenic potential and testing in advance is unnecessary. The indications are the same as for collagen, although hyaluronic acid is slightly more viscous to inject.

Hyaluronic acid is also available in various concentrations, so fine creases in the area of the eyes can be treated with material with a lower concentration and nasolabial folds and lips can be augmented with material with a higher concentration.

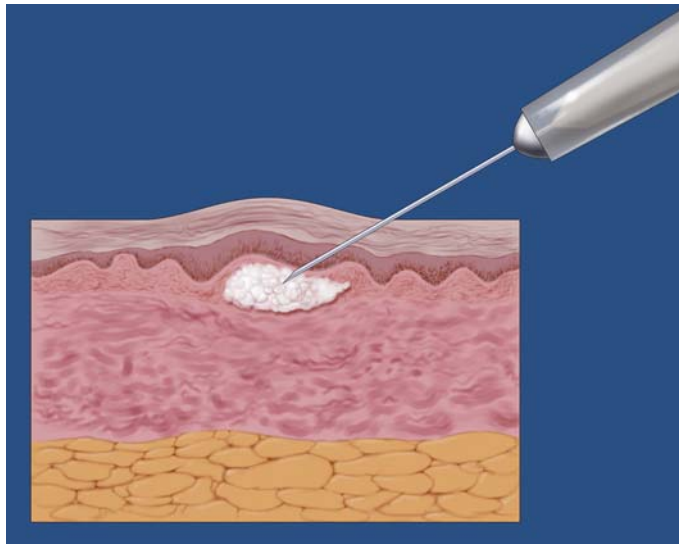
More information can be found in Volume I of the *Manual of Aesthetic Surgery*, pp. 226–238.

---

\* Collagen GmbH, Hansa-Allee 201, 40549 Düsseldorf, Germany.  
Inamed Aesthetics GmbH, Hansa-Allee 201, 40549 Düsseldorf, Germany.



Untreated skin with loss of collagen and elastin fibers and sagging of the upper layer of skin.



### Injection Technique

The liquid collagen is injected intradermally at an angle of  $30^\circ$ , resulting in over-correction and the “blanching effect.”

The injection must be strictly intradermal, and it is essential that it is not subcutaneous, as otherwise it will be ineffective and the material will be absorbed immediately. If the correct injection technique is used, the result will last for 6–8 months. Maintenance injections can then be given.

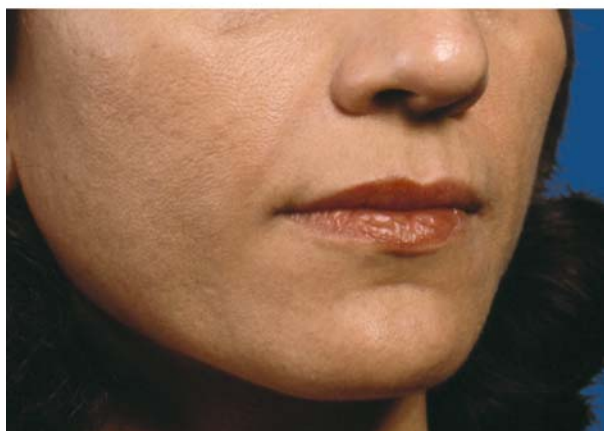
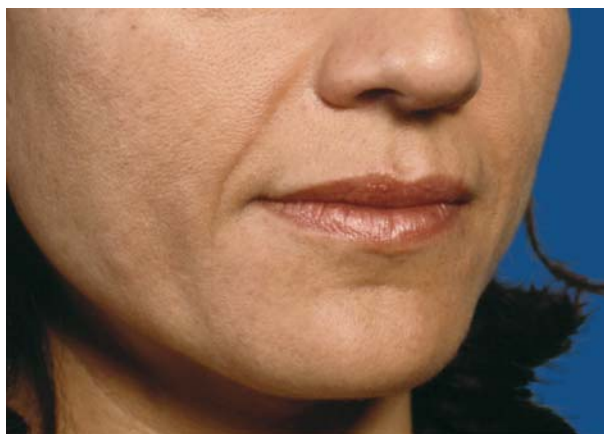
---

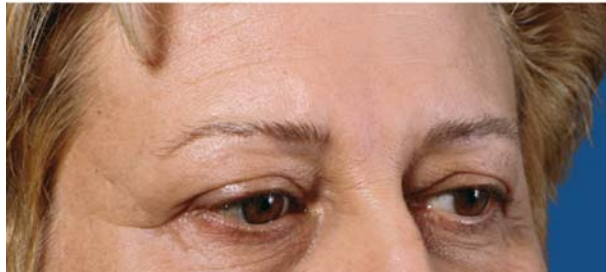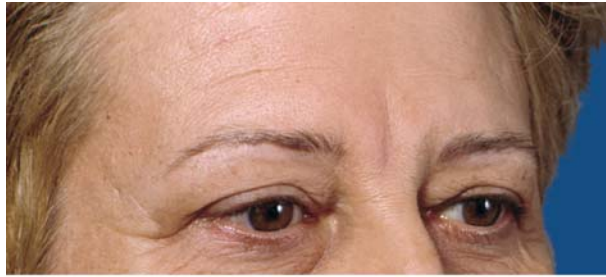## Report – Technique

### Collagen and Hyaluronic Acid

- The skin must be thoroughly disinfected prior to the injection. Nerve block anesthesia with 1% Ultracain and additional adrenaline can be used in patients who are particularly sensitive to pain and when treating large areas. Surface anesthesia with the anesthesia ointment EMLA® (lidocaine-prilocaine cream) may be given at the patient's request.
- Hyaluronic acid and collagen are injected directly into the wrinkle using Mang's serial point-by-point technique with overcorrection. The injection should be made at an angle of 30°. The patient should be lying down and the doctor carrying out the treatment should be sitting. Overcorrection can be up to 100%. If the injections are placed correctly, raising of the skin and a blanching effect will be visible immediately.
- The injection should be as close as possible to the surface. The point-by-point technique is used to remove forehead wrinkles (glabella), nasolabial folds and lip wrinkles. Fine eye wrinkles are treated with linear injections. The needle is inserted superficially along the eye wrinkle and pushed forwards; when it is retracted, the material flows like water into a riverbed. The wrinkle is then massaged immediately to prevent nodules forming. In principle, all wrinkles in the face and neck area can be treated with these two techniques. The skin is always pretensioned by applying mild traction.
- Fine corrections can be made at the end of the procedure with the aid of a magnifying glass. All nodules and necklacelike structures should be smoothed and massaged. The injectable material should spread out, almost as if in a riverbed, if an optimal result is to be achieved.
- A high-concentration collagen is used to enlarge the lips. When carrying out lip augmentation for the first time, it is advisable to begin filling-in at the margin of the lip, i.e., at the transition of the lip from red to white. The needle should be inserted along the edge of the lip at an angle of 10–20°, starting at the corner of the mouth and working toward the center. Ideally, the material should be distributed along the vermilion border, thus redefining the contours. Up to 4 ml of collagen may be injected per session, depending on the extent of lip augmentation.
- After the treatment is completed, dexpanthenol ointment should be applied evenly to the injection sites and the treated areas should be compressed under slight pressure for approx. 15 min. Avoid sun and alcohol for 24 h. Make-up can be worn again 1 day after the operation. The patient is also able to return to work 1 day after the operation.



This is a 38-year-old female patient with a deep nasolabial fold.  
Injection of 1 ml collagen on each side.  
Follow-up after four months with smoothed nasolabial fold.



This is a female patient with forehead wrinkles.  
Injection of hyaluronic acid.  
Findings after 4 months – smoothed forehead wrinkles.

### Crystalline Polylactic Acid

Polylactic acid is available as a lyophilisate that is dissolved with water for injections. In addition to microspheres, polylactic acid contains the products carboxymethylcellulose and mannitol. Poly-L-lactic acid is biocompatible, immunologically inactive, and biologically absorbable. Synthetic production is used; therefore skin testing is not necessary\*.

- Indication: deep folds, to provide contours and to build up volume, e.g., nasolabial folds, marionette folds, and cheeks, possibly chin, scars, and upper lip. Also to build up the cheeks in cases of lipoatrophy.
- Mechanism: after Sculptra® has been injected, the wrinkle is mechanically filled with the injected volumes. The water contained in the suspension is, however, absorbed by the body within a few days and the wrinkle returns. A gradual and natural build-up of volume is achieved only after this as a result of the formation of new collagen fibers. This provides a lasting effect which, in a good case, may last for more than 2 years. Induration may sometimes occur.
- Contraindications: allergy to one of the components; acute or chronic skin diseases: injections in the vermilion of the lips.
- Explanation of procedure: a written declaration of consent must be obtained from the patient regarding possible complications such as hematomas, swellings, reddening of the skin and formation of nodules.
  - Injection depth: deep dermis to the border to the subcutis.
  - Materials required: poly-L-lactic acid (Sculptra®)  
Water for injections  
Possibly local anesthetic
  - Storage: at room temperature (not above 30 °C)

\* Aventis Pharma Deutschland GmbH, Königsteiner Strasse 10, 65812 Bad Soden, Germany.

---

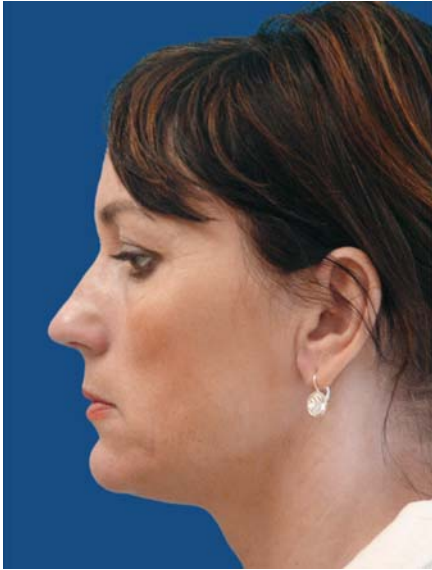**Usage:**

- Reconstitute the lyophilisate with 5 ml water for injection (note: it can also be dissolved with 4 ml water and 1 ml local anesthetic). Add the water to the bottle slowly and allow to stand for at least 2 h so that the water can penetrate the lyophilisate
- reduce photographic documentation prior to treatment.
- Possibly local anesthesia (cream or regional anesthesia).
- Disinfect skin.
- Shake the bottle well until the suspension is homogeneous, immediately before use Shake again before opening the bottle in every case!
- Use a 26-Ga needle for injection.
- Check that the injection needle is unobstructed before every injection is given.
- Linear injection technique: first insert the full length of the cannula, then inject with a slight punching pressure when withdrawing the needle. Inject only small quantities (0.1–0.2 ml per injection).
- Then massage the area of the face treated (preferably with cream to reduce the friction) and cool if necessary to reduce the swelling.
- Aftercare: cooling until the swelling has reduced. Massage the areas of the face treated for a few minutes over several days.

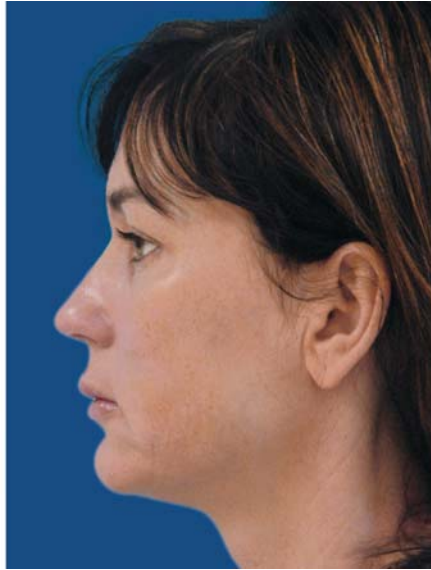---

### **Contouring Using the Mang Method**

This involves combined treatment with NewFill® for the deeper layers of skin (subcutaneous linear injection technique) and Viscontour® for the superficial wrinkles (epidermal point-by-point injection technique). Our experience has shown that combined treatment with the lactic acid product Sculptra® and the hyaluronic acid product Viscontour® produces good results in the long term although neither material is alloplastic.



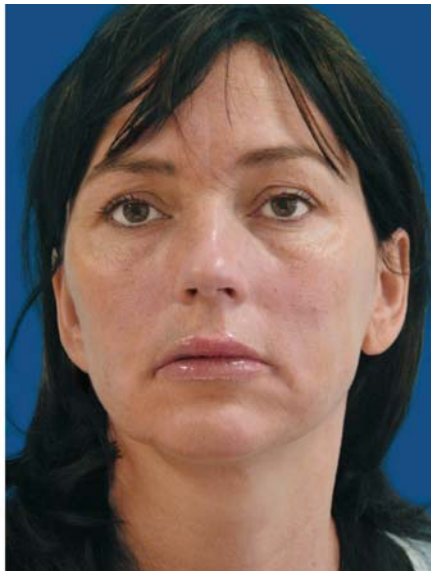Before treatment



After treatment



Before treatment



After treatment

---

### Botulinum Toxin

Horizontal lines and glabella wrinkles are often difficult to remove surgically. The forehead is made up of numerous mimicry muscles that cannot be entirely smoothed-out even following a brow lift (endoscopic, coronal, or hairline cut). Botox is therefore an important resource for removing wrinkles in the forehead region. Patients are amazed at the results and even accept that the injections will have to be repeated after 4–6 months if they want to have a smooth forehead.

Botulinum toxin must be injected by an experienced doctor under sterile conditions in the clinic, with the treatment carried out as day-case surgery. Otherwise, significant complications may occur, including paralysis of the eyes. The preoperative marking of the injection sites is particularly important if adverse side effects are to be avoided. The patient should frown so that it is possible to see the area of maximum muscle activity. Particular care should be taken in the supraorbital region and lateral to the pupillary boundary (illustrations).

No more than 1.5 ml botulinum toxin, corresponding to 60 U of Botox, should be injected per session. Treatment should be repeated after 4 months at the earliest. It is safe to give three injections per year.

As the ampules supplied by the company contain 2.5 ml botulinum toxin, which is dissolved in non-preserved saline solution, it is advisable to inject 1.2 ml per session. To avoid wasting of the material it is always advisable to treat two patients at the same time.

It is possible to treat periorbital wrinkles, perioral wrinkles, a drooping corner of the mouth, and wrinkles in the chin and neck (platysma), as well as forehead wrinkles, with botulinum toxin. The platysma can extend over the thorax as far as beyond the second rib and is above the fascia here. Diagonal neck wrinkles can be treated via 6–12 injection sites. These should be positioned in the shape of an upside-down triangle and 4 U of Botox should be injected at each site, at intervals of 1 cm with the needle at an angle of 45°. This treatment can also be combined with a facelift, but we recommend that botulinum toxin is not be given intraoperatively while the patient is under anesthesia. Botulinum toxin should not be given until the second day after the operation for medicolegal reasons.

More information can be found in Volume I, pp. 244–250.



---

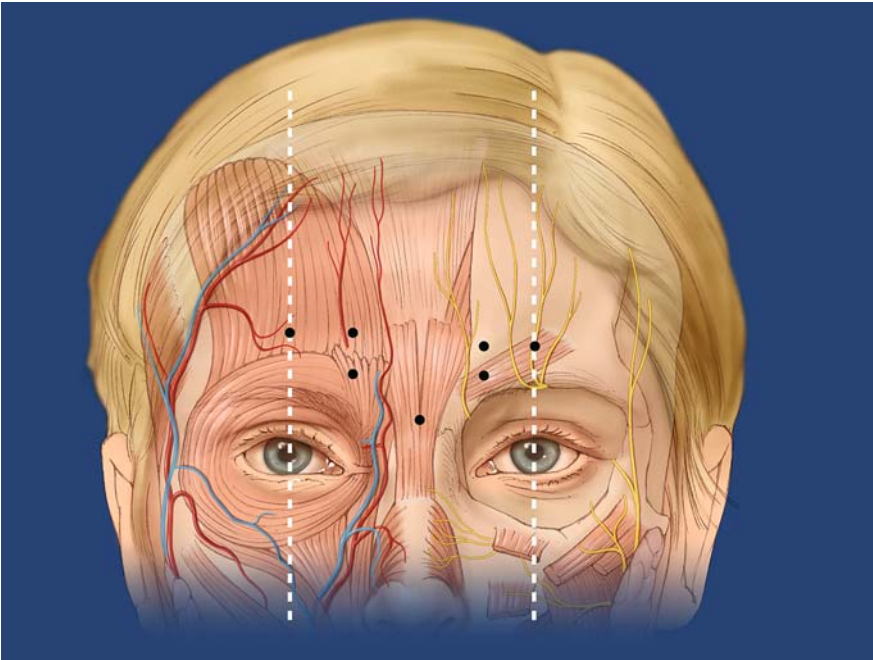
### Report – Technique

- Little material is required for botulinum toxin injections. The ampule contents are dissolved in 2.5 ml of a non-preserved saline solution. The suction of the syringe plunger is evidence of the vacuum inside the ampule.
- For the injection, we use a convention insulin syringe with appropriately fine graduations (4 U of botulinum toxin correspond to 0.1 ml). It is recommended that the novice use syringes with a volume of 0.3 ml so that the dosage of the injections can be even more accurate.
- The injection is made directly into the center of the muscle with a 30-Ga cannula. In the forehead and glabella regions, it is recommended that the injection be made at an angle of 90°, vertical to the periosteum. The syringe is then pulled back slightly until the center of the muscle is reached. The material, usually 0.1 ml, is then injected. The injection quantity is lower/fewer units are injected in the perioral and periorbital areas, i. e., 2–3 U.
- The marking of the injection sites prior to the operation is particularly important if adverse side effects are to be avoided. The injection must be made under sterile conditions following prior careful disinfection.
- In women with highly arched eyebrows, the muscles of the forehead are not highly developed. They have a lower mass and therefore only a small amount of Botox is required for paralysis. The fixed points for the injection in such cases are the midline between the two eyebrows, and on the vertical line from the inner canthus to the upper margin of the osseous orbit as well as 1 cm cranial to this.
- In women with more horizontal eyebrows, the muscles are more highly developed, and a slightly larger quantity of botulinum toxin is therefore required. Additional injections can be made 1 cm above the osseous margin of the orbit in a line running from the middle of the pupil in a cranial direction. There is a danger of ptosis if material is injected lower than this.
- In patients with pronounced horizontal wrinkles caused by the activity of the frontalis muscle, the injections are made along an imaginary horizontal line between the eyebrows and hairline in the vertical line running from the pupil in a cranial direction. Further injections are made between these two points. Additional sites can be defined individually depending on muscle activity and the depth of the wrinkles in the forehead area.

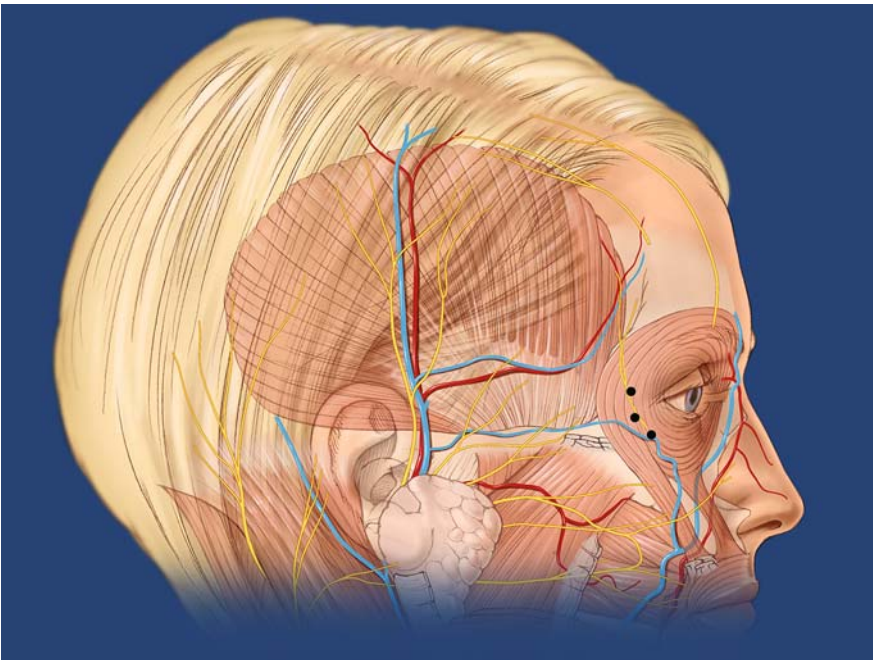
- 
- Eyebrows that appear too straight and droop at the sides can be lifted with injections. In this procedure, botulinum toxin is injected into the upper lateral section of the orbicularis oculi muscle at a site close to the orbital margin, 1–2 cm above the lateral corner of the eyelid. Applying a counterpull to the frontalis muscle causes slight raising of the lateral eyebrow.
  - Crow’s feet are treated with one injection 1.5 cm lateral to the canthus and two injections cranial and caudal to this point. The osseous orbit serves as a point of orientation. Tensioning of the orbicularis muscle can sometimes create a tense or bitter facial expression. By injecting Botox into parts of the ring muscle, this can be modified to give the patient a more friendly facial expression. The injections are made directly below the edge of the lower eyelid in the mid-pupillary line. During the injections, the patient should have his or her eyes open and be looking upwards.
  - Depending on how vigorously the orbicularis oris muscle is contracted, 2–4 injection sites are distributed in a line along the lip margins, i.e., one point lateral to the philtrum on the left margin of the lips and one on the right, and one further point.
  - Furrows develop over the years as a result of the pull of the depressor anguli oris muscle and these run from the corner of the mouth in a caudal direction. The injection is made into the center of the muscle, which can be identified by palpation, approx. 1 cm lateral and 1 cm caudal to the corner of the mouth.
  - If the skin is highly elastotic, contraction of the mentalis muscle may result in the chin having a “cobblestone” appearance. Botulinum toxin (0.1 ml) is injected at two paramedial injection points, approx. 0.5–1 cm above the tip of the chin.
  - The platysma can be inactivated by botulinum toxin so that the neck appears smooth when tensioned. Treatment should be started with low doses. The experienced doctor can then extend the injections to the entire face with the following units:

---

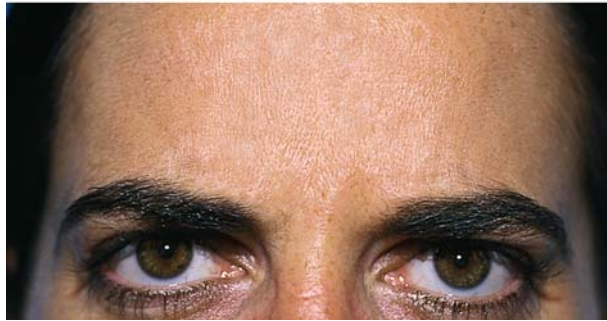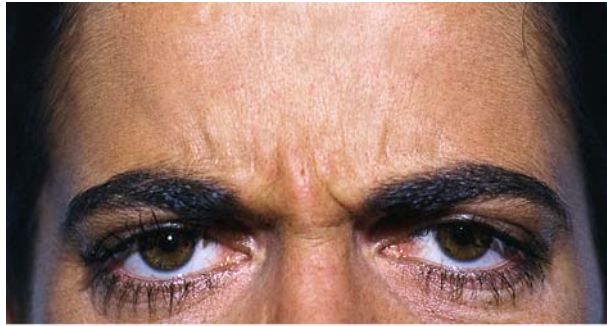Diagram of the injection sites in the forehead and peri-orbital region ▶  
 Please note: No injections should be made lateral to the midpupillary line owing to the risk of disorders in the eyebrow and upper lid region.



No injection lateral to this line



- 
- Twenty units of botulinum toxin, injected into the procerus muscle and the middle of the corrugator supercilii muscle, divided into several individual doses, are sufficient to smooth “anger wrinkles.” To reduce the activity of the frontalis muscle, treatment should be with a total dose of around 16 units per session. The treated areas are compressed briefly after the injection. The patient must then keep his/her head upright.
  - Three units of botulinum toxin per injection site are used to smooth crow’s feet in the area of the eyes. In the perioral area, 1–2 U are injected per injection site with the needle at an oblique angle, inserted only slightly and pointing in a cranial direction.
  - To lift the corner of the mouth, 3–5 U are injected into the center of the depressor anguli oris muscle. The center is identified by palpation.
  - In the chin region, 3–5 U injected at two injection sites in the area of the mentalis muscle will be sufficient to achieve a smooth appearance. The injection should be vertical and in the direction of the periosteum.
  - When treating the submental region, the platysma should be contracted and held between the thumb and index finger (platysmal bands). Four units of botulinum toxin are injected subcutaneously, directly into the platysma at intervals of 1 cm with the needle at an angle of 45°.
  - There are many indications for the use of botulinum toxin and the aesthetic surgeon must gradually push the boundaries to be able to achieve good results without risks.



A 37-year-old patient with pronounced forehead mimcry.  
Injection of 1.0 ml botulinum toxin in the forehead area following prior marking of the injection site.  
Findings 3 months after treatment.

---

## Mang's Spacelift

### Introduction

The name spacelift was chosen by the author and protected by patent (no. 30323891) as appropriately purified and centrifugated, recycled fat droplets are injected into the entire face, as in a honeycomb, using microinjections. The fat particles break down but, as a result of the contact with vessels (because they are not injected in large quantities in a bolus dose), they are able to form their own fibroblasts and the catabolized fat cells are augmented with fibroblasts and elastin fibers. Virtually no scars are formed and the face stabilizes as a result of the procedure. Naturally, injections can be made beneath other wrinkles in the forehead and nasolabial area using a conventional fat injection technique. Lipotransfer is also recommended for lip augmentation.

(Further information on lipotransfer in Volume I, p 240–243)

### Indications

As early as 1893, Neuber reported that adipose tissue transplant material could survive only in the smallest particles. This is the most important condition for a successful fat transplant.

In 1922, Lexer stated that if the adipose tissue is not damaged by bleeding either when it is removed or when it is implanted, it can survive for 3 years.

In 1950, Peer announced that up to 50% of transplanted fat survives if excessive negative pressure is not exerted on the fat during extraction by suction and excessive positive pressure is not exerted on the fat during injection. Vascularization of the fat droplets takes place after 4 days and until that time survival is guaranteed as a result of diffusion.

In 1986, Coleman reported that fat can only survive as a tissue compound and not as an individual cell. Oil, blood, and local anesthetics must be separated from the structural fat by gentle centrifugation. The individual particles of adipose tissue must be positioned close to the vessels to be fed to facilitate independent anchoring in the surrounding tissue. Thus, all the criteria for a stable transplant would be fulfilled.

---

**Indications:**

- To replace atrophied or wasted structures resulting from aging or the sequelae of inflammatory skin diseases (e.g., acne)
  - To strengthen existing structures
  - To create harmonious and aesthetically pleasing facial features by replacing wasted tissue with fan-shaped, three-dimensional implantation of autologous fat particles
  - Congenital or acquired deformities of the osseous and connective tissue structures (sequelae of burning, blunt soft-tissue injuries, facial fractures, cleft lips, midfacial hypoplasia, hemifacial atrophies, micrognathia)
- The overall appearance of the face and the proportions can be improved by emphasizing specific facial structures (e.g., the chin appears smaller when the lips and the margins of the lower jaw are augmented).
  - The fat must be removed under sterile conditions in the operating room.
  - Sites for fat removal are those where contours can be achieved without creating hollows (e.g., double chin, lower abdomen, medial side of the thigh, knee).
  - Following tumescent anesthesia, the fat is removed using low-vacuum liposuction ( $-0.2$  atm; this is approximately 20–30 % of the vacuum used with normal liposuction) with a blunt 2 ml suction cannula.
  - The diameter of the cannula openings should correspond to a Luer-Lock so that the fat particles can pass through the equipment without being damaged further during the later transplantation = gentle curettage of the tissue with minimal vacuum.



---

### Instruments

- Tumescence pump syringe [1]
- Handpiece [2]
- Suction cannulas [3]
- Sterile holder for centrifuge with syringe [4]
- Centrifuge, see video
- Syringes 10 ml and 1 ml with adapter Luer-Lock [5]
- (Use, see video)

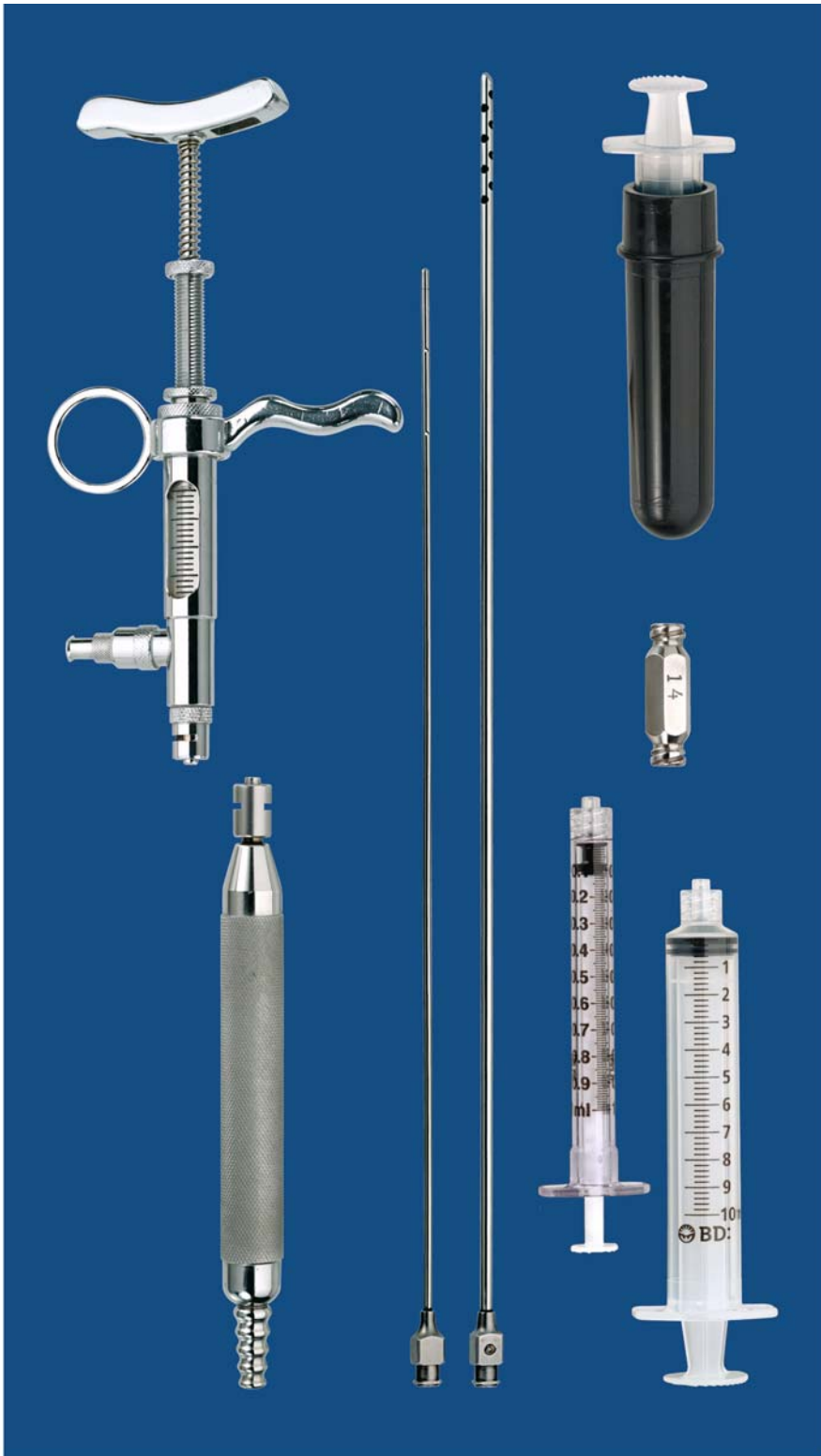### Technique

- If suction is performed using a conventional liposuction system, the fat is now transferred to 10 ml syringes under sterile conditions. The plungers are then removed from the syringes. The syringes are placed in a centrifuge and spun at 3,000 rpm for 4 min.
- This separates the aspirate into three layers:
  - The top layer consists of oil and ruptured fat cells; this is drained and carefully dabbed away.
  - The bottom layer consists of tumescence solution and blood; this is drained off.
  - The middle layer is made up of usable subcutaneous adipose tissue; using an adapter, this is transferred into a 1 ml Luer-Lock syringe without traumatization.

### Injection Technique

- The fat should be injected in a fan shape and in two to three layers. The face is built up and stabilized with fat droplets using a three-dimensional technique, as if in a honeycomb.
- The supraorbital, infraorbital; and mental nerves can be blocked to provide anesthesia. The individual injection sites may also be treated with local anesthesia.
- The fat removed using the tumescence technique is spun at 3,000 rpm for 4 min so that only vital, purified fat is used for the fat injection. The fat is transferred into 1-ml Luer-Lock syringes using a special adapter. The globules of fat can be positioned, as if they are a string of pearls, using a 20- or 23-Gg needle. This ensures surface contact with the surrounding capillaries and also allows the fat implants to become firmly anchored in the surrounding connective tissue.





- Three-dimensional implantation of fat globules is particularly effective. With this technique, several channels are placed on top of one another in a fan-shaped pattern at various levels within the subcutaneous tissue. It is best to begin with the deepest fan-shaped layer and then place the fan-shaped layers on top of one another. In addition, particularly pronounced mimicry wrinkles on the forehead and in the nasolabial area can be treated separately using the intracutaneous serial point-by-point technique with a fine needle, in a similar way to the point-by-point collagen technique.
- It is important that all the areas treated by injection are massaged with the finger when the treatment is completed so that there is no bulging and no nodules form. This applies particularly to sites treated by injection in the lip, nasolabial, zygomatic arch, and forehead areas. Lip modeling can be performed easily with this technique, but three injections will be required (at 0, 6, and 12 months).
- The survival of the transplanted fat globules can only be guaranteed if the maximum distance to well-perfused host tissue is 1.5 mm. Otherwise, the fat transplant will die, it will be absorbed, or it will become calcified.
- First, a tunnel is created at the tip using the cannula and without exerting any pressure. This is filled with purified fat when the cannula is pulled back, by exerting slight, uniform pressure on the plunger. A row of channels is then created with the cannula, and these are filled with fat when the cannula is pulled back.
- Compression bandages are only necessary if there is concern about possible displacement of the implant. Areas with pronounced mimicry, e.g., the glabella, are immobilized with Steri-Strips. Cooling for 2–3 days is advisable. Antibiotic cover is given.
- Several sessions (up to three) are usually necessary, as the connective tissue septa of the subcutaneous tissue will only allow in a certain quantity of adipose tissue transplants. Otherwise, the fat globules will be traumatized. A certain amount of edema also always develops in the host area as a result of the infiltration.

---

### Possible complications:

- Edema indicating repair processes in the many small channels created; possible for up to 4 weeks.
- Hematomas (owing to incorrect technique).
- Overcorrection, undercorrection.
- The formation of palpable and visible nodules, even in the tissue surrounding the defect, can be avoided if a fan-shaped implantation technique is used.
- Fat necrosis occurs if too much fat has been implanted in a limited host area.  
Please note: the maximum distance permitted from the center of the fat droplet to the surrounding capillary tissue is 1.5 mm. Otherwise, fat necrosis and possibly calcification may occur.
- Migration of the fat implant is possible if the injection is made into muscle or firm connective tissue.
- Infections.
- Nerve and vascular damage is virtually ruled out if blunt cannulas are used.

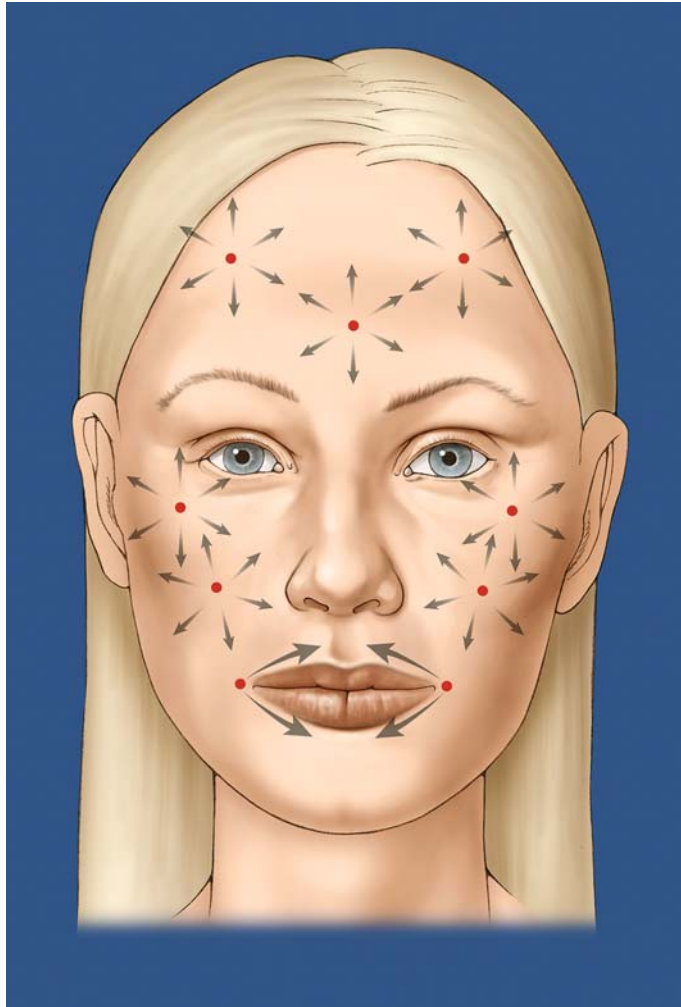
### Advantages of lipotransfer:

- The fat globules can be obtained easily using liposuction.
- The transplant is autologous.
- No immunological reactions/complications are to be expected.
- Fat can be injected below all wrinkles and depressions if the correct technique is used.
- It is possible to repeat the treatment without any problems.
- The costs are comparatively low.

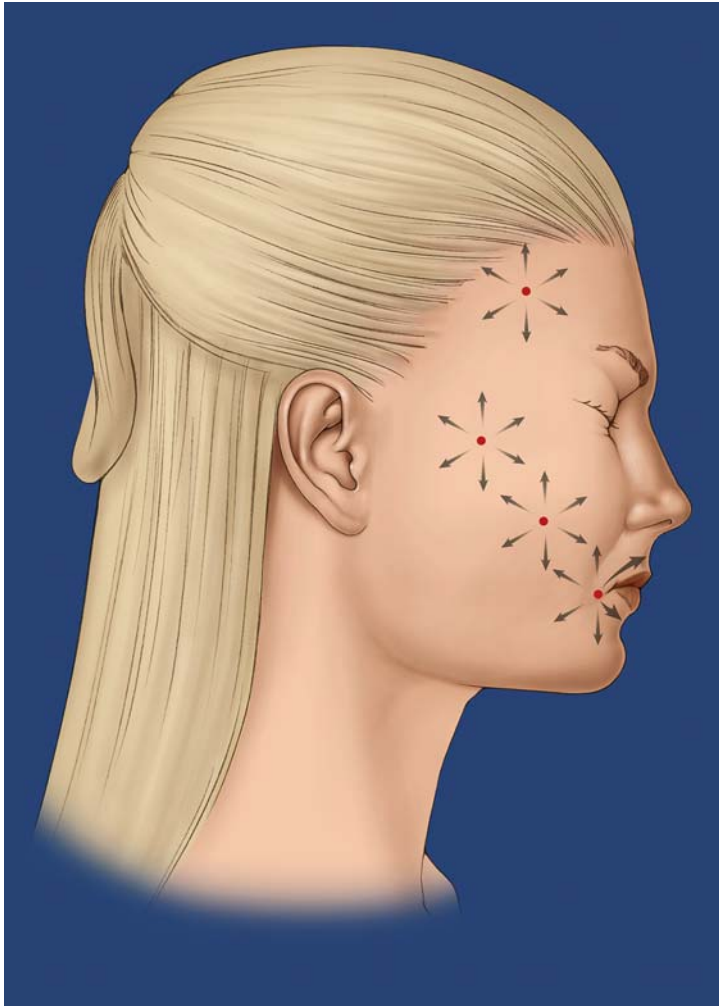
Surplus aspirated fat can be frozen (e.g., 2×10 ml) and reinjected again in divided doses (at 0, 6, and 12 months). The fat should be stored at -18 °C for no longer than 1 year.

Remove the syringes filled with fat from the freezer 3 h before reinjection. Each fat transplant should be marked with the operation date and the patient's name and date of birth.

As a result of the divided and repeated injection of fat cells, increased fibrosis (booster effect) occurs and this ensures a longer-lasting effect.



Frontal injection sites



Lateral injection sites

---

### **Diagram of the Fat Injection**

Ideally, the fat will be injected in drops into the infrastructural connective tissue (ICT) in a three-dimensional way. This ensures surface contact with the surrounding capillaries and allows the fat to become anchored in the surrounding connective tissue. It is transformed into separate scar and connective tissue as a result of fibroblast activity, which ensures the facial skin is stabilized and acts as a prophylaxis against aging.

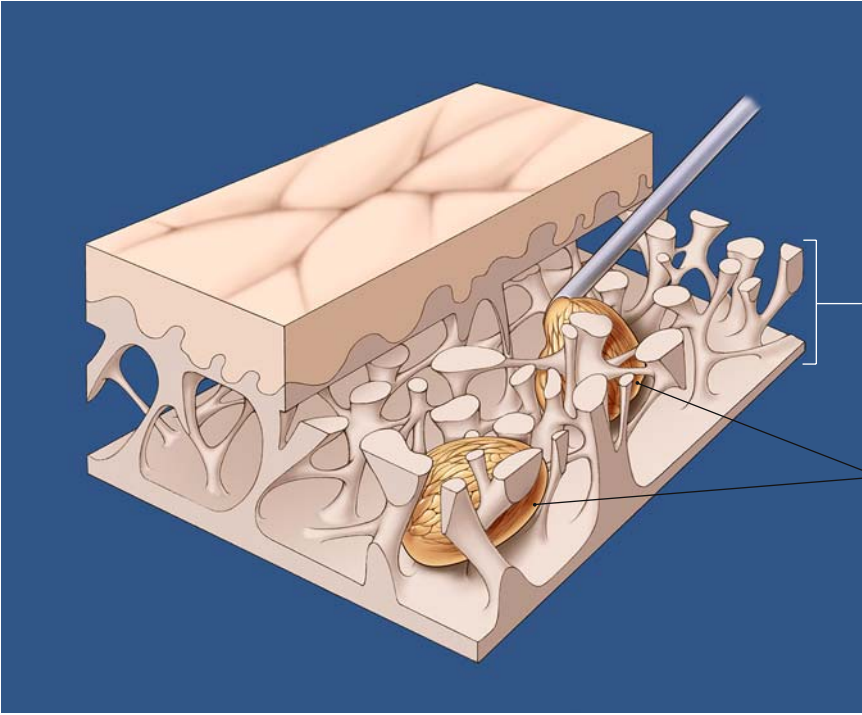
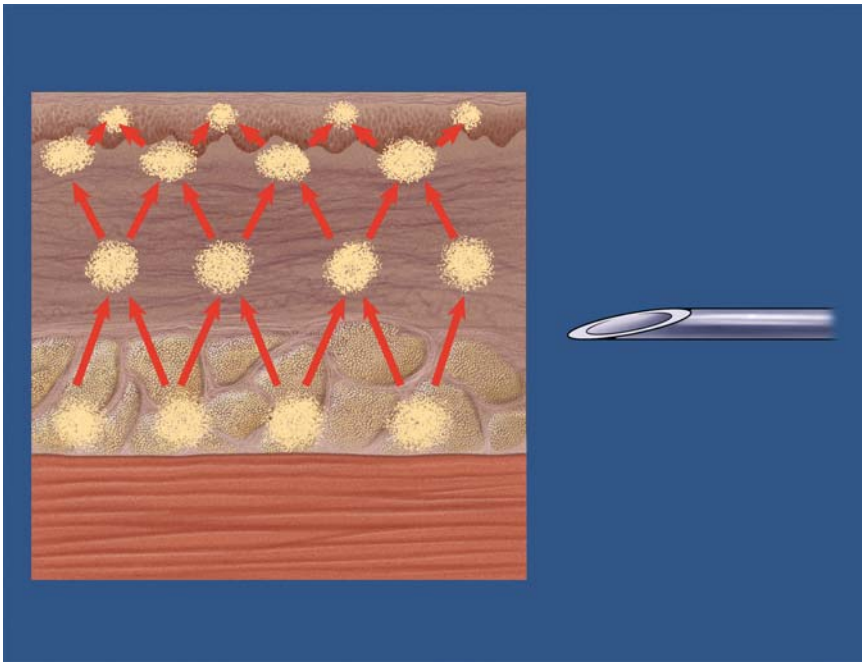
A spacelift is not recommended if there are hanging areas of skin. A spacelift can postpone the need for a facelift but is not a substitute for one.

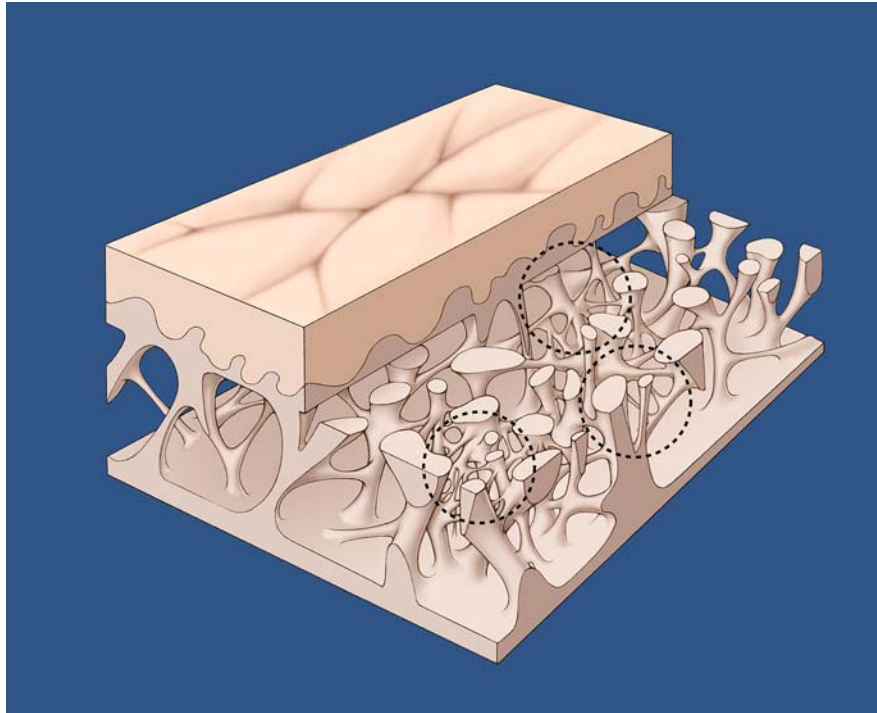
---

### **Three-Dimensional Diagram of Fat Injection into Subcutaneous Tissue**

The fat droplets lodge themselves in the subcutaneous tissue. If positioned correctly, and because they are not injected in a bolus dose, they become associated with the capillaries and consequently, following appropriate transformation, they help to stabilize the infrastructural connective tissue (ICT).

Infrastructural  
connective  
tissue (ICT)



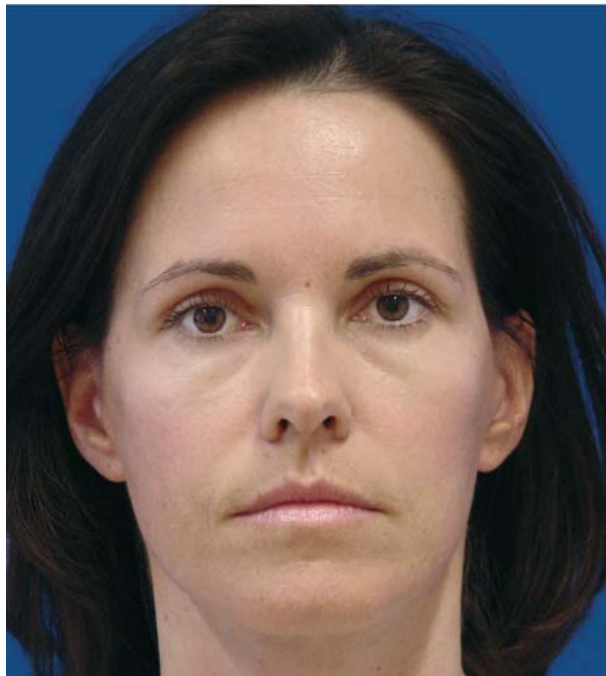

Breakdown/transformation of adipose tissue as a result of fibroblast activity

### **Increasing the Density of the Connective Tissue Following Breakdown of Fat Droplets**

The loss of elastin and collagen fibers caused by aging can be partly offset with the breakdown/transformation of adipose tissue as a result of fibroblast activity. The absorption rate for fat is different for every patient, so even this procedure must be carefully explained. Even though this method does not offer eternal youth, the spacelift is a step forward towards the goal of biological anti-aging.





A 39-year-old female patient with drooping eyelids, nasolabial and lip wrinkles, and a tired facial expression.

Findings 6 months after the operation following two fat injections (First session 15 ml, second session 8 ml).

---

## Dermabrasion

### Introduction

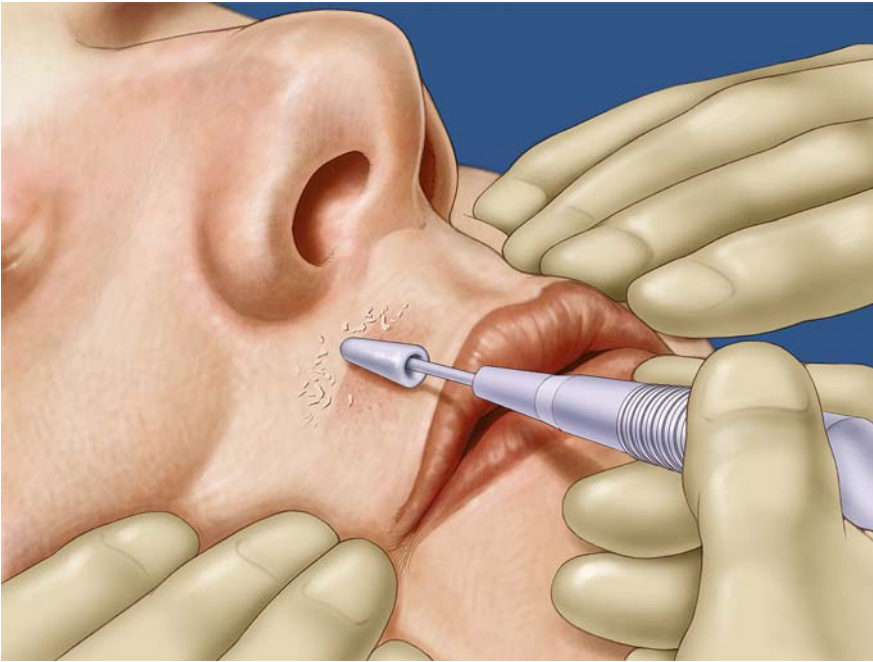Dermabrasion demands experience, skill, and concentration from the doctor carrying out the treatment. If performed well, the results for dermabrasion are very good, particularly in the perioral region and the area of the lips. The doctor's experience will determine whether he/she chooses to use chemical peeling, laser treatment, or abrasion treatment. This depends on the patient's age and skin type.

The abrasion head, which is coated with diamond dust, must be supported and held perpendicular to the plane of rotation. The pressure on the burr should always be the same to avoid creating grooves. Dermabrasion should not be performed below the level of the dermis. After-care consists of placing a wound gauze soaked in antibiotic ointment on the wound. This dressing is removed after 24 h. The face is treated with dexpanthenol ointment for a further 8 days. Make-up may be applied after epithelization of the wound surface. It is necessary to protect the skin from the sun or even avoid the sun for 3 months (pigment abnormalities).

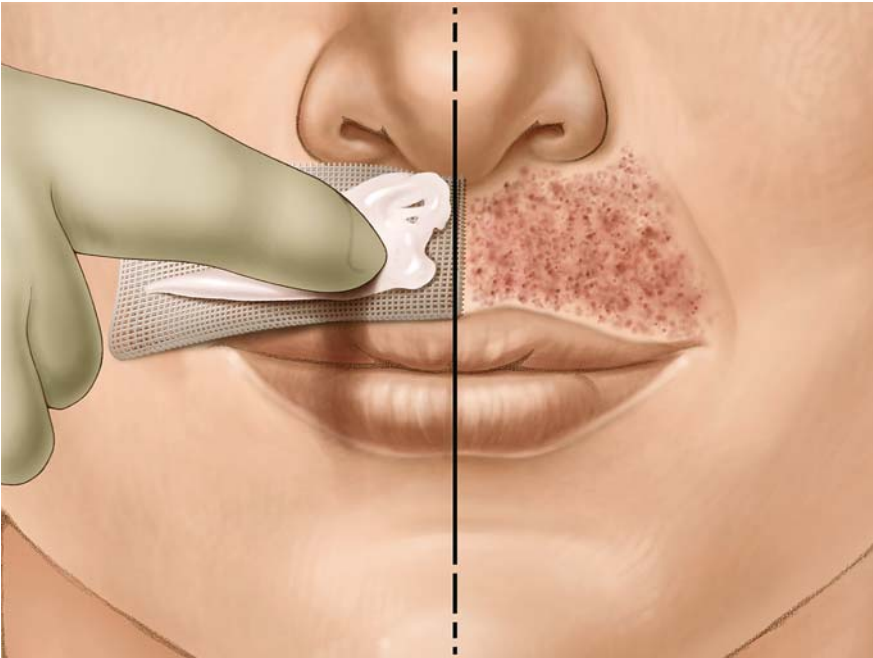
More information can be found in Volume I, pp 244–250

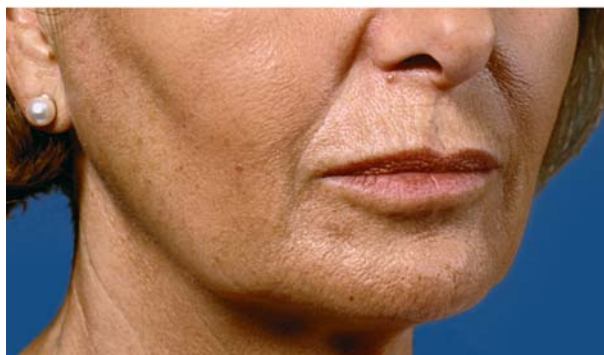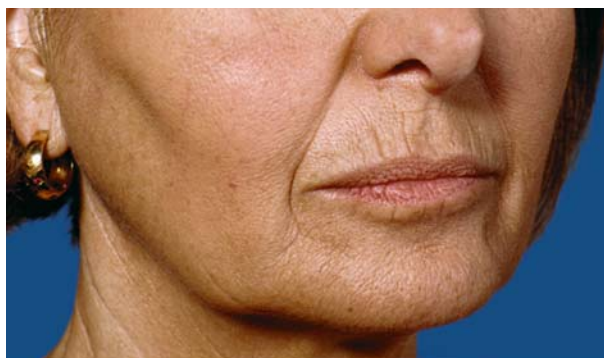### Report – Technique

- Protective goggles should be worn during the procedure. The operation site should be draped and disinfected carefully. The skin should be tightened by an assistant. Level/flat surfaces can be created by stretching the skin. This facilitates abrasion and permits the application of treatment at an exact depth. Skin tension must be maintained during the entire abrasion procedure. The abrasion head, which is coated with extremely fine diamond dust, must always be kept perpendicular to the plane of rotation. It should not be guided in the direction of rotation. Instead, it should be moved over the surface of the skin against the rotation of the abrasion head at an angle of 90° and slight pressure should be applied. Punctiform, superficial bleeding is the most reliable indicator that the grinding procedure has reached the optimal depth. Abrasion should not be performed at a deeper level.
- Dermabrasion is complete when an even wound surface with fine, punctiform/diffuse bleeding has been created. A wound gauze soaked in antibiotic ointment is then placed over the wound.



**Dermabrasion**





A 54-year-old patient with wrinkles in the perioral and upper lip areas. Findings 12 months after dermabrasion.

---

## Chemical Peeling

### Introduction

Chemical peeling falls into the dermatologist's sphere and can be studied in full in textbooks covering this field. The same applies to all types of laser treatment. These two procedures are therefore discussed only briefly in this manual.

Chemical peeling includes various types of peeling, which differ in terms of the intensity (e.g., fruit acid, glycolic acid, alpha hydroxy acid, trichloroacetic acid, phenol). The application of the agents appears simple, but experience is vital and an expert assessment of the skin areas is essential.

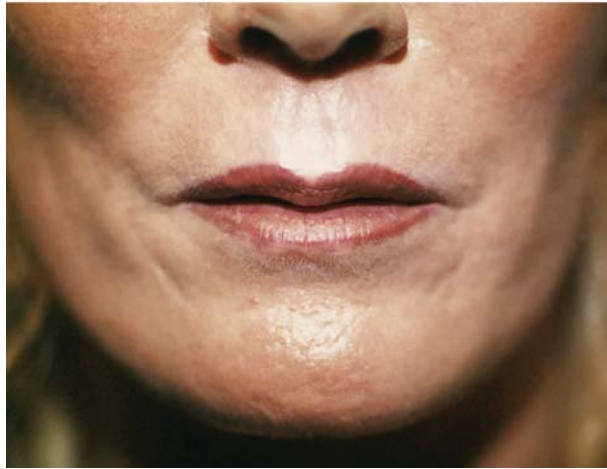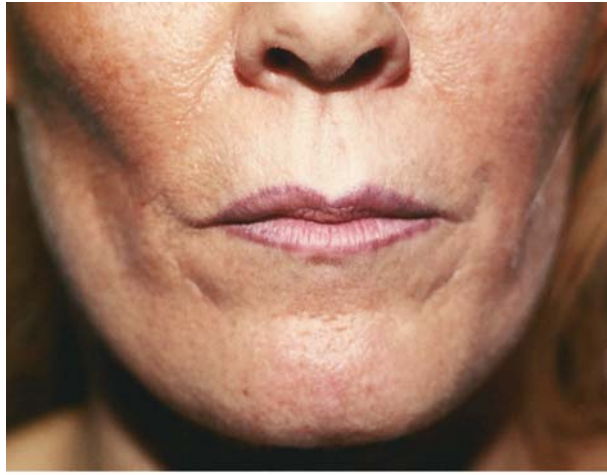The key to successful peeling is to apply the solution evenly and homogeneously, to provide accurate information about the risks (scarring and abnormal pigmentation), and to carry out the correct follow-up treatment.

Further information can be found in Volume I, pp 274–278.

---

**Report – Technique**

- The most practical, most effective, and safest method of chemical peeling for the novice is to use 30 % trichloroacetic acid. This removes the entire upper layer of skin, down to the reticular dermis. Nerve block anesthesia of the infraorbital and/or mental nerves can be used in patients who are particularly sensitive to pain, but local anesthesia using an occlusive dressing is usually sufficient.
- Following disinfection, the skin is treated with acetone to remove superficial skin scales. This allows better penetration of the acid into the skin. After the acid has been applied, the area to be treated is marked. The acid is applied homogenously over the entire surface at a consistent pressure. This is the true art of any type of peeling. The application of the acid may be repeated several times, depending on the depth of the wrinkles, using slight pressure. Each area of skin must be treated with the same intensity so that the skin relief does not vary later. The typical blanching, which is a sign that the treatment has started to take effect (frost effect), begins before the treatment has been completed.
- Follow-up treatment is with Vaseline as this reduces the sensation of tautness. Herpes prophylaxis with acyclovir 400 mg three times daily is recommended for 5 days as well as antibiotic cover.



Female patient with numerous wrinkles in the mouth region.  
Findings six months after chemical peeling with trichloroacetic acid.



---

## Erbium-YAG Laser

### Introduction

The euphoria generated by laser therapy in the 1990s has dissipated somewhat, as the long-term results of treatment for the aging face did not live up to all the expectations. Laser surgery will develop further in the future and the repertoire of the aesthetic surgeon is unimaginable without it, but its use must be considered very carefully.

Skin resurfacing with pulsed CO<sub>2</sub> laser treatment was explained in detail in Volume I of the manual, so only pulsed erbium-YAG laser treatment will be described briefly here. The advantage of using erbium-YAG laser treatment instead of CO<sub>2</sub> laser treatment is that there is less necrosis and the treated area heals more rapidly because of the lower thermal impact on deeper tissue layers. The lack of a coagulation effect, however, limits the treatment of wrinkles as it is presumed that the collagen structure will not change because the ablation is virtually non-thermal.

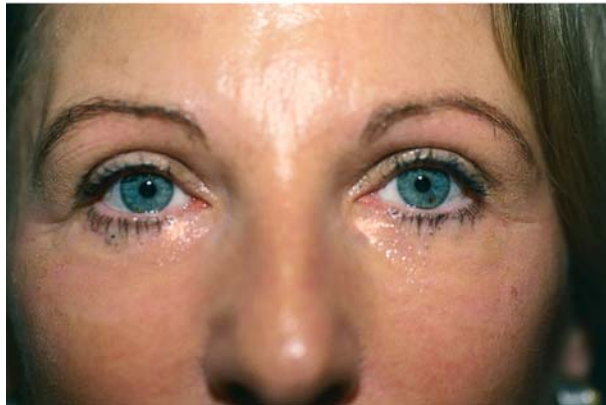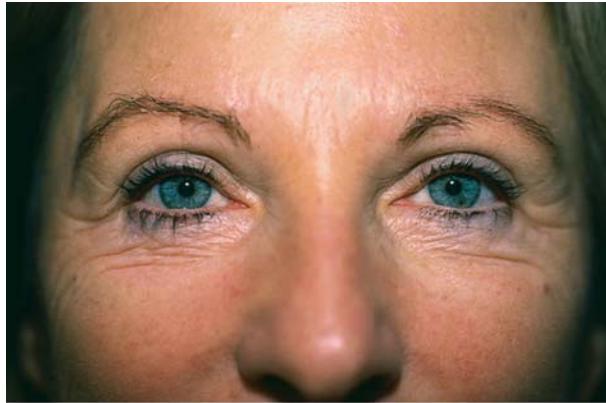In principle, pulsed CO<sub>2</sub> laser treatment can be used in all cases where erbium-YAG laser treatment is recommended, so an aesthetic surgeon should only purchase an erbium-YAG laser if his work focuses on anti-aging surgery of the face.

More information can be found in Volume I, p 269.

### Report – Technique

- Crow's feet in the lower-lid area can be treated well with the erbium-YAG laser. The advantage of this non-invasive procedure, which can be carried out on an outpatient basis, is the rapid healing of the treated sites. Following disinfection and anesthesia of the operation site (e.g., blocking of the infraorbital nerve), the boundaries of the section to be treated by laser are first defined. The laser is then guided evenly, section by section, over the area to be ablated. Slight overlapping will not be harmful. The use of the erbium-YAG laser as an additional resource during plastic/aesthetic procedures, e.g., facelift or blepharoplasty, is an elegant, non-invasive way of treating wrinkles and creases in aged and sun-damaged facial skin quickly, especially around the mouth and eyes and on the forehead and cheeks. When used correctly, possible risks such as abnormal pigmentation and scarring are virtually ruled out. The effect achieved is good when smoothing superficial and medium-depth skin wrinkles. When treating deeper skin wrinkles, there is definitely an improvement in the overall appearance, but the wrinkles cannot be





A 39-year-old female patient with deep lower-lid creases.  
Six weeks after erbium-YAG laser treatment.  
(First pass: fluence 5.7 J/cm<sup>2</sup> at 8 Hz,  
Second pass: fluence 4.2 J/cm<sup>2</sup> at 8 Hz)

completely removed. In this case, CO<sub>2</sub> laser treatment is more effective. Wound discharge and crust formation are less pronounced following erbium-YAG laser treatment and do not persist for as long as with CO<sub>2</sub> laser treatment. There is also less postoperative skin reddening and this reduces more quickly.

- Use of the erbium-YAG laser for patients who have aesthetically disturbing skin changes in the facial area that are not yet too severe can therefore enhance the spectrum of practical work performed by surgeons with an interest in skin surgery.

---

## Hyal System

### Introduction

The Hyal System makes use of the fact that native hyaluronic acid has a high level of biointeractivity and can therefore increase fibroblast activity and the neosynthesis of endogenous hyaluronic acid, elastin and collagen. Unlike highly cross-linked, chemically changed hyaluronic acids which are used exclusively as dermal fillers, the Hyal System\* injection technique attempts to create attractive tissue by building up the extracellular matrix of the skin areas in three dimensions using small droplets, a method similar to that used in a spacelift.

The desired effect is achieved in 6 weeks at the latest. It is intended more as prophylaxis against aging skin and can also be used in the area of the neck, chest and hands.

In 1934, Karl Meyer and John Palmer isolated hyaluronic acid (a glucosaminoglycan) from the vitreous body of a cow's eye. Hyaluronic acid, a linear polymer, is made up of the disaccharide units D-glucuronic acid and N-acetyl-glucosamine. It occurs naturally in human eyes, in joint surfaces, and in the skin. In the skin, it serves as a substrate of the cell structure and the extracellular matrix. In the dermis, it is associated with the elasticity and hydration of the skin. It also increases fibroblast activity and the neosynthesis of endogenous hyaluronic acid, elastin and collagen. Until very recently, hyaluronic acid was considered to be only a space-filling substance with a purely mechanical function. We now know that hyaluronic acid specifically modulates biological processes in humans and animals via endogenous membrane receptors. Depending on the area of application, we can therefore regard hyaluronic acid both as a medication with a long-term pharmacological effect and as a medical product when only the viscoelastic properties of this macromolecule are used. In aesthetic medicine, it is used to reduce skin wrinkles, to increase regional volume, and to treat scarring, as well as to improve skin tautness and strength.

---

\* Merz Pharmaceuticals GmbH, Eckenheimer Landstraße 100,  
60318 Frankfurt/Main, Germany.

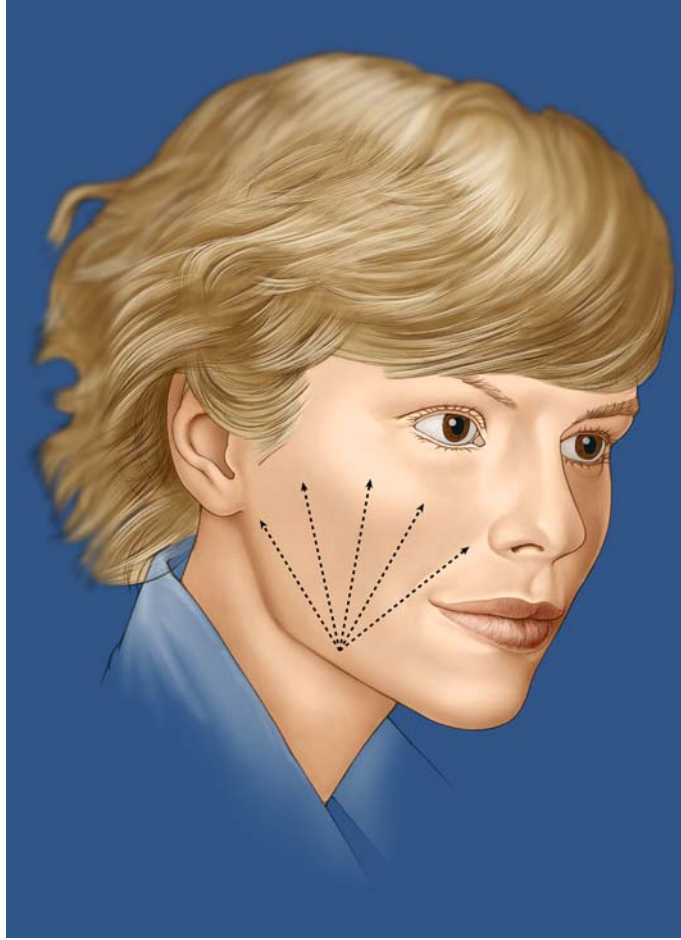
In general, it is possible to distinguish the two products.

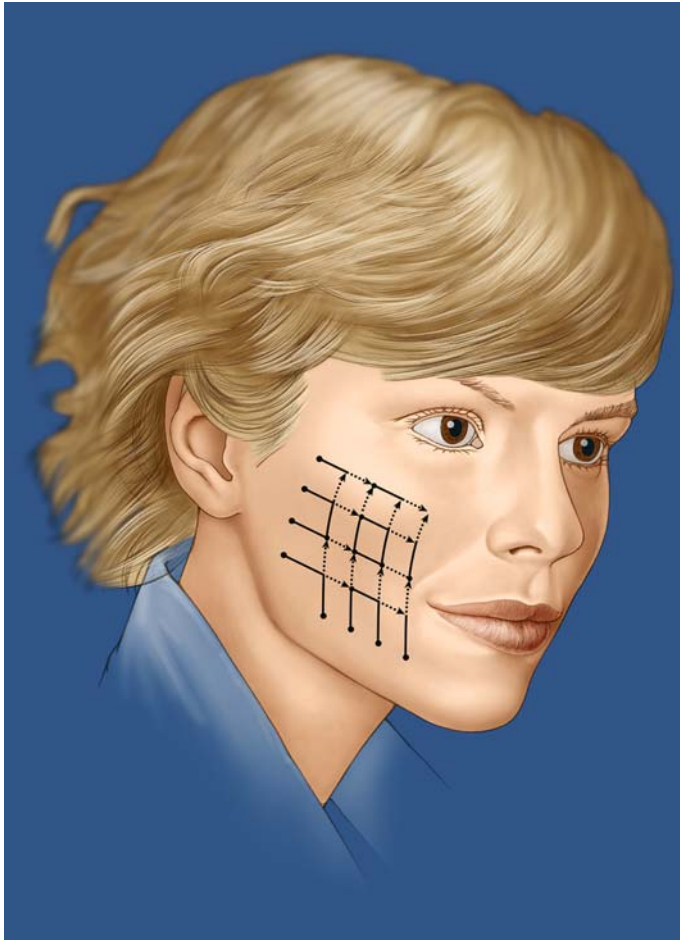
- **1. Dermal filler**
  - Highly cross-linked, chemically modified hyaluronic acid
  - Molecule inertia
  - Static skin implant
  - Mechanical increase in volume
- **2. Hyal System**
  - Native hyaluronic acid
  - High level of biointeractivity
  - Homogeneous distribution in the skin layers/surfaces
  - Biorevitalization with long-term effect

Hyal System is available in 1.1 ml ready-to-use syringes. This is a natural, chemically unchanged hyaluronic acid polymer (polysaccharide). The solution is highly concentrated and has a low viscosity and therefore has good flow properties in comparison with dermal fillers.

### Report – Technique

- Following surface or nerve-block anesthesia (supraorbital, infraorbital, mental) and disinfection, injection of the Hyal System into the papillary dermis via a 30-gauge cannula is started.
- The angle of insertion is normally 10–15° and the cannula should then be advanced parallel to the surface of the skin. Blanching of the skin will be visible if the injection has been given correctly. A cross-link, tunnel, or fan injection technique is used depending on the anatomical region. A serial point-by-point injection technique can also be used with appropriate indications (nasolabial). In the cheek region, a cross-link injection technique is used, i. e., following an imaginary, diagonal framework; injections are given either at every or at every second horizontal and vertical point of intersection, and the entire area to be treated is thus undermined. The needle is inserted at an angle of 10–15° and then moved so that it is parallel to the surface of the skin. This ensures the correct injection level (the papillary dermis) is reached. The injections are first made in a horizontal direction and the area being treated is then briefly compressed. The injections are then continued in a vertical direction.
- At the sides of the eyes, the tunnel technique is most suitable. Injections are made into the upper dermis in parallel lines.
- The cross-link technique is most suitable for treating the glabella and the upper area of the forehead because of the large area coverage. In modified form, this technique can be applied laterally.





- 
- To achieve a rejuvenating effect in the upper perioral region, the Hyal System is injected parallel to the upper lip in droplets. Similar injections are made parallel to the lower lip to complete this treatment.
  - The Hyal System can also be used to tighten larger areas of the neck, the décolleté region and the hands, and a modified cross-link technique must be used in these areas, i. e., systematic, even, and fan-shaped injections must be given over the entire area to achieve a satisfactory result. The aim is to establish fibroblast activity and neogenesis of endogenous hyaluronic acid, elastin and collagen.
  - Depending on the size of the areas to be treated, multiple syringes of 1.1 ml may be injected. We use 2 ampules per session.
  - In young patients who still have firm skin tone, three injections at intervals of 4 weeks will be necessary initially. Subsequent injections should be repeated every 4–8 months to maintain the result. In older patients with atonic skin and insufficient elasticity, three injections should be given at fortnightly intervals and boosters should then be given every 3–6 months.

#### **Follow-up Treatment**

- Following treatment, the undermined area should be compressed for approx. 15 min. The Hyal System is an innovative method to restore better quality to the aging skin. In the future, it is certain that there will be many useful developments in aesthetic surgery.

## Literature

- Alt TH (1991) Dermabrasion. In: Krause CJ, Mangat DS, Pastorek N (eds) *Aesthetic facial surgery*. Lippincott, Philadelphia, pp 623–641
- Aspacio RA, Wheeland RG (1992) Use of lasers in cosmetic surgery. *Am J Cosm Surg* 9:131–140
- Baker TJ (1962) Chemical face peeling and rhytidectomy. A combined approach for facial rejuvenation. *Plast Reconstr Surg* 29:199–207
- Baker TJ (1963) Chemical face peeling: An adjunct to surgical face lifting. *South Med J* 56:412
- Baker TJ (1978) Patient selection and psychological evaluation. *Plast Surg* 5:3
- Baker TJ, Gordon HL (1986) *Surgical Rejuvenation of the Face*. Mosby, St. Louis
- Brody HJ (1989) Complications of chemical peeling. *J. Dermatol Surg Oncol* 15:1010
- Collins PS (1989) Trichloroacetic acid peels revisited. *Dermatol Surg Oncol* 15:933
- DaSilva N (1962) Dermabrasion with miniature electric suction dermatome. *Plast Reconstr Surg* 30:690
- Gasparotti M, Lewis CM, Toledo LS (1993) *Superficial Liposculpture. Manual of Technique*. Springer, New York
- Gonzales-Ulloa M (1962) Facial wrinkles. *Plast Reconstr Surg* 29:658
- Graff D (1836) Örtliche erbliche Erschlaffung der Haut. *Wschr Ges Heilk* 225–227
- Johnson JB, Hadley RC (1964) The aging face. In: Converse JM (ed): *Reconstructive Plastic Surgery*. WB Saunders, Philadelphia, pp 1306–1342
- Kamer FM, Lefkoff LA (1992) Injectable collagen, chemical peeling and dermabrasion as an adjunct to rhytidectomy. *Fac Plast Surg* 8:89–92
- Klein JA (1993) Tumescent technique for local anesthesia improves safety in large-volume liposuction. *Plast Reconstr Surg* 92:1085–1098
- Kotler R (1992) Chemical rejuvenation of the face. CV Mosby, St. Louis
- Kromayer E (1905) Rotationsinstrumente: Ein neues technisches Verfahren in der dermatologischen Kleinchirurgie. *Chir Dermat Z (Berlin)* 12:26
- Levis GK (1954) Surgical treatment of wrinkles. *Arch Otolaryngol* 60:334
- Lexer E (1910) Zur Gesichtsplastik. *Arch Klin Chir* 92:749
- Litton C (1962) Chemical face lifting. *Plast Reconstr Surg* 29:371
- MacGregor FC (1953) Some psychological hazards of plastic surgery of the face. *Plast Reconstr Surg* 12:123
- Mang WL (1980). *Techniken und Methoden der modernen Medizin*. Steinkopff Verlag
- Mang WL (1983), Funktionell-Ästhetische Nasenplastik. *Ärztl. Prax.* 35:1206–1208
- Mang WL (1984) Bioimplantate in der HNO-Chirurgie. *HNO-Nachr* 58:58
- Mang WL (1984) Injectable collagen: A new biomaterial for the correction of aesthetically undesirable facial soft tissue defects. In: *Eur. Workshop of Injectable Collagen*, Genf
- Mang WL (1985) Technik und Ergebnisse der Behandlung mit injizierbaren Kollagen. In: Wolff HH, Schneller W (eds) *Fortschritte der operativen Dermatologie, Bd II*. Springer, Heidelberg New York Berlin
- Mang WL (1985) Zyderm Kollagen-Implant: Eine sinnvolle Ergänzung in der ästhetischen Kopf-Hals-Chirurgie? In: *Die Ästhetik von Form und Funktion in der plastischen und Wiederherstellungschirurgie*. Hrsg. G Pfeiffer, Springer, Berlin Heidelberg New York
- Mang WL (1992) *Ästhetische Gesichtschirurgie*. Steinkopff Verlag
- Mang WL (1996) *Ästhetische Chirurgie Bd I*. Einhorn-Press Verlag
- Mang WL (1998) *Ästhetische Chirurgie Bd II*. Einhorn-Press Verlag
- Mang WL (2002) *Manual of Aesthetic Surgery 1*. Springer, Berlin Heidelberg New York
- Mang WL, Permanetter W (1986) Injizierbares Kollagen – eine neue Behandlungsmethode zur Korrektur ästhetisch störender Altersveränderungen. Früh- und Spätergebnisse. In: *Plastische und Wiederherstellungschirurgie des Alters*. Hrsg. H. Neubauer. pp 221–228. Springer, Berlin Heidelberg New York

- 
- Miller CC (1924) *Cosmetic Surgery*. FA Davis, Philadelphia, pp 30–32
- Pangman WJ II, Wallace RM (1961) Cosmetic surgery of the face and neck. *Plast Reconstr Surg* 27:544
- Pitanguy I (1978) Ancillary procedures in face lifting. *Clin Plast Surg* 5:51
- Pitanguy I (1979) The aging face. In: Carlsen L, Slatt B (eds) *The naked face*. General Publishing, Ontario, p 27
- Pitanguy I et al. (1995) Submental liposuction as an ancillary procedure in face-lifting. *FACE*, vol 4 (1):1–13
- Pitanguy I et al. (1996) Skin resurfacing with the CO<sup>2</sup> laser. *Rev Bras Cir* 86:313–325
- Rees TD (1973) *Cosmetic facial surgery*. WB Saunders, Philadelphia
- Rees TD (1980) *Aesthetic plastic surgery*. WB Saunders, Philadelphia
- Schwab W (1994) *Atlas der Kopf-Hals-Chirurgie*. Kohlhammer, Stuttgart
- Schwab W, Mang WL et al. (1984) Was gibt es Neues in der plastischen Chirurgie im Kopf-Halsbereich für den praktizierenden HNO-Arzt? *Laryngol Rhinol Otol* 63:323–343
- Spira M, Dahl G, Freeman R, Gerow FJ, Hardy SB (1970) Chemosurgery – a histological study. *Plast Reconstr Surg* 45:247
- Spira M, Gerow FJ, Hardy SB (1974) Complications of chemical face peeling. *Plast Reconstr Surg* 54:397
- Walter C (1997) *Plastisch-chirurgische Eingriffe im Kopf-Hals-Bereich*. Thieme, Stuttgart
- Wilkinson TS (1994) *Practical Procedures in Aesthetic Plastic Surgery*. Springer, New York



---

## Prospects – What Is the Future of Aesthetic Surgery?

There has been a boom in aesthetic surgery all over the world and the rate of growth has doubled. The age of patients ranges from 14 to 80 years and every fifth cosmetic operation is now requested by a man. Research into new materials, implants, instruments and equipment, even robot-controlled operation modules, is important for the further development of aesthetic surgery, but these can never replace the skill of the aesthetic surgeon. A first-rate aesthetic surgeon must not only be well-trained; he must also be a psychologist and an artist if he wants good results.

The fundamental requirement, however, is correct training.

Aesthetic surgery is high-tech surgery. It has a fixed position in society and must establish itself as an independent, interdisciplinary specialty. Aesthetic surgery must no longer be taught as an appendage to the specialties of surgery, plastic surgery, ENT surgery or maxillofacial surgery, but must be taught over a 3-year advanced training period following high-quality surgical or plastic surgery training and acknowledged as a specialty with a recognized title. This is my hope for the future, as only this will make it possible for us to achieve worldwide quality assurance and make aesthetic surgery a recognized specialist surgical discipline.

Aesthetic surgeons should work together with specialists in all disciplines whom they could learn from, and with whom they should exchange their knowledge at conferences throughout the world, never forgetting the Hippocratic oath. Aesthetic surgery should not be “alteration surgery” but rather “well-being surgery.” We have understood our profession correctly if we are able to make patients feel good.

As president of the International Society of Aesthetic Surgery (ISAS\*), in the future I would like to give all young colleagues with an interest in this field an opportunity to become members and make the specialty of aesthetic surgery accessible in a yearly “exchange of ideas.” Only when the range of treatments is improved and developed further internationally, and there is a spirit of cooperation among surgeons, will we be able to gain better recognition within society for this field. I hope that this manual can play a part in this and my dream one day, of standardized training leading to the title “aesthetic surgeon,” will become a reality.

---

\* International Society of Aesthetic Surgery, Graf Lennart Bernadotte-Straße 1, 88131 Lindau, Germany.

---

Aesthetic surgery is a specialty of the future. Young doctors are extremely interested in this field. Doctors from all over the world visit Prof. Mang's clinic every day. *The Manual of Aesthetic Surgery*, Volumes I and II, forms the basis for comprehensive training in the field of aesthetic surgery.

The Bodenseeklinik offers an opportunity for interested doctors to apply the knowledge described in the two volumes of the manual in practical aesthetic surgery. A hospitality fee of 250 US dollars per day is charged for this. This money will be used by the Prof. Mang Foundation charity to help needy children.